Since January 2020 Elsevier has created a COVID-19 resource centre with free information in English and Mandarin on the novel coronavirus COVID-19. The COVID-19 resource centre is hosted on Elsevier Connect, the company's public news and information website.

Elsevier hereby grants permission to make all its COVID-19-related research that is available on the COVID-19 resource centre - including this research content - immediately available in PubMed Central and other publicly funded repositories, such as the WHO COVID database with rights for unrestricted research re-use and analyses in any form or by any means with acknowledgement of the original source. These permissions are granted for free by Elsevier for as long as the COVID-19 resource centre remains active.

CHAPTER FIVE

Smell deficits in COVID-19 and possible links with Parkinson's disease

Aron Emmi[a,b,c], Michele Sandre[b,c], Andrea Porzionato[a,c], and Angelo Antonini[b,c,*]

[a]Institute of Human Anatomy, Department of Neuroscience, University of Padova, Padova, Italy
[b]Parkinson and Movement Disorders Unit, Department of Neuroscience, Centre for Rare Neurological Diseases (ERN-RND), University of Padova, Padova, Italy
[c]Center for Neurodegenerative Disease Research (CESNE), University of Padova, Padova, Italy
*Corresponding author: e-mail address: angelo.antonini@unipd.it

Contents

1. Introduction 92
2. Clinical features of COVID-19 olfactory impairment 92
   2.1 Individual variables influencing COVID-19 olfactory impairment 92
   2.2 SARS-CoV-2 variants and their relationship with olfactory impairment 93
3. Neuropathology of COVID-19 olfactory impairment 94
4. Olfactory impairment in COVID-19 and parkinsonism 97
References 99

Abstract

Olfactory impairment is a common symptom in Coronavirus Disease 2019 (COVID-19), the disease caused by Severe Acute Respiratory Syndrome—Coronavirus 2 (SARS-CoV-2) infection. While other viruses, such as influenza viruses, may affect the ability to smell, loss of olfactory function is often smoother and associated to various degrees of nasal symptoms. In COVID-19, smell loss may appear also in absence of other symptoms, frequently with a sudden onset. However, despite great clinical interest in COVID-19 olfactory alterations, very little is known concerning the mechanisms underlying these phenomena. Moreover, olfactory dysfunction is observed in neurological conditions like Parkinson's disease (PD) and can precede motor onset by many years, suggesting that viral infections, like COVID-19, and regional inflammatory responses may trigger defective protein aggregation and subsequent neurodegeneration, potentially linking COVID-19 olfactory impairment to neurodegeneration. In the following chapter, we report the neurobiological and neuropathological underpinnings of olfactory impairments encountered in COVID-19 and discuss the implications of these findings in the context of neurodegenerative disorders, with particular regard to PD and alpha-synuclein pathology.

International Review of Neurobiology, Volume 165
ISSN 0074-7742
https://doi.org/10.1016/bs.irn.2022.08.001

Copyright © 2022 Elsevier Inc.
All rights reserved.

1. Introduction

Coronavirus Disease 2019 (COVID-19), the disease caused by Severe Acute Respiratory Syndrome—Coronavirus 2 (SARS-CoV-2), is often associated with a wide spectrum of neurological manifestations (Ellul et al., 2020; Helms et al., 2020; Huang et al., 2021; Iadecola, Anrather, & Kamel, 2020; Mao et al., 2020). Intriguingly, the COVID-19 pandemic brought to the attention of clinicians an astonishing number of patients affected by mild symptoms, the most frequent being a sudden and complete loss of olfaction, which may last for a variable period of time (Guerrero et al., 2021).

Often wrongfully regarded as an ancillary sense, olfaction covers a great role in our everyday life for its involvement in lifeguarding processes (e.g., avoiding dangerous chemicals), as well as in food evaluation. As the pleasantness of gustatory and olfactory stimuli represents an important contributor to patients' quality of life, olfactory impairment is also frequently associated to anhedonia, lack of motivation and depressive symptoms in patients with COVID-19 (Athanassi, Dorado Doncel, Bath, & Mandairon, 2021; Voruz et al., 2022).

Aside of the functional impairments deriving from olfactory dysfunction, the olfactory system directly links the brain to the external environment, representing a gateway through which many viruses, such as herpesvirus-1 and 6, may access the central nervous system (CNS) (Duarte et al., 2019; Harberts et al., 2011). Also, the olfactory system is involved in the pathogenesis of different neurodegenerative diseases, like Parkinson's (PD) and Alzheimer's disease (Sulzer, 2007), due to its connections to the entorhinal cortex and limbic system, suggesting special care for possible long-term consequences of viral infections. In this context, olfactory transmucosal invasion of SARS-CoV-2, and the inflammatory correlates of COVID-19 at the level of the olfactory system, must be carefully considered, as they may represent possible factors for the establishment, or the precipitation, of protein aggregation and neurodegenerative phenomena.

2. Clinical features of COVID-19 olfactory impairment

2.1 Individual variables influencing COVID-19 olfactory impairment

During the first waves of the COVID-19 pandemic, olfactory impairment was regarded as a common clinical feature experienced by numerous

patients. Early studies correlated higher propensity for acute olfactory loss with a more indolent course, but subsequent work suggested elevated prevalence of smell loss across most COVID-19 cases, regardless of severity (Brann et al., 2020). Hornuss et al. (2020) evidenced that olfactory alterations often occur unnoticed in COVID-19 patients, and that they do not represent a predictor of severe COVID-19 manifestations. Moreover, a substantial proportion of patients with previous mild-to-moderate symptomatic COVID-19 characterized by new onset of chemosensory dysfunction, still complained on altered sense of smell or taste 1 year after the onset (Brann et al., 2020). These long-term effects of COVID-19 on chemosensory functions have been investigated recently by Shelton et al. (2022), evidencing that only a restricted cluster of patients experience long-term smell loss. The authors discovered a genetic mutation in COVID-19 patients that was associated with a greater propensity for smell or taste loss. The mutation was found in two overlapping genes, called UGT2A1 and UGT2A2, encoding proteins that remove odor molecules from the nostrils after they have been detected. However, interactions between SARS-CoV-2 and the aforementioned genes remain to be clarified.

Among the main issues concerning the evaluation of individual olfactory outcomes in COVID-19, objective testing of olfactory function represents a major aspect of concern. In the case of chemical senses, two main objective tests have been developed and used over the years in the clinic, namely the Sniffin' Sticks (Hummel et al., 2009) and the University of Pennsylvania Smell Inventory Test (UPSIT) (Doty et al., 2014), while others are being developed. Their use is mandatory in order to have an objective evaluation of the level of impairment, since the subjective report is often misleading. However, they both require the direct testing of the patient, which may be difficult or impossible in the case of COVID-19 infected patients. Conversely, collecting data from patients may be of paramount importance to follow the disease, even though the utility of self-reporting about chemical sensitivity has been repeatedly questioned (Hummel et al., 2009).

2.2 SARS-CoV-2 variants and their relationship with olfactory impairment

Intriguingly, aside from intra-individual differences underlying more or less severe olfactory impairment in COVID-19, SARS-CoV-2 variants may as well affect olfactory outcome in the general populations. Coelho, Reiter, French, and Costanzo (2022) surveyed 616,318 people in the United States who had COVID-19. The authors found that, compared

to those who had been infected with the original virus, people who had contracted the Alpha variant—the first variant of concern to arise—were 50% as likely to have chemosensory disruption. This probability fell to 44% for the later Delta variant, and to 17% for the latest variant, Omicron. While this clinical data appears to be in line with a less severe clinical outcome associated with newer variants, no studies to date have examined the impact of different SARS-CoV-2 variants on the olfactory mucosa, either in animal models, or in the neuropathological setting. Thus, the pathophysiology of olfactory impairment in new SARS-CoV-2 variants, such as the recently circulating Omicron variant, remain to be investigated.

3. Neuropathology of COVID-19 olfactory impairment

Other coronaviruses, such as Severe Acute Respiratory Syndrome Coronavirus 1 (SARS-CoV-1), are known to enter the brain of transgenic mice via the olfactory bulb, leading to neuronal necrosis in the absence of encephalitis (Netland, Meyerholz, Moore, Cassell, & Perlman, 2008). Similarly, high levels of viral RNA were found in the brainstem and thalamus of transgenic mice following intranasal inoculation of the Middle-Eastern Respiratory Syndrome Coronavirus (MERS-CoV) (Li et al., 2016), suggesting for a common neuroinvasive potential.

As far as SARS-CoV-2 is concerned, most studies agree on the extensive inflammatory processes occurring in the olfactory mucosa and bulb of COVID-19 patients (Emmi et al., 2021; Matschke et al., 2020; Meinhardt et al., 2021; Schwabenland et al., 2021; Thakur et al., 2021), but often conflicting findings are reported concerning SARS-CoV-2 neurotropism. Douaud et al. (2022) investigated structural brain changes before and after a SARS-CoV-2 infection in a large sample of UK Biobank participants, revealing significant reductions in gray matter thickness and tissue-contrast in the orbitofrontal cortex and parahippocampal gyrus, along with prominent alterations in brain areas functionally connected to the primary olfactory cortex. Positron emission tomography (PET) hypometabolism in long COVID patients encompassing the olfactory gyrus and the connected limbic/paralimbic regions, extended to the brainstem and the cerebellum (Guedj et al., 2021), and in the right parahippocampal gyrus and the right thalamus (Sollini et al., 2021) was also reported.

From a neuropathological perspective, several studies identified SARS-CoV-2 viral antigens and genomic sequences through RT-PCR, immunohistochemistry, in-situ hybridization and even electron microscopy in the

human olfactory system (Khan et al., 2021; Meinhardt et al., 2021; Zazhytska et al., 2022). Meinhardt et al. (2021) detected SARS-CoV-2 Spike protein in primary olfactory neurons of the olfactory mucosa in a large sample of COVID-19 patients, suggesting an olfactory-transmucosal route of infection throughout the CNS, as testified also by the detection of viral RNA at the level of the olfactory bulb and the medulla oblongata.

Conversely, two recent studies found viral genomic sequences and antigens in sustentacular cells of the olfactory epithelium, but not in olfactory neurons (Khan et al., 2021; Zazhytska et al., 2022). This was associated with the reorganization of nuclear architecture and downregulation of olfactory receptors, as well as their signaling pathways, in neuronal cells of the olfactory mucosa, hinting towards a non-cell autonomous cause of anosmia (Zazhytska et al., 2022). Two studies of single nucleus RNA sequencing of brains of COVID-19 patients, focusing on the olfactory system and the choroid plexus, detected broad perturbations, with upregulation of genes involved in innate antiviral response and inflammation, microglial activation and neurodegeneration, but found no direct evidence of viral RNA in the tissue (Fullard et al., 2021; Yang et al., 2021). Similarly, authors have not detected viral proteins/ RNA through immunohistochemistry or in-situ hybridization, even though viral genomic sequences were found via RT-PCR assays (Lee et al., 2021; Solomon et al., 2020; Thakur et al., 2021). In concordance to these findings, animal model studies suggest that loss of smell is related to damage to the cilia and olfactory epithelium, but not infection of the olfactory neurons. For example, in an experiment where hamsters were nasally infected with SARS-CoV-2, the olfactory epithelium and cilia became very damaged, leading to anosmia, but no infection was observed in the olfactory neurons (Bryche et al., 2020). Furthermore, Brann et al. (2020) demonstrated that mouse, non-human primate and human olfactory mucosa express two key genes involved in SARS-CoV-2 entry, ACE2 and TMPRSS2. However, single cell sequencing revealed that ACE2 is expressed in support cells, stem cells, and perivascular cells, rather than in neurons.

Concerning neuroinflammation occurring in the olfactory system of COVID-19 patients, Schwabenland et al. (2021) performed deep spatial profiling of the local immune response through imaging mass spectrometry, revealing significant immune activation in the medulla oblongata and in the olfactory bulb, with a prominent role mediated by CD8+ T-cell—microglia crosstalk in the parenchyma. Similarly, other authors (Emmi et al., 2021; Matschke et al., 2020; Solomon et al., 2020) detected prominent astrogliosis,

microglial activation and microglial nodules in the brainstem and olfactory structures of COVID-19 subjects, as seen in Fig. 1. Hence, even though the detection of SARS-CoV-2 in olfactory neuronal cells has not been consistently reproduced throughout studies, most findings support marked neuroinflammation of the olfactory system in COVID-19. Combined with recent studies indicating indirect downregulation of olfactory receptor pathways mediated by sustentacular cell infection, it appears that olfactory impairment in COVID-19 may not always be associated to direct viral invasion of olfactory neuronal cells, with subsequent olfactory-transmucosal spread of the virus throughout the CNS but can also be mediated by sustentacular cell infection and dysregulation of olfactory receptor pathways.

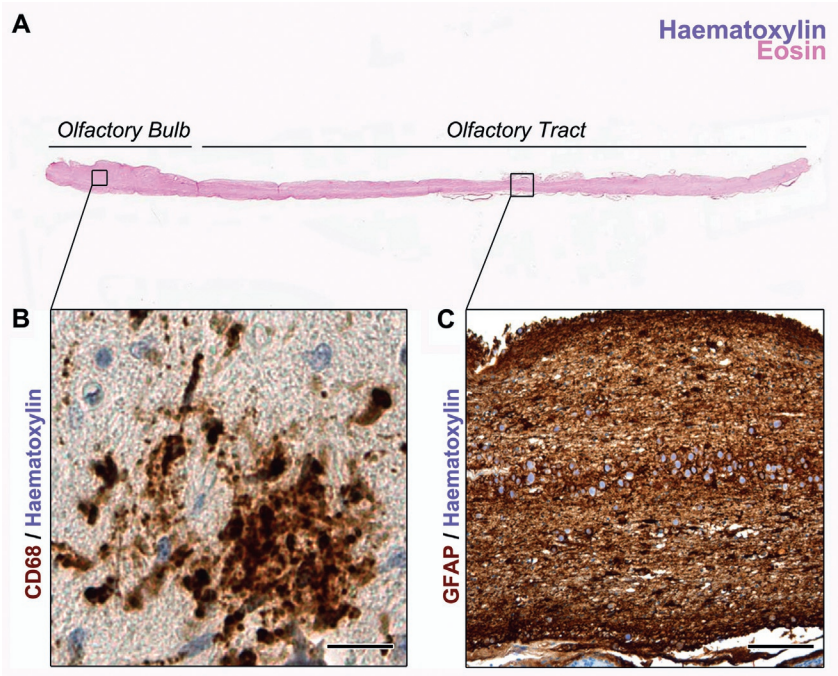

Fig. 1 (A) Olfactory bulb and tract of a person who died due to COVID-19, Hematoxylin & Eosin staining. (B) Microglial nodule in the olfactory bulb, as demonstrated by CD68 immunoperoxidase staining. (C) Prominent astrogliosis of the olfactory tract with numerous corpora amylacea representing a non-specific finding in COVID-19, often difficult to disentangle from patient comorbidities. GFAP immunoperoxidase staining. This material has been obtained from an autopsy performed at the Institute of Anatomy of the University of Padua, Italy.

4. Olfactory impairment in COVID-19 and parkinsonism

Despite being counted as a respiratory virus, SARS-CoV-2 is associated to frequent and sometimes severe neurological manifestations, posing important interrogatives on the short and long-term effects of SARS-CoV-2 infection on the CNS. Particularly concerning is the hypothesis that SARS-CoV-2 infection of the CNS may predispose, or quickly precipitate, the development of PD (Beauchamp, Finkelstein, Bush, Evans, & Barnham, 2020; Bouali-Benazzouz & Benazzouz, 2021; Brundin, Nath, & Beckham, 2020). This hypothesis arises both from the 1917 Spanish flu and von Economo's encephalitis lethargica pandemics, which have seen a surge of post-encephalitic parkinsonism following the waves of the pandemic, and the known association between viral infection and the development of transient or permanent movement disorders (Jang, Boltz, Webster, & Smeyne, 2009). In fact, pathogens, and in particular respiratory viruses, have been suggested as a potential etiopathogenic factor for PD, leading to parkinsonism in subjects over the age of 50, regardless of genetic substrate (Beauchamp et al., 2020; Tanner et al., 1999). The well-established neuropathological staging of PD, suggested by Braak & Braak, also appears to account for neurotropic pathogens that may infect the CNS either through the vagus nerve (pneumo-gastric pathway) or by accessing the brain through the olfactory systems. Both the olfactory bulb and tract, as well as the medulla oblongata where the vagal nuclei are located, represent the very first sites of early PD neuropathology, and interestingly also represent the main sites of inflammation/ infection encountered in COVID-19 (Hawkes, Del Tredici, & Braak, 2007; Klingelhoefer & Reichmann, 2015). Furthermore, viral-related inflammation might render the CNS susceptible to preceding or subsequent stressors (Sulzer, 2007), even in the absence of direct viral invasion; indeed, past history of infection was associated with a 20% higher risk of presenting PD in the future (Meng, Shen, & Ji, 2019). In the case of coronaviruses (CoV), higher antibodies titers against common CoV have been detected in the cerebrospinal fluid (CSF) of people with PD (PwP) when compared to controls, while there was evidence of post-encephalitic parkinsonism in mice infected with a CoV strain (MHV-A59) (Fazzini, Fleming, & Fahn, 1992; Fishman et al., 1985).

In a recent study, Semerdzhiev, Fakhree, Segers-Nolten, Blum, and Claessens (2022) demonstrated that in the presence of SARS-CoV-2 Nucleocapsid protein, the onset of alpha-synuclein aggregation into

amyloid fibrils is strongly accelerated, indicating that N-protein facilitates the formation of a critical nucleus for aggregation. Fibril formation does not only appear to accelerate, but also proceeds in an unusual two-step process. In cells, the presence of Nucleocapsid protein changes the distribution of alpha-synuclein over different conformations, which likely represent different functions at already short time scales. Similarly, Charnley et al. (2022) identified two peptides from the SARS-CoV-2 proteome that self-assemble into amyloid assemblies. These amyloids were shown to be highly toxic to neuronal cells and are hypothesized to trigger neurological symptoms in COVID-19. The cytotoxicity and protease-resistant structure of these assemblies may result in their persistent presence in the CNS of patients, even following infection, and could partially explain the lasting neurological symptoms of COVID-19, especially those that are novel in relation to other post-viral syndromes, such as those following the original SARS-CoV-1. The outlook in relation to triggering of progressive neurodegenerative disease remains uncertain. Given the typically slow progress of neurodegenerative disease, if such a phenomenon exists, it will most probably take some time to become evident epidemiologically. In an animal model study performed by Käufer et al. (2022), microglial activation and neuronal proteinopathy persisted even beyond viral clearance. Viral protein exposure in the nasal cavity led to pronounced microglia activation in the olfactory bulb beyond viral clearance. Cortical, but not hippocampal, neurons accumulated hyperphosphorylated tau and alpha-synuclein, in the absence of overt inflammation and neurodegeneration. Importantly, not all brain regions were affected, in line with the selective vulnerability hypothesis. In this animal model, despite the absence of virus in brain, neurons developed signatures of proteinopathies that may contribute to progressive neuronal dysfunction.

This is further confirmed by available neuropathological studies on COVID-19 decedents, showing very little and often conflicting evidence on SARS-CoV-2 neurotropism. On the other hand, all available neuropathological studies are carried on subjects who died during the acute phases of the disease (Emmi et al., 2021; Matschke et al., 2020; Schwabenland et al., 2021; Solomon et al., 2020), and, as such, the neuropathological alterations occurring in cases of chronic infection or in the post-infection timeframe are yet unknown. Neurodegenerative changes induced by either direct infection or by the indirect effects mediated by neuroinflammation may not be appreciable or detectable in patients who died shortly after infection,

and as most subjects in neuropathological studies already present important neurological comorbidities, it is not possible to determine which markers of neurodegeneration are directly related to COVID-19, and which are related to patient morbidity.

References

Athanassi, A., Dorado Doncel, R., Bath, K. G., & Mandairon, N. (2021). Relationship between depression and olfactory sensory function: A review. *Chemical Senses*, *46*. https://doi.org/10.1093/chemse/bjab044.

Beauchamp, L. C., Finkelstein, D. I., Bush, A. I., Evans, A. H., & Barnham, K. J. (2020). Parkinsonism as a third wave of the COVID-19 pandemic? *Journal of Parkinson's Disease*, *10*(4), 1343–1353. https://doi.org/10.3233/JPD-202211.

Bouali-Benazzouz, R., & Benazzouz, A. (2021). Covid-19 infection and parkinsonism: Is there a link? *Movement Disorders*, *36*(8), 1737–1743. https://doi.org/10.1002/mds.28680.

Brann, D. H., Tsukahara, T., Weinreb, C., Lipovsek, M., Van den Berge, K., Gong, B., et al. (2020). Non-neuronal expression of SARS-CoV-2 entry genes in the olfactory system suggests mechanisms underlying COVID-19-associated anosmia. *Science Advances*, *6*(31). https://doi.org/10.1126/sciadv.abc5801.

Brundin, P., Nath, A., & Beckham, J. D. (2020). Is COVID-19 a perfect storm for Parkinson's disease? *Trends in Neurosciences*, *43*(12), 931–933. https://doi.org/10.1016/j.tins.2020.10.009.

Bryche, B., St Albin, A., Murri, S., Lacôte, S., Pulido, C., Ar Gouilh, M., et al. (2020). Massive transient damage of the olfactory epithelium associated with infection of sustentacular cells by SARS-CoV-2 in golden Syrian hamsters. *Brain, Behavior, and Immunity*, *89*, 579–586. https://doi.org/10.1016/j.bbi.2020.06.032.

Charnley, M., Islam, S., Bindra, G. K., Engwirda, J., Ratcliffe, J., Zhou, J., et al. (2022). Neurotoxic amyloidogenic peptides in the proteome of SARS-COV2: Potential implications for neurological symptoms in COVID-19. *Nature Communications*, *13*(1), 3387. https://doi.org/10.1038/s41467-022-30932-1.

Coelho, D. H., Reiter, E. R., French, E., & Costanzo, R. M. (2022). Decreasing incidence of chemosensory changes by COVID-19 variant. *Otolaryngology and Head and Neck Surgery*. https://doi.org/10.1177/01945998221097656. 1945998221097656.

Doty, R. L., Bayona, E. A., Leon-Ariza, D. S., Cuadros, J., Chung, I., Vazquez, B., et al. (2014). The lateralized smell test for detecting Alzheimer's disease: Failure to replicate. *Journal of the Neurological Sciences*, *340*(1–2), 170–173. https://doi.org/10.1016/j.jns.2014.03.022.

Douaud, G., Lee, S., Alfaro-Almagro, F., Arthofer, C., Wang, C., McCarthy, P., et al. (2022). SARS-CoV-2 is associated with changes in brain structure in UK biobank. *Nature*, *604*(7907), 697–707. https://doi.org/10.1038/s41586-022-04569-5.

Duarte, L. F., Farías, M. A., Álvarez, D. M., Bueno, S. M., Riedel, C. A., & González, P. A. (2019). Herpes simplex virus type 1 infection of the central nervous system: Insights into proposed interrelationships with neurodegenerative disorders. *Frontiers in Cellular Neuroscience*, *13*. https://doi.org/10.3389/fncel.2019.00046.

Ellul, M. A., Benjamin, L., Singh, B., Lant, S., Michael, B. D., Easton, A., et al. (2020). Neurological associations of COVID-19. *Lancet Neurology*, *19*(9), 767–783. https://doi.org/10.1016/s1474-4422(20)30221-0.

Emmi, A., Rizzo, S. M. R., Barzon, L., Carturan, E., Sinigaglia, A., Riccetti, S., et al. (2021). *COVID-19 neuropathology: Evidence for SARS-CoV-2 invasion of human brainstem nuclei*. https://doi.org/10.1101/2022.06.29.498117.

Fazzini, E., Fleming, J., & Fahn, S. (1992). Cerebrospinal fluid antibodies to coronavirus in patients with Parkinson's disease. *Movement Disorders*, *7*(2), 153–158. https://doi.org/10.1002/mds.870070210.

Fishman, P. S., Gass, J. S., Swoveland, P. T., Lavi, E., Highkin, M. K., & Weiss, S. R. (1985). Infection of the basal ganglia by a murine coronavirus. *Science (New York, N.Y.)*, *229*(4716), 877–879. https://doi.org/10.1126/science.2992088.

Fullard, J. F., Lee, H.-C., Voloudakis, G., Suo, S., Javidfar, B., Shao, Z., et al. (2021). Single-nucleus transcriptome analysis of human brain immune response in patients with severe COVID-19. *Genome Medicine*, *13*(1), 118. https://doi.org/10.1186/s13073-021-00933-8.

Guedj, E., Campion, J. Y., Dudouet, P., Kaphan, E., Bregeon, F., Tissot-Dupont, H., et al. (2021). (18)F-FDG brain PET hypometabolism in patients with long COVID. *European Journal of Nuclear Medicine and Molecular Imaging*, *48*(9), 2823–2833. https://doi.org/10.1007/s00259-021-05215-4.

Guerrero, J. I., Barragán, L. A., Martínez, J. D., Montoya, J. P., Peña, A., Sobrino, F. E., et al. (2021). Central and peripheral nervous system involvement by COVID-19: A systematic review of the pathophysiology, clinical manifestations, neuropathology, neuroimaging, electrophysiology, and cerebrospinal fluid findings. *BMC Infectious Diseases*, *21*(1), 515. https://doi.org/10.1186/s12879-021-06185-6.

Harberts, E., Yao, K., Wohler, J. E., Maric, D., Ohayon, J., Henkin, R., et al. (2011). Human herpesvirus-6 entry into the central nervous system through the olfactory pathway. *Proceedings of the National Academy of Sciences*, *108*(33), 13734–13739. https://doi.org/10.1073/pnas.1105143108.

Hawkes, C. H., Del Tredici, K., & Braak, H. (2007). Parkinson's disease: A dual-hit hypothesis. *Neuropathology and Applied Neurobiology*, *33*(6), 599–614. https://doi.org/10.1111/j.1365-2990.2007.00874.x.

Helms, J., Kremer, S., Merdji, H., Clere-Jehl, R., Schenck, M., Kummerlen, C., et al. (2020). Neurologic features in severe SARS-CoV-2 infection. *The New England Journal of Medicine*, *382*(23), 2268–2270. https://doi.org/10.1056/NEJMc2008597.

Hornuss, D., Lange, B., Schröter, N., Rieg, S., Kern, W. V., & Wagner, D. (2020). Anosmia in COVID-19 patients. *Clinical Microbiology and Infection*, *26*(10), 1426–1427. https://doi.org/10.1016/j.cmi.2020.05.017.

Huang, C., Huang, L., Wang, Y., Li, X., Ren, L., Gu, X., et al. (2021). 6-month consequences of COVID-19 in patients discharged from hospital: A cohort study. *Lancet*, *397*(10270), 220–232. https://doi.org/10.1016/s0140-6736(20)32656-8.

Hummel, T., Rissom, K., Reden, J., Hähner, A., Weidenbecher, M., & Hüttenbrink, K.-B. (2009). Effects of olfactory training in patients with olfactory loss. *The Laryngoscope*, *119*(3), 496–499. https://doi.org/10.1002/lary.20101.

Iadecola, C., Anrather, J., & Kamel, H. (2020). Effects of COVID-19 on the nervous system. *Cell*, *183*(1), 16–27.e11. https://doi.org/10.1016/j.cell.2020.08.028.

Jang, H., Boltz, D. A., Webster, R. G., & Smeyne, R. J. (2009). Viral parkinsonism. *Biochimica et Biophysica Acta*, *1792*(7), 714–721. https://doi.org/10.1016/j.bbadis.2008.08.001.

Käufer, C., Schreiber, C. S., Hartke, A.-S., Denden, I., Stanelle-Bertram, S., Beck, S., et al. (2022). Microgliosis and neuronal proteinopathy in brain persist beyond viral clearance in SARS-CoV-2 hamster model. *eBioMedicine*, *79*, 103999. https://doi.org/10.1016/j.ebiom.2022.103999.

Khan, M., Yoo, S.-J., Clijsters, M., Backaert, W., Vanstapel, A., Speleman, K., et al. (2021). Visualizing in deceased COVID-19 patients how SARS-CoV-2 attacks the respiratory and olfactory mucosae but spares the olfactory bulb. *Cell*, *184*(24), 5932–5949. e5915. https://doi.org/10.1016/j.cell.2021.10.027.

Klingelhoefer, L., & Reichmann, H. (2015). Pathogenesis of Parkinson disease- -the gut-brain axis and environmental factors. *Nature Reviews. Neurology*, *11*(11), 625–636. https://doi.org/10.1038/nrneurol.2015.197.

Lee, M. H., Perl, D. P., Nair, G., Li, W., Maric, D., Murray, H., et al. (2021). Microvascular injury in the brains of patients with Covid-19. *The New England Journal of Medicine*, *384*(5), 481–483. https://doi.org/10.1056/NEJMc2033369.

Li, K., Wohlford-Lenane, C., Perlman, S., Zhao, J., Jewell, A. K., Reznikov, L. R., et al. (2016). Middle East respiratory syndrome coronavirus causes multiple organ damage and lethal disease in mice transgenic for human dipeptidyl peptidase 4. *The Journal of Infectious Diseases*, *213*(5), 712–722. https://doi.org/10.1093/infdis/jiv499.

Mao, L., Jin, H., Wang, M., Hu, Y., Chen, S., He, Q., et al. (2020). Neurologic manifestations of hospitalized patients with coronavirus disease 2019 in Wuhan, China. *JAMA Neurol*, 77(6), 683–690. https://doi.org/10.1001/jamaneurol.2020.1127.

Matschke, J., Lütgehetmann, M., Hagel, C., Sperhake, J. P., Schröder, A. S., Edler, C., et al. (2020). Neuropathology of patients with COVID-19 in Germany: A post-mortem case series. *The Lancet Neurology*, *19*(11), 919–929. https://doi.org/10.1016/S1474-4422(20)30308-2.

Meinhardt, J., Radke, J., Dittmayer, C., Franz, J., Thomas, C., Mothes, R., et al. (2021). Olfactory transmucosal SARS-CoV-2 invasion as a port of central nervous system entry in individuals with COVID-19. *Nature Neuroscience*, *24*(2), 168–175. https://doi.org/10.1038/s41593-020-00758-5.

Meng, L., Shen, L., & Ji, H. F. (2019). Impact of infection on risk of Parkinson's disease: A quantitative assessment of case-control and cohort studies. *Journal of Neurovirology*, *25*(2), 221–228. https://doi.org/10.1007/s13365-018-0707-4.

Netland, J., Meyerholz, D. K., Moore, S., Cassell, M., & Perlman, S. (2008). Severe acute respiratory syndrome coronavirus infection causes neuronal death in the absence of encephalitis in mice transgenic for human ACE2. *Journal of Virology*, *82*(15), 7264–7275. https://doi.org/10.1128/jvi.00737-08.

Schwabenland, M., Salié, H., Tanevski, J., Killmer, S., Lago, M. S., Schlaak, A. E., et al. (2021). Deep spatial profiling of human COVID-19 brains reveals neuroinflammation with distinct microanatomical microglia-T-cell interactions. *Immunity*, *54*(7), 1594–1610.e1511. https://doi.org/10.1016/j.immuni.2021.06.002.

Semerdzhiev, S. A., Fakhree, M. A. A., Segers-Nolten, I., Blum, C., & Claessens, M. M. A. E. (2022). Interactions between SARS-CoV-2 N-protein and α-synuclein accelerate amyloid formation. *ACS Chemical Neuroscience*, *13*(1), 143–150. https://doi.org/10.1021/acschemneuro.1c00666.

Shelton, J. F., Shastri, A. J., Fletez-Brant, K., Auton, A., Chubb, A., Fitch, A., et al. (2022). The UGT2A1/UGT2A2 locus is associated with COVID-19-related loss of smell or taste. *Nature Genetics*, *54*(2), 121–124. https://doi.org/10.1038/s41588-021-00986-w.

Sollini, M., Morbelli, S., Ciccarelli, M., Cecconi, M., Aghemo, A., Morelli, P., et al. (2021). Long COVID hallmarks on [18F]FDG-PET/CT: A case-control study. *European Journal of Nuclear Medicine and Molecular Imaging*, *48*(10), 3187–3197. https://doi.org/10.1007/s00259-021-05294-3.

Solomon, I. H., Normandin, E., Bhattacharyya, S., Mukerji, S. S., Keller, K., Ali, A. S., et al. (2020). Neuropathological features of Covid-19. *The New England Journal of Medicine*, *383*(10), 989–992. https://doi.org/10.1056/NEJMc2019373.

Sulzer, D. (2007). Multiple hit hypotheses for dopamine neuron loss in Parkinson's disease. *Trends in Neurosciences*, *30*(5), 244–250.

Tanner, C. M., Ottman, R., Goldman, S. M., Ellenberg, J., Chan, P., Mayeux, R., et al. (1999). Parkinson disease in twins: An etiologic study. *JAMA*, *281*(4), 341–346. https://doi.org/10.1001/jama.281.4.341.

Thakur, B., Dubey, P., Benitez, J., Torres, J. P., Reddy, S., Shokar, N., et al. (2021). A systematic review and meta-analysis of geographic differences in comorbidities and associated severity and mortality among individuals with COVID-19. *Scientific Reports*, *11*(1), 8562. https://doi.org/10.1038/s41598-021-88130-w.

Thakur, K. T., Miller, E. H., Glendinning, M. D., Al-Dalahmah, O., Banu, M. A., Boehme, A. K., et al. (2021). COVID-19 neuropathology at Columbia University Irving medical center/New York presbyterian hospital. *Brain*, *144*(9), 2696–2708. https://doi.org/10.1093/brain/awab148.

Voruz, P., Allali, G., Benzakour, L., Nuber-Champier, A., Thomasson, M., Jacot de Alcântara, I., et al. (2022). Long COVID neuropsychological deficits after severe, moderate, or mild infection. *Clinical and Translational Neuroscience*, *6*(2), 9. Retrieved from https://www.mdpi.com/2514-183X/6/2/9.

Yang, A. C., Kern, F., Losada, P. M., Agam, M. R., Maat, C. A., Schmartz, G. P., et al. (2021). Dysregulation of brain and choroid plexus cell types in severe COVID-19. *Nature*, *595*(7868), 565–571. https://doi.org/10.1038/s41586-021-03710-0.

Zazhytska, M., Kodra, A., Hoagland, D. A., Frere, J., Fullard, J. F., Shayya, H., et al. (2022). Non-cell-autonomous disruption of nuclear architecture as a potential cause of COVID-19-induced anosmia. *Cell*, *185*(6), 1052–1064.e1012. https://doi.org/10.1016/j.cell.2022.01.024.