Since January 2020 Elsevier has created a COVID-19 resource centre with free information in English and Mandarin on the novel coronavirus COVID-19. The COVID-19 resource centre is hosted on Elsevier Connect, the company's public news and information website.

Elsevier hereby grants permission to make all its COVID-19-related research that is available on the COVID-19 resource centre - including this research content - immediately available in PubMed Central and other publicly funded repositories, such as the WHO COVID database with rights for unrestricted research re-use and analyses in any form or by any means with acknowledgement of the original source. These permissions are granted for free by Elsevier for as long as the COVID-19 resource centre remains active.

Handbook of Clinical Neurology, Vol. 189 (3rd series)
Respiratory Neurobiology: Physiology and Clinical Disorders, Part II
R. Chen and P.G. Guyenet, Editors
https://doi.org/10.1016/B978-0-323-91532-8.00004-5
Copyright © 2022 Elsevier B.V. All rights reserved

Chapter 17

Neurologic complications of coronavirus and other respiratory viral infections

FRANCESCO CAVALLIERI[1,2], JOHANN SELLNER[3,4], MARIALUISA ZEDDE[1], AND ELENA MORO[5]*

[1]*Neurology Unit, Neuromotor and Rehabilitation Department, Azienda USL-IRCCS di Reggio Emilia, Reggio Emilia, Italy*
[2]*Clinical and Experimental Medicine PhD Program, University of Modena and Reggio Emilia, Modena, Italy*
[3]*Department of Neurology, Landesklinikum Mistelbach-Gänserndorf, Mistelbach, Austria*
[4]*Department of Neurology, Christian Doppler Medical Center, Paracelsus Medical University, Salzburg, Austria*
[5]*Division of Neurology, CHU of Grenoble, Grenoble Alpes University, Grenoble Institute of Neurosciences, Grenoble, France*

Abstract

In humans, several respiratory viruses can have neurologic implications affecting both central and peripheral nervous system. Neurologic manifestations can be linked to viral neurotropism and/or indirect effects of the infection due to endothelitis with vascular damage and ischemia, hypercoagulation state with thrombosis and hemorrhages, systemic inflammatory response, autoimmune reactions, and other damages. Among these respiratory viruses, recent and huge attention has been given to the coronaviruses, especially the severe acute respiratory syndrome coronavirus 2 (SARS-CoV-2) pandemic started in 2020. Besides the common respiratory symptoms and the lung tropism of SARS-CoV-2 (COVID-19), neurologic manifestations are not rare and often present in the severe forms of the infection. The most common acute and subacute symptoms and signs include headache, fatigue, myalgia, anosmia, ageusia, sleep disturbances, whereas clinical syndromes include mainly encephalopathy, ischemic stroke, seizures, and autoimmune peripheral neuropathies. Although the pathogenetic mechanisms of COVID-19 in the various acute neurologic manifestations are partially understood, little is known about long-term consequences of the infection. These consequences concern both the so-called long-COVID (characterized by the persistence of neurological manifestations after the resolution of the acute viral phase), and the onset of new neurological symptoms that may be linked to the previous infection.

INTRODUCTION

Acute respiratory viral illnesses are among the leading causes of human diseases worldwide. More than 200 antigenically distinct viruses from 10 genera are known to cause viral respiratory illness (Mackie, 2003). Most of these viral infections cause acute respiratory disease of the upper respiratory tract, while lower respiratory tract infections are less frequent. The conditions caused by respiratory viruses are named according to the syndrome, including "common cold," pharyngitis, laryngotracheobronchitis, tracheitis, bronchiolitis, bronchitis, and pneumonia (Charlton et al., 2018). Although respiratory viral infection occurs most commonly in children, healthy adults, older, and immunocompromised people can be affected well. The primary function of the respiratory tract is to conduct air deep into the lungs where vital gas exchanges occur. A variety of airborne pathogens constantly challenge this function, most of them respiratory viruses. The impact of viral respiratory infections depends on the host's ability to develop a protective immune response that clears the

*Correspondence to: Elena Moro, Service de neurologie, CHU de Grenoble (Hôpital Nord), Boulevard de la Chantourne, 38043 La Tronche, France. Tel: +33-4-76-76-94-52, Fax: +33-4-76-76-56-31, E-mail: emoro@chu-grenoble.fr

virus (Flerlage et al., 2021). If the immune system fails to provide the necessary response within an appropriate timeframe or a hyperactive response is mounted, the airway structures cannot maintain their function and eventually causes respiratory dysfunction (Dakhama et al., 2005). In addition, viruses can cause damage to the peripheral and central nervous system (PNS and CNS, respectively), which can lead to neurogenic respiratory dysfunction (Pizzi, 2021). More recently, this topic was brought to the fore with the severe acute respiratory syndrome coronavirus-2 (SARS-CoV-2) outbreak (Tan et al., 2021). This chapter provides insights into the pulmonary and neurologic basis of respiratory dysfunction related to infections with coronaviruses and other respiratory viruses. Furthermore, the pathophysiological mechanisms and clinical manifestations of neurological involvement of human coronaviruses are discussed.

RESPIRATORY VIRUSES AND OTHER VIRUSES CAUSING RESPIRATORY DYSFUNCTION

The incidence of viral respiratory disease has increased over time (Global Burden of Disease Study C, 2015). This increase reflects both improved diagnostic techniques and the growing population of immunocompromised individuals. Both DNA and RNA viruses can cause viral respiratory disease. Viral respiratory disease can vary from a mild and self-limited illness to a life-threatening infection (Fragkou et al., 2021). Poor prognosis depends on the organism's virulence, and the age, comorbidities, and immune status of the host (Han et al., 2020). Viruses that can cause respiratory disease (so-called "Respiratory viruses") are listed in Table 17.1. The four most frequent etiologies of viral pneumonia in children and immunocompetent adults are influenza virus, Respiratory syncytial virus (RSV), adenovirus, and Parainfluenza virus (PIV). Influenza virus types A and B are responsible for more than half of all community-acquired viral pneumonia cases, particularly during influenza outbreaks (Davis et al., 2014). Moreover, enteroviruses account for occasional respiratory illnesses during the summer months (Graf et al., 2019). Interestingly, in 2020 and 2021, the stringent public health measures imposed to control the COVID-19 pandemic have suppressed most seasonal respiratory viruses; the notable exception is human rhinovirus/enterovirus (Champredon et al., 2021; Rodgers et al., 2021).

RESPIRATORY DYSFUNCTION BY VIRAL INFECTION

Respiratory viruses can be transmitted via respiratory secretions over multiple routes, independently and simultaneously. The main four ways include direct transmission via physical contact, indirect transmission via contact with contaminated surfaces or objects, direct spread through the air from one respiratory tract to another via large respiratory droplets, and fine respiratory aerosols (Leung, 2021). Once transmitted to a host, viruses may accomplish their first rounds of replication in the oral and nasal cavity, and the nasopharynx before eventually spreading to the lower airways. However, direct infection of the lower airways is possible via the inhalation route. Respiratory viruses that enter the airway interact primarily with epithelial cells, the leading site of

Table 17.1

Respiratory viruses

Adenoviridae (adenoviruses)	**Paramyxoviridae (paramyxoviruses)**	**Retroviridae (retroviruses)**
Coronaviridae (coronaviruses)	PIV	HIV
SARS	RSV	HTLV-1
MERS	hMPV	**Herpesviridae**
2019-nCoV	Measles virus	HSV-1, HSV-2
Bunyavtridae (arboviruses)	**Picornaviridae (picornaviruses)**	HHV-6
Hantavirus	Rhinovirus	HHV-7
Orthomyxoviridae (orthomyxoviruses)	Enteroviruses,	HHV-8
Influenza virus	Enterovirus 71	VZV
Papovaviridae (polyomavirus)	Coxsackievirus	CMV
JCV	Echovirus	EBV
BK virus		**Reoviridae (rotavirus)**

The bold text represents the difference families of viruses. Abbreviations: *2019-nCoV*, 2019 novel coronavirus; *CMV*, Cytomegalovirus; *EBV*, Epstein–Barr virus; *HHV-6*, herpesvirus-6; *HHV-7*, herpesvirus-7; *HHV-8*, herpesvirus-8; *HIV*, human immunodeficiency virus; *hMPV*, human metapneumovirus; *HSV-1*, herpes simplex virus-1; *HSV-2*, herpes simplex virus-2; *HTLV-1*, human lymphotropic virus type 1; *JCV*, John Cunningham virus; *MERS*, Middle East respiratory syndrome; *PIV*, parainfluenza virus; *RSV*, respiratory syncytial virus; *SARS*, severe acute respiratory syndrome; *VZV*, varicella-zoster virus.

viral replication and the source of many mediators that can initiate both physiologic airway responses and innate and adaptive immune responses (Clementi et al., 2021; Wang et al., 2021). Some respiratory viruses are present in feces or infected cells from the gastrointestinal tract. Thus, transmission via direct contact with feces or aerosolization during toilet flushing needs to be considered (Johnson et al., 2013). The eye may serve as another route of viral entry for respiratory viruses, and the upper respiratory tract could be reached via the lacrimal duct. Respiratory failure and hypoxemia are common clinical manifestations of respiratory infection. In such cases, disease progression typically comprises a compensated hypoxic phase, often with nonspecific signs and symptoms (Guo et al., 2021). This phase may be followed by decompensation and rapid deterioration to severe respiratory failure, with the need of invasive ventilation or even extracorporeal membrane oxygenation rescue. Therefore, the correct timing of respiratory support therapy is critical.

Pathogenesis of virus-induced airway dysfunction

Most respiratory viruses multiply in the epithelium of the upper airway, and secondarily infect the lung through airway secretions or hematogenous spread (Flerlage et al., 2021). Severe pneumonia may result in extensive consolidation of the lungs with varying degrees of bleeding, with some patients developing bloody pleural effusions and diffuse alveolar damage (Clementi et al., 2021; Klomp et al., 2021). The mechanism of injury to tissues depends on the virus involved. Some viruses are mainly cytopathic, directly affecting the pneumocytes or the bronchial cells (Gorski et al., 2012). With others, overexuberant inflammation from the immune response is the mainstay of the pathogenic process (Valdebenito et al., 2021). Respiratory viruses damage the respiratory tract and stimulate the host to release multiple humoral factors. The immune responses can be categorized according to the patterns of cytokine production (Gomez-Escobar et al., 2021). Type 1 cytokines promote cell-mediated immunity, while type 2 cytokines mediate allergic reactions. Children infected with RSV who develop acute bronchiolitis rather than mild upper respiratory infection, have impaired type 1 immunity or augmented type 2 immunity. In addition to humoral responses, cell-mediated immunity appears necessary for recovery from certain respiratory viral infections (Newton et al., 2016; Connors et al., 2016). Impaired type 1 response may explain why immunocompromised patients have more severe viral pneumonia. Viral infections can also alter bacterial colonization patterns, increase bacterial adherence to respiratory epithelium, reduce mucociliary clearance, and alter bacterial phagocytosis by host cells (Meskill and O'Bryant, 2020).

Pathogenesis of nervous system dysfunction leading to respiratory disturbances

Control of ventilation depends on a brainstem neuronal network that orchestrates the activity of the motor neurons innervating the respiratory muscles. This network comprises the pontine respiratory group and dorsal and ventral respiratory groups in the medulla (Smith et al., 2013; Del Negro et al., 2018). Thus, neurologic disorders affecting these areas, or the respiratory motor unit, may lead to abnormal breathing (Nogues and Benarroch, 2008). In addition, the more acute the lesion, the greater is the probability of developing respiratory failure. Several diseases, including viral CNS infections, may selectively or prominently affect nuclei and pathways involved in respiratory control. These disorders are frequently associated with impaired cardiovascular control, emphasizing the close interactions between respiratory, cardiovagal, and sympathetic vasomotor control networks.

Viruses as cause of central neurogenic respiratory dysfunction

Lesions affecting the pontine respiratory group, the nucleus of the tractus solitarius (NTS), the ventral respiratory group (VRG), or the central chemoreceptors may cause central alveolar hypoventilation (congenital central hypoventilation syndrome [CCHS]), abnormal respiratory rhythm, or both (Demartini et al., 2020). Impairment of the automatic control of ventilation causes central alveolar hypoventilation syndrome, which includes repetitive morning headaches, nocturnal sleep disruption, or daytime tiredness and sleepiness (Boing and Randerath, 2015). In addition, cyanosis, irregular breathing patterns during sleep or wakefulness, or absence of dyspnea during exercise may occur. Lesions involving the dorsolateral region of the pons may lead to apneustic breathing, and paroxysmal hyperventilation may arise after an acute lesion in the upper brainstem. Cases of viral causes of central hypoventilation syndrome in the literature are scarce. A case of acquired central hypoventilation was reported postmortem in an 8-year-old boy (Giangaspero et al., 1988). The neuropathological examination revealed viral encephalitic lesions in the hypothalamus and the brainstem. Another case of a 28-year-old woman with central hypoventilation who had undergone immunosuppression due to double intestinal-kidney transplantation has been reported (Larrosa-Barrero et al., 2018). She developed progressive multifocal leukoencephalopathy (PML). The lesions were located in the left margin and the posterior part of

the brainstem, the posterior part of the mesencephalon, and the three bilateral cerebellar peduncles. The medulla damage was considered irreversible, so long-term non-invasive ventilation (NIV) was prescribed. A case of Ondine's curse in a 17-month-old boy with detection of both Hemophilus influenzae and HSV-1, and encephalitic lesions in the medulla, cerebellum, and upper cervical cord was also published (Tirupathi et al., 2008). At 4.5 years of age, the child remained quadriplegic, and she required nocturnal and intermittent diurnal ventilatory support via a tracheostomy for persisting central hypoventilation syndrome. Death in poliomyelitis is usually the result of bulbar involvement with respiratory and cardiovascular impairment. Bulbar poliomyelitis occurs in 10%–15% of cases with paralysis. Bulbar polio can involve any of the cranial nerves and the medullary reticular formation. The latter can result in respiratory dysfunction, including ataxic breathing and cardiovascular symptoms (hypotension, hypertension, and cardiac arrhythmias) (Romero and Modlin, 2015). Also, the prevalence of sleep apnea syndrome, nocturnal alveolar hypoventilation, and restless legs syndrome in the aftermath of polio is higher than in the general population (Leotard et al., 2020).

Viruses are an important cause of infectious and parainfectious myelitis (Isada and Miller, 2020). Although some viruses are highly cytolytic and directly damage the CNS (e.g., poliovirus), virus-specific and autoimmune host cellular immune responses presumably contribute to spinal cord damage and neurologic dysfunction in acute viral myelitis associated with less virulent or noncytolytic viruses (Lerner et al., 2021). Postinfectious CNS syndromes are an essential consideration following a viral infection, and the virus cannot be detected in CSF during acute myelitis (Schulte et al., 2021). The most important risk factors for respiratory complications associated with spinal cord injuries are lesions above C5 and American Spinal Injury Association (ASIA) Grade A impairment scale score (Roberts et al., 2017). A patient with a near-complete lesion above C5 will typically have impaired diaphragm function and is likely to require a period of endotracheal intubation and mechanical ventilation (Hassid et al., 2008).

The infection may preferentially involve spinal cord gray matter, white matter, or both in viral myelitis. The area of spinal cord involvement generally extends to at least several vertebral segments (Nardone et al., 2017; Feige et al., 2020). Myelitis with bilateral corticospinal tract involvement at high cervical levels may lead to "autonomous breathing," with loss of ability to initiate voluntary respiratory movements (Nogues and Benarroch, 2008). Lesions at the ventrolateral region of the cervical spinal cord may lead to loss of automatic breathing. Acute lesions involving the dorsolateral medulla may also result in involuntary breathing loss, usually associated with impaired swallowing and cough reflex and thus an increased risk of aspiration pneumonia. Medullary lesions can also cause "ratchet breathing," which is characterized by irregular and jerky inspiratory breaths with short apneic pauses during mid-inspiration (Nogues and Benarroch, 2008). The clinical presentation of acute viral myelitis can be divided into a poliomyelitis-like gray matter syndrome and a partial or complete white matter syndrome. However, the latter may also involve gray matter structures (Murphy et al., 2021). Nonspecific upper respiratory symptoms with fever may usher in or antedate acute myelitis. In poliomyelitis, a prodromal illness consisting of headache, fever, or mental status changes may occur (Romero and Modlin, 2015). Within days, a pure motor deficit consisting of flaccid weakness of one or more limbs without sensory abnormalities or urinary bladder dysfunction develops. Preferential involvement of anterior horn cells in gray matter suggests poliovirus infection. Polio-like disease is also seen with coxsackieviruses A and B, enteroviruses-70 and -71, West Nile virus (WNV), Japanese encephalitis virus, and tick-borne encephalitis virus (Ide et al., 2021). In contrast, individuals presenting with prominent sensory disturbances, urinary retention, and weakness with either hypo- or hyper-reflexia have myelitis due to involvement of the white matter. This involvement usually affects only part of the transverse expansion of the spinal cord and manifests as asymmetric motor and sensory symptoms. When both halves of the spinal cord are affected, the entity is termed acute transverse myelitis and patients have bilateral weakness and sensory loss. Viruses causing myelitis are listed in Table 17.2.

Viruses as cause of peripheral nervous system dysfunction and respiratory muscle unit disorders

Respiratory failure because of respiratory muscle weakness is often a prominent manifestation of different disorders affecting the motor unit (Nogues and Benarroch, 2008). Inspiratory muscle weakness ultimately results in alveolar hypoventilation and impaired CO_2 exchange. However, the initial effect is loss of ability to increase ventilation efforts in response to increased demands (fever, infection). As muscle weakness progresses and ventilatory needs remain excessive, inspiratory muscles suffer fatigue. Tachypnea is the usual response to unmet ventilatory demands, but it also enhances the work of breathing. Inspiratory muscle weakness predisposes to atelectasis by reducing vital capacity, tidal volume, and the volume of sighs.

Guillain–Barré syndrome (GBS) is an immune-mediated polyradiculoneuropathy (Wakerley and Yuki, 2013). In most patients, the acute onset of neurologic

Table 17.2

Viruses causing myelitis

HERPESVIRUSES	FLAVIVIRUSES	**PARAMYXOVIRUS**
HSV-1 and -2	Dengue virus	**Measles virus**
VZV	Japanese encephalitis virus	**Mumps virus**
CMV	Tick-borne encephalitis virus	**PICORNAVIRUSES**
HHV-6 and -7	**ORTHOMYXOVIRUSES**	**Coxackieviruses A and B**
EBV	**Influenza A virus**	**Echoviruses**
		Enterovirus-70 and -71
		Polioviruses

Respiratory viruses are marked in bold.
Abbreviations: *CMV*, Cytomegalovirus; *EBV*, Epstein-Barr virus; *HSV-1*, herpes simplex virus-1; *HSV-2*, herpes simplex virus-2; *VZV*, Varicella-zoster virus.

symptoms is preceded by an infective illness, followed by progressive limb weakness, which can last up to 4 weeks before reaching plateau. Molecular mimicry is the presumed immunopathogenesis and Campylobacter jejunii, Cytomegalovirus (CMV), Zika virus, and SARS-CoV-2 are the most common pathogens involved (Shahrizaila et al., 2021). Other respiratory viruses implicated in the pathogenesis of GBS are influenza virus A and B virus, and Epstein–Barr virus (EBV) (Sellner and Steiner, 2014). GBS and its variants commonly disrupt respiratory muscle innervation, making intubation and mechanical ventilation necessary in 25%–50% of patients, for a mean duration of 18–29 days (Shang et al., 2020). Absolute criteria for intubation in GBS include impaired consciousness, respiratory or cardiac arrest, shock, arrhythmias, blood-gas alterations, and bulbar dysfunction with confirmed aspiration. Predictors of the need for ventilatory support in GBS include cranial nerve involvement and a history of infection in the 8 days before the onset of symptoms. Paraclinical prognostic factors are reduced action potential amplitude in phrenic nerve stimulation and diaphragm examination, and high cerebrospinal fluid protein levels (Ning et al., 2020; Wen et al., 2021). In addition, life-threatening complications due to dysautonomia are seen in more than one-third of the patients (Chakraborty et al., 2020). These include blood pressure shifts, bradycardia, profound hypotension with sedatives, and hyperkalemia.

PATHOPHYSIOLOGIC MECHANISMS OF NEUROLOGIC INVOLVEMENT IN HUMAN CORONAVIRUS INFECTION

There are currently seven types of known human coronaviruses: HCoV-229E, HCoV-OC43, HCoV-NL63, HCoV-HKU1, SARS-CoV-1, Middle East Respiratory Syndrome-related Coronavirus (MERS), and SARS-CoV-2 (Algahtani et al., 2016; Cevik et al., 2020). Although human coronaviruses are typically associated with a prevalent involvement of the respiratory tract, three coronaviruses have been clearly shown to infect also neurons (i.e., HCoV-229E, HCoV-OC43, and SARS-CoV-1). To date, MERS, SARS-CoV-1, and SARS-CoV-2 have been associated with neurologic diseases (Zubair et al., 2020). Virus may enter the brain and spinal cord usually through either retrograde neuronal dissemination or hematogenous spread (Algahtani et al., 2016). The hematogenous spread occurs through viremia (the presence and multiplication of a given virus in the blood stream). On the other hand, retrograde viral infection occurs when a given virus infects neuronal tissue in the periphery with subsequent contamination to the central nervous system (CNS) using transport mechanisms within the neurons to gain access to the affected vulnerable areas (Algahtani et al., 2016). In the following section, the neuro-invasiveness and pathophysiologic mechanisms of neurologic involvement of SARS-CoV-1, MERS, HCoV-OC43, HCoV-229E, and SARS-CoV-2 will be discussed.

SARS-CoV-1

SARS-CoV-1 led to a clinical illness that is similar to many acute respiratory infections, although a large proportion of patients presented with a rapid deterioration with respiratory distress within the second week of illness (Vijayanand et al., 2004). Although the lung is the major target of infection, SARS-CoV-1 can also be neuroinvasive, primarily infecting the olfactory bulb and subsequently spreading from neuron to neuron to connected areas of the brain (Netland et al., 2008; Desforges et al., 2014, 2019). In animal models, infected mice likely died from dysfunction and/or death of infected neurons, especially those located in the cardiorespiratory centers of the medulla (Netland et al., 2008; Desforges et al., 2014, 2019). SARS-CoV-1 infiltrates the intracellular space of the host cell after binding the angiotensin converting enzyme 2 (ACE2) receptors

which represent the main target of the virus (Desforges et al., 2014, 2019). Transgenic mice that express the ACE2 in airway and other epithelia developed a rapidly lethal infection after intranasal inoculation with a human strain of the virus (McCray Jr et al., 2007). After involvement of the airway epithelia and the alveolar spaces, the virus spread to the brain leading to upregulation of pro-inflammatory cytokines and chemokines in both the lung and the brain McCray Jr et al., 2007). In animal models, SARS-CoV can invade the CNS even after an intraperitoneal infection, with subsequent neuronal loss and appearance of neurological symptoms (Tseng et al., 2007; Desforges et al., 2014).

In the early 2000s, postmortem studies performed during the SARS-CoV-1 pandemic detected the virus in the brains of infected patients (Xu et al., 2005; Gu et al., 2005). Using electronic microscopy, SARS-CoV-1 fragments nesting reverse transcription–polymerase chain reaction (PCR) were found in brain tissue specimens from a comatose patient with a severe form of SARS-CoV-1 infection with diffuse brain edema and multiple high-density lesions at CT scan (Xu et al., 2005). In the same case, pathologic examination of brain tissue revealed necrosis of neurons and gliocyte hyperplasia, whereas immunostaining demonstrated the expression of interferon-γ-induced monokines in gliocytes with the infiltration of CD68+ monocytes/macrophages and CD3+ T lymphocytes (Xu et al., 2005). In another study reporting on brain autopsies from eight patients who died from SARS-CoV-1 infection, specimens of SARS-CoV-1 genome sequences were detected by electronic microscopy and real-time RT-PCR (Gu et al., 2005). The virus was found in the cytoplasm of hypothalamic and cortical neurons together with edema and scattered red degeneration of the neurons (Gu et al., 2005). In two other cases, edema was found around the small veins in the brain, with infiltration of the vascular walls by monocytes and lymphocytes (Ding et al., 2004). Taken together, these anatomopathological findings confirm that SARS-CoV-1 can infect the CNS leading to immunopathologic damage, through the attraction of immune effector cells to the site of virus infection (Xu et al., 2005).

MERS-CoV

Since the reported first case of MERS-CoV infection in Saudi Arabia in 2012, 2578 laboratory-confirmed cases have been reported globally to date, including 888 associated deaths, with a case-fatality ratio (CFR) of 34.4% (Kim et al., 2017; WHO, 2021). MERS-CoV infection typically causes severe lower respiratory tract infection, and it is occasionally associated with gastrointestinal symptoms and renal failure (Desforges et al., 2019). MERS-CoV most probably originated from bats before infecting an intermediary reservoir (the dromedary) (Omrani et al., 2015). Although possible, human-to-human MERS-CoV transmission appears difficult, as it requires extended close contact with an infected individual (Desforges et al., 2019). Unlike SARS-CoV-1 and SARS-CoV-2, which penetrate the host cell through the ACE-2 receptors, the main target of MERS-CoV is the dipeptidyl peptidase-4 (DPP4, also known as CD26), expressed on the cell surface and involved in glucose metabolism (Raj et al., 2013; Arabi et al., 2015; Al-Hameed, 2017). DPP4 is widely expressed in many tissues and organs including lungs, kidneys, placenta, liver, skeletal muscles, heart, brain (both neurons and astrocytes), endothelium, T lymphocytes, and pancreas (Abbott et al., 1994). The presence of DPP4 receptors in the brain may explain the susceptibility of neurons to infection (Arabi et al., 2015).

Animal studies have shown that both SARS-CoV and MERS-CoV can directly cause neuronal death in the medulla respiratory center by an upregulation of IL-1, IL-6 and TNF alpha cytokines response, possibly through either an inflammatory response or autophagy (McCray Jr et al., 2007; Netland et al., 2008; Montalvan et al., 2020). In vitro studies, evaluating the human tissue tropism of MERS-CoV in different cell lines, have confirmed that the virus can infect human neurons (Chan et al., 2013; Kim et al., 2017). However, although murine models develop CNS infection following intranasal inoculation with MERS-CoV, this virus has never been detected in human CNS (Chan et al., 2013; Li et al., 2016; Kim et al., 2017). Indeed, CNS involvement in MERS-CoV infection may be mostly due to an auto-immune reaction through autoreactive T-cells which recognize viral and myelin antigens as similar molecules, rather than to viral infection itself (Chan et al., 2013; Joob and Wiwanitkit, 2015; Al-Hameed, 2017; Kim et al., 2017; Verstrepen et al., 2020).

HCoV-OC43 and HCoV-229E

In immunocompetent individuals, HCoV-229E and HCov-OC43 usually cause upper respiratory tract infections, such as rhinitis, laryngitis/pharyngitis, or otitis (Desforges et al., 2019). However, several in vitro and animal data have confirmed that HCoV-OC43 and HCoV-229E are naturally neuroinvasive (Desforges et al., 2014). HCoV-OC43 and HCoV-229E have been also isolated from the brains of people suffering from multiple sclerosis (MS) together with the detection of intrathecal synthesis of antibodies to HCV-OC43 and HCV-229E (Arbour et al., 2000; Jha et al., 2021). Indeed, HCoV-OC43 and HCoV-229E are able to infect human neurons and glial cells in cell cultures (Arabi et al., 2015; Arbour et al., 2000). In particular, oligodendrocytes,

astrocytes, microglia, and neurons are susceptible to acute infection with HCoV-OC43, and all support persistent infection except microglia (Arbour et al., 1999; Hulswit et al., 2019; Zubair et al., 2020). This was confirmed by the detection of HCoV-OC43 after more than 1 year post-inoculation in a murine model of coronavirus encephalitis (Jacomy and Talbot, 2003). In murine models, HCoV-OC43 can invade the CNS intranasally through a trans-synaptic spread with a subsequent direct virus-mediated neuronal damage (Jacomy and Talbot, 2003; Dubé et al., 2018; Jha et al., 2021). After brain invasion, HCoV-OC43 could disseminate from the olfactory bulb to other regions of the brain, including the cortex and the hippocampus, the brainstem and spinal cord (Desforges et al., 2013; Desforges et al., 2014). The CNS damage causes a range of neurologic disorders in mice, including encephalitis and transient flaccid paralysis (Jacomy and Talbot, 2003; Dubé et al., 2018). During the infection, it has been assumed that the typical responses to control viral infections, such as inflammatory and cytolytic strategies, are not used by the immune system in the brain since they can have potentially devastating consequences (Jha et al., 2021). This may lead to a type of immune response in the CNS that favor viral latency as well as reactivation in favorable situations (Miller et al., 2016; Jha et al., 2021). This differs from SARS-CoV-1 in which it is assumed that the immune-mediated injury is mainly responsible of neuronal damage.

SARS-CoV-2

The spectrum of invasiveness of SARS-CoV-2 is relatively well known today (Datta et al., 2020). Although the main target of SARS-CoV-2 is the epithelium of the respiratory tract (with prevalent respiratory symptoms), the virus can infect multiple organs, including the brain.

SARS-CoV-2 relies on its obligate receptor, the ACE2, to enter the host cells (Jackson et al., 2022). The glycoprotein viral spike (S) mediates the attachment and the fusion of the virus to the host cell membrane. The S protein consists of two subunits: the S1 subunit which binds ACE2 and the S2 subunit which anchors the S protein to the membrane and mediates the membrane fusion (Jackson et al., 2022). The entry of the virus into the host cell is further mediated by the transmembrane serine protease 2 (TMPRSS2) that cleaves the S protein allowing the entry into the host cell (Hoffmann et al., 2020; Tiwari et al., 2021). The ACE2 receptor has further potential functions during SARS-CoV-2 infection, including mediation of intracellular inflammation through the activation of tumor necrosis factor-α (TNF-α), and induction of shedding of the ACE2 receptor (Haga et al., 2008; Williams et al., 2021a, b). SARS-CoV-2 primarily targets the respiratory epithelium which is very rich in ACE2 receptors (Cevik et al., 2020). However, ACE2 receptors are present not only in the lung alveolar epithelial and small intestine epithelial cells but also in various human organs (oral and nasal mucosa, nasopharynx, stomach, skin, lymph nodes, thymus, bone marrow, spleen, liver, kidney, and brain) (Cevik et al., 2020; Zubair et al., 2020; Reza-Zaldívar et al., 2021; Chen et al., 2021). In these organs, ACE2 receptors are highly localized in the arterial and venous endothelial cells and arterial smooth muscle (Hamming et al., 2004). The possible entry routes for SARS-CoV-2 into central nervous system and potential intracellular consequences are showed in Fig. 17.1.

Mechanisms of neuronal damage

In the CNS, ACE2 receptors have been found in neurons, microglia, astrocytes, and oligodendrocytes and are expressed in multiple regions of the human and mouse brain, including the motor cortex, posterior cingulate cortex, ventricles, choroid plexus, striatum, paraventricular nuclei of the thalamus, substantia nigra, olfactory bulb, middle temporal gyrus, ventrolateral medulla, nucleus of tractus solitarius, and dorsal motor nucleus of the vagal nerve (Zubair et al., 2020; Reza-Zaldívar et al., 2021; Chen et al., 2021). Furthermore, ACE2 protein has been also observed in human brain vessels (Hamming et al., 2004), particularly in pericytes and smooth muscle cells in the vascular wall whereas they have not been found but in the endothelium lining cerebral vessels (Iadecola et al., 2020). Studies with human brain organoids, a stem cell-derived reductionist experimental system, have highlighted the neurotropic effects of SARS-CoV-2 in vitro (Ramani et al., 2021). One of these studies has showed clear evidence of infection in brain organoids with accompanying metabolic changes in infected and neighboring neurons, together with the demonstration of SARS-CoV-2 neuroinvasion in vivo in mice that overexpressed human ACE2 (Song et al., 2021). The susceptibility to infection could also be influenced by the anatomic and function location of different types of neurons as demonstrated in brain cells derived from human pluripotent stem cells, in which dopaminergic neurons, but not cortical neurons or microglia, were particularly susceptible to SARS-CoV-2 infection (Iadecola et al., 2020; Yang et al., 2020). This could be at least partly related to the presence of ACE2 receptors in the substantia nigra, as well as its coexpression with dopamine decarboxylase, an enzyme converting L-dopa to dopamine (Bouali-Benazzouz and Benazzouz, 2021). On the contrary, one study found that cerebral organoids, neural progenitor cells, neurons, and astrocytes express low levels of ACE2 and TMPRSS2 and correspondingly

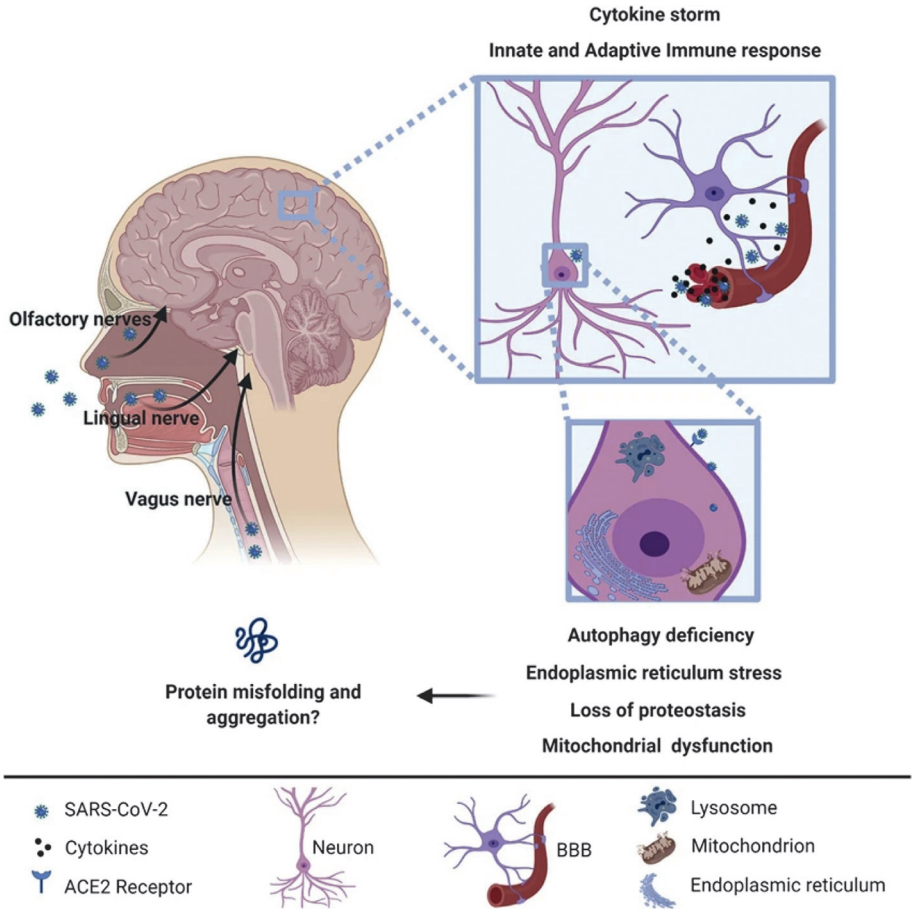

Fig. 17.1. Possible entry routes for SARS-CoV-2 into central nervous system and potential intracellular consequences. There is evidence for SARS-CoV-2 invasion of vasculature in the brain, but little evidence for SARS-CoV-2 in brain parenchyma at this time: this issue will become clearer with results from ongoing autopsy studies. Whether or not the virus is present in neurons or astrocytes, there may be multiple consequences for brain cells, in part through intracellular responses to inflammation that could lead to protein misfolding, a feature of neurodegenerative disorders. Reprinted, with permission, from Sulzer D, Antonini A, Leta V et al. (2020). COVID-19 and possible links with Parkinson's disease and parkinsonism: from bench to bedside. NPJ Parkinsons Dis 6: 18.

are not highly permissive to SARS-CoV-2 infection, even though the infected neuronal cells activate the 2′, 5′-oligoadenylate synthetase 2, an antiviral interferon-stimulated gene, the complement system and apoptotic genes (Tiwari et al., 2021). Postmortem studies have shown the presence of SARS-CoV-2 in cortical neurons, thus providing evidence for the neuroinvasive capacity of SARS-CoV-2 (Song et al., 2021). Indeed, a recent systematic review reported the frequency of neuropathologic findings in COVID-19 patients: microgliosis (52.5%), astrogliosis (45.6%), inflammatory infiltrates (44.0%), hypoxic–ischemic lesions (40.8%), edema (25.3%), and hemorrhagic lesions (20.5%), while SARS-CoV-2 RNA and proteins were identified in brain specimens of 41.9% and 28.3% of subjects, respectively (Cosentino et al., 2021). The detection rate of SARS-CoV-2 RNA and proteins in brain specimens did not differ between patients with and those without neurologic symptoms (Cosentino et al., 2021). Cerebrospinal fluid (CSF) studies have not clarified the role of the direct neuroinvasion in SARS-CoV-2 infection. Indeed, the detection of SARS-CoV-2 in CSF with PCR or with evaluation for intrathecal antibody synthesis appears to be rare, and it has only been found in a very small percentage of patients (Lersy et al., 2021; Lewis et al., 2021a). All these heterogeneous results highlight the need to further investigate the neuroinvasiveness of SARS-CoV-2.

The ability of coronavirus to induce a robust inflammatory response even within the CNS has been confirmed through both in vitro cell cultures and in vivo mouse models (Bohmwald et al., 2018). Indeed, coronavirus neurovirulence correlates with the ability of the virus to induce pro-inflammatory cytokines (IL-12 p40, TNFα, IL-6, IL-15, and IL-1β) signaling from

astrocytes and microglia in a mouse model (Bohmwald et al., 2018; Bodro et al., 2020). Furthermore, primary glial cell cultures exposed to coronavirus secrete several pro-inflammatory cytokines such as IL-6, IL-12, IL-15, and TNFα (Bohmwald et al., 2018; Bodro et al., 2020). Recent CSF studies have also confirmed the intrathecal inflammatory response related to COVID-19 infection with increased inflammatory CSF markers (elevated albumin quotient, CSF-specific IgG oligoclonal band, mirror pattern) (Lersy et al., 2021). People with COVID-19 and related inflammatory neurologic diseases presented with increased levels of IL-2, IL-4, IL-6, IL-10, IL-12, CXCL8, and CXCL10 in the CSF while encephalopathic individuals showed high serum levels of IL-6, CXCL8, and active TGF-β1 (Espíndola et al., 2021). Elevated plasma and CSF levels of cytokines, glial fibrillary acidic protein and neurofilament light chain in people with COVID-19 may be related to the pro-inflammatory systemic and brain response that involves microglial activation with subsequent neuronal damage (Kanberg et al., 2020; Pilotto et al., 2020a; Edén et al., 2021; Solomon, 2021). Moreover, even in the absence of SARS-CoV-2 brain invasion, viral proteins shed in the circulation and molecular complexes from damaged cells, such as the nuclear protein high mobility group box 1, could enter the brain through a compromised blood–brain barrier (BBB) inducing an innate immune response in pericytes, brain-resident macrophages, and microglia, impairing brain function and increasing cytokine production (Dantzer, 2018; Iadecola et al., 2020). Further potential pathogenic mechanisms of neuronal damage include coagulopathies with associated cerebral ischemic injury (see the following section) and systemic hypoxia secondary to lung disease that can result in anoxic/hypoxic brain injury (Balcom et al., 2021; Pizzi, 2021). Overall, the virus can infect the brain through at least five ways, alone or in concert: hematic propagation (with blood–brain barrier rupture), neuronal direct infection (through the olfactory epithelium and nerve), transneural retrograde propagation (vesicular transport, passive diffusion), serotoninergic pathways (from the serotoninergic dorsal raphe nucleus), and lymphatic vessels (lymphocytes and infected leukocytes) (Sinha et al., 2021). However, the trans-synaptic and hematic viral entries to the brain seem to be more commonly accepted.

Trans-synaptic route

Coronaviruses can spread within the PNS and CNS thanks to endocytosis or exocytosis mediated trans-synaptic transfer and can move along microtubules back to neuronal cell bodies using the fast axonal vesicular transport (Dubé et al., 2018; Zubair et al., 2020). There is evidence from animal models supporting a retrograde transfer of SARS-CoV-2 from the olfactory epithelium or through the cribriform bone to the brain in 7 days (Wu et al., 2020, Baig et al., 2020). Moreover, anosmia and ageusia are commonly symptoms in COVID-19 patients (Moro et al., 2020), probably due to the direct viral infection of the olfactory system and gustatory receptors. Consequently, concerns were raised that olfactory infection with SARS-CoV-2 might lead to CNS involvement in infected subjects (Solomon, 2021). The olfactory neuroepithelium consists of a limited number of cell types arranged in a roughly laminar pattern, with sustentacular cells in the most apical location, followed by bipolar sensory olfactory receptor neurons and then the basal cells (Hu et al., 2020). The apical dendrites of olfactory neurons end in the olfactory epithelium at the roof of the nasal-pharyngeal cavity, while the unmyelinated axons leave the neuroepithelium and penetrate the cribriform plate into the olfactory bulb which has connections to many higher brain regions including piriform cortex, amygdala, olfactory tubercle, entorhinal cortex, orbitofrontal cortex, hypothalamus, thalamus, and hippocampus (Mori et al., 2005; Hu et al., 2020; Meunier et al., 2021). The cells of the olfactory epithelium highly express ACE-2 receptors and TMPRSS2, which are essential for viral binding and replication (Brann et al., 2020; Reza-Zaldívar et al., 2021). However, studies using single-cell sequencing in mouse models have detected ACE2 and TMPRSS2 in the nasal mucosa at the RNA and protein levels in epithelial cells (sustentacular cells) and not olfactory neurons (Brann et al., 2020; Butowt and Bilinska, 2020; Pizzi, 2021; Solomon, 2021). However, a subsequent postmortem study has showed, through immunohistochemistry for neuronal markers TuJ1, NF-200 and OMP on olfactory mucosa samples, that SARS-CoV-2 is present in olfactory neurons. These findings support the hypothesis that SARS-CoV-2 is able to use the olfactory mucosa as a port of entry into the brain (Lemprière, 2021; Meinhardt et al., 2021).

Furthermore, recent studies have pointed out the essential role of neuropilins in cell infectivity promoting SARS-CoV-2 entry and infection, particularly if coexpressed with ACE-2 and TMPRSS2 (Reza-Zaldívar et al., 2021). Neuropilins are highly expressed in the respiratory and olfactory epithelium (Reza-Zaldívar et al., 2021). This indirect evidence (i.e., the expression of ACE2, TMPRSS2 and neuropilins in the nasal mucosa and the frequent presence of hyposmia and hypogeusia as early symptoms in people with COVID-19 infection) supports the possible neuroinvasion of the virus into the CNS via olfactory neurons (Brann et al., 2020; Pizzi, 2021; Solomon, 2021).

The SARS-CoV-2 CNS invasion through the olfactory route it is also supported by isolated case reports

about the presence of transient cortical FLAIR hyperintensity on magnetic resonance imaging (MRI) in the gyrus rectus, the anterior cingulate gyrus, polar part of the first frontal gyrus, piriform cortex, amygdala, and anterior hippocampus in COVID-19 positive individuals with smell disorders (Eliezer et al., 2020; Politi et al., 2020; Casez et al., 2021). In addition to the transcribial route and the olfactory nerve, the virus may use other peripheral nerves such as the vagus nerve, which reaches the brainstem through gut afferents (Reza-Zaldívar et al., 2021). This hypothesis is supported from the strong presence of ACE-2 receptors in intestinal epithelial cells and the detection of SARS-CoV-2 in feces of people with COVID-19 (Chen et al., 2020). Moreover, previous reports of anterograde and retrograde viral transmission from duodenal cells to brainstem neurons (such as influenza virus and hemagglutinating encephalomyelitis virus) is consistent with the hypothesis of neuro-invasion through retrograde neuronal transport of SARS-CoV-2 infection from the enterocyte to the enteric nervous system and through the vagal nerve up to the CNS (Keyhanian et al., 2020; Reza-Zaldívar et al., 2021). The possible role of the vagal nerve is particularly relevant considering that evidence of brainstem involvement in severe COVID-19 has been provided by both neurophysiologic, clinic and histopathologic data, especially at the medullary level (Manganelli et al., 2020; Keyhanian et al., 2020; Bocci et al., 2021). Indeed, viral antigens were detected in respiratory brainstem centers including the solitary tract nucleus and the nucleus ambiguous, leading to the hypothesis that the brainstem involvement likely contributes to respiratory failure in people with COVID-19 (Keyhanian et al., 2020; Manganelli et al., 2020; Bocci et al., 2021). Finally, the trigeminal nerve, which usually supplies nociceptive cells in nasal cavity as well as sensory fibers in conjunctiva, might be a further potential source of CNS involvement (Keyhanian et al., 2020).

Hematogenous route

The so-called "hematogenous route" refers to the presence of a given virus in the blood where it can either infects endothelial cells of the BBB or infect leukocytes that will become a viral reservoir for dissemination toward the CNS (Desforges et al., 2014). The BBB includes multiple components which control its permeability: astrocytes, pericytes, extracellular matrix, and specialized brain microvascular endothelial cells that are joined through tight junctions (TJs) (Bohmwald et al., 2018). Endothelial cells of the brain capillaries express ACE2-receptors and thus they are potential cell-hosts for SARS-CoV-2 (Hamming et al., 2004). A recent in vitro study supports that SARS-CoV-2 can cross the BBB through a transcellular pathway accompanied by basement membrane disruption without obvious alteration of TJs (Zhang et al., 2021). Furthermore, the presence of the virus in neural and capillary endothelial cells was detected at postmortem examination from a frontal lobe tissue specimen of an individual with COVID-19 (Paniz-Mondolfi et al., 2020). The direct viral endothelial infection could lead to subsequent endothelial injury in the peripheral vasculature causing endothelitis and potential endothelial ACE2 downregulation (Najjar et al., 2020). Furthermore, SARS-CoV-2 also infects choroid plexus epithelial cells in human brain organoids highlighting that the blood–cerebrospinal fluid barrier might be an entry point for the virus into the CNS (Pellegrini et al., 2020; Zhang et al., 2021). SARS-CoV-2 can also pass through the BBB by infecting leukocytes, the so called "Trojan horse mechanism" well described for HIV, in which infected immune cells pass from the blood through the BBB to infect the CNS (Zubair et al., 2020). Infected peripheral lymphocytes and macrophages could also facilitate viral penetration across BBB, meninges, and choroid plexus (Reza-Zaldívar et al., 2021). SARS-CoV-1 and 229E-CoV have been shown to infect leucocytes (i.e., lymphocytes, granulocytes, and monocytes) which all express ACE2 receptors (Zubair et al., 2020; Reza-Zaldívar et al., 2021). Infiltrating protective immune cells, and migrating from the bloodstream into the CNS parenchyma through disrupted BBB could be favored by the disruption of the BBB mediated by systemic inflammatory response to SARS-CoV-2 infection (Wu et al., 2020; Baig et al., 2020) that can lead to the development of the so-called "cytokines storm." Cytokines storm is a hyperinflammatory, pathologic state that results from a sudden increase in specific circulating pro-inflammatory cytokines levels, which leads to overwhelming systemic inflammation, exacerbating viral pathogenesis and causing sepsis, Acute Respiratory Distress Syndrome (ARDS), and multiorgan failure (Mahmudpour et al., 2020; Thepmankorn et al., 2021). The most commonly detected cytokines in the plasma of people with COVID-19 are pro-inflammatory cytokines such as IL1β, IL6, IL12, CXCL10, IL2, IFNγ, and monocyte chemoattractant protein (Williams et al., 2021a, b). Even if this Trojan horse mechanism involving the extravasation of infected leukocytes into meninges and the cerebrospinal fluid is plausible, compelling evidence for immune cell infection by SARS-CoV-2 is still unclear (Reza-Zaldívar et al., 2021).

NEUROLOGIC MANIFESTATIONS OF HUMAN CORONAVIRUS INFECTION

SARS-CoV-1

During the SARS-CoV-1 pandemic of 2002–2003, neurologic complications were reported in a subset of

patients (Zubair et al., 2020) including peripheral nervous diseases, rhabdomyolysis, neuromuscular disorders, seizures, and large artery ischemic stroke (Hu et al., 2020). SARS-CoV-1 RNA has been found in the CSF of people who experienced generalized tonic–clonic seizures or status epilepticus, highlighting its epileptogenicity properties (Hung et al., 2003; Verstrepen et al., 2020). Ischemic stroke in SARS-CoV-1 infection has been reported in few cases, always in association with large vessel occlusion (Karimi et al., 2020). Neuromuscular disorders in SARS-CoV-1 infection were predominantly reported as late-onset sequelae, including critical-illness polyneuropathy and myopathy (Tsai et al., 2004). Muscle weakness and elevated serum creatine kinase levels occurred in more than 30% of patients while postmortem histological examinations revealed the presence of myopathy, either resulting from critical illness myopathy or from the immune response against the virus (Verstrepen et al., 2020). Last, three cases of GBS axonal-variant after SARS-CoV-1 infection have been reported (Zubair et al., 2020).

MERS-CoV

Neurologic manifestations in MERS-CoV infection appeared concomitantly with respiratory symptoms or 2–3 weeks later (Arabi et al., 2015; Kim et al., 2017). In the main study which investigated clinical outcome of MERS-CoV infection in 70 patients, neurologic manifestations were frequently reported (Saad et al., 2014). In particular, myalgia was reported in 20% of patients, headache in 13%, confusion in 25%, and seizures in the 8% of patients (Saad et al., 2014). Other studies reported specific neurologic syndromes associated with MERS-CoV infection including Bickerstaff's encephalitis, GBS, spontaneous intracranial hemorrhage (Al-Hameed, 2017; Kim et al., 2017) or complex syndromes characterized by altered level of consciousness ranging from confusion to coma, ataxia, and focal motor deficit with widespread, bilateral hyperintense lesions on T2-weighted imaging at brain MRI study (Arabi et al., 2015).

SARS-CoV-2

SARS-CoV-2 infection has been associated with several neurologic symptoms and manifestations due to both CNS and PNS involvement, ranging from nonspecific symptoms (headache, myalgia, dizziness, fatigue) to cerebrovascular disease, encephalitis, movement disorders, myelitis, cranial and peripheral neuropathies (Moro et al., 2020; Romoli et al., 2020). Based on systematic reviews and individual patient data meta-analysis, 7.8% (95% CI 1.6–31.2) of hospitalized people with COVID-19 had neurological disease (Singh et al., 2021).

The most prevalent neurological symptoms in COVID-19 were anosmia (43.1% (35.2%–51.3%)), weakness (40.0% (27.9%–53.5%)), fatigue (37.8% (31.6%–44.4%)), dysgeusia (37.2% (29.8%–45.3%)), and myalgia (25.1% (19.8%–31.3%)) (Rogers et al., 2021). Several reports and reviews of neurologic manifestations of SARS-CoV-2 have been published so far, but they often suffer from poor comparability of data, different case definitions (on clinical, neuropathologic and neuroradiologic ground) and sometimes incomplete diagnostic pathway (see the qualification of cryptogenic stroke in one of the first reviews) (Fraiman et al., 2020). Some authors have used a symptom-based approach or a mixed approach whereas others have focused on neuroradiologic or (less often) neuropathologic details. The case definition is not uniform across the studies and the severity of infection is differently stated. These limitations make the epidemiology and the impact of neurologic manifestations of SARS-CoV-2 very challenging to ascertain. The definition provided by the WHO for confirmed, probable and suspected COVID-19 cases (WHO, 2020a) has not been uniformly applied to neurologic manifestations such as SARS-CoV-2 associated meningitis, encephalitis, myelitis, acute disseminated encephalomyelitis (ADEM), GBS, and stroke (Ellul et al., 2020). Using standardized definitions would increase the comparability of data across countries and help to reliably distinguish a nonspecific and specific association between infection and neurological manifestations. For some manifestations, uniform formal definitions and diagnostic criteria do not exist, i.e., for "encephalopathy" (Slooter et al., 2020). In particular, the proposed definitions of SARS-CoV-2 meningitis, encephalitis, myelitis, or CNS vasculitis (Ellul et al., 2020) require the SARS-CoV-2 detection in CSF or brain tissue or the evidence of SARS-CoV-2-specific intrathecal antibody, and no other explanatory pathogen or cause found.

In a recent systematic review, the main neurologic manifestations were considered and rated (Leven and Bösel, 2021). Miscellaneous disorders (including anosmia and hyposmia) accounted for 1676/4075 cases, followed by metabolic/toxic CNS dysfunction with 1106/4075 cases, and cerebrovascular disease with 451/4075 cases (Leven and Bösel, 2021). As discussed above, the occurrence of neurologic manifestations is not surprising given the involvement of the central and peripheral nervous system through vascular effects (endothelial dysfunction, thrombotic microangiopathy), para-infectious autoimmune effects (cytokines storm), and postinfectious autoimmune effects (cellular immunity and autoantibodies).

Neurologic manifestations in people with COVID-19 carry a higher disease severity and a worse prognosis,

prolonging hospital staying. Encephalopathy and stroke had the strongest association with a more severe disease (Liotta et al., 2020). Pre-existing morbidity partially accounts for the outcome. Indeed, identified risk factors for poor outcome include preexisting neurological disorders, age, male sex, white race, hypertension, diabetes, intubation, and higher sequential organ failure assessment scores (Liotta et al., 2020; Chou et al., 2021; Frontera et al., 2021). Additional elements that affect the diagnoses and management of neurologic complications are the effects of the pandemic on the organization of care and the severity of systemic SARS-CoV-2 infection. With regard to the latter, the neurologic manifestations, in particular the cerebrovascular ones, worsen the outcome of the infection whereas the infection severity negatively affects the evolution of the neurologic disease.

The principal acute and subacute neurological manifestations of COVID-19 infection are reported in Table 17.3, and discussed in details in the following section.

Acute and subacute manifestations

Encephalitis and encephalopathies

COVID-19 has been associated with an increased prevalence of acute encephalopathy both as main feature at presentation and together with respiratory failure and systemic involvement in people admitted in intensive care unit (ICU) (Koralnik and Tyler, 2020). COVID-19 encephalopathy is defined by a rapidly developing (less than 4 weeks) pathologic process in the brain leading to delirium, decreased level of consciousness or coma (Koralnik and Tyler, 2020). People with encephalopathy may additionally have seizures, headache, or extrapyramidal signs. According to the general updated definition of encephalopathy (Slooter et al., 2020), including delirium, the clinical and neuroimaging spectrum is heterogeneous (Kremer et al., 2020) but its pathology remains incompletely understood. The occurrence of this complication even outside the pandemic has been associated with increased hospital length of stay and higher mortality (Ely et al., 2004). There are few case series including a very small sample of people with severe COVID-19 encephalopathy and a clinical response to steroid treatment, suggesting inflammatory mechanisms (Pugin et al., 2020; Uginet et al., 2021). In 31 individuals with a neurologic diagnosis of COVID-19 encephalopathy (22 in the intermediate care units, 6 in the standard care unit, and 3 in the ICU), the severity of the pneumonia was not associated with severity of the COVID-19 encephalopathy (Uginet et al., 2021). The clinical presentation was characterized by greater incidence of headache and corticospinal tract signs at neurologic examination in severe vs. mild encephalopathy. The presence of headache, even in the prodromal phase, was a strong predictor of developing a severe COVID-19 encephalopathy (OR = 12.0; 95% CI (1.2–117.4); $P = 0.033$). In three elderly patients, hypersomnolence and generalized myoclonus, aggravated by auditory and tactile stimuli and with exaggerated startle response, electroencephalography (EEG) and MRI did not reveal any abnormality (Rábano-Suárez et al., 2020). The main EEG feature was activity slowing in 73.9%, as reported in critically ill people with COVID-19 (Vespignani et al., 2020). As previously reported, in these cases there was not a significant increase in cell count on CSF examination but an increase in CSF/serum quotient of albumin (Uginet et al., 2021), and brain MRI abnormalities with prominent features of intracranial vessels gadolinium enhancement (85.0% of patients) (Keller et al., 2020), mainly on vertebral arteries without sign of stenosis or downstream ischemia, and cerebral microbleeds (44% of patients) with a prevalent mixed distribution. There were no differences in term of brain MRI abnormalities between severe and mild COVID-19 encephalopathies. However, other reports of neuroimaging abnormalities in COVID-19 associated encephalopathy described cortical or subcortical white matter T2/FLAIR signal hyperintensity as common feature, although in many patients, neuroimaging abnormalities may not be present (Jain et al., 2020; Mahammedi et al., 2020; Radmanesh et al., 2020a, b; Abenza Abildúa et al., 2021). Periventricular white matter T2/FLAIR hyperintensity and microbleeds on brain MRI are often attributed to microangiopathy; however, critically ill patients often have severe coagulopathy and severe microangiopathy with several microbleeds (Maas, 2020; Radmanesh et al., 2020b).

A peculiar form of acute encephalopathy with distinctive neuroimaging findings has been reported in people with COVID-19 as acute necrotizing encephalopathy (Elkady and Rabinstein, 2020). This is a rapidly evolving brain disorder with symmetric, multiple neuroimaging lesions in the thalamus, basal ganglia, deep cerebral white matter, and brain stem. The clinic manifestations are seizures, focal neurologic deficit, and coma.

In the published series, the prevalence of COVID-19 encephalopathy is underestimated due to the lack of systematic screening by a neurologist and to the difficult identification of this condition in patients severely affected and admitted in ICU. Moreover, several patients, in particular during the first wave of the pandemic, did not undergo EEG, neuroimaging or CSF examination. Therefore, both ends of the severity line, i.e., patients with very severe involvement and patients with milder or prodromal signa, may not have been identified. Another clear limitation is included in the broad definition of encephalopathy, which is, in fact, a common manifestation of multiple organ dysfunction (acute respiratory insufficiency and renal, hepatic, or cardiac failure)

Table 17.3

Acute and subacute clinic manifestations of COVID-19 infection

Acute and subacute manifestations	Prevalence	Clinical clues	Instrumental findings	Possible pathophysiologic mechanisms	Treatment
Encephalitis and encephalopathies	Largely underestimated; the prevalence of delirium was 55% in a large cohort of COVID-19 patients admitted in ICU (Koralnik and Tyler, 2020). COVID-related encephalitis is anecdotally reported.	Headache, delirium, decreased level of consciousness, seizures, extrapyramidal signs (Koralnik and Tyler, 2020).	Cortical or subcortical white matter T2/FLAIR signal hyperintensity, periventricular white matter T2/FLAIR hyperintensity and microbleeds on MRI. Necrotizing encephalopathy with symmetric, multiple neuroimaging lesions in the thalamus, basal ganglion, deep cerebral white matter, and brain stem (Elkady and Rabinstein, 2020).	Inflammatory process of the vessel wall (endothelial hypothesis) (Keller et al., 2020) Hypoxemia without dyspnea Immunomediated or autoimmune process.	Management of the underlying disease, steroid treatment, symptomatic treatment for delirium.
Stroke and other cerebrovascular diseases	Ischemic stroke: 0.9%–2.71% of hospital admissions for COVID-19 in clinical series (Logroscino and Beghi, 2021). The incidence of intracranial hemorrhage has ranged from 0.2% to 0.9%. CVT incidence in a large cohort of hospitalized patients was 0.08% (Baldini et al., 2021). Posterior reversible encephalopathy (PRES) was anecdotally reported.	Large vessel occlusion in young patients without significant vascular risk factors; relatively more prevalent ischemic vs. hemorrhagic stroke (this last one affected by antithrombotic medication for COVID-related coagulopathy). High D-dimer levels. Prognosis often related to the severity of infection. Cerebrovascular complications may be underreported, in particular in the first wave of the pandemic.	Large vessel occlusion with intra-arterial multiple thrombi; simultaneous ischemic lesions in several vascular territories; multiple scattered cortico-subcortical ischemic and microhemorrhagic lesions on MRI.	Coagulopathy; endothelitis with postinfective small vessel vasculitis; hypercoagulability and pro-inflammatory state associated with infection cardioembolism.	No specific treatment. Cerebrovascular disease should be treated as usual in the standard of care, mainly for time dependent treatment.
Headache	Prevalence between 10% and 20% (Islam et al., 2020; Rogers et al., 2021).	25% of patients complained a migraine-like headache, whereas the most common presentation is a predominantly frontal, tension-type-like headache (Caronna and Pozo-Rosich, 2021; García-Azorín et al., 2021).	N/A	Different mechanisms involved both unspecific (fever, hypoxia) and specific (direct viral invasion, systemic factors like cytokine storm, COVID-19-related rhinosinusitis) (Caronna and Pozo-Rosich, 2021; García-Azorín et al., 2021).	Up to now, no specific treatment exists for COVID-19 related headache. (Caronna and Pozo-Rosich, 2021).

Continued

Table 17.3

Continued

Acute and subacute manifestations	Prevalence	Clinical clues	Instrumental findings	Possible pathophysiologic mechanisms	Treatment
Olfactory dysfunction	Prevalence between 41% and 52% of COVID-19 patients (Agyeman, et al., 2020; Tong et al., 2020).	OD is common and may represent one of the earliest symptoms of the infection (Tong et al., 2020). OD is more frequent in mild COVID-19 forms compared to moderate-to-critical forms (Lechien et al., 2021).	MRI studies: transient edema of the olfactory clefts (Eliezer et al., 2020); transient cortical FLAIR hyperintensity in gyrus rectus and olfactory bulbs (Politi et al., 2020). FDG-PET scan: reduced metabolic activity in the orbitofrontal cortex (Galougahi et al., 2020).	Linked to inflammatory responses involving support cells of the olfactory epithelium with subsequent damage to sustentacular cells and olfactory neurons (Saussez et al., 2021).	OD usually disappeared in 95% of patients at 6 months (Lechien et al., 2021). Uncertain evidence for systemic steroids and nasal irrigation (intranasal steroid/ mucolytic/decongestant) (Vaira et al., 2021).
Seizures	Retrospective cohort studies report a seizures prevalence between 0.06% and 1.5% of hospitalized patients (Rogers et al., 2021; Oliveira et al., 2021).	Many cases with new-onset focal seizures, serial seizures, and status epilepticus have been reported in the literature (Asadi-Pooya et al., 2021).	Electroencephalography findings: abnormal background activity and generalized slowing. Epileptiform abnormalities in the form of focal intermittent epileptiform discharges, lateralized periodic discharges and generalized periodic discharges (Kubota et al., 2021; Hwang et al., 2021).	Multifactorial, depending on patients' characteristics, severity of the infection, drug interactions, specific neurological involvement with brain damage and direct viral neuroinvasion (Emami et al., 2020; Asadi-Pooya et al., 2021; Pizzi, 2021).	Up to now, no specific treatment reported for COVID-19-related seizures.
Myelitis	Twenty cases reported in the literature (Schulte et al., 2021; Artemiadis et al., 2021).	In the majority of cases classical triad of weakness of the lower extremities, sensory deficits in the form of a sensory level, and bladder or bowel dysfunction (Schulte et al., 2021; Artemiadis et al., 2021). Symptoms mainly occurred from 8 to 10 days after symptoms of COVID-19 infection even if, in a minority of cases, they could appear simultaneously to respiratory symptoms (Schulte et al., 2021; Artemiadis et al., 2021).	Heterogeneous MRI pattern including central longitudinal T2 changes without corresponding enhancement; T2-bright and centrally necrotic enhancing lesions; a more tract-specific disease (Huang et al., 2021a, b).	Para- or postinfective mechanisms (Schulte et al., 2021).	Intravenous corticosteroids followed by second line treatment with immune therapy (plasma exchange in most of the cases) (Schulte et al., 2021; Artemiadis et al., 2021).

GBS spectrum disorders	Including hospitalized and nonhospitalized COVID-19 cases, 0.15% pooled GBS prevalence (Palaiodimou et al., 2021).	Most of the cases had typical GBS clinical form characterized by weakness and sensory signs starting in the legs and progressing to arms and cranial muscles. Some specific GBS variants have been reported including Miller Fisher syndrome, facial diplegia and polyneuritis cranialis (Maury et al., 2021). The interval between the onset of symptoms of COVID-19 infection and GBS ranged from 8 to 24 days (mean 9 days) (Palaiodimou et al., 2021).	Most of the cases had demyelinating electrophysiological subtype (De Sanctis et al., 2020). COVID-19 is associated with a 3-fold increase in the likelihood of AIDP compared to noninfected contemporary or historical GBS controls (Palaiodimou et al., 2021).	By direct damage of the virus and/or by dysregulation of the immune response (Filosto et al., 2021). Possible immune cross-reaction with the *N*-acetyl-galactosamine residue of GM1 (Filosto et al., 2021).	Clinical outcomes, including in-hospital mortality, and treatment (either intravenous immunoglobulin or plasmapheresis) were comparable between COVID-19 GBS patients and noninfected contemporary or historical GBS controls (Palaiodimou et al., 2021).
Multiple cranial neuropathies	Few cases reported in the literature (Sharifian-Dorche et al., 2020; Gupta et al., 2021).	Cranial nerve abnormalities including impaired eye movement with oculomotor, trochlear or abducens palsy; trigeminal neuropathy and BP (Sharifian-Dorche et al., 2020; Gupta et al., 2021).	Heterogeneous results from brain-MRI studies ranging from normal findings to involvement of different cranial nerves based on clinical syndrome (Sharifian-Dorche et al., 2020; Gupta et al., 2021).	Unclear	Steroids, antiviral drugs, eye drops, and oral lubricants (Sharifian-Dorche et al., 2020; Gupta et al., 2021).
Neuromuscular junction disorders	Few cases reported in the literature (Restivo et al., 2020; Andalib et al., 2021).	Onset of myasthenia gravis' symptoms within 5–7 days after fever onset (Restivo et al., 2020; Andalib et al., 2021).	Significant decrement at repetitive stimulation of facial and ulnar nerves (Restivo et al., 2020).	Molecular mimicry mechanisms (Restivo et al., 2020; Andalib et al., 2021).	Pyridostigmine, steroids, plasmapheresis.
Muscular involvement	COVID-19 infection is associated with myalgia or fatigue in 11%–70% of cases, and CK elevation in 9%–33% (Romero-Sánchez et al., 2020; Mahammedi et al., 2020; Guilmot et al., 2020; Agarwal et al., 2021; Suh et al., 2021).	May vary from diffuse myalgia and fatigue to myopathic features.	Case–control autopsy series: most individuals with severe COVID-19 showed signs of myositis likely related to release of cytokines (Suh et al., 2021; Aschman et al., 2021). Detection of viral load was low or negative in most skeletal and cardiac muscles assessed (Suh et al., 2021; Aschman et al., 2021).	SARS-CoV-2 may lead to a postinfectious, immune-mediated myopathy (Suh et al., 2021; Aschman et al., 2021).	Up to now, no specific treatment reported.

Abbreviations: AIDP: acute inflammatory demyelinating polyneuropathy; BP: Bell's Palsy; CK: creatine kinase; CVT: cerebral venous thrombosis; GBS: Guillain–Barré syndrome; ICU: intensive care unit; OD: olfactory dysfunction.

because the body fails to maintain the normal functioning of the brain (Slooter et al., 2020). The pathophysiologic hypotheses of the published cases suggest, among other mechanisms, the role of inflammation of the vessel wall, maybe linked to the endothelial hypothesis (Keller et al., 2020), as demonstrated by histopathology of people with intracerebral hematoma and subarachnoid hemorrhage (Hernández-Fernández et al., 2020). However, hypoxemia-induced encephalopathy may a valuable alternative hypothesis, mainly in intubated and/or ventilated patients with ARDS. A limitation in generalizability of this last hypothesis is that the severity of COVID-19 encephalopathy is not associated with the severity of pneumonia. Some authors suggest a different mechanism, called "happy or silent hypoxemia" (i.e., hypoxemia without dyspnea), as consequence of inappropriate cortical processing of interoceptive information from the respiratory system (Allali et al., 2020; Couzin-Frankel, 2020). The core of this hypothesis is that the presence of COVID-19 encephalopathy may interfere with the activation of several cortical regions involved in the dyspnea perception, in particular the insula (Burki and Lee, 2010). The role of an immunopathogenic mechanism related to COVID-19, as for other neurologic manifestations, is hard to support because of the absence of white matter lesions and meningeal or parenchymal gadolinium enhancement on brain MRI, and absence of pleocytosis in the CSF. Moreover, the absence of direct proof of SARS-CoV-2 in the CSF is strongly in favor of an indirect (or inflammatory) effect of SARS-CoV-2 for explaining encephalopathy. In this reasoning, the rationale of using steroid treatment is evident, and the response to steroid and/or immunoglobulins has been documented (Abenza-Abildúa et al., 2020; Pugin et al., 2020; Pilotto et al., 2020b). However, in the reported cases, the majority of patients spontaneously recovered from encephalopathy without steroids (Uginet et al., 2021). The unifying hypothesis for many central neurologic manifestations in COVID-19 remains that of SARS-CoV-2-induced endothelitis, which has been confirmed by autopsy in some cases (Varga et al., 2020).

Encephalitis is an acute, diffuse, inflammatory condition of the brain, clinically characterized by fever, headache, seizure, focal neurological deficits, and altered consciousness. One of the main features of the diagnosis of an infectious encephalitis is the demonstration of the responsible virus in CSF; but besides infections, encephalitis can also have an autoimmune or paraneoplastic etiology.

In COVID-19-associated encephalitis, CSF examination may show inflammatory changes (increased protein and/or increased cells) and, in rare cases, the virus was identified in CSF. In three reported cases, an indirect enzyme-linked immunosorbent assay (ELISA) in CSF demonstrated elevated levels of IgM for SARS-CoV-2 (Benameur et al., 2020). Isolated cases of COVID-19 encephalitis associated with positivity for onconeuronal antibodies (antirecoverin, antititin, and anti-Yo antibodies) were reported (Saenz Lafourcade et al., 2021). However, in monocentric series, brain MR imaging abnormalities, especially leptomeningeal enhancement, and increased inflammatory markers in CSF are frequent in people with neurologic manifestations related to COVID-19, whereas SARS-CoV-2 detection in CSF remained scanty (Lersy et al., 2021).

Stroke and other cerebrovascular diseases

Cerebrovascular disease related to COVID-19 includes ischemic and hemorrhagic arterial stroke, cortical venous sinus thrombosis (CVST), and intracranial vasculitis-induced microvascular occlusive disorder. The most commonly reported event has been ischemic stroke, mainly in elderly people with severe COVID-19 illness and vascular risk factors. However, a subcategory of COVID-19-related ischemic stroke due to large vessel occlusion and involvement of multiple territories has been reported also in young people without vascular risk factors (Cavallieri et al., 2020; Oxley et al., 2020). Few cases of COVID-19-associated CVST have been reported and they do not have sex or age predilection (Fraiman et al., 2020). The most common symptom reported is headache, but also focal neurologic deficits are common findings. Both ischemic stroke and CVST are likely related to the pro-coagulant state and endothelial damage associated with COVID-19, and highly elevated C-reactive protein (CRP) and D-dimer have been reported (Tang et al., 2020; Fraiman et al., 2020). The association with thrombocytopenia suggests a potential underlying virus-associated microangiopathy (Ellul et al., 2020). The laboratory findings of pro-coagulant state on admission have been associated with a poor survival in people with COVID-19 pneumonia (Tang et al., 2020). Apart from the increased bleeding risk related to the antithrombotic medications in individuals with severe infection, a direct effect of the virus in circumventricular organ and endothelial cells may disrupt cerebral autoregulation, leading to blood pressure fluctuations and further increasing the risk of intracerebral and/or subarachnoid hemorrhage. Also, cytokines storm and sympathetic overactivity together with direct neuroinvasion and endothelial dysfunction may promote the formation and/or the rupture of pre-existing aneurysms (Al Saiegh et al., 2020).

The impairment of cerebral autoregulation is a potential trigger of posterior reversible encephalopathy syndrome (PRES), reported as COVID-19-related manifestation in very few cases, often with pre-existing hypertension and

diabetes (Doo et al., 2021). A clinical and neuroradiological/neuropathological manifestation of COVID-19 is an extensive intracranial vasculitis with diffuse microthrombosis and microhemorrhages resulting in a neuroradiological semeiology similar to critical illness. In one of the first reported cases, SARS-CoV-2 RNA was detected in the CSF (Saitta et al., 2020).

Headache

In the setting of COVID-19 infection, headache is one of the most frequent neurological symptoms, also reported in the first case series from Wuhan (Mao et al., 2020). The frequency of headache in people with COVID-19 was reported to be moderate to high from most physicians (60%) who participated in the survey promoted by the European Academy of Neurology during the first wave of the COVID-19 outbreak in 2020 (Moro et al., 2020). Initially, the prevalence of headache in people with COVID-19 was estimated between 13% and 74.6% (Gonzalez-Martinez et al., 2021), but subsequent systematic reviews and meta-analysis have defined this prevalence between 10% and 20% (Islam et al., 2020; Rogers et al., 2021). The severity and the outcome of the infection do not significantly influence the prevalence of headache (Islam et al., 2020), even if it has been recently reported that headache is associated with a more benign SARS-CoV-2 infection (Gonzalez-Martinez et al., 2021). Headache frequency and phenotype are similar in male and female patients, but literature data are conflicting as regards the effect of sex on headache intensity (Al-Hashel et al., 2021; García-Azorín et al., 2021). Around 25% of patients experience a migraine-like headache, whereas the most common presentation is a predominantly frontal, tension-type headache (Caronna and Pozo-Rosich, 2021; García-Azorín et al., 2021). From a pathophysiologic point of view, in the setting of COVID-19 infection, headache may be the result of different mechanisms both unspecific (fever, hypoxia) and specific (direct viral invasion, systemic factors like cytokine storm, COVID-19-related rhinosinusitis) (Caronna and Pozo-Rosich, 2021; Straburzyński et al., 2021). Up to now, no specific treatment exists for headache related to COVID-19, and drugs can be chosen according to headache phenotype (Caronna and Pozo-Rosich, 2021).

Olfactory dysfunction

Olfactory dysfunction (OD) is common in people with COVID-19 infection (Mazzoli et al., 2020; Jalessi et al., 2020) and may represent one of the earliest symptoms in the clinical course of infection (Tong et al., 2020). According to several systematic reviews and meta-analysis, the OD prevalence among people with COVID-19 infection is between 41% and 52% (Agyeman et al., 2020; Tong et al., 2020). OD is more prevalent in mild COVID-19 forms than in moderate-to-critical forms, and usually disappeared in 95% of patients at 6 months (Lechien et al., 2021). OD pathogenesis in COVID-19 seems to be linked to inflammatory responses involving support cells of the olfactory epithelium which, in some individuals, can persist after the infection with progressive damage to the sustentacular cells and olfactory neurons (Saussez et al., 2021). The detection of SARS-CoV-2 in CSF studies of people with altered olfactory and/or gustatory function is extremely rare, supporting this hypothesis (Lewis et al., 2021b). Till now, no robust clinical markers predictive of the long-term evolution of OD after the infection have been found (Saussez et al., 2021). Moreover, evidence about the efficacy and harms of treatments for persistent OD following COVID-19 infection are lacking (O'Byrne et al., 2021). Recently, a Cochrane review about the treatment of OD in COVID-19 infection has been published, including only one study with a small sample size, which assessed systemic steroids and nasal irrigation (intranasal steroid/mucolytic/decongestant) (Vaira et al., 2021; O'Byrne et al., 2021). The review underlined that the evidence regarding the benefits and harms from this intervention is very uncertain (Vaira et al., 2021).

Seizures

Acute symptomatic seizures have been reported in sporadic COVID-19 cases, usually occurring between three and 7 days from initial symptoms onset (Pizzi, 2021; Santos de Lima et al., 2021). Seizures rarely represent the presenting symptoms of the infection (Fasano et al., 2020). Retrospective cohort studies have estimated the seizure prevalence ranging from 0.06% to 1.5% of COVID-19 patients (Oliveira et al., 2021; Rogers et al., 2021). The etiology of seizures is most likely multifactorial, depending on patients' characteristics (in particular, comorbidities such as diabetes or kidney disease), severity of the systemic infection that can lead to multiorgan failure, metabolic issues, or severe systemic hypoxemia with anoxic/hypoxic brain injury, drug interactions, specific neurologic involvement with brain damage (encephalitis or cerebrovascular events), and direct viral neuroinvasion (Emami et al., 2020; Asadi-Pooya et al., 2021; Pizzi, 2021). In addition, the interaction between SARS-CoV-2 and Angiotensin II, which has proconvulsant properties, may play a role together with the cytokine storm (Vohora et al., 2020). Indeed, the possible downregulation of ACE2 receptors during the infection may lead to a shift to angiotensin processing by ACE rather than ACE2 receptors, leading to an increased seizure susceptibility (Vohora et al., 2020).

Concerning EEG findings, cohort studies have found that abnormal background activity and generalized

slowing were common findings among people with COVID-19. Epileptiform abnormalities in the form of focal intermittent epileptiform discharges, lateralized periodic discharges, and generalized periodic discharges have been reported in the 20% of patients (Kubota et al., 2021; Hwang et al., 2021).

Myelitis

Acute myelitis is a very rare neurologic complication of SARS-CoV-2 infection with few case descriptions (Schulte et al., 2021). Indeed, to date, only 20 cases of COVID-19-associated acute myelitis have been reported in the literature (Schulte et al., 2021; Artemiadis et al., 2021). In most cases, neurologic symptoms consisted of the classical triad of weakness of the lower extremities, sensory deficits in the form of a sensory level, and bladder or bowel dysfunction (Artemiadis et al., 2021; Schulte et al., 2021). Acute myelitis symptoms mainly occurred from 8 to 10 days after symptoms of COVID-19 infection even if, in a minority of cases, they could appear simultaneously with respiratory symptoms (Artemiadis et al., 2021; Schulte et al., 2021).

The MRI pattern of spinal cord involvement is heterogeneous and includes: central longitudinal T2 changes without corresponding enhancement; T2-bright and centrally necrotic enhancing lesions, a more tract-specific disease, with ventral horn–predominant T2 hyperintensity or a dorsal column–predominant T2 signal abnormality; and a lateral and dorsal column–specific disease (Huang et al., 2021a). In two reported cases, spinal cord MRI was unrevealing (Schulte et al., 2021).

In three cases, acute myelitis was accompanied by encephalopathy, while in two cases the co-occurrence of acute myelitis with the GBS variant acute motor axonal neuropathy (AMAN) was reported (Artemiadis et al., 2021; Schulte et al., 2021). Most cases had a myelopathy that fulfilled Longitudinally Extensive Transverse Myelitis (LETM) criteria (Schulte et al., 2021). CSF findings reflected an inflammatory process in the majority of patients, whereas CSF PCR for SARS-CoV-2 was always negative; in two cases, specific antibodies were found (i.e., antimyelin oligodendrocyte glycoprotein-spectrum disorder and aquaporin-4 neuromyelitis optica) (Huang et al., 2021a).

Most patients were treated with intravenous corticosteroids (e.g., methylprednisolone) and about half of them received a second line of immune therapy (plasma exchange in most cases) (Artemiadis et al., 2021; Schulte et al., 2021). Acute myelitis may occur in the setting of COVID-19 infection with para- or postinfection mechanisms. However, whether the condition and the observed radiological characteristics are specific to SARS-CoV-2 infection need to be clarified in future studies (Schulte et al., 2021).

Neuromuscular involvement

COVID-19 can affect the PNS and the muscles leading to different neurological manifestations: GBS spectrum disorders, multiple cranial neuropathies, nerve pain, neuromuscular junction disorders, myalgias, myopathy, and myositis (Andalib et al., 2021). This peripheral involvement is multifactorial and caused by a combination of direct invasion (ACE2 receptors are expressed in muscle tissue) and systemic immune response with cytokine storm (McGonagle et al., 2020).

Since the beginning of the outbreak, GBS cases in people with SARS-CoV-2 have been increasingly reported, highlighting the possible link between these two entities. Subsequent observational studies have reported that GBS was found in less than 0.5% of hospitalized people with COVID-19 (Guilmot et al., 2020; Mahammedi et al., 2020; Romero-Sánchez et al., 2020; Agarwal et al., 2021; Maury et al., 2021). A recent systematic review and meta-analysis have confirmed these preliminary findings reporting that among people with COVID-19, including hospitalized and nonhospitalized cases, the pooled GBSs prevalence was 0.15% (95% CI 0%–0.49%) (Palaiodimou et al., 2021). However, epidemiologic data about the incidence of GBS during the pandemic are conflicting. Indeed, one observational multicenter study reported an increased incidence of GBS during the COVID-19 outbreak in northern Italy, supporting a pathogenic link between the SARS-CoV-2 and GBS (Filosto et al., 2021). However, a subsequent large-scale epidemiological study during the COVID-19 pandemic in the United Kingdom did not confirm a causal link between COVID-19 and GBS (Keddie et al., 2021). Most cases reported in the literature had typical GBS clinical features predominantly with a demyelinating electrophysiological subtype (De Sanctis et al., 2020). Indeed, COVID-19 is associated with a threefold increase in the likelihood of acute inflammatory demyelinating neuropathy among patients infected with SARS-CoV-2 compared to non-infected contemporary or historical GBS controls (Palaiodimou et al., 2021). Moreover, some specific GBS variants have been also described in people with COVID-19 including Miller Fisher syndrome, facial diplegia and polyneuritis cranialis (Maury et al., 2021). The interval between the onset of symptoms of COVID-19 infection and GBS ranged from 8 to 24 days (mean 9 days; median 10 days) (Palaiodimou et al., 2021). Clinical outcomes, including in-hospital mortality, and treatment (either intravenous immunoglobulin or plasmapheresis) were comparable between COVID-19 GBS

patients and noninfected contemporary or historical GBS controls (Palaiodimou et al., 2021).

The virus may induce nerve damage both directly and/or by dysregulation of the immune response through a cytokine storm (Filosto et al., 2021). As SARS-CoV-2 spike protein interacts with the *N*-acetyl-galactosamine residue of GM1 for anchoring to the cell surface, an immune cross-reaction between epitopes within the spike-bearing gangliosides and sugar residues of surface peripheral nerve glycolipids is also possible (Filosto et al., 2021).

Cranial nerve abnormalities besides the spectrum of GBS have been also reported in COVID-19 patients including impaired eye movement with oculomotor, trochlear, or abducens palsy and trigeminal neuropathy (Sharifian-Dorche et al., 2020). Few cases of Bell's palsy (BP) in COVID-19 infection have been described (Codeluppi et al., 2020; Gupta et al., 2021). Although BP has been suggested to be caused by many other viruses, evidence of BP in people with COVID-19 indicates a possible association of SARS-CoV-2 virus with BP etiopathogenesis even if the exact mechanisms by which SARS-CoV-2 causes BP are still unclear (Gupta et al., 2021). New-onset myasthenia gravis (MG) after COVID-19 infection can also occur and may also be due to molecular mimicry mechanisms as with other neurologic manifestations (Restivo et al., 2020; Andalib et al., 2021). Muscle symptoms with elevated serum creatine kinase (CK) are frequent in people with COVID-19 as first reported in the case series from Wuhan (Mao et al., 2020). Indeed, the infection is associated with myalgia or fatigue in 11%–70% of individuals, and CK elevation in 9%–33% (Guilmot et al., 2020; Mahammedi et al., 2020; Romero-Sánchez et al., 2020; Agarwal et al., 2021; Suh et al., 2021). Recently, two case–control autopsy series have found that most individuals with severe COVID-19 showed signs of myositis ranging from mild to severe, likely related to release of cytokines (Aschman et al., 2021; Suh et al., 2021). Detection of viral load was low or negative in most skeletal and cardiac muscles assessed and probably attributable to circulating viral RNA rather than genuine infection of myocytes with no evidence of direct SARS-CoV-2 invasion of these tissues (Aschman et al., 2021; Suh et al., 2021). These findings suggest that SARS-CoV-2 may lead to a postinfectious, immune-mediated myopathy (Aschman et al., 2021; Suh et al., 2021). Inflammation of skeletal muscles was also found to be associated with the duration of illness and was more pronounced than cardiac inflammation (Aschman et al., 2021). The presence of myalgia at hospital admission has been recently associated with both preexisting history of musculoskeletal pain, and musculoskeletal pain as long-term post-COVID sequelae (Fernández-de-Las-Peñas et al., 2021). Postmortem studies have also reported the presence of myopathic features in diaphragmatic muscle of critically ill COVID-19 patients with distinct characteristics compared with critically ill patients without COVID-19 (Shi et al., 2021). Another postmortem case series found SARS-CoV-2 RNA in 15% of diaphragm muscle specimens obtained from 26 consecutive autopsies of critically ill COVID-19 patients (Shi et al., 2020). Diaphragmatic involvement may contribute to the ongoing dyspnea and fatigue in the patients surviving COVID-19 infection (Shi et al., 2021).

Long-term manifestations

Long-COVID syndrome and neurologic manifestations

Long-COVID or post-COVID syndrome is defined by the National Institute for Health and Care Excellence (NICE) as "signs and symptoms that develop during or after an infection consistent with COVID-19 which continue for more than 12 weeks and are not explained by an alternative diagnosis" (Ayoubkhani et al., 2021; National Institute for Health and Care Excellence, 2021).

In a systematic review and meta-analysis of the long-term effect of COVID-19, the five most common symptoms reported were fatigue (58%), headache (44%), attention disorder (27%), hair loss (25%), and dyspnea (24%) (Lopez-Leon et al., 2021; Yan et al., 2021).

Female sex, more than five early symptoms of infection, early dyspnea, prior psychiatric disorders, and specific biomarkers (e.g., D-dimer, CRP, and lymphocyte count) have been reported as risk factors for the development of long-COVID syndrome (Yong, 2021). The underlying pathogenesis of long-COVID syndrome remains unclear, but clinical symptoms can be extensive, affect multiple organs, and may persist for many months after illness-onset (Lopez-Leon et al., 2021; Yan et al., 2021). Neurologic and psychiatric symptoms may be prominent in long-COVID and neurologists, in common with other medical specialists, are likely to require an understanding of relevant symptoms to develop optimal management strategies and services (Williams et al., 2021a, b). Indeed, recent prospective observational cohort studies (Huang et al., 2021b; Pilotto et al., 2021) have reported that at 6 months after acute infection, COVID-19 survivors are mainly troubled with fatigue or muscle weakness, sleep difficulties, memory/attention disorders and anxiety or depression. Moreover, at 6-month neurological examination, 40% of patients still exhibited neurological abnormalities, such as hyposmia (18.0%), cognitive deficits (17.5%), postural tremor (13.8%), and subtle motor/sensory deficits (7.6%) (Pilotto et al., 2021). Older age, premorbid

comorbidities, and severity of COVID-19 were found to be predictors of neurological manifestations in the long term after the infection (Pilotto et al., 2021). The nonspecific cognitive complaints identified as "brain fog" by several people after the infection has been prominently mentioned in the media with a great deal of resonance (Graham et al., 2021). A recent observational cohort study found that SARS-CoV-2 positive individuals performed worse in attention and working memory cognitive tasks compared to demographic-matched controls, highlighting that nonhospitalized individuals with COVID-19 experience prominent and persistent "brain fog" and fatigue that affect their cognition and quality of life (Graham et al., 2021). Moreover, one prospective study that compared COVID-19 survivors with non-COVID-19 volunteers has showed the existence of potential brain micro-structural changes related to SARS-CoV-2 infection which may be linked to cognitive symptoms after the infection (Lu et al., 2020). Sleep disturbances represent another important manifestation of long-COVID syndrome. They have been reported in 26% of post-COVID patients at 6-month follow-up in one large study conducted in Wuhan, China (Huang et al., 2021b). However, detailed data on the incidence and characteristics of sleep disorders in long-COVID syndrome as well as information on the optimal treatment strategies are still needed (Bhat and Chokroverty, 2021).

The exact pathophysiology of neurologic manifestations in long-COVID syndrome is still unclear. To date, biomarkers and imaging findings are not identified. For severe COVID-19 courses, it is assumed that inflammation, hypoxemia, and vascular mechanisms might contribute to the etiopathogenesis of neurological manifestations of long-COVID syndrome. Finally, SARS-CoV-2 may also trigger the production of autoantibodies (Boesl et al., 2021).

COVID-19 and neurodegeneration

Neurodegenerative diseases, including amyloid-related diseases (cerebral amyloid angiopathy and Alzheimer's disease), Parkinson disease (PD), frontotemporal dementia, and other tauopathies are common diseases. Their prevalence is rising and may double within the next 20 years (Tysnes and Storstein, 2017; Collaborators, 2019). Although the main damage underlying neurodegenerative disorders is in the brain, their onset and course is substantially affected by lifestyle, genetic predisposition, and somatic pathologies including infections associated with systemic inflammation (Holmes, 2013; Lim et al., 2015; Giridharan et al., 2019; Walker et al., 2019). Therefore, the hypothesis that COVID-19 infection can be a trigger or modifying factor of neurodegenerative diseases has been proposed (Verkhratsky et al., 2020). Age is the major risk factor for neurodegenerative diseases (Hou et al., 2019) and a strong predictor of severe clinical picture with prolonged course of COVID-19 (Koff and Williams, 2020). Among the neurologic and psychiatric complications of COVID-19, symptoms of clinical parkinsonism were reported in few cases, suggesting a potential direct link between SARS-CoV-2 infection and neurodegeneration (Brundin et al., 2020). In two cases, COVID-19 may have been the "second hit" on a genetic risk trait (Cavallieri et al., 2021).

In addition to the above-reported mechanisms of brain damage by SARS-CoV-2, the spike proteins from the wild type (WT) and the South African B.1.351 (SA) variants bind to the monoamine oxidase (MAO) enzymes with an affinity comparable to that for ACE2 (Hok et al., 2022). This binding of the spike protein could change the affinities of MAO_A (serotonin-preferring) and MAO_B (dopamine preferring) enzymes for their neurotransmitter substrates, misbalancing their levels, and suggesting that the interference with the brain MAO catalytic activity is responsible for the increased neurodegenerative illnesses following a COVID-19 infection (Hok et al., 2022).

In PD, another interesting molecular mechanism is under investigation. It is related to the potential interference of α-synuclein with pathologic processes following viral infection. Indeed, α-synuclein plays a dual role in neurodegeneration; this protein forms toxic oligomers and inclusion bodies (Surgucheva et al., 2014a, b) but it also has a protective effect against neurodegeneration by inhibiting pro-inflammatory responses and facilitating immune reactions against infections (Surguchov, 2015; Labrie and Brundin, 2017; Lesteberg and Beckham, 2019).

It is known that the expression of α-synuclein in neurons inhibits viral RNA replication, facilitates immune responses, and prevent neuroinvasion (Beatman et al., 2015; Massey and Beckham, 2016; Stolzenberg et al., 2017). A recent hypothesis proposes that α-synuclein overexpression in people with PD might reduce the consequences of coronavirus infection by inhibiting the spread of the virus from PNS to CNS (Ait Wahmane et al., 2020). However, in animal models, coronavirus infection can induce cytotoxic aggregation of proteins, including α-synuclein (Tulisiak et al., 2019; Pavel et al., 2020). Moreover, dopaminergic neurons have elevated bioenergetic demands due to highly arborized axons and are highly vulnerable to impairment in proteostasis due to the large axon size (Pavel et al., 2020).

Another piece of this complex puzzle is that α-synuclein expression can be induced following viral infection (Whittaker et al., 2020), so increasing the probability of aggregation (Follmer, 2020).

Moreover, a study profiling 65,309 single-nucleus transcriptomes from 30 frontal cortex and choroid plexus samples across 14 control individuals and 8 subjects with COVID-19 without molecular traces of SARS-CoV-2 in the brain, showed broad cellular perturbations in the barrier cells of the choroid plexus, allowing peripheral T cells to infiltrate the brain parenchyma (Yang et al., 2021). An interesting finding is that specific microglia and astrocyte subpopulations associated with COVID-19 were found, and these cells shared features with pathological cell states that have been previously reported in human neurodegenerative disease (Keren-Shaul et al., 2017; Mathys et al., 2019; Sala Frigerio et al., 2019).

Therefore, longitudinal accurate follow-up of people who had COVID-19 seems to be necessary, especially using registries.

CONCLUSIONS

The occurrence of various neurologic symptoms and manifestations in people affected by coronavirus is not rare. The involvement of both central and peripheral nervous system can have several pathogenetic pathways, including direct viral lesion, endothelial dysfunction, thrombotic microangiopathy, hypoxia, systemic inflammation, and autoimmune reaction. In SARS-CoV-2 infection, neuroinflammatory changes of the brain and brainstem are the most common autopsy findings. Acute neurologic manifestations are more often present in severe form of COVID-19 and are linked to poor prognosis. Although acute and subacute neurologic signs, symptoms and manifestations linked to SARS-CoV-2 are well identified, much less is known about their long-term effects. Moreover, nothing is known about the possible viral impact within the life course of people who had COVID-19. Since it is likely that SARS-CoV-2 will continue to affect humans for the foreseeable future, our knowledge about this virus will grow and allow us to find answers to the open questions that have been illustrated in this chapter.

References

Abbott CA, Baker E, Sutherland GR et al. (1994). Genomic organization, exact localization, and tissue expression of the human CD26 (dipeptidyl peptidase IV) gene. Immunogenetics 40: 331–338.

Abenza-Abildúa MJ, Ramírez-Prieto MT, Moreno-Zabaleta R et al. (2020). Neurological complications in critical patients with COVID-19. Neurologia (Engl Ed) 35: 621–627.

Abenza Abildúa MJ, Atienza S, Carvalho Monteiro G et al. (2021). Encephalopathy and encephalitis during acute SARS-CoV-2 infection. Spanish Society of Neurology COVID-19 Registry. Neurologia (Engl Ed) 36: 127–134.

Agarwal P, Ray S, Madan A et al. (2021). Neurological manifestations in 404 COVID-19 patients in Washington State. J Neurol 268: 770–772.

Agyeman AA, Chin KL, Landersdorfer CB et al. (2020). Smell and taste dysfunction in patients with COVID-19: a systematic review and meta-analysis. Mayo Clin Proc 95: 1621–1631.

Ait Wahmane S, Achbani A, Ouhaz Z et al. (2020). The possible protective role of α-synuclein against the SARS-CoV-2 infections in patients with Parkinson's disease. Mov Disord 35: 1293–1294.

Al Saiegh F, Ghosh R, Leibold A et al. (2020). Status of SARS-CoV-2 in cerebrospinal fluid of patients with COVID-19 and stroke. J Neurol Neurosurg Psychiatry 91: 846–848.

Algahtani H, Subahi A, Shirah B (2016). Neurological complications of middle east respiratory syndrome coronavirus: a report of two cases and review of the literature. Case Rep Neurol Med 2016: 3502683.

Al-Hameed FM (2017). Spontaneous intracranial hemorrhage in a patient with Middle East respiratory syndrome corona virus. Saudi Med J 38: 196–200.

Al-Hashel JY, Abokalawa F, Alenzi M et al. (2021). Coronavirus disease-19 and headache; impact on pre-existing and characteristics of de novo: a cross-sectional study. J Headache Pain 22: 97.

Allali G, Marti C, Grosgurin O et al. (2020). Dyspnea: the vanished warning symptom of COVID-19 pneumonia. J Med Virol 92: 2272–2273.

Andalib S, Biller J, Di Napoli M et al. (2021). Peripheral nervous system manifestations associated with COVID-19. Curr Neurol Neurosci Rep 21: 9.

Arabi YM, Harthi A, Hussein J et al. (2015). Severe neurologic syndrome associated with Middle East respiratory syndrome corona virus (MERS-CoV). Infection 43: 495–501.

Arbour N, Côté G, Lachance C et al. (1999). Acute and persistent infection of human neural cell lines by human coronavirus OC43. J Virol 73: 3338–3350.

Arbour N, Day R, Newcombe J et al. (2000). Neuroinvasion by human respiratory coronaviruses. J Virol 74: 8913–8921.

Artemiadis A, Liampas A, Hadjigeorgiou L et al. (2021). Myelopathy associated with SARS-COV-2 infection. A systematic review. Neurol Res 43: 633–641.

Asadi-Pooya AA, Simani L, Shahisavandi M et al. (2021). COVID-19, de novo seizures, and epilepsy: a systematic review. Neurol Sci 42: 415–431.

Aschman T, Schneider J, Greuel S et al. (2021). Association between SARS-CoV-2 infection and immune-mediated myopathy in patients who have died. JAMA Neurol 78: 948–960.

Ayoubkhani D, Khunti K, Nafilyan V et al. (2021). Post-covid syndrome in individuals admitted to hospital with covid-19: retrospective cohort study. BMJ 372: n693.

Baig AM, Khaleeq A, Ali U et al. (2020). Evidence of the COVID-19 virus targeting the CNS: tissue distribution, host-virus interaction, and proposed neurotropic mechanisms. ACS Chem Neurosci 11: 995–998.

Balcom EF, Nath A, Power C (2021). Acute and chronic neurological disorders in COVID-19: potential mechanisms of disease. Brain 144: 3576–3588.

Baldini T, Asioli GM, Romoli M et al. (2021). Cerebral venous thrombosis and severe acute respiratory syndrome coronavirus-2 infection: a systematic review and meta-analysis. Eur J Neurol 28: 3478–3490.

Beatman EL, Massey A, Shives KD et al. (2015). Alpha-synuclein expression restricts RNA viral infections in the brain. J Virol 90: 2767–2782.

Benameur K, Agarwal A, Auld SC et al. (2020). Encephalopathy and encephalitis associated with cerebrospinal fluid cytokine alterations and coronavirus disease, Atlanta, Georgia, USA, 2020. Emerg Infect Dis 26: 10.

Bhat S, Chokroverty S (2021). Sleep disorders and COVID-19. Sleep Med S1389-9457(21)00403-2.

Bocci T, Bulfamante G, Campiglio L et al. (2021). Brainstem clinical and neurophysiological involvement in COVID-19. J Neurol 268: 3598–3600.

Bodro M, Compta Y, Sánchez-Valle R (2020). Presentations and mechanisms of CNS disorders related to COVID-19. Neurol Neuroimmunol Neuroinflamm 8: e923.

Boesl F, Audebert H, Endres M et al. (2021). A neurological outpatient clinic for patients with post-COVID-19 syndrome—a report on the clinical presentations of the first 100 patients. Front Neurol 12: 738405.

Bohmwald K, Gálvez NMS, Ríos M et al. (2018). Neurologic alterations due to respiratory virus infections. Front Cell Neurosci 12: 386.

Boing S, Randerath WJ (2015). Chronic hypoventilation syndromes and sleep-related hypoventilation. J Thorac Dis 7: 1273–1285.

Bouali-Benazzouz R, Benazzouz A (2021). Covid-19 infection and Parkinsonism: is there a link? Mov Disord 36: 1737–1743.

Brann DH, Tsukahara T, Weinreb C et al. (2020). Non-neuronal expression of SARS-CoV-2 entry genes in the olfactory system suggests mechanisms underlying COVID-19-associated anosmia. Sci Adv 6: eabc5801.

Brundin P, Nath A, Beckham JD (2020). Is COVID-19 a perfect storm for Parkinson's disease? Trends Neurosci 43: 931–933.

Burki NK, Lee LY (2010). Mechanisms of dyspnea. Chest 138: 1196–1201.

Butowt R, Bilinska K (2020). SARS-CoV-2: olfaction, brain infection, and the urgent need for clinical samples allowing earlier virus detection. ACS Chem Neurosci 11: 1200–1203.

Caronna E, Pozo-Rosich P (2021). Headache as a symptom of COVID-19: narrative review of 1-year research. Curr Pain Headache Rep 25: 73.

Casez O, Willaume G, Grand S et al. (2021). Teaching neuroimages: SARS-CoV-2-related encephalitis: MRI pattern of olfactory tract involvement. Neurology 96: e645–e646.

Cavallieri F, Marti A, Fasano A et al. (2020). Prothrombotic state induced by COVID-19 infection as trigger for stroke in young patients: a dangerous association. eNeurologicalSci 20: 100247.

Cavallieri F, Fioravanti V, Toschi G et al. (2021). COVID-19 and Parkinson's disease: a casual association or a possible second hit in neurodegeneration? J Neurol 3: 1–3.

Cevik M, Kuppalli K, Kindrachuk J et al. (2020). Virology, transmission, and pathogenesis of SARS-CoV-2. BMJ 371: m3862.

Chakraborty T, Kramer CL, Wijdicks EFM et al. (2020). Dysautonomia in Guillain-Barre syndrome: prevalence, clinical spectrum, and outcomes. Neurocrit Care 32: 113–120.

Champredon D, Bancej C, Lee L et al. (2021). Implications of the unexpected persistence of human rhinovirus/enterovirus during the COVID-19 pandemic in Canada. Influenza Other Respir Viruses 7. https://doi.org/10.1111/irv.12930.

Chan JF, Chan KH, Choi GK et al. (2013). Differential cell line susceptibility to the emerging novel human betacoronavirus 2c EMC/2012: implications for disease pathogenesis and clinical manifestation. J Infect Dis 207: 1743–1752.

Charlton CL, Babady E, Ginocchio CC et al. (2018). Practical guidance for clinical microbiology laboratories: viruses causing acute respiratory tract infections. Clin Microbiol Rev 32: e00042-18.

Chen Y, Chen L, Deng Q et al. (2020). The presence of SARS-CoV-2 RNA in the feces of COVID-19 patients. J Med Virol 92: 833–840.

Chen R, Wang K, Yu J et al. (2021). The spatial and cell-type distribution of SARS-CoV-2 receptor ACE2 in the human and mouse brains. Front Neurol 11: 573095.

Chou SH, Beghi E, Helbok R et al. (2021). Global incidence of neurological manifestations among patients hospitalized with COVID-19. A report from the GCS-NeuroCOVID Consortium and the ENERGY Consortium. JAMA Netw Open 4: e2112131.

Clementi N, Ghosh S, Santis MD et al. (2021). Viral respiratory pathogens and lung injury. Clin Microbiol Rev 34: e00103–e00120.

Codeluppi L, Venturelli F, Rossi J et al. (2020). Facial palsy during the COVID-19 pandemic. Brain Behav 11: e01939.

Collaborators GD (2019). Global, regional, and national burden of Alzheimer's disease and other dementias, 1990–2016: a systematic analysis for the global burden of disease study 2016. Lancet Neurol 18: 88–106.

Connors TJ, Ravindranath TM, Bickham KL et al. (2016). Airway CD8(+) T cells are associated with lung injury during infant viral respiratory tract infection. Am J Respir Cell Mol Biol 54: 822–830.

Cosentino G, Todisco M, Hota N et al. (2021). Neuropathological findings from COVID-19 patients with neurological symptoms argue against a direct brain invasion of SARS-CoV-2: a critical systematic review. Eur J Neurol 28: 3856–3865.

Couzin-Frankel J (2020). The mystery of the pandemic's 'happy hypoxia'. Science 368: 455–456.

Dakhama A, Lee YM, Gelfand EW (2005). Virus-induced airway dysfunction: pathogenesis and biomechanisms. Pediatr Infect Dis J 24: S159–S169; discussion S66-67.

Dantzer R (2018). Neuroimmune interactions: from the brain to the immune system and vice versa. Physiol Rev 98: 477–504.

Datta SD, Talwar A, Lee JT (2020). A proposed framework and timeline of the spectrum of disease due to SARS-CoV-2 infection: illness beyond acute infection and public Health implications. JAMA 324: 2251–2252.

Davis LE, Koster F, Cawthon A (2014). Neurologic aspects of influenza viruses. Handb Clin Neurol 123: 619–645.

De Sanctis P, Doneddu PE, Viganò L et al. (2020). Guillain-Barré syndrome associated with SARS-CoV-2 infection. A systematic review. Eur J Neurol 27: 2361–2370.

Del Negro CA, Funk GD, Feldman JL (2018). Breathing matters. Nat Rev Neurosci 19: 351–367.

Demartini Z, Maranha Gatto LA, Koppe GL et al. (2020). Ondine's curse: myth meets reality. Sleep Med X 2: 100012.

Desforges M, Favreau DJ, Brison E et al. (2013). Human coronaviruses. Respiratory pathogens revisited as infectious neuroinvasive, neurotropic, and neurovirulent agents. In: SK Singh, D Ruzek (Eds.), Neuroviral infections. RNA viruses and retroviruses. CRC Press/Taylor and Francis, Boca Raton, pp. 93–121.

Desforges M, Le Coupanec A, Brison E et al. (2014). Neuroinvasive and neurotropic human respiratory coronaviruses: potential neurovirulent agents in humans. Adv Exp Med Biol 807: 75–96.

Desforges M, Le Coupanec A, Dubeau P et al. (2019). Human coronaviruses and other respiratory viruses: underestimated opportunistic pathogens of the central nervous system? Viruses 12: 14.

Ding Y, He L, Zhang Q et al. (2004). Organ distribution of severe acute respiratory syndrome (SARS) associated coronavirus (SARS-CoV) in SARS patients: implications for pathogenesis and virus transmission pathways. J Pathol 203: 622–630.

Doo FX, Kassim G, Lefton DR et al. (2021). Rare presentations of COVID-19: PRES-like leukoencephalopathy and carotid thrombosis. Clin Imaging 69: 94–101.

Dubé M, Le Coupanec A, Wong AHM et al. (2018). Axonal transport enables neuron-to-neuron propagation of human coronavirus OC43. J Virol 92: e00404–e00418.

Edén A, Kanberg N, Gostner J et al. (2021). CSF biomarkers in patients with COVID-19 and neurologic symptoms: a case series. Neurology 96: e294–e300.

Eliezer M, Hamel AL, Houdart E et al. (2020). Loss of smell in patients with COVID-19: MRI data reveal a transient edema of the olfactory clefts. Neurology 95: e3145–e3152.

Elkady A, Rabinstein AA (2020). Acute necrotizing encephalopathy and myocarditis in a young patient with COVID-19. Neurol Neuroimmunol Neuroinflamm 7: e801.

Ellul MA, Benjamin L, Singh B et al. (2020). Neurological associations of COVID-19. Lancet Neurol 19: 767–783.

Ely EW, Shintani A, Truman B et al. (2004). Delirium as a predictor of mortality in mechanically ventilated patients in the intensive care unit. JAMA 291: 1753–1762.

Emami A, Fadakar N, Akbari A et al. (2020). Seizure in patients with COVID-19. Neurol Sci 41: 3057–3061.

Espíndola OM, Gomes YCP, Brandão CO et al. (2021). Inflammatory cytokine patterns associated with neurological diseases in coronavirus disease 2019. Ann Neurol 89: 1041–1045.

Fasano A, Cavallieri F, Canali E et al. (2020). First motor seizure as presenting symptom of SARS-CoV-2 infection. Neurol Sci 41: 1651–1653.

Feige J, Moser T, Hauer L et al. (2020). Clinical challenges in a 49-year-old patient with severe tick-borne myeloradiculitis despite complete active vaccination. Vaccines (Basel) 8: 93.

Fernández-de-Las-Peñas C, Rodríguez-Jiménez J, Fuensalida-Novo S et al. (2021). Myalgia as a symptom at hospital admission by severe acute respiratory syndrome coronavirus 2 infection is associated with persistent musculoskeletal pain as long-term post-COVID sequelae: a case-control study. Pain 162: 2832–2840.

Filosto M, Cotti Piccinelli S, Gazzina S et al. (2021). Guillain-Barré syndrome and COVID-19: an observational multicentre study from two Italian hotspot regions. J Neurol Neurosurg Psychiatry 92: 751–756.

Flerlage T, Boyd DF, Meliopoulos V et al. (2021). Influenza virus and SARS-CoV-2: pathogenesis and host responses in the respiratory tract. Nat Rev Microbiol 19: 425–441.

Follmer C (2020). Gut microbiome imbalance and neuroinflammation: impact of COVID-19 on Parkinson's disease. Mov Disord 35: 1495–1496.

Fragkou PC, Moschopoulos CD, Karofylakis E et al. (2021). Update in viral infections in the intensive care unit. Front Med (Lausanne) 8: 575580.

Fraiman P, Godeiro Junior C, Moro E et al. (2020). COVID-19 and cerebrovascular diseases: a systematic review and perspectives for stroke management. Front Neurol 11: 574694.

Frontera JA, Sabadia S, Lalchan R et al. (2021). A prospective study of neurologic disorders in hospitalized patients with COVID-19 in New York City. Neurology 96: e575–e586.

Galougahi MK, Yousefi-Koma A, Bakhshayesshkaram M et al. (2020). 18 FDG PET/CT scan reveals hypoactive orbitofrontal cortex in anosmia of COVID-19. Acad Radiol 27: 1042–1043.

García-Azorín D, Sierra Á, Trigo J et al. (2021). Frequency and phenotype of headache in covid-19: a study of 2194 patients. Sci Rep 11: 14674.

Giangaspero F, Schiavina M, Sturani C et al. (1988). Failure of automatic control of ventilation (Ondine's curse) associated with viral encephalitis of the brainstem: a clinicopathologic study of one case. Clin Neuropathol 7: 234–247.

Giridharan VV, Masud F, Petronilho F et al. (2019). Infection-induced systemic inflammation is a potential driver of Alzheimer's disease progression. Front Aging Neurosci 11: 122.

Global Burden of Disease Study C (2015). Global, regional, and national incidence, prevalence, and years lived with disability for 301 acute and chronic diseases and injuries in 188 countries, 1990-2013: a systematic analysis for the Global Burden of Disease Study 2013. Lancet 386: 743–800.

Gomez-Escobar LG, Hoffman KL, Choi JJ et al. (2021). Cytokine signatures of end organ injury in COVID-19. Sci Rep 11: 12606.

Gonzalez-Martinez A, Fanjul V, Ramos C et al. (2021). Headache during SARS-CoV-2 infection as an early symptom associated with a more benign course of disease: a case-control study. Eur J Neurol 28: 3426–3436.

Gorski SA, Hufford MM, Braciale TJ (2012). Recent insights into pulmonary repair following virus-induced inflammation of the respiratory tract. Curr Opin Virol 2: 233–241.

Graf J, Hartmann CJ, Lehmann HC et al. (2019). Meningitis gone viral: description of the echovirus wave 2013 in Germany. BMC Infect Dis 19: 1010.

Graham EL, Clark JR, Orban ZS et al. (2021). Persistent neurologic symptoms and cognitive dysfunction in non-hospitalized Covid-19 "long haulers". Ann Clin Transl Neurol 8: 1073–1085.

Gu J, Gong E, Zhang B et al. (2005). Multiple organ infection and the pathogenesis of SARS. J Exp Med 202: 415–424.

Guilmot A, Maldonado Slootjes S, Sellimi A et al. (2020). Immune-mediated neurological syndromes in SARS-CoV-2-infected patients. J Neurol 268: 751–757.

Guo L, Jin Z, Gan TJ et al. (2021). Silent hypoxemia in patients with COVID-19 pneumonia: a review. Med Sci Monit 27: e930776.

Gupta S, Jawanda MK, Taneja N et al. (2021). A systematic review of Bell's Palsy as the only major neurological manifestation in COVID-19 patients. J Clin Neurosci 90: 284–292.

Haga S, Yamamoto N, Nakai-Murakami C et al. (2008). Modulation of TNF-alpha-converting enzyme by the spike protein of SARS-CoV and ACE2 induces TNF-alpha production and facilitates viral entry. Proc Natl Acad Sci U S A 105: 7809–7814.

Hamming I, Timens W, Bulthuis ML et al. (2004). Tissue distribution of ACE2 protein, the functional receptor for SARS coronavirus. A first step in understanding SARS pathogenesis. J Pathol 203: 631–637.

Han J, Shi LX, Xie Y et al. (2020). Analysis of factors affecting the prognosis of COVID-19 patients and viral shedding duration. Epidemiol Infect 148: e125.

Hassid VJ, Schinco MA, Tepas JJ et al. (2008). Definitive establishment of airway control is critical for optimal outcome in lower cervical spinal cord injury. J Trauma 65: 1328–1332.

Hernández-Fernández F, Sandoval Valencia H, Barbella-Aponte RA et al. (2020). Cerebrovascular disease in patients with COVID-19: neuroimaging, histological and clinical description. Brain 143: 3089–3103.

Hoffmann M, Kleine-Weber H, Schroeder S et al. (2020). SARS-CoV-2 cell entry depends on ACE2 and TMPRSS2 and is blocked by a clinically proven protease inhibitor. Cell 181: 271–280.e8.

Hok L, Rimac H, Mavri J et al. (2022). COVID-19 infection and neurodegeneration: computational evidence for interactions between the SARS-CoV-2 spike protein and monoamine oxidase enzymes, Comput Struct Biotechnol J 20: 1254–1263.

Holmes C (2013). Review: systemic inflammation and Alzheimer's disease. Neuropathol Appl Neurobiol 39: 51–68.

Hou Y, Dan X, Babbar M et al. (2019). Ageing as a risk factor for neurodegenerative disease. Nat Rev Neurol 15: 565–581.

Hu J, Jolkkonen J, Zhao C (2020). Neurotropism of SARS-CoV-2 and its neuropathological alterations: similarities with other coronaviruses. Neurosci Biobehav Rev 119: 184–193.

Huang HY, Shah LM, McNally JS et al. (2021a). COVID-19-associated myelitis involving the dorsal and lateral white matter tracts: a case series and review of the literature. AJNR Am J Neuroradiol 42: 1912–1917a.

Huang C, Huang L, Wang Y et al. (2021b). 6-month consequences of COVID-19 in patients discharged from hospital: a cohort study. Lancet 397: 220–232.

Hulswit RJG, Lang Y, Bakkers MJG et al. (2019). Human coronaviruses OC43 and HKU1 bind to 9-O-acetylated sialic acids via a conserved receptor-binding site in spike protein domain A. Proc Natl Acad Sci U S A 116: 2681–2690.

Hung EC, Chim SS, Chan PK et al. (2003). Detection of SARS coronavirus RNA in the cerebrospinal fluid of a patient with severe acute respiratory syndrome. Clin Chem 49: 2108–2109.

Hwang ST, Ballout AA, Sonti AN et al. (2021). EEG abnormalities and their radiographic correlates in a COVID-19 inpatient cohort. Neurol Clin Pract. https://doi.org/10.1212/CPJ.0000000000001136.

Iadecola C, Anrather J, Kamel H (2020). Effects of COVID-19 on the nervous system. Cell 183: 16–27.e1.

Ide W, Melicosta M, Trovato MK (2021). Acute flaccid myelitis. Phys Med Rehabil Clin N Am 32: 477–491.

Isada CM, Miller R (2020). Acute infectious myelopathies. Curr Opin Infect Dis 33: 251–258.

Islam MA, Alam SS, Kundu S et al. (2020). Prevalence of headache in patients with coronavirus disease 2019 (COVID-19): a systematic review and meta-analysis of 14,275 patients. Front Neurol 11: 562634.

Jackson CB, Farzan M, Chen B et al. (2022). Mechanisms of SARS-CoV-2 entry into cells. Nat Rev Mol Cell Biol 23: 3–20.

Jacomy H, Talbot PJ (2003). Vacuolating encephalitis in mice infected by human coronavirus OC43. Virology 315: 20–33.

Jain R, Young M, Dogra S et al. (2020). COVID-19 related neuroimaging findings: a signal of thromboembolic complications and a strong prognostic marker of poor patient outcome. J Neurol Sci 414: 116923.

Jalessi M, Barati M, Rohani M et al. (2020). Frequency and outcome of olfactory impairment and sinonasal involvement in hospitalized patients with COVID-19. Neurol Sci 41: 2331–2338.

Jha NK, Ojha S, Jha SK et al. (2021). Evidence of coronavirus (CoV) pathogenesis and emerging pathogen SARS-CoV-2 in the nervous system: a review on neurological impairments and manifestations. J Mol Neurosci 71: 2192–2209.

Johnson D, Lynch R, Marshall C et al. (2013). Aerosol generation by modern flush toilets. Aerosol Sci Technol 47: 1047–1057.

Joob B, Wiwanitkit V (2015). Neurologic syndrome due to MERS: is there a possibility that the virus can cross the blood-brain barrier to cause a neurological problem? Ann Trop Med Publ Health 8: 231.

Kanberg N, Ashton NJ, Andersson LM et al. (2020). Neurochemical evidence of astrocytic and neuronal injury commonly found in COVID-19. Neurology 95: e1754–e1759.

Karimi L, Sales C, Crewther SG et al. (2020). Acute ischemic stroke in SARS-CoV, MERS-CoV, SARS-CoV-2: neurorehabilitation implications of inflammation induced immunological responses affecting vascular systems. Front Neurol 11: 565665.

Keddie S, Pakpoor J, Mousele C et al. (2021). Epidemiological and cohort study finds no association between COVID-19 and Guillain-Barré syndrome. Brain 144: 682–693.

Keller E, Brandi G, Winklhofer S et al. (2020). Large and small cerebral vessel involvement in severe COVID-19: detailed clinical workup of a case series. Stroke 51: 3719–3722.

Keren-Shaul H, Spinrad A, Weiner A et al. (2017). A unique microglia type associated with restricting development of Alzheimer's disease. Cell 169: 1276–1290.

Keyhanian K, Umeton RP, Mohit B et al. (2020). SARS-CoV-2 and nervous system: from pathogenesis to clinical manifestation. J Neuroimmunol 350: 577436.

Kim JE, Heo JH, Kim HO et al. (2017). Neurological complications during treatment of middle east respiratory syndrome. J Clin Neurol 13: 227–233.

Klomp M, Ghosh S, Mohammed S et al. (2021). From virus to inflammation, how influenza promotes lung damage. J Leukoc Biol 110: 115–122.

Koff WC, Williams MA (2020). Covid-19 and immunity in aging populations—a new research agenda. N Engl J Med 383: 804–805.

Koralnik IJ, Tyler KL (2020). COVID-19: a global threat to the nervous system. Ann Neurol 88: 1–11.

Kremer S, Lersy F, Anheim M et al. (2020). Neurologic and neuroimaging findings in patients with COVID-19: a retrospective multicenter study. Neurology 95: e1868–e1882.

Kubota T, Gajera PK, Kuroda N (2021). Meta-analysis of EEG findings in patients with COVID-19. Epilepsy Behav 115: 107682.

Labrie V, Brundin P (2017). Alpha-synuclein to the rescue: immune cell recruitment by alpha-synuclein during gastrointestinal infection. J Innate Immun 9: 437–440.

Larrosa-Barrero R, Matute WIG, Mutiozabal AM et al. (2018). Central alveolar hypoventilation due to progressive multifocal leukoencephalopathy. Pulmonology 24: 54–56.

Lechien JR, Chiesa-Estomba CM, Beckers E et al. (2021). Prevalence and 6-month recovery of olfactory dysfunction: a multicentre study of 1363 COVID-19 patients. J Intern Med 290: 451–461.

Lemprière S (2021). SARS-CoV-2 detected in olfactory neurons. Nat Rev Neurol 17: 63.

Leotard A, Levy J, Hartley S et al. (2020). Sleep disorders in aging polio survivors: a systematic review. Ann Phys Rehabil Med 63: 543–553.

Lerner AM, De Rocco AJ, Yang L et al. (2021). Unraveling the mysteries of acute flaccid myelitis: scientific opportunities and priorities for future research. Clin Infect Dis 72: 2044–2048.

Lersy F, Benotmane I, Helms J et al. (2021). Cerebrospinal fluid features in patients with coronavirus disease 2019 and neurological manifestations: correlation with brain magnetic resonance imaging findings in 58 patients. J Infect Dis 223: 600–609.

Lesteberg KE, Beckham JD (2019). Immunology of west Nile virus infection and the role of alpha-synuclein as a viral restriction factor. Viral Immunol 32: 38–47.

Leung NHL (2021). Transmissibility and transmission of respiratory viruses. Nat Rev Microbiol 19: 528–545.

Leven Y, Bösel J (2021). Neurological manifestations of COVID-19—an approach to categories of pathology. Neurol Res Pract 3: 39.

Lewis A, Frontera J, Placantonakis DG et al. (2021a). Cerebrospinal fluid in COVID-19: a systematic review of the literature. J Neurol Sci 421: 117316.

Lewis A, Frontera J, Placantonakis DG et al. (2021b). Cerebrospinal fluid from COVID-19 patients with olfactory/gustatory dysfunction: A review. Clin Neurol Neurosurg 207: 106760.

Li K, Wohlford-Lenane C, Perlman S et al. (2016). Middle East respiratory syndrome coronavirus causes multiple organ damage and lethal disease in mice transgenic for human dipeptidyl peptidase 4. J Infect Dis 213: 712–722.

Lim SL, Rodriguez-Ortiz CJ, Kitazawa M (2015). Infection, systemic inflammation, and Alzheimer's disease. Microbes Infect 17: 549–556.

Liotta EM, Batra A, Clark JR et al. (2020). Frequent neurologic manifestations and encephalopathy-associated morbidity in Covid-19 patients. Ann Clin Transl Neurol 7: 2221–2230.

Logroscino G, Beghi E (2021). Stroke epidemiology and COVID-19 pandemic. Curr Opin Neurol 34: 3–10.

Lopez-Leon S, Wegman-Ostrosky T, Perelman C et al. (2021). More than 50 long-term effects of COVID-19: a systematic review and meta-analysis. Sci Rep 11: 16144.

Lu Y, Li X, Geng D et al. (2020). Cerebral micro-structural changes in COVID-19 patients—an MRI-based 3-month follow-up study. EClinicalMedicine 25: 100484.

Maas MB (2020). Critical medical illness and the nervous system. Continuum (Minneap Minn) 26: 675–694.

Mackie PL (2003). The classification of viruses infecting the respiratory tract. Paediatr Respir Rev 4: 84–90.

Mahammedi A, Saba L, Vagal A et al. (2020). Imaging in neurological disease of hospitalized COVID-19 patients: an Italian multicenter retrospective observational study. Radiology 297: E270–E273.

Mahmudpour M, Roozbeh J, Keshavarz M et al. (2020). COVID-19 cytokine storm: the anger of inflammation. Cytokine 133: 155151.

Manganelli F, Vargas M, Iovino A et al. (2020). Brainstem involvement and respiratory failure in COVID-19. Neurol Sci 41: 1663–1665.

Mao L, Jin H, Wang M et al. (2020). Neurologic manifestations of hospitalized patients with coronavirus disease 2019 in Wuhan, China. JAMA Neurol 77: 683–690.

Massey AR, Beckham JD (2016). Alpha-synuclein, a novel viral restriction factor hiding in plain sight. DNA Cell Biol 35: 643–645.

Mathys H, Davila-Velderrain J, Peng Z et al. (2019). Single-cell transcriptomic analysis of Alzheimer's disease. Nature 570: 332–337.

Maury A, Lyoubi A, Peiffer-Smadja N et al. (2021). Neurological manifestations associated with SARS-CoV-2 and other coronaviruses: a narrative review for clinicians. Rev Neurol (Paris) 177: 51–64.

Mazzoli M, Molinari MA, Tondelli M et al. (2020). Olfactory function and viral recovery in COVID-19. Brain Behav 11: e02006.

McCray Jr PB, Pewe L, Wohlford-Lenane C et al. (2007). Lethal infection of K18-hACE2 mice infected with severe acute respiratory syndrome coronavirus. J Virol 81: 813–821.

McGonagle D, Sharif K, O'Regan A et al. (2020). The role of cytokines including Interleukin-6 in COVID-19 induced pneumonia and macrophage activation syndrome-like disease. Autoimmun Rev 19: 102537.

Meinhardt J, Radke J, Dittmayer C et al. (2021). Olfactory transmucosal SARS-CoV-2 invasion as a port of central nervous system entry in individuals with COVID-19. Nat Neurosci 24: 168–175.

Meskill SD, O'Bryant SC (2020). Respiratory virus co-infection in acute respiratory infections in children. Curr Infect Dis Rep 22: 3.

Meunier N, Briand L, Jacquin-Piques A et al. (2021). COVID 19-induced smell and taste impairments: putative impact on physiology. Front Physiol 11: 625110.

Miller KD, Schnell MJ, Rall GF (2016). Keeping it in check: chronic viral infection and antiviral immunity in the brain. Nat Rev Neurosci 17: 766–776.

Montalvan V, Lee J, Bueso T et al. (2020). Neurological manifestations of COVID-19 and other coronavirus infections: a systematic review. Clin Neurol Neurosurg 194: 105921.

Mori I, Nishiyama Y, Yokochi T et al. (2005). Olfactory transmission of neurotropic viruses. J Neurovirol 11: 129–137.

Moro E, Priori A, Beghi E et al. (2020). The international European Academy of Neurology survey on neurological symptoms in patients with COVID-19 infection. Eur J Neurol 27: 1727–1737.

Murphy OC, Messacar K, Benson L et al. (2021). Acute flaccid myelitis: cause, diagnosis, and management. Lancet 397: 334–346.

Najjar S, Najjar A, Chong DJ et al. (2020). Central nervous system complications associated with SARS-CoV-2 infection: integrative concepts of pathophysiology and case reports. J Neuroinflammation 17: 231.

Nardone R, Versace V, Brigo F et al. (2017). Herpes simplex virus type 2 myelitis: case report and review of the literature. Front Neurol 8: 199.

National Institute for Health and Care Excellence (2021). COVID-19 rapid guideline: managing the long-term effects of COVID-19. Published: 18 December 2020, Last updated: 11 November. https://www.nice.org.uk/guidance/ng188.

Netland J, Meyerholz DK, Moore S et al. (2008). Severe acute respiratory syndrome coronavirus infection causes neuronal death in the absence of encephalitis in mice transgenic for human ACE2. J Virol 82: 7264–7275.

Newton AH, Cardani A, Braciale TJ (2016). The host immune response in respiratory virus infection: balancing virus clearance and immunopathology. Semin Immunopathol 38: 471–482.

Ning P, Yang B, Yang X et al. (2020). A nomogram to predict mechanical ventilation in Guillain-Barre syndrome patients. Acta Neurol Scand 142: 466–474.

Nogues MA, Benarroch E (2008). Abnormalities of respiratory control and the respiratory motor unit. Neurologist 14: 273–288.

O'Byrne L, Webster KE, MacKeith S et al. (2021). Interventions for the treatment of persistent post-COVID-19 olfactory dysfunction. Cochrane Database Syst Rev 7: CD013876.

Oliveira V, Seabra M, Rodrigues R et al. (2021). Neuro-COVID frequency and short-term outcome in the Northern Portuguese population. Eur J Neurol 28: 3360–3368.

Omrani AS, Al-Tawfiq JA, Memish ZA (2015). Middle East respiratory syndrome coronavirus (MERS-CoV): animal to human interaction. Rev Neurol (Paris) 109: 354–362.

Oxley TJ, Mocco J, Majidi S et al. (2020). Large-vessel stroke as a presenting feature of Covid-19 in the young. N Engl J Med 382: e60.

Palaiodimou L, Stefanou MI, Katsanos AH et al. (2021). Prevalence, clinical characteristics and outcomes of Guillain-Barré syndrome spectrum associated with COVID-19: a systematic review and meta-analysis. Eur J Neurol 28: 3517–3529.

Paniz-Mondolfi A, Bryce C, Grimes Z et al. (2020). Central nervous system involvement by severe acute respiratory syndrome coronavirus-2 (SARS-CoV-2). J Med Virol 92: 699–702.

Pavel A, Murray DK, Stoessl AJ (2020). COVID-19 and selective vulnerability to Parkinson's disease. Lancet Neurol 19: 719.

Pellegrini L, Albecka A, Mallery DL et al. (2020). SARS-CoV-2 infects the brain choroid plexus and disrupts the blood-CSF barrier in human brain organoids. Cell Stem Cell 27: 951–961.e5.

Pilotto A, Odolini S, Stefano Masciocchi S et al. (2020a). Steroid-responsive encephalitis in COVID-19 disease. Ann Neurol 88: 423–427B.

Pilotto A, Padovani A, ENCOVID-BIO Network (2020b). Reply to the letter "COVID-19-associated encephalopathy and cytokine-mediated neuroinflammation". Ann Neurol 88: 861–862a.

Pilotto A, Cristillo V, Cotti Piccinelli S et al. (2021). Long-term neurological manifestations of COVID-19: prevalence and predictive factors. Neurol Sci 42: 4903–4907.

Pizzi MA (2021). Acute neurologic manifestations of respiratory viruses. Continuum (Minneap Minn) 27: 1365–1381.

Politi LS, Salsano E, Grimaldi M (2020). Magnetic resonance imaging alteration of the brain in a patient with coronavirus disease 2019 (COVID-19) and anosmia. JAMA Neurol 77: 1028–1029.

Pugin D, Vargas MI, Thieffry C et al. (2020). COVID-19-related encephalopathy responsive to high doses glucocorticoids. Neurology 95: 543–546.

Rábano-Suárez P, Bermejo-Guerrero L, Méndez-Guerrero A et al. (2020). Generalized myoclonus in COVID-19. Neurology 95: e767–e772.

Radmanesh A, Derman A, Lui YW et al. (2020a). COVID-19—associated diffuse leukoencephalopathy and microhemorrhages. Radiology 297: E223–E227. A.

Radmanesh A, Raz E, Zan E et al. (2020b). Brain imaging use and findings in COVID-19: a single academic center experience in the epicenter of disease in the United States. AJNR Am J Neuroradiol 41: 1179–1183. B.

Raj VS, Mou H, Smits SL et al. (2013). Dipeptidyl peptidase 4 is a functional receptor for the emerging human coronavirus-EMC. Nature 495: 251–254.

Ramani A, Pranty AI, Gopalakrishnan J (2021). Neurotropic effects of SARS-CoV-2 modeled by the human brain organoids. Stem Cell Rep 16: 373–384.

Restivo DA, Centonze D, Alesina A et al. (2020). Myasthenia gravis associated with SARS-CoV-2 infection. Ann Intern Med 173: 1027–1028.

Reza-Zaldívar EE, Hernández-Sapiéns MA, Minjarez B et al. (2021). Infection mechanism of SARS-COV-2 and its implication on the nervous system. Front Immunol 11: 621735.

Roberts TT, Leonard GR, Cepela DJ (2017). Classifications in brief: American Spinal Injury Association (ASIA) impairment scale. Clin Orthop Relat Res 475: 1499–1504.

Rodgers L, Sheppard M, Smith A et al. (2021). Changes in seasonal respiratory illnesses in the United States during the coronavirus disease 2019 (COVID-19) pandemic. Clin Infect Dis 73: S110–S117.

Rogers JP, Watson CJ, Badenoch J et al. (2021). Neurology and neuropsychiatry of COVID-19: a systematic review and meta-analysis of the early literature reveals frequent CNS manifestations and key emerging narratives. J Neurol Neurosurg Psychiatry 92: 932–941.

Romero JR, Modlin JF (2015). Bulbar poliomyelitis. In: JE Bennett, R Dolin, J Martin (Eds.), Mandell, Douglas, and Bennett's principles and practice of infectious diseases, eighth edn. Elsevier, Amsterdam, pp. 2073–2079.e2.

Romero-Sánchez CM, Díaz-Maroto I, Fernández-Díaz E et al. (2020). Neurologic manifestations in hospitalized patients with COVID-19: the ALBACOVID registry. Neurology 95: e1060–e1070.

Romoli M, Jelcic I, Bernard-Valnet R et al. (2020). A systematic review of neurological manifestations of SARS-CoV-2 infection: the devil is hidden in the details. Eur J Neurol 27: 1712–1726.

Saad M, Omrani AS, Baig K et al. (2014). Clinical aspects and outcomes of 70 patients with Middle East respiratory syndrome coronavirus infection: a single-center experience in Saudi Arabia. Int J Infect Dis 29: 301–306.

Saenz Lafourcade C, Pinel González A, Martin ÁG (2021). Disimmune encephalopathy with onconeuronal antibodies in SARS-CoV-2 infected patients. Med Clin (Engl Ed) 157: e357–e358.

Saitta L, Molin A, Villani F et al. (2020). Brain microvascular occlusive disorder in COVID-19: a case report. Neurol Sci 41: 3401–3404.

Sala Frigerio C, Wolfs L, Fattorelli N et al. (2019). The major risk factors for Alzheimer's disease: age, sex, and genes modulate the microglia response to aβ plaques. Cell Rep 27: 1293–1306.e6.

Santos de Lima F, Issa N, Seibert K et al. (2021). Epileptiform activity and seizures in patients with COVID-19. J Neurol Neurosurg Psychiatry 92: 565–566.

Saussez S, Sharma S, Thiriard A et al. (2021). Predictive factors of smell recovery in a clinical series of 288 coronavirus disease 2019 patients with olfactory dysfunction. Eur J Neurol 28: 3702–3711.

Schulte EC, Hauer L, Kunz AB et al. (2021). Systematic review of cases of acute myelitis in individuals with COVID-19. Eur J Neurol 28: 3230–3244.

Sellner J, Steiner I (2014). Neurologic complications of hepatic viruses. Handb Clin Neurol 123: 647–661.

Shahrizaila N, Lehmann HC, Kuwabara S (2021). Guillain-Barre syndrome. Lancet 397: 1214–1228.

Shang P, Zhu M, Baker M et al. (2020). Mechanical ventilation in Guillain-Barre syndrome. Expert Rev Clin Immunol 16: 1053–1064.

Sharifian-Dorche M, Huot P, Osherov M et al. (2020). Neurological complications of coronavirus infection; a comparative review and lessons learned during the COVID-19 pandemic. J Neurol Sci 417: 117085.

Shi Z, De Vries H, Vlaar A et al. (2020). Diaphragm pathology in critically ill patients with COVID-19 and postmortem findings from 3 medical centers. JAMA 181: 122–124.

Shi Z, Bogaards SJP, Conijn S et al. (2021). COVID-19 is associated with distinct myopathic features in the diaphragm of critically ill patients. BMJ Open Respir Res 8: e001052.

Singh B, Lant S, Cividini S et al. (2021). Prognostic indicators and outcomes of hospitalised COVID-19 patients with neurological disease: a systematic review and individual patient data meta-analysis. Lancet Preprint.

Sinha S, Mittal S, Roy R (2021). Parkinson's disease and the COVID-19 pandemic: a review article on the association between SARS-CoV-2 and α-synucleinopathy. J Mov Disord 14: 184–192.

Slooter AJC, Otte WM, Devlin JW et al. (2020). Updated nomenclature of delirium and acute encephalopathy: statement of ten Societies. Intensive Care Med 46: 1020–1022.

Smith JC, Abdala AP, Borgmann A et al. (2013). Brainstem respiratory networks: building blocks and microcircuits. Trends Neurosci 36: 152–162.

Solomon T (2021). Neurological infection with SARS-CoV-2—the story so far. Nat Rev Neurol 17: 65–66.

Song E, Zhang C, Israelow B, et al.A. (2021). Neuroinvasion of SARS-CoV-2 in human and mouse brain. J Exp Med 218: e20202135.

Stolzenberg E, Berry D, Yang D et al. (2017). A role for neuronal alpha-synuclein in gastrointestinal immunity. J Innate Immun 9: 56–463.

Straburzyński M, Nowaczewska M, Budrewicz S et al. (2021). COVID-19-related headache and sinonasal inflammation: a longitudinal study analysing the role of acute rhinosinusitis and ICHD-3 classification difficulties in SARS-CoV-2 infection. Cephalalgia 20: 3331024211 040753.

Suh J, Mukerji SS, Collens SI et al. (2021). Skeletal muscle and peripheral nerve histopathology in COVID-19. Neurology 97: e849–e858.

Surgucheva I, He S, Sharma R et al. (2014a). Role of synucleins in traumatic brain injury an experimental in vitro and in vivo study. Mol Cell Neurosci 63: 114–123. B.

Surgucheva I, Newell KL, Burns J et al. (2014b). New α- and g-synuclein immunopathological lesions in human brain. Acta Neuropathologica Commun 2: 132. A.

Surguchov A (2015). Intracellular dynamics of synucleins: here, there and everywhere. Int Rev Cell Mol Biol 320: 103–169.

Tan BH, Liu JM, Gui Y et al. (2021). Neurological involvement in the respiratory manifestations of COVID-19 patients. Aging (Albany NY) 13: 4713–4730.

Tang N, Li D, Wang X et al. (2020). Abnormal coagulation parameters are associated with poor prognosis in patients with novel coronavirus pneumonia. J Thromb Haemost 18: 844–847.

Thepmankorn P, Bach J, Lasfar A et al. (2021). Cytokine storm induced by SARS-CoV-2 infection: the spectrum of its neurological manifestations. Cytokine 138: 155404.

Tirupathi S, Webb DW, Phelan E et al. (2008). Central hypoventilation syndrome after Haemophilus influenzae type b meningitis and herpes infection. Pediatr Neurol 39: 358–360.

Tiwari SK, Wang S, Smith D et al. (2021). Revealing tissue-specific SARS-CoV-2 infection and host responses using human stem cell-derived lung and cerebral organoids. Stem Cell Rep 16: 437–445.

Tong JY, Wong A, Zhu D et al. (2020). The prevalence of olfactory and gustatory dysfunction in COVID-19 patients: a systematic review and meta-analysis. Otolaryngol Head Neck Surg 163: 3–11.

Tsai LK, Hsieh ST, Chao CC et al. (2004). Neuromuscular disorders in severe acute respiratory syndrome. Arch Neurol 61: 1669–1673.

Tseng CT, Huang C, Newman P et al. (2007). Severe acute respiratory syndrome coronavirus infection of mice transgenic for the human Angiotensin-converting enzyme 2 virus receptor. J Virol 81: 1162–1173.

Tulisiak CT, Mercado G, Peelaerts W et al. (2019). Can infections trigger alpha-synucleinopathies? Prog Mol Biol Transl Sci 168: 299–322.

Tysnes OB, Storstein A (2017). Epidemiology of Parkinson's disease. J Neural Transm (Vienna) 124: 901–905.

Uginet M, Breville G, Assal F et al. (2021). COVID-19 encephalopathy: clinical and neurobiological features. J Med Virol 93: 4374–4381.

Vaira LA, Hopkins C, Petrocelli M et al. (2021). Efficacy of corticosteroid therapy in the treatment of long-lasting olfactory disorders in COVID-19 patients. Rhinology 59: 21–25.

Valdebenito S, Bessis S, Annane D et al. (2021). COVID-19 lung pathogenesis in SARS-CoV-2 autopsy cases. Front Immunol 12: 735922.

Varga Z, Flammer AJ, Steiger P et al. (2020). Endothelial cell infection and endotheliitis in COVID-19. Lancet 395: 1417–1418.

Verkhratsky A, Li Q, Melino S et al. (2020). Can COVID-19 pandemic boost the epidemic of neurodegenerative diseases? Biol Direct 15: 28.

Verstrepen K, Baisier L, Cauwer D et al. (2020). Neurological manifestations of COVID-19, SARS and MERS. Acta Neurol Belg 120: 1051–1060.

Vespignani H, Colas D, Lavin BS et al. (2020). Report of EEG finding on critically ill patients with COVID-19. Ann Neurol 88: 626–630.

Vijayanand P, Wilkins E, Woodhead M (2004). Severe acute respiratory syndrome (SARS): a review. Clin Med (Lond) 4: 152–160.

Vohora D, Jain S, Tripathi M et al. (2020). COVID-19 and seizures: is there a link? Epilepsia 61: 1840–1853.

Wakerley BR, Yuki N (2013). Infectious and noninfectious triggers in Guillain-Barre syndrome. Expert Rev Clin Immunol 9: 627–639.

Walker KA, Ficek BN, Westbrook R (2019). Understanding the role of systemic inflammation in Alzheimer's disease. ACS Chem Neurosci 10: 3340–3342.

Wang CC, Prather KA, Sznitman J et al. (2021). Airborne transmission of respiratory viruses. Science 373: eabd9149.

Wen P, Wang L, Liu H et al. (2021). Risk factors for the severity of Guillain-Barre syndrome and predictors of short-term prognosis of severe Guillain-Barre syndrome. Sci Rep 11: 11578.

Whittaker A, Anson M, Harky A (2020). Neurological manifestations of COVID-19: a systematic review and current update. Acta Neurol Scand 142: 14–22.

WHO (2020a). Director-general's opening remarks at the media briefing on COVID-19—11 March 2020. https://www.who.int/director-general/speeches/detail/who-director-general-s-opening-remarks-at-the-mediabriefing-on-covid-19%2D%2D-11-march-2020.

WHO (October 2021). MERS situation update. http://www.emro.who.int/health-topics/mers-cov/mers-outbreaks.html.

Williams A, Branscome H, Khatkar P et al. (2021a). A comprehensive review of COVID-19 biology, diagnostics, therapeutics, and disease impacting the central nervous system. J Neurovirol 27: 667–690.

Williams S, Wynford-Thomas R, Robertson NP (2021b). Long-COVID: neurological manifestations and management. J Neurol 268: 4915–4917.

Wu Y, Xu X, Chen Z et al. (2020). Nervous system involvement after infection with COVID-19 and other coronaviruses. Brain Behav Immun 87: 18–22.

Xu J, Zhong S, Liu J et al. (2005). Detection of severe acute respiratory syndrome coronavirus in the brain: potential role of the chemokine mig in pathogenesis. Clin Infect Dis 41: 1089–1096.

Yan Z, Yang M, Lai CL (2021). Long COVID-19 syndrome: a comprehensive review of its effect on various organ systems and recommendation on rehabilitation plans. Biomedicine 9: 966.

Yang L, Han Y, Nilsson-Payant BE et al. (2020). A human pluripotent stem cell-based platform to study SARS-CoV-2 tropism and model virus infection in human cells and organoids. Cell Stem Cell 27: 125–136.e7.

Yang AC, Kern F, Losada PM et al. (2021). Dysregulation of brain and choroid plexus cell types in severe COVID-19. Nature 595: 565–571. https://doi.org/10.1038/s41586-021-03710-0.

Yong SJ (2021). Long COVID or post-COVID-19 syndrome: putative pathophysiology, risk factors, and treatments. Infect Dis (Lond) 53: 737–754.

Zhang L, Zhou L, Bao L et al. (2021). SARS-CoV-2 crosses the blood-brain barrier accompanied with basement membrane disruption without tight junctions alteration. Signal Transduct Target Ther 6: 337.

Zubair AS, McAlpine LS, Gardin T et al. (2020). Neuropathogenesis and neurologic manifestations of the coronaviruses in the age of coronavirus disease 2019: a review. JAMA Neurol 77: 1018–1027.