Since January 2020 Elsevier has created a COVID-19 resource centre with free information in English and Mandarin on the novel coronavirus COVID-19. The COVID-19 resource centre is hosted on Elsevier Connect, the company's public news and information website.

Elsevier hereby grants permission to make all its COVID-19-related research that is available on the COVID-19 resource centre - including this research content - immediately available in PubMed Central and other publicly funded repositories, such as the WHO COVID database with rights for unrestricted research re-use and analyses in any form or by any means with acknowledgement of the original source. These permissions are granted for free by Elsevier for as long as the COVID-19 resource centre remains active.

Journal of Cardiology Cases xxx (xxxx) xxx

Contents lists available at ScienceDirect

Journal of Cardiology Cases

journal homepage: www.elsevier.com/locate/jccase

Case Report

An autopsy case report of fulminant myocarditis: Following mRNA COVID-19 vaccination

Naoki Hoshino (MD) [a], Masanobu Yanase (MD, PhD) [a,*], Taisuke Ichiyasu (MD) [b], Kazuhiko Kuwahara (MD, PhD) [b], Hideki Kawai (MD, PhD) [a], Takashi Muramatsu (MD, PhD) [a], Hideki Ishii (MD, PhD, FJCC) [c,d], Tetsuya Tsukamoto (MD, PhD) [b], Shin-ichiro Morimoto (MD, PhD, FJCC) [a], Hideo Izawa (MD, PhD, FJCC) [a]

[a] Department of Cardiology, Fujita Health University School of Medicine, Toyoake, Japan
[b] Department of Diagnostic Pathology, Fujita Health University School of Medicine, Toyoake, Japan
[c] Department of Cardiology, Fujita Health University Bantane Hospital, Nagoya, Japan
[d] Department of Cardiovascular Medicine, Gunma University Graduate School of Medicine, Japan

ARTICLE INFO

Article history:
Received 28 January 2022
Received in revised form 12 June 2022
Accepted 20 June 2022
Available online xxxx

Keywords:
Autopsy
Coronavirus disease 2019
Myocarditis
mRNA
Vaccination
Eosinophilic myocarditis

ABSTRACT

There have been few case reports on fatal outcomes in patients with acute myocarditis after mRNA coronavirus disease 2019 (COVID-19) vaccination. In most cases of myocarditis after mRNA COVID-19 vaccination, the myocarditis is mild, and the prognosis is good. Here we report an autopsy case of fulminant myocarditis following mRNA COVID-19 vaccination.

Learning objective: The global distribution of the mRNA coronavirus disease 2019 vaccine requires consideration of appropriate treatment for postvaccination myocarditis. Eosinophil-mediated immunological injury to cardiomyocytes can be involved in the cause of fulminant inflammation from the pathological findings of postvaccination myocarditis.

© 2022 Japanese College of Cardiology. Published by Elsevier Ltd. All rights reserved. This is an open access article under the CC BY-NC-ND license (http://creativecommons.org/licenses/by-nc-nd/4.0/).

Introduction

The first mRNA vaccine for humans against the coronavirus disease 2019 (COVID-19) pandemic has been developed and is being used worldwide; however, postvaccination myocarditis has also been reported. Most reported cases of post-mRNA vaccination myocarditis are considered non-life-threatening [1,2]. However, there have been case reports of fatal fulminant myocarditis [3]. Moreover, there are extremely few autopsy cases of myocarditis after mRNA vaccination [3].

Case report

A 27-year-old man was transferred to the emergency room in cardiopulmonary arrest. The patient had just received the first dose of the mRNA-1273 severe acute respiratory syndrome coronavirus 2 (SARS-CoV-2) vaccine (Moderna, Cambridge, MA, USA) 8 days earlier and had no symptoms such as chest pain suspected of myocarditis or general fatigue suspected of low cardiac output after the vaccination until the emergency room visit. He was a professional athlete; his teammates called for an ambulance when he was found sitting unconscious during practice. Upon arrival at the emergency room, he presented asystole. Despite cardiopulmonary resuscitation, fatal ventricular arrhythmias (Fig. 1A) repeated, and he eventually received venoarterial extracorporeal membrane oxygenation (VA-ECMO) and Impella CP (Abiomed, Danvers, MA, USA), after 2 h of his visit. A chest radiograph obtained in an emergency room showed an enlarged heart and pulmonary congestion (Fig. 1E). The patient had undergone right elbow medial collateral ligament reconstruction 3 months before the recent hospitalization. An electrocardiogram (ECG) abnormality and mild cardiac shadow enlargement in chest radiograph had been noted preoperatively (Fig. 1B, D); however, since he was asymptomatic, no further examination was performed. Additionally, he had no family history of cardiovascular disease or sudden death.

On admission to the coronary care unit, blood pressure was 81/45 mmHg, pulse rate was 73/min, and the temperature was 37.2 °C with

* Corresponding author at: 1-98 Dengaku, Kutsukake, Toyoake 470-1192, Japan.
E-mail address: masanobu.yanase@fujita-hu.ac.jp (M. Yanase).

https://doi.org/10.1016/j.jccase.2022.06.006
1878-5409/© 2022 Japanese College of Cardiology. Published by Elsevier Ltd. All rights reserved. This is an open access article under the CC BY-NC-ND license (http://creativecommons.org/licenses/by-nc-nd/4.0/).

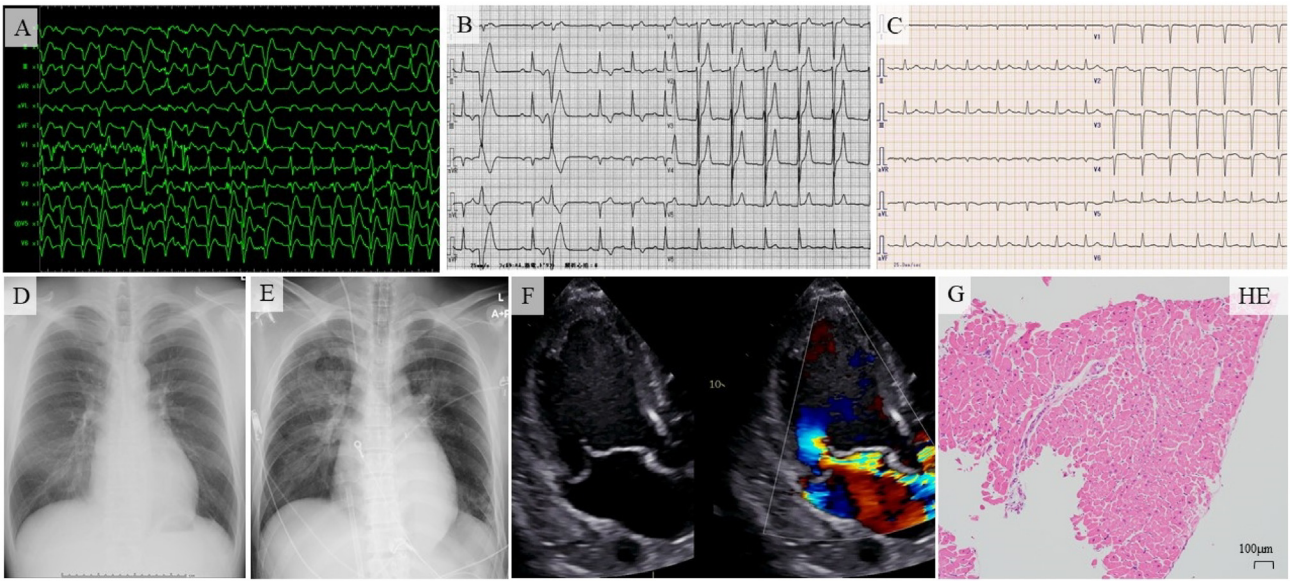

Fig. 1. Fatal ventricular arrhythmia at the time of arrival at the hospital (A), comparison of electrocardiographic findings (B, C) and chest radiograph findings (D, E) at 3 months before admission and upon admission, transthoracic echocardiography on admission (F), right ventricular endomyocardial biopsy specimen with hematoxylin and eosin (HE) staining (G). Sustained ventricular tachycardia (A). Sinus rhythm, right axis deviation, poor R-wave progression, and monomorphic premature ventricular contractions (B). T-wave depression on chest leads in addition to previous findings (C). Chest radiographs showed mildly enlarged cardiac shadows already 3 months before admission (D) and pulmonary congestion findings on admission (E). The left ventricle is severely enlarged. Prolapse of the posterior mitral leaflet and severe mitral regurgitation are observed (F). There is no evidence of inflammation or fibrosis in the biopsy sample (G).

VA-ECMO at 2.2 L/min, noradrenaline at 0.4 μg/kg/min, and dobutamine at 1.0 μg/kg/min. The nasopharyngeal SARS-CoV-2 polymerase chain reaction test was negative. ECG showed sinus rhythm, right-axis deviation, and poor R-wave progression (Fig. 1C). Blood tests revealed severe liver and kidney dysfunction, lactic acidosis, elevated highly sensitive troponin I level, with no significant increase in eosinophil count. Transthoracic echocardiography showed that left ventricular end-diastolic diameter increased to 77 mm and left ventricular ejection fraction (LVEF) decreased to 25 %. Right ventricular contraction also decreased severely. The left ventricular wall thickness was 14 mm, slightly thickened, and there was a small amount of pericardial effusion. Furthermore, the posterior leaflet of the mitral valve was significantly prolapsed, which indicated severe mitral regurgitation (MR) (Fig. 1F). There was no evidence of vegetation or ruptured chordae tendineae. Coronary angiography showed normal coronary arteries, and we performed endomyocardial biopsy from the right ventricular side of ventricular septum and obtained three specimens. We

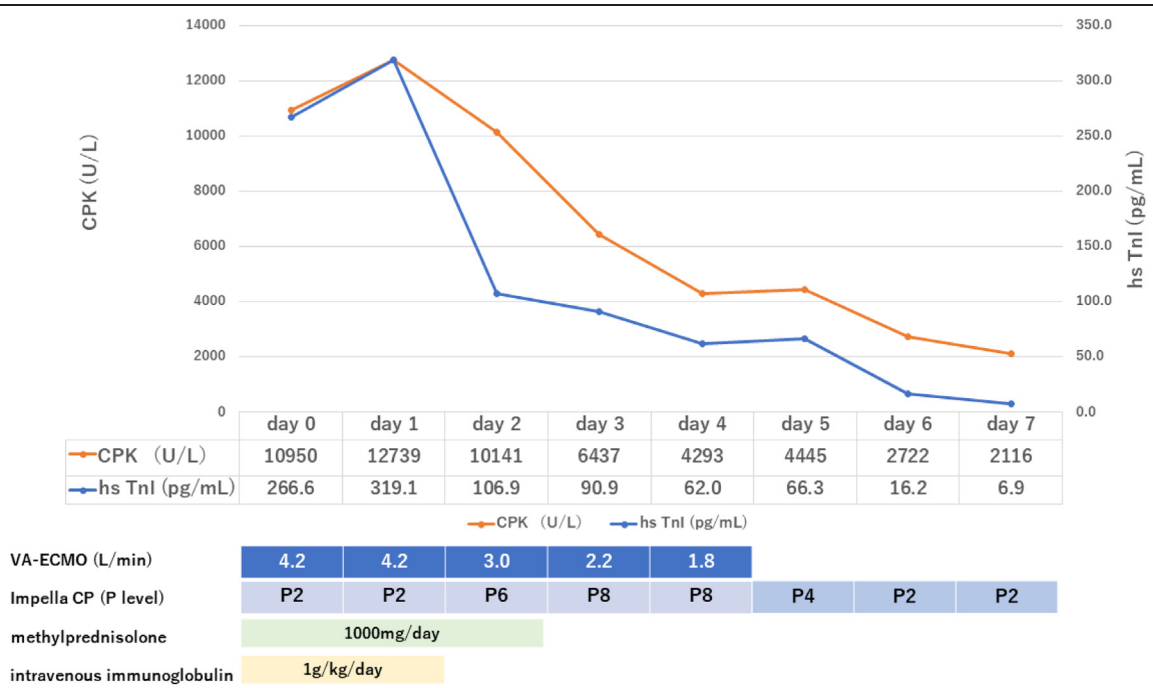

Fig. 2. Trend of blood highly sensitive troponin I and creatinine phosphokinase until removal of mechanical cardiac support devices. After admission, blood high-sensitivity troponin I and creatinine phosphokinase promptly decreased.
hs TnI, high-sensitivity troponin I; CPK, creatine phosphokinase; VA-ECMO, venoarterial extracorporeal membrane oxygenation.

considered the patient to have fulminant myocarditis developed in the presence of stage B heart failure due to chronic severe MR and started corticosteroid pulse therapy (methylprednisolone 1000 mg/day for 3 days) and intravenous immunoglobulin (IVIG) therapy (1 g/kg for 2 days). The results of the endomyocardial biopsy were no inflammatory findings in the myocardium in all three specimens (Fig. 1G). After initiation of ventricular assist devices with VA-ECMO and Impella CP, steroid pulse therapy, and IVIG therapy, cardiac enzyme level decreased (Fig. 2). He was able to wean off VA-ECMO on day 4; however, anisocoria appeared on the same day and head computed tomography revealed diffuse severe brain edema. On day 7, his LVEF improved to 45 %, and Impella CP was weaned. On day 9, the electroencephalogram became flat. The patient died on day 28 due to progressive multiorgan failure. The blood eosinophil count showed no significant increase until his death.

An autopsy revealed asymmetric left ventricular hypertrophy, thickening of the right ventricular wall (550 g; LV wall, 11–16 mm; RV wall, 5–7 mm), myxomatous degeneration of the posterior leaflet of the mitral valve, and hypertrophy of the posteromedial papillary muscle (Fig. 3A). Microscopic findings revealed that cardiac myocytolysis and widespread fibrosis were observed (Fig. 3B, C) and significant mixed inflammatory infiltration (T cells, macrophages, and eosinophils) was observed in the left ventricular free wall and the anterior potion of the ventricular septum (Fig. 3D–F), which led to the diagnosis of myocarditis. There was no evidence of CD138+ CD79a+ CD20− plasmocytes. Although asymmetric left ventricular hypertrophy was observed, cardiac muscle cell disorganization that is characteristic of hypertrophic cardiomyopathy was not observed. In contrast to the left ventricular free wall, the posterior potion of the ventricular septum and right ventricular free wall had almost no inflammatory cell infiltration or fibrosis, and almost normal myocardium was maintained (Fig. 3G, H). Additionally, the posterior papillary muscles showed a similar inflammatory cell infiltrate at the left ventricular myocardium, with extensive and severe fibrosis (Fig. 3I).

Discussion

We report an autopsy case of a 27-year-old healthy man who presented with cardiopulmonary arrest 8 days after the first dose of the mRNA-1273 SARS-CoV-2 vaccine and was finally diagnosed with

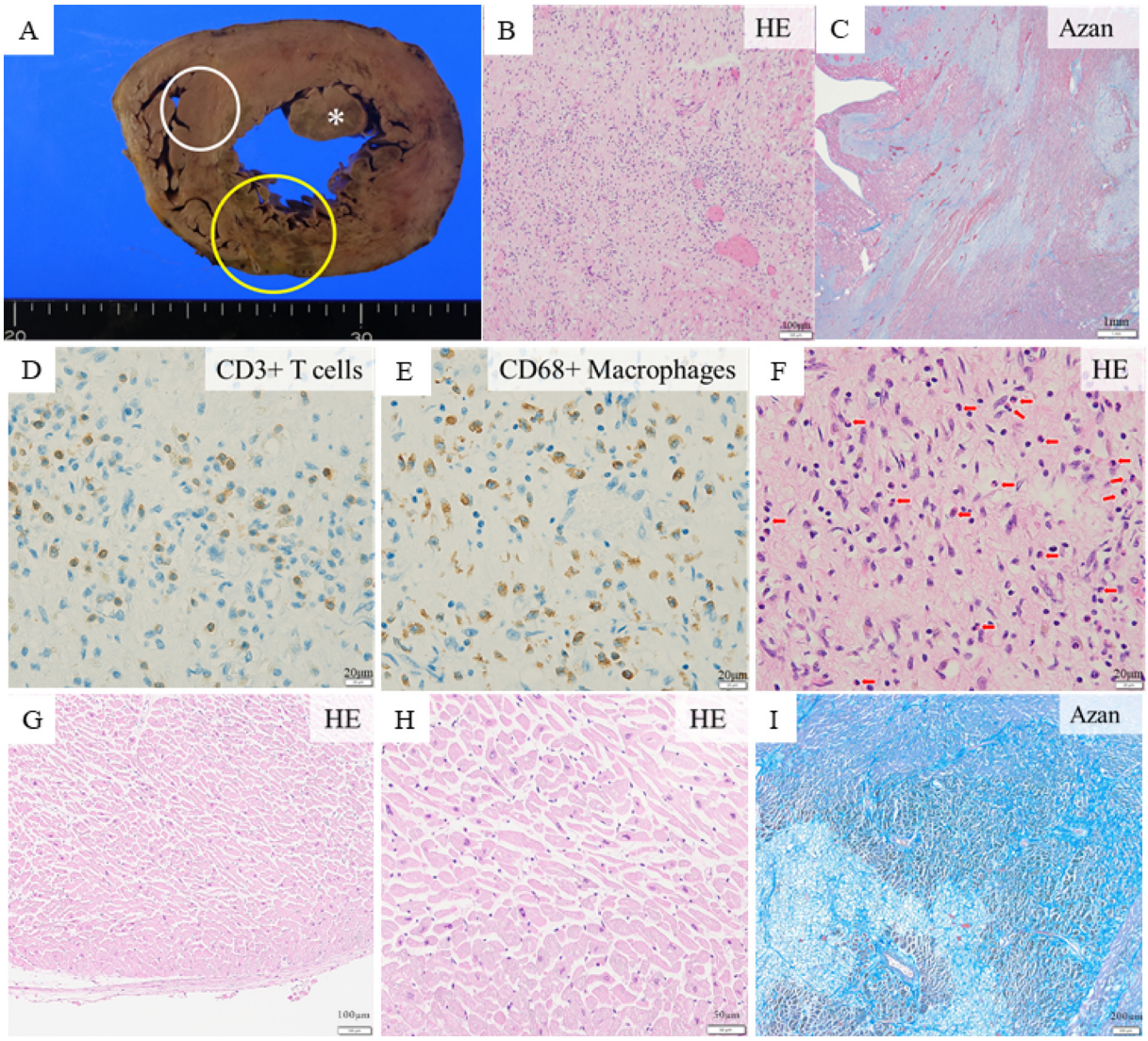

Fig. 3. Cardiac macroscopic and microscopic findings. The macroscopic findings (A) indicate asymmetric left ventricular hypertrophy, thickening of the right ventricular wall, and hypertrophy of the posteromedial papillary muscle (*). Histopathologic findings of the left ventricular anterior wall (yellow circle) stained with hematoxylin and eosin (HE) (B) and Azan (C). Significant mixed inflammatory infiltration and widespread fibrosis were observed. Anti-CD3 antibody (D), anti-CD68 antibody (E), and HE (F). Disseminated eosinophils are noted (red arrows). In contrast, the posterior potion of the ventricular septum (white circle) had no inflammatory cell infiltration or fibrosis (G, H). The posteromedial papillary muscle had a similar mixed inflammatory cell infiltrate as the left ventricular myocardium, with extensive and severe fibrosis (I).

fulminant myocarditis. Mitral valve prolapse is relatively common in athletes, also known as arrhythmic mitral valve prolapse, and may present with ventricular arrhythmias and sudden cardiac death even in the absence of hemodynamic impairment [4–6]. In this case, endomyocardial biopsy performed before death showed no evidence of myocarditis; therefore, cardiopulmonary arrest due to arrhythmic mitral valve prolapse was considered a possible differential diagnosis. However, the autopsy showed obvious severe myocardial inflammation findings, leading to the diagnosis of myocarditis. It is difficult to distinguish hypertrophic cardiomyopathy from the athlete's heart occasionally [7], the patient presented with asymmetric left ventricular hypertrophy, but no findings characteristic of hypertrophic cardiomyopathy were seen on autopsy. Therefore, we considered that his left ventricular hypertrophy was a consequence of the athlete's heart and MR. Microscopic findings showed infiltration of T cells, macrophages, and eosinophils. Such myocarditis with lymphocytic and eosinophilic infiltration has been reported after mRNA COVID-19 vaccination [3,8]. Lymphocytic and eosinophilic infiltration was also observed in myocarditis after smallpox vaccination and a mechanism of immune-mediated myocarditis has been speculated [9]. In addition, Frustaci et al. reported three cases of pathohistologically defined eosinophilic myocarditis after COVID19 vaccination, referring to the possibility of eosinophilic myocarditis (hypersensitivity myocarditis) as an allergic reaction and the possibility that immunosuppressive therapy including steroids may be effective [10]. Considering the response to steroid pulse therapy, it is possible that this mechanism of eosinophil-mediated immunological injury to cardiomyocytes is also involved in this case. This patient's eosinophilic infiltrate may have decreased from the time of onset because of the 4-week interval between onset and death and steroid treatment. Microscopic findings of the posterior potion of the ventricular septum showed no inflammatory cell infiltrate, and the myocardial biopsy findings are consistent with a sampling error. If the endomyocardial biopsy results were not a sampling error, then his first fatal arrhythmia was caused by arrhythmic mitral valve prolapse and athlete's heart, with myocarditis occurring afterward. However, considering his sequence of events integrally, it is still highly likely that it was a sampling error. Fibrosis of the papillary muscle and myocardium is also observed in patients with arrhythmic mitral valve prolapse, and similar findings were noted in this case [5,6]. This may indicate that the patient had an arrhythmogenic substrate and was more susceptible to fatal arrhythmias.

Conclusions

Here, we reported an autopsy case of fulminant myocarditis following mRNA COVID-19 vaccination. The microscopic findings revealed that significant mixed inflammatory infiltration (T cells, macrophages, and eosinophils) and widespread fibrosis were observed in the left ventricle. Steroid therapy may be effective in the treatment of fulminant myocarditis following mRNA COVID-19 vaccination.

Declaration of competing interest

The authors declare that there is no conflict of interest.

Acknowledgments

The authors would like to thank MARUZEN-YUSHODO Co., Ltd. (https://kw.maruzen.co.jp/kousei-honyaku/) for the English language editing.

References

[1] Tailor PD, Feighery AM, El-Sabawi B, Prasad A. Case report: acute myocarditis following the second dose of mRNA-1273 SARS-CoV-2 vaccine. Eur Heart J Case Rep 2021;5:319.
[2] Diaz GA, Parsons GT, Gering SK, Meier AR, Hutchinson IV, Robicsek A. Myocarditis and pericarditis after vaccination for COVID-19. JAMA 2021;326:1210–2.
[3] Verma AK, Lavine KJ, Lin CY. Myocarditis after Covid-19 mRNA vaccination. N Engl J Med 2021;385:1332–4.
[4] Basso C, Iliceto S, Thiene G, Perazzolo Marra M. Mitral valve prolapse, ventricular arrhythmias, and sudden death. Circulation 2019;140:952–64.
[5] Caselli S, Mango F, Clark J, Pandian NG, Corrado D, Autore C, et al. Prevalence and clinical outcome of athletes with mitral valve prolapse. Circulation 2018;137:2080–2.
[6] Miller MA, Dukkipati SR, Turagam M, Liao SL, Adams DH, Reddy VY. Arrhythmic mitral valve prolapse: JACC review topic of the week. J Am Coll Cardiol 2018;72:2904–14.
[7] Basavarajaiah S, Wilson M, Junagde S, Jackson G, Whyte G, Sharma S, et al. Physiological left ventricular hypertrophy or hypertrophic cardiomyopathy in an elite adolescent athlete: role of detraining in resolving the clinical dilemma. Br J Sports Med 2006;40:727–9.
[8] Kazama S, Okumura T, Kimura Y, Ito R, Araki T, Mizutani T, et al. Biopsy-proven fulminant myocarditis requiring mechanical circulatory support following COVID-19 mRNA vaccination. CJC Open 2022;4:501–5.
[9] Murphy JG, Wright RS, Bruce GK, Baddour LM, Farrell MA, Edwards WD, et al. Eosinophilic-lymphocytic myocarditis after smallpox vaccination. Lancet 2003;362:1378–80.
[10] Frustaci A, Verardo R, Galea N, Lavalle C, Bagnato G, Scialla R, et al. Hypersensitivity myocarditis after COVID-19 mRNA vaccination. J Clin Med 2022;11:1660.