Since January 2020 Elsevier has created a COVID-19 resource centre with free information in English and Mandarin on the novel coronavirus COVID-19. The COVID-19 resource centre is hosted on Elsevier Connect, the company's public news and information website.

Elsevier hereby grants permission to make all its COVID-19-related research that is available on the COVID-19 resource centre - including this research content - immediately available in PubMed Central and other publicly funded repositories, such as the WHO COVID database with rights for unrestricted research re-use and analyses in any form or by any means with acknowledgement of the original source. These permissions are granted for free by Elsevier for as long as the COVID-19 resource centre remains active.

Radiology Case Reports 17 (2022) 2841–2849

Available online at www.sciencedirect.com

ScienceDirect

journal homepage: www.elsevier.com/locate/radcr

Case Report

Mammographic findings of diffuse axillary tail trabecular thickening following immunization with mRNA COVID-19 vaccines: Case series study☆

Richard Adam, BS[a,*], *Tim Duong, PhD*[a,b], *Laura Hodges, MD*[b], *Christine Staeger-Hirsch, MD*[b], *Takouhie Maldjian, MD*[b]

[a] *Stony Brook University, 100 Nicolls Road, Stony Brook, NY, 11794, USA*
[b] *Department of Radiology, Albert Einstein College of Medicine and Montefiore Medical Center, Bronx, NY, USA*

ARTICLE INFO

Article history:
Received 12 March 2022
Revised 11 April 2022
Accepted 13 April 2022

Keywords:
COVID-19
Mammography
Trabecular thickening

ABSTRACT

Axillary lymphadenopathy has been reported after ipsilateral COVID-19 vaccination and can cause confusion for possible malignancy [1]. Intrinsic findings isolated to the breast has not been previously reported. This is the first case series of ipsilateral reversible changes of diffuse axillary tail trabecular thickening on screening mammography in totally asymptomatic patients in connection with COVID vaccination, 3 of which were isolated findings, confirmed by complete resolution of all imaging findings on follow up. In all instances, imaging was performed within 1 week of the first or third dose of an mRNA COVID-19 vaccine. These findings can be confused with breast cancer. Spontaneous resolution distinguishes vaccine-related findings from breast cancer.

© 2022 The Authors. Published by Elsevier Inc. on behalf of University of Washington. This is an open access article under the CC BY-NC-ND license (http://creativecommons.org/licenses/by-nc-nd/4.0/)

In this study, we describe 5 similar cases of diffuse axillary tail trabecular thickening demonstrated on screening mammography within 1 week post COVID vaccine. Given the ongoing global efforts to vaccinate against COVID-19, these associated changes could present a diagnostic dilemma, as they can also be seen in breast cancer. COVID-19 vaccine will likely become a recurring event, with foreseeable boosters at regular time intervals. As a result, post COVID vaccination sequela will likely be encountered much more frequently and will need to be managed and addressed properly.

Case Reports

An asymptomatic patient presented for screening mammography in 2021, 2 days after receiving her first dose of COVID-19 vaccine (Pfizer). Her screening mammogram demonstrated diffuse axillary tail trabecular thickening on the left, ipsilateral to the side of COVID vaccine injection (Fig. 1A). The patient was assigned BI-RADS 0 and further evaluation with spot compression was recommended. She received her 2nd COVID

☆ Competing Interests: The authors have declared that no competing interests exist.

* Corresponding author.
E-mail address: Richard.adam@stonybrook.edu (R. Adam).

https://doi.org/10.1016/j.radcr.2022.04.028

1930-0433/© 2022 The Authors. Published by Elsevier Inc. on behalf of University of Washington. This is an open access article under the CC BY-NC-ND license (http://creativecommons.org/licenses/by-nc-nd/4.0/)

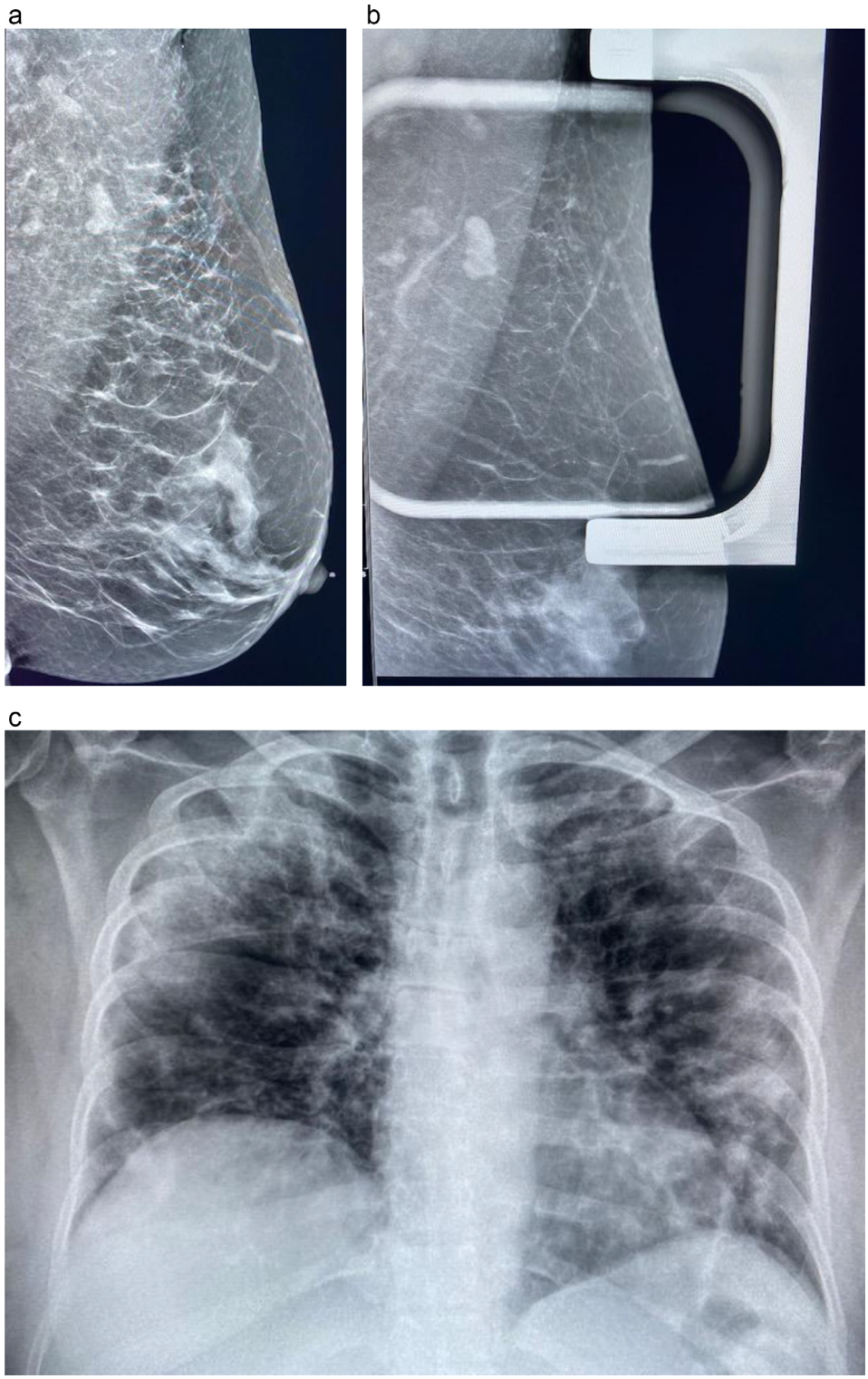

Fig. 1 – (A) Screening left mammogram demonstrates trabecular thickening of the left axillary tail region, ipsilateral to the side of COVID vaccination. (B) Follow-up diagnostic mammography 7 weeks later with spot compression demonstrates complete resolution of the trabecular thickening. (C) Frontal view of the chest demonstrates bilateral airspace opacities with peripheral predominance, characteristic of COVID pneumonia.

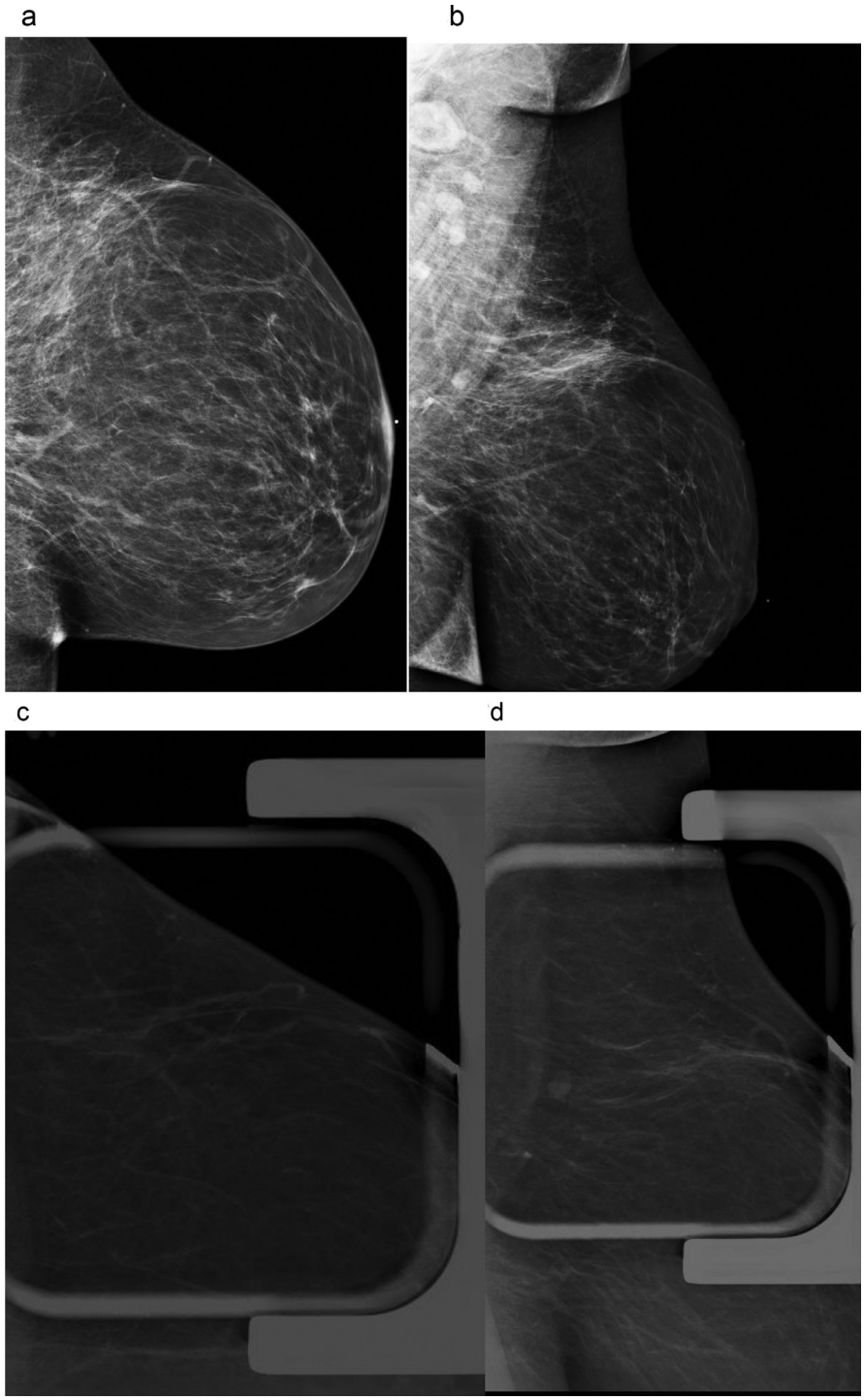

Fig. 2 – (A, B) CC and MLO images from screening mammogram demonstrate trabecular thickening of the left axillary tail region and a prominent axillary lymph node, ipsilateral to the side of COVID vaccination. (C, D) Spot compression CC and MLO images from follow-up diagnostic mammography performed 1 month later demonstrate resolution of left axillary tail trabecular thickening. (E) Follow-up left axillary ultrasound demonstrates normal appearing lymph node.

vaccine in 2021, 3 weeks after her first vaccine. She returned 1 month after her 2nd vaccination (7 weeks after her screening mammogram) for her diagnostic mammogram, which showed complete resolution of the findings (Fig. 1B). Pertinent past medical history revealed that she had been hospitalized for COVID pneumonia 3 months prior to her first vaccination and screening mammogram (Fig. 1C). Patient had a medical history of hypertension and obesity.

An asymptomatic patient presented for screening mammography in 2021, 5 days after receiving her first dose

Fig. 2 – Continued

of COVID vaccine (Moderna). Her screening mammogram demonstrated diffuse left axillary tail trabecular thickening and axillary node enlargement ipsilateral to the side of injection (Figs. 2A and B). The patient was assigned BI-RADS 0 and further evaluation was recommended. Diagnostic left mammogram (Figs. 2C and D) and left axillary ultrasound (Fig. 2E) performed 1 month after screening mammogram demonstrated resolution of the findings. The patient did not receive a 2nd vaccination. Patient had history of hypertension and morbid obesity.

An asymptomatic patient presented for screening mammography 3 days after receiving her first dose of COVID vaccine (Moderna). Screening mammogram demonstrated diffuse axillary tail trabecular thickening and axillary node enlargement ipsilateral to the side of inoculation (Fig. 3A). The patient was assigned BI-RADS 0 and further evaluation was recommended. She received her 2nd vaccine 4 weeks after her 1st vaccine. She had diagnostic mammography 6 weeks after her screening mammogram (3 weeks after her 2nd vaccination), which demonstrated resolution of both axillary tail trabecular thickening and lymph node enlargement (Fig. 3B). Diagnostic left axillary ultrasound demonstrated normal-appearing lymph node (Fig. 3C). Patient had no significant medical history.

An asymptomatic patient presented for screening mammography 5 days after receiving her 3rd dose (booster) of COVID vaccine (Moderna). She received her first and second doses 10 months and 9 months prior to screening mammography. Screening mammogram demonstrated diffuse left axillary tail trabecular thickening ipsilateral to the side of inoculation (Figs. 4A and B). The patient was assigned BI-RADS 0 and further evaluation was recommended. 6 weeks after her screening mammogram she returned for diagnostic mammogram (Figs. 4C and D) and ultrasound (Fig. 4E), both of which were negative. Patient had a medical history of obesity and hypertension. Patient also had a history of scleroderma.

An asymptomatic patient presented for screening mammogram 2 days after receiving her 3rd dose (booster) of COVID vaccine (Moderna). She received her first and second doses 9 months and 8 months prior to screening mammography. Screening mammogram demonstrated diffuse left axillary tail trabecular thickening ipsilateral to the side of inoculation (Fig. 5A). The patient was assigned BI-RADS 0 and further evaluation was recommended.5 weeks after her screening mammogram she returned for diagnostic mammogram (Fig. 5B) and ultrasound, both of which were negative. One month prior to her booster and screening mammogram, the

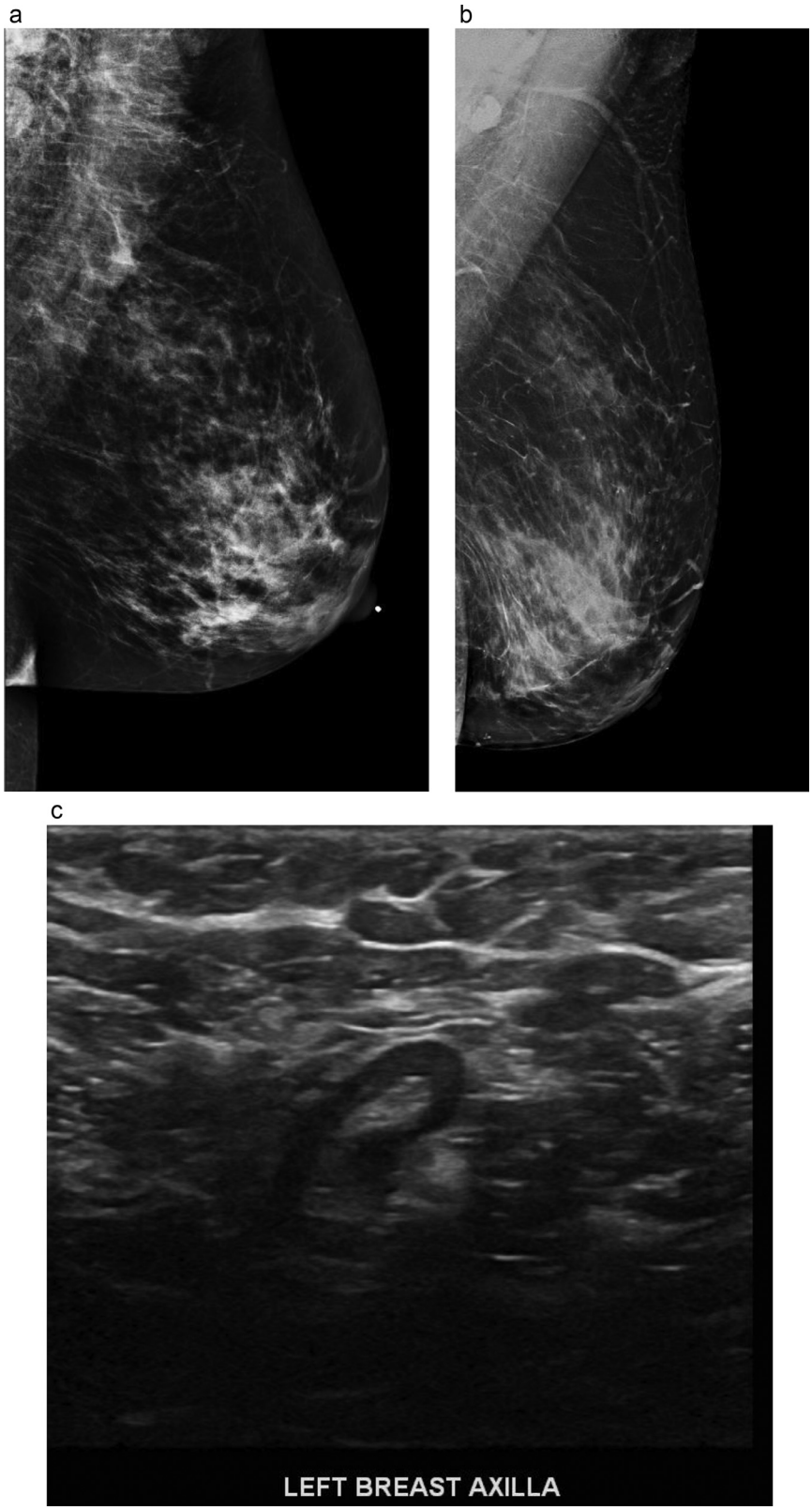

Fig. 3 – (A) MLO from screening mammogram demonstrates trabecular thickening of the left axillary tail region and prominent axillary lymph nodes, ipsilateral to the side of COVID vaccination. (B) Follow-up diagnostic mammogram performed 6 weeks later demonstrates resolution of axillary tail trabecular thickening and axillary lymphadenopathy. (C) Left axillary ultrasound performed at the same time as diagnostic mammogram demonstrates normal-appearing axillary lymph node.

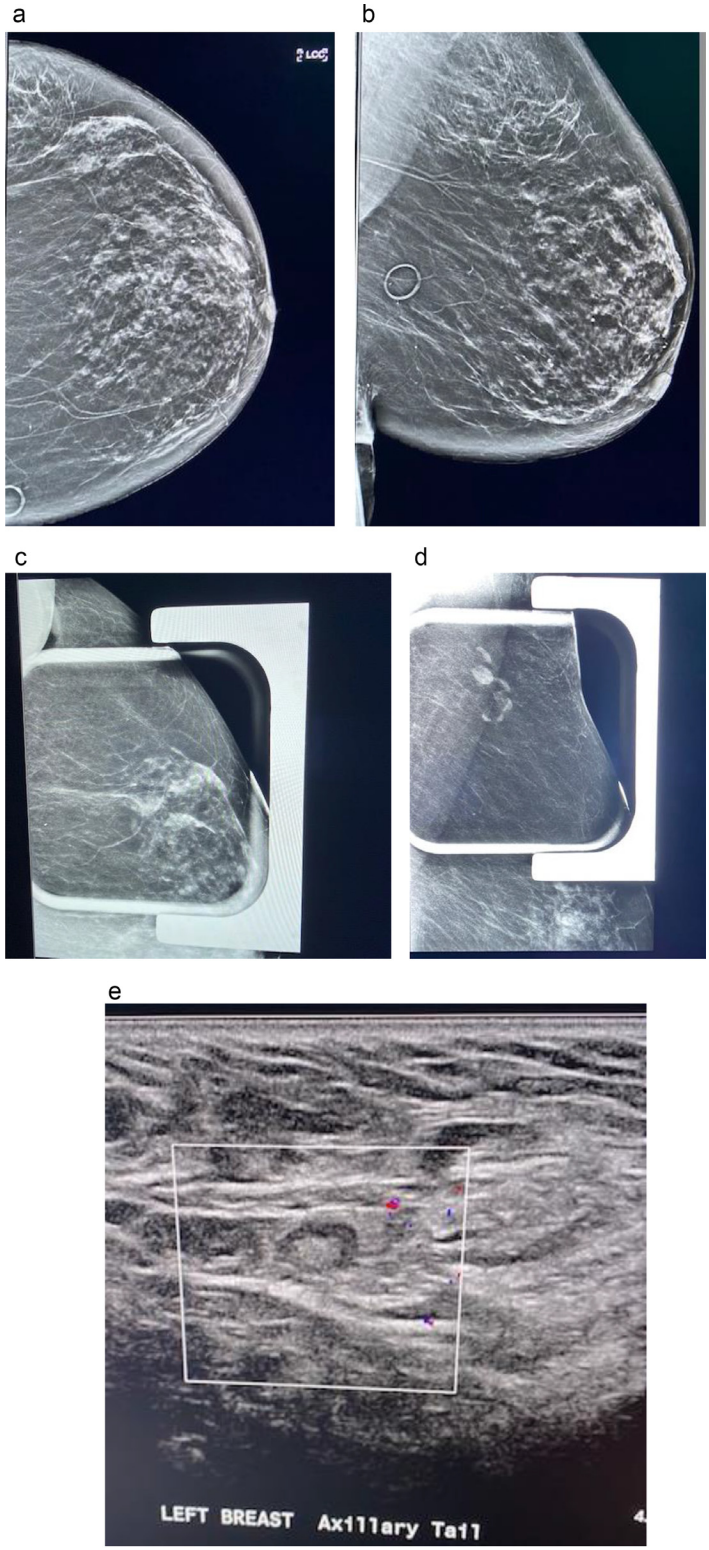

Fig. 4 – Screening left mammogram demonstrates trabecular thickening of the left axillary tail region, ipsilateral to the side of COVID vaccination (A, B) Follow-up diagnostic mammography 6 weeks later with spot compression demonstrates complete resolution of the trabecular thickening (C, D). Axillary tail ultrasound demonstrates normal sized and normal appearing lymph nodes (E).

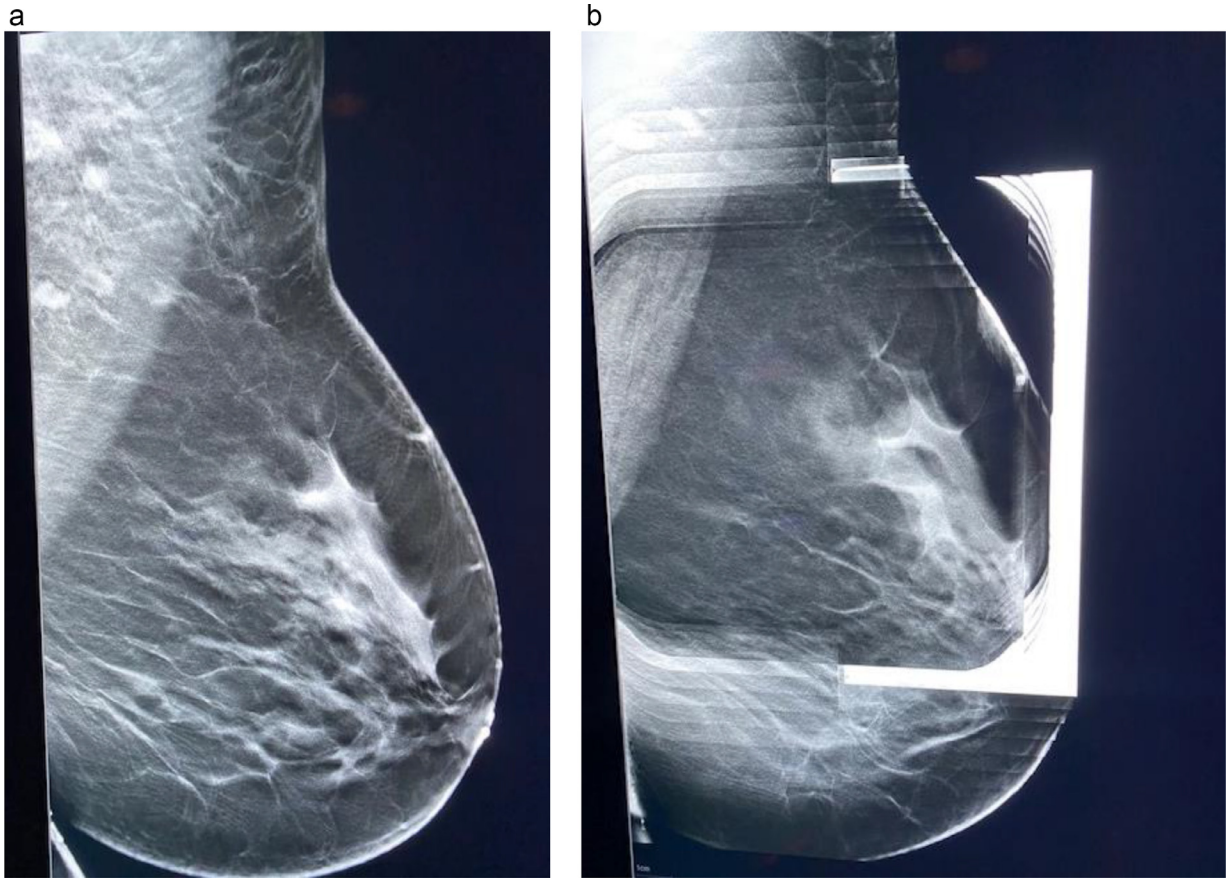

Fig. 5 – Screening left mammogram demonstrates trabecular thickening of the left axillary tail region, ipsilateral to the side of COVID vaccination (A). Follow-up diagnostic mammography 5 weeks later with spot compression demonstrates complete resolution of the trabecular thickening (B).

patient had COVID infection, with symptoms of cough, fever, and headaches. Patient had a medical history of obesity and prediabetes.

Follow up diagnostic mammography demonstrated resolution of all findings in all 5 patients, which were therefore attributed to post-COVID vaccination sequelae.

Discussion

Enlarged, hyperplastic axillary nodes have been previously described with COVID vaccine [1]. Mostazavi described axillary adenopathy in 23 women post COVID-19 vaccine in a retrospective study [2]. Additional investigations followed these reports with evolving recommendations. Current SBI recommendations state that "it may be appropriate to give a BI-RADS category 2 (benign) assessment" with unilateral axillary lymphadenopathy on mammogram ipsilateral to recent COVID vaccine injection when no suspicious mammographic findings are seen, and for patients undergoing short term follow up (BI-RADS category 3) a 12 week or more follow up is recommended [3]. In the scenario of imaging detected ipsilateral axillary adenopathy within 12 weeks of COVID vaccine injection and no patient history of breast cancer, the EUSOBI guidelines recommends benign designation (BI-RADS category 2) in asymptomatic patients with no suspicious breast findings at imaging and probably benign designation (BI-RADS category 3) in patients with breast symptoms and no suspicious breast findings at imaging [4]. In patients with prior history of breast cancer, EUSOBI guidelines recommend that vaccination be administered in the contralateral arm or in the anterolateral thigh [4]. As per EUSOBI guidelines, breast imaging should preferably be performed before or at least 12 weeks after vaccination, depending on clinical context (recommending there be no delay in patients with newly diagnosed breast cancer) [4].

Post vaccination adenopathy is a well known entity. Axillary adenopathy has been shown post influenza vaccination on PET and CT scans [5]. Hartscock reported 9 of 20 cases of post-vaccine lymphadenitis secondary to recent smallpox vaccine inoculation in 1968, incorrectly initially diagnosed as malignant lymphoma [6]. Newfield reported a case in 1990 of unilateral axillary lymph node enlargement 2 months post BCG vaccine in a 50-year-old woman, originally misdiagnosed as pathologic [7]. In 2008, unilateral adenopathy in adults after ipsilateral deltoid muscle injection of the human papilloma virus (HPV) vaccine was reported [8].

Prominent axillary lymph nodes on imaging can present a diagnostic dilemma in patients with breast cancer, as well as other oncological patients. Avid axillary lymph node uptake of [18 F] FDG ipsilateral to COVID vaccine on PET/CT has been reported in 54% of oncological patients, and in 37% of patients this was deemed unlikely to be related to metastatic disease [9]. Taking vaccination histories and giving vaccinations contralateral to known malignancies was recommended [9]. A case series of 4 breast cancer patients with metabolically active axillary lymph nodes on PET/CT post COVID-19 vaccination all had biopsy proven reactive lymph nodes, illustrating the dilemma in this cohort [10]. Axillary lymph nodes are the most common site for lymph node seeding in breast cancer and are also the most common site for reactive lymphadenopathy post COVID-19 vaccination. In the setting of enlarged /metabolically active axillary lymph nodes ipsilateral to COVID-19 vaccination on PET/CT, axillary ultrasound at 4 weeks to document resolution has been suggested [10].

A case series of 3 patients describes mammographic findings in the breast in conjunction with axillary adenopathy post COVID-19 vaccination, 2 of which had clinical symptoms at presentation which were presumably vaccine-related [11]. One patient presented 10 days post- vaccination with lymphadenopathy /palpable lump, focal soft tissue thickening and erythema, demonstrating prominent axillary lymph node with adjacent focal soft tissue changes on diagnostic mammogram [11]. Vaccine related reactive lymphadenitis could produce these findings. Focal asymmetry in conjunction with lymphadenopathy was described in the other 2 patients one day post vaccination, with focal asymmetry resolving on follow-up [11]. Resolving focal asymmetry could represent summation artifact, as well as post-vaccine local reactive changes which typically occur in the immediate post-vaccination time frame described, with 1 patient demonstrating concurrent arm, axillary, face /neck swelling and showing correlative imaging findings of focal asymmetry and skin thickening [11,12]. In their study, persistent lymphadenopathy seen on follow-up imaging in 2 of the 3 cases, up to 27 days post-vaccine, was not pursued further to confirm resolution [11]. Malignancy has recently been reported in persistent lymph nodes post COVID-vaccination in asymptomatic screening mammography patients having no other lymphadenopathy elsewhere in the body [13].

Diffuse axillary tail trabecular thickening post COVID-vaccine as an isolated finding, without skin thickening, lymphadenopathy, and erythema is a novel finding and raises the possibility of a mechanism besides local reactive changes. Three of our patients had hypertension and obesity, both of which place patients at greater risk of mortality with COVID-19 [14]. Obesity is associated with increased severity and lethality of COVID, as is hypertension [15,16]. One of our patients with both obesity and hypertension was previously hospitalized for COVID-19 pneumonia (Fig. 1C). Another one of our patients had COVID infection, with upper respiratory symptoms, 1 month prior to her 3rd vaccination (booster), and had a history of obesity and pre-diabetes. Obesity-induced chronic inflammation may precipitate hyperinflammation, cytokine storm, ARDS and COVID-associated-coagulopathy (CAC) and may lead to severe complications related to COVID [17]. Proinflammatory cytokines associated with hypertension may similarly predispose to augmented immune response with adverse course and severity of COVID infection [18]. Lung complications in COVID infection may in part be auto-immune mediated due to cross-reaction with pulmonary surfactant protein, since 13 of the 24 pentapeptides in lung surfactant are the same as those in spike glycoprotein in COVID-19 [19]. This cross-reactivity has also been demonstrated in other organs, as one study showed that SARS-CoV-2 antibodies reacts with 28 of 55 diverse human tissue antigens, including barrier proteins, gastrointestinal, thyroid and neural tissues, and others [20]. One of our patients had scleroderma, an auto-immune disorder which may predispose to acquiring other auto-immune processes and potentially predispose to this mechanism of cross-reactivity to the vaccine. The mRNA vaccine instructs cells to synthesize a portion of the spike protein, which, like the native viral spike protein /antigen, stimulates the immune system to synthesize antibodies. These antibodies may demonstrate some degree of cross-reactivity with human tissues due to the similarity of human tissue constituents to the spike protein. The rare occurrence of myocarditis post-vaccination is explained by cross-reaction of antibodies to SARS-CoV-2 spike glycoproteins with structurally similar myocardial protein sequences [21,22]. Risk and severity of myocarditis in the unvaccinated setting from COVID far exceeds the risk of myocarditis from vaccination, which is milder [23]. Myocarditis when occurring is observed in the first 7 days post vaccination [23]. Our patients demonstrated diffuse trabecular thickening 2 days, 5 days, 3 days, 5 days, and 2 days post vaccination, all falling within this time frame, potentially resulting from a similar immune-mediated mechanism heightened by underlying pro-inflammatory conditions such as hypertension and/or obesity (present in 4 of our patients). Local reactions typically occur within 48 hours after vaccination (day 0 of vaccine to 2 days after vaccine), lasting between 1 and 2 days, and do not fit all our patients timelines and presentations, since 2 of them presented 5 days post-vaccine and none showed local soft tissue swelling or skin thickening [12].

This is the first case series of ipsilateral reversible changes of diffuse axillary tail trabecular thickening, seen as an isolated finding in 3 of our 5 patients, on screening mammography in totally asymptomatic patients in connection with COVID vaccination (3 after 1st vaccination and 2 after 3rd Moderna vaccination /booster), confirmed by complete resolution of all imaging findings on follow up. 4 of our 5 patients received Moderna and 1 received Pfizer vaccine. While the findings we describe were seen in asymptomatic screening patients, clinical findings of focal soft tissue swelling or the perception of a “lump” felt by the patient or the doctor could prompt a diagnostic exam. Whether in the screening or diagnostic setting, recognition of these findings as a sequela of COVID-19 vaccination would potentially obviate many unnecessary biopsies and follow-ups that would strain the healthcare system and cause unnecessary patient anxiety. We would continue to recommend diagnostic work-up to document resolution, as tumor infiltration can have an identical appearance. When accompanied by enlarged ipsilateral axillary lymph nodes the differential diagnosis includes breast cancer with axillary lymph node involvement. While inflammatory breast cancer in addition to mastitis could manifest

as diffuse trabecular thickening, our cases lacked skin thickening typically seen with these diagnoses. A larger study can be performed to ascertain the frequency of imaging findings intrinsic to the breast post-COVID vaccine.

Patient consent

The author was unable to obtain written consent from the patient(s) or from the patient(s) relatives, despite attempts to do so. Because of the public interest in publication, the anonymization of the patient, and that attempts had been made to contact the patient and their relatives, exceptional agreement for publication of the case report was given by the Editor-in-Chief of the journal *Radiology Case Reports*.

REFERENCES

[1] Mehta S, Sales RM, Babagmemi K, Levy A, McGrath AL, Drotman M, et al. Unilateral axillary adenopathy in the setting of Covid-19 vaccine. Clin Imaging 2021;75:12–15.

[2] Mortazavi S. Coronavirus Disease (COVID-19) vaccination associated axillary adenopathy: imaging findings and follow-up recommendations in 23 Women. AJR Am J Roentgenol 2021 doi:Online ahead of print. PMID: 33624520. doi:10.2214/AJR.21.25651.

[3] Grimm L., Srini A., Dontchos B., Ruan C., Zeng X., Xu A., et. al. Revised SBI recommendations for the management of axillary adenopathy in patients with recent COVID-19 vaccination. Available at: https://www.sbi-online.org, 2020, March 10, 2022.

[4] Schiaffino S, Pinker K, Magni V. Axillary lymphadenopathy at the time of COVID-19 vaccination: ten recommendations from the European Society of Breast Imaging (EUSOBI). Insights Imaging 2021;12(1):119.

[5] Shirone N, Shinkai T, Yamane T, Uto F, Yoshimura H, Tamai H, et al. Axillary lymph node accumulation on FDG-PET/CT after influenza vaccination. Ann Nuclear Med 2012;26:248–52.

[6] Hartsock RJ. Postvaccinial lymphadenitis. Hyperplasia of lymphoid tissue that simulates malignant lymphomas. Cancer 1968;21(4):632–49.

[7] Newfield L, Naschitz JE, Yeshurun D. BCG-induced axillary lymph-adenitis in the adult. Harefuah 1990;119(7–8):199–200.

[8] Studdiford J, Lamb K, Horvath K, Altshuler M, Stonehous A. Development of unilateral cervical and supraclavicular lymphadenopathy after human papilloma virus vaccination. Pharmacotherapy 2008;28(9):1194–7.

[9] Skawran S, Gennari AG, Dittli M, Treyer V, Muehlematter UJ, Maurer A, et al. [18 F] FDG Uptake of Axillary Lymph Nodes after COVID-19 Vaccination in Oncological PET/CT: Frequency, Intensity and Potential Clinical Impact. Eur. Radiol. 2022;32(1):508–16.

[10] Brown AH, Shah S, Groves AM, Wan S, Malhotra A. The challenge of staging breast cancer with PET/CT in the Era of COVID Vaccination. Clin Nucl Med 2021. doi:10.1097/RLU.0000000000003683.

[11] Locklin JN, Woodard GA. Mammographic and sonographic findings in breast and axillary tail following a COVID-19 vaccine. Clin Imaging 2021;80:202–4.

[12] Available at: https://www.cdc.gov/vaccines/covid-19/info-by-product/pfizer/reactogenicity.html, 2020, February 13, 2022.

[13] Nguyen DL, Ambinder EB, Myers KS, Mullen LA, Panigrahi B, Oluyemi E. COVID-19 vaccine-related axillary adenopathy on breast imaging: follow-up recommendations and histopathologic findings. AJR Am J Roentgenol 2021 doi:Epub ahead of print. PMID: 34935404. doi:10.2214/AJR.21.27162.

[14] Katz MH. Regardless of Age, Obesity and Hypertension Increase Risks with COVID-19. JAMA Intern Med 2021;181(3):381. doi:10.1001/jamainternmed.2020.5415.

[15] Petrakis D, Margină D, Tsarouhas K, et al. Obesity a risk factor for increased COVID 19 prevalence, severity and lethality (Review). Mol Med Rep 2020;22(1):9–19. doi:10.3892/mmr.2020.11127.

[16] Chen J., Liu Y., Qin J., et al Hypertension as an independent risk factor for severity and mortality in patients with COVID-19: a retrospective study Postgraduate Medical, Journal Published Online First 2021. doi:10.1136/postgradmedj-2021-140674.

[17] Demeulemeester F, de Punder K, van Heijningen M, van Doesburg F. Obesity as a Risk Factor for Severe COVID-19 and Complications. A Review. Cells. 2021;10(4):933 Published 2021 Apr 17. doi:10.3390/cells10040933.

[18] Gao C, Zhu L, Jin CC, Tong YX, Xiao AT, Zhang S. Proinflammatory cytokines are associated with prolonged viral RNA shedding in COVID-19 patients. Clin Immunol 2020;221:108611 doi:Epub 2020 Oct 14. PMID: 33068796; PMCID: PMC7554496. doi:10.1016/j.clim.2020.108611.

[19] Kanduc D, Shoenfeld Y. On the molecular determinants of the SARS-CoV-2 attack. Clin. Immunol. 2020;215:108426. doi:10.1016/j.clim.2020.108426.

[20] Vojdani A, Vojdani E, Kharrazian D. Reaction of human monoclonal antibodies to SARS- CoV-2 proteins with tissue antigens: implications for autoimmune diseases. Front. Immunol 2021. doi:10.3389/fimmu.2020.617089.

[21] Heymans S, Cooper LT. Myocarditis after COVID-19 mRNA vaccination: clinical observations and potential mechanisms. Nat Rev Cardiol 2022;19:75–7. doi:10.1038/s41569-021-00662-w.

[22] Vojdani A, Kharrazian D. Potential antigenic cross-reactivity between SARS-CoV-2 and human tissue with a possible link to an increase in autoimmune diseases. Clin. Immunol. 2020;217:108480.

[23] Patone M, Mei XW, Handunnetthi L. Risks of myocarditis, pericarditis, and cardiac arrhythmias associated with COVID-19 vaccination or SARS-CoV-2 infection. Nat Med 2021. doi:10.1038/s41591-021-01630-0.