Since January 2020 Elsevier has created a COVID-19 resource centre with free information in English and Mandarin on the novel coronavirus COVID-19. The COVID-19 resource centre is hosted on Elsevier Connect, the company's public news and information website.

Elsevier hereby grants permission to make all its COVID-19-related research that is available on the COVID-19 resource centre - including this research content - immediately available in PubMed Central and other publicly funded repositories, such as the WHO COVID database with rights for unrestricted research re-use and analyses in any form or by any means with acknowledgement of the original source. These permissions are granted for free by Elsevier for as long as the COVID-19 resource centre remains active.

Journal français d'ophtalmologie xxx (xxxx) xxx—xxx

Disponible en ligne sur
ScienceDirect
www.sciencedirect.com

Elsevier Masson France
EM|consulte
www.em-consulte.com

ORIGINAL ARTICLE

Central serous chorioretinopathy following the BNT162b2 mRNA vaccine

Choriorétinopathie séreuse centrale consecutive au vaccin à ARN messager BNT162b2

J. Hanhart[a,*], E. Roditi[a], L.M. Wasser[a], W. Barhoum[b], D. Zadok[a], K. Brosh[a]

[a] *Department of Ophthalmology Shaare-Zedek Medical Center Affiliated with the Hebrew University, Hadassah School of Medicine, Jerusalem, Israel*
[b] *Carmel Medical Center, Haifa, Israel*

Received 9 January 2022; accepted 18 January 2022

KEYWORDS
Central serous chorioretinopathy;
Vaccination;
COVID-19;
Severe acute respiratory syndrome coronavirus 2 (SARS-CoV-2);
BNT162b2 mRNA vaccine;
Serous retinal detachment;
Pachychoroid

Summary
Background and purpose. — Severe acute respiratory syndrome coronavirus 2 (SARS-CoV-2) has accelerated vaccine development. The BNT162b2 messenger RNA (mRNA) vaccine is being administered worldwide. The purpose of this case series is to report a possible association between the BNT162b2 mRNA vaccine and Central serous chorioretinopathy (CSC). Although rare, CSC has been reported following the administration of anthrax, influenza and smallpox vaccines.
Methods. — Four individuals who developed CSC following the BNT162b2 mRNA vaccine were examined in our institution using multimodal imaging of the retina, and their demographic data were analyzed and compared to all the similar cases published to date.
Results. — Four patients (3 males, 1 female) between the ages of 35 and 65 presented with acute CSC ($n = 3$) and relapsed CSC ($n = 1$) within the first week following the administration of the BNT162b2 mRNA vaccine. Three individuals demonstrated hyper-reflective foci in the outer segments of the retina.
Conclusions. — The timing of the BNT162b2 mRNA vaccine administration relative to the development of CSC suggests a possible causal relationship. Further research is necessary to explore this possible association.
© 2022 Elsevier Masson SAS. All rights reserved.

* Corresponding author.
E-mail address: hanhart@szmc.org.il (J. Hanhart).
[1] J. Hanhart and E. Roditi contributed equally to this work.

https://doi.org/10.1016/j.jfo.2022.01.006
0181-5512/© 2022 Elsevier Masson SAS. All rights reserved.

MOTS CLÉS
Choriorétinopathie séreuse centrale ;
Vaccination ;
COVID-19 ;
Coronavirus 2 du syndrome respiratoire aigu sévère ;
SARS-CoV-2 ;
Vaccin BNT162b2 à RNA messager ;
Décollement séreux de la rétine ;
Pachychoroïde

Résumé
Objectif. — La pandémie de COVID-19 a stimulé le développement de vaccins dirigés contre son agent étiologique, le coronavirus 2 du syndrome respiratoire aigu sévère (SARS-CoV-2). Actuellement, le vaccin à ARN messager BNT162b2 est largement utilisé. Nous présentons, ici, une série de cas de choriorétinopathie séreuse centrale potentiellement associée à l'administration dudit vaccin. Quoique relativement rare, la choriorétinopathie séreuse centrale avait préalablement été décrite dans les suites de vaccins contre l'anthrax, la grippe ou encore la variole.
Méthodes. — Analyse des données démographiques, cliniques, ainsi que de l'imagerie multimodale de quatre patients ayant présenté une choriorétinopathie séreuse centrale dans les suites immédiates du vaccin à ARN messager BNT162b2 et mise en parallèle avec tous les cas similaires publiés à ce jour.
Résultats. — Quatre patients (trois hommes, une femme) âgés de 35 à 65 ans ont été reçus dans notre service avec un tableau de choriorétinopathie séreuse centrale aiguë (3 cas) ou récidivante (1 cas), alors que, la même semaine, ils avaient reçu leur première injection du vaccin à ARN messager BNT162b2. Chez trois de ces sujets, des foyers hyper-réflectifs pouvaient être observés dans les couches externes de la rétine.
Conclusions. — La proximité temporelle entre la vaccination au BNT162b2 et l'apparition d'une choriorétinopathie séreuse centrale pourrait indiquer une relation causale. Ce lien, possible, demande à être confirmé par de plus larges études.
© 2022 Elsevier Masson SAS. Tous droits réservés.

Background

Severe acute respiratory syndrome coronavirus 2 (SARS-CoV-2) and its pandemic coronavirus disease 2019 (COVID-19) have led to accelerated vaccine development. The BNT162b2 messenger RNA (mRNA) vaccine has been widely administered in Israel [1—4]. At present, close to 6.7 million individuals of a population of 9.2 million have received at least one dose of the vaccine, as a fourth dose is currently being administrated to selected groups.

Central serous chorioretinopathy (CSC) is a multifactorial disease that causes central vision loss. It primarily affects men and has been demonstrated as early as 7 years and as late as 83 years of age. The peak incidence is between 40 to 50 years of age [5]. While advances in understanding the etiology and physiopathology of CSC have been made over the last decade the disease is not yet fully understood [6]. CSC has been strongly associated with elevated levels of endogenous and exogenous glucocorticoids [7], type-A ''tense obsessional'' or ''worrisome'' personalities, and high levels of psychological stress [8]. The presence of a thickened choroid is a key clinical finding [5,6,8]. SARS-CoV-2 itself has been suspected of triggering CSC [9—13].

CSC has been reported in association with anthrax [14], influenza [15] and smallpox [16] vaccinations. However, this association is rare and, before the advent of vaccination against SARS-CoV-2, only 6 cases of CSC as a possible consequence of vaccination were mentioned in the literature.

We report 4 individuals who presented to the Retina Clinic, three of whom demonstrated acute CSC and one who demonstrated a relapse of previously stable CSC, several days following administration of the first BNT162b2 vaccine.

Case series

Case 1

A 35-year-old male presented due to visual disturbances in his right eye 2 days after receiving the first dose of the BNT162b2 mRNA vaccine. Past medical and ocular history was unremarkable. On presentation, corrected distance visual acuity (CDVA) was 20/40 and 20/20 in the right and left eye respectively. Intraocular pressures (IOP) were 13 mmHg bilaterally. Slit-lamp examination of the anterior segment was normal. Funduscopic examination of the right eye showed sub-retinal fluid (SRF) on the nasal macula adjacent to the optic disc. The left fundus appeared normal. Optical Coherence Tomography (OCT) revealed a serous retinal detachment with SRF involving the fovea and the nasal aspect of the macula (Fig. 1A). Hyper-reflective foci were noted in the outer layers of the neurosensory retina along the detached retina (Fig. 1C). Enhanced Depth Imaging OCT (EDI-OCT) revealed a measured sub-foveal choroidal thickness (SFCT) of 452 μm in the right eye and 507 μm in the left eye (Fig. 1A and D). The subject was diagnosed with CSC and ophthalmologic examinations were advised. One week following diagnosis, symptoms and visual acuity remained unchanged and more SRF was visible in OCT imaging (Fig. 1B).

Case 2

A 45-year-old male presented with a one-month history of blurred vision in his right eye which began several days following the first dose of the BNT162b2 vaccine. According to

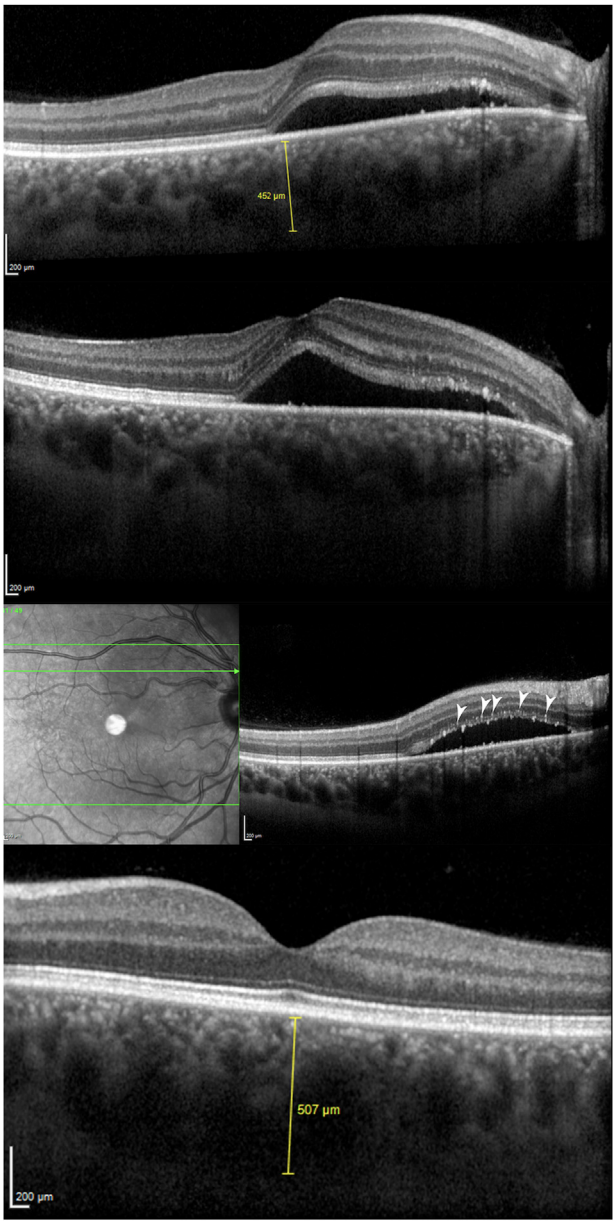

Figure 1. Enhanced Depth Imaging Optic Coherence Tomography (EDI-OCT) for patient 1. A. On presentation, right eye demonstrated SFCT of 452 µm, SRF under the fovea and nasal macula (B) worsening of the SRF. C. Horizontal scan superior to fovea demonstrating multiple hyper-reflective foci at the photoreceptor layers (arrowheads). D. Left eye on presentation which demonstrated SFCT of 507 µm with an attached flat retina.

the patient, no worsening of vision was noted after administration of the second dose of the vaccine, which he received 9 days prior to presentation. Past ocular history included CSC of the right eye diagnosed two years prior following an initial episode of serous retinal detachment that resolved after one month. The patient was being followed every 6 months and his ophthalmologic examination was stable. On admission, CDVA was 20/30 in his right eye and 20/20 in his left eye. IOP and slit-lamp examination of the anterior segment was normal. Funduscopic examination of the right eye demonstrated pigmentary changes at the fovea. OCT revealed a small pigment epithelial detachment (PED) under the fovea, with an adjacent small amount of SRF in the right eye (Fig. 2A). On the left eye, a very small serous retinal detachment nasal to the fovea was visualized (Fig. 2B). Bilateral OCT-Angiography (OCT-A) and fundus autofluorescence (FAF) were unremarkable. A diagnosis of CSC was made and observation was advised. Three weeks later visual acuity and clinical findings were unchanged, but worsening of the SRF on the EDI-OCT was seen. The SFCT measured 517 µm and 487 µm on the right and left eye respectively (Fig. 2C and D).

Case 3

A 65-year-old female presented to the Emergency Department complaining of 2 weeks of visual disturbances in her right eye. She reported symptoms beginning two days following administration of the first dose BNT162b2 mRNA vaccine. Past ocular history included dry macular degeneration in both eyes. On admission, CDVA was 20/50 and 20/20 in the right and left eye respectively. IOP measurements were 20 mmHg bilaterally. Slit-lamp examination was normal. Funduscopic examination of the right eye demonstrated hard drusen and a limited circular serous retinal detachment with SRF in the macula. Minimal hard drusen were evident in the left eye. On EDI-OCT of the right eye, SRF was present with a central foveal thickness of 514 µm. In addition, hyper-reflective foci in the outer neurosensory detached retina and small drusen were evident (Fig. 3A). SFCT measurements were 440 µm and 435 µm in the right and left eye respectively (Fig. 3A and B). OCT-A revealed an absence of flow at the level of the retinal pigment epithelium (RPE), without evidence of a choroidal neovascular membrane. On fluorescein angiography (FA) late phase, minimal pinpoint leakage superotemporal to the fovea was seen (Fig. 3C). A diagnosis of CSC was made and observation was advised. Subsequently, the patient received the second dose of the vaccine. At the two-month follow-up visit, CDVA had deteriorated to 20/70, and expansion of the serous retinal detachment was observed (Fig. 3D). En-face OCT revealed hyper-reflective foci at the outer nuclear layer segment (Fig. 3E).

Case 4

A 44-year-old male presented with a blurred vision of his right eye for one week. Ten days prior the patient had received the first BNT162b2 vaccine. Past medical history included anxiety treated with escitalopram 15 mg per day for 5 years and asthma treated with fluticasone furoate/vilanterol 100 mcg/25 mcg inhalation powder administered once every two days for one year. Past ocular history was unremarkable. On presentation, CDVA was 20/25 and 20/20 in his right and left eye, respectively. Slit-lamp and IOP examinations were normal. Fundoscopic examination of the right eye revealed a small circular serous retinal detachment involving the macula and was normal for the left eye. OCT of the right eye demonstrated SRF with a central foveal thickness of 391 µm, hyper-reflective foci in the outer neurosensory detached retina, and clumps at the level of the RPE (Fig. 4A). Steroid Inhalations were

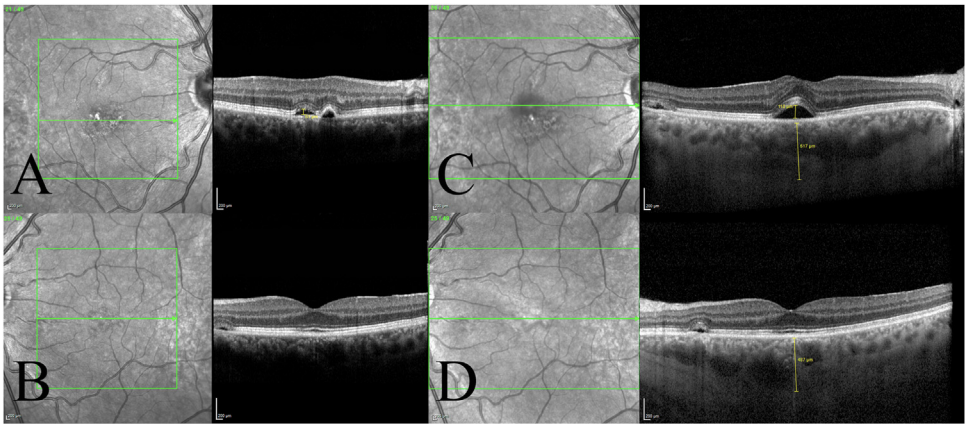

Figure 2. Optic Coherence Tomography (OCT) of patient 2. A. On presentation, the right eye demonstrated a focal pigment epithelium detachment with adjacent subretinal fluid inferior to the fovea. C. EDI-OCT of the right eye one month after presentation demonstrated worsening of the subretinal fluid and a thickened choroid measuring 517 μm. B. Left eye OCT demonstrated a para-foveal bleb with SRF on presentation (D) EDI-OCT of the left eye at follow-up demonstrated a thickened choroid of 487 μm.

discontinued. Subsequently, the patient received the second dose of the vaccine. At the one-month follow-up appointment, visual acuity was unchanged and SRF had improved slightly, with a central foveal thickness of 368 μm on OCT (Fig. 4B).

Discussion

The BNT162b2 mRNA vaccine introduces genetic material into cells generating a systemic humoral and cellular immune response [17].

Delbarre et al. reported the case of a healthy 38-year-old man, a military doctor, who presented with blurred central vision in the left eye 7 days after receiving the first dose of the Pfizer-BioNTech COVID-19 vaccine [18]. Dilated fundus exam of the left eye showed a serous macular neurosensory detachment, confirmed by OCT and fluorescein angiography. The authors acknowledge that it is not possible to confirm a causative link between CSCR and COVID-19 vaccine. However, they consider the timing between the first dose and the onset of symptoms as well as the low incidence of CSR (9.9 per 100,000 individuals) and the absence of risk factors for CSR development for their patient as a strong argument for a causal relationship.

Yu Lee et al. reported the case of a healthy 41-year-old Asian female who presented with disc edema in one eye and CSC in the other eye two days after receiving her first dose of another kind of COVID-19 vaccine (Vaxzevria, AstraZeneca) [19]. CSC gradually resolved, so that at three-month follow-up, no more serous detachment was detected.

In our report, three individuals presented with acute CSC and one with a previously diagnosed CSC relapse.

In all our subjects, like in those previously described by Delbarre and Yu Lee, symptoms began within one week following the first dose of the anti-SARS-CoV-2 vaccine. Similarly, our three subjects who had CSC diagnosed as a new condition had no other identifiable risk factors (cases 1—3). In all cases, clinical resolution resulted within three months, with variable or no visual sequelae.

Interestingly, three subjects (cases 1, 3 and 4) demonstrated hyper-reflective foci in the outer retinal layers. In 2005, Spaide & Klancnik hypothesized that hyper-reflective foci present in CSC may represent macrophages engorged with phagocytosed outer segments [20]. Wang et al. proposed that the mechanism of hyper-reflective foci may represent an agglutination of the outer segments of photoreceptors secondary to the leaking of plasma components following disruption of the outer blood-retina barrier [21]. Back then, OCT resolution limited the study of these observations. More recently, a study utilizing adaptive optics scanning light ophthalmoscopy and OCT, with enhanced resolution described findings in 5 individuals with CSC. The authors identified clusters resembling vessel-associated macrophages surrounding the inner retina capillaries that remain invisible to standard OCT resolution [22]. The identity and significance of the intraretinal hyper-reflective clusters are still unknown, but this may suggest the involvement of an immunologic mechanism in the physiopathology of CSC.

The proximity of the BNT162b2 mRNA vaccine in all our 4 subjects suggests that immunization triggered the development of CSC in these individuals. Other explanations for the development of CSC following the BNT162b2 mRNA vaccine include the effect of psychological stress and subsequent endogenous corticosteroid release surrounding vaccination which may have resulted in SRF accumulation. Additionally, diseases such as CSC may randomly relapse and remit, and this could have coincidentally occurred surrounding the vaccination.

As the COVID-19 vaccination campaign proceeds and many countries deliver booster shots, all individuals with known CSC or with any change in vision following immunization should be encouraged to promptly visit their treating ophthalmologist. As for other possible ocular complications [10,23,24], further research is necessary to explore the possible association between CSC and BNT162b2 mRNA vaccination.

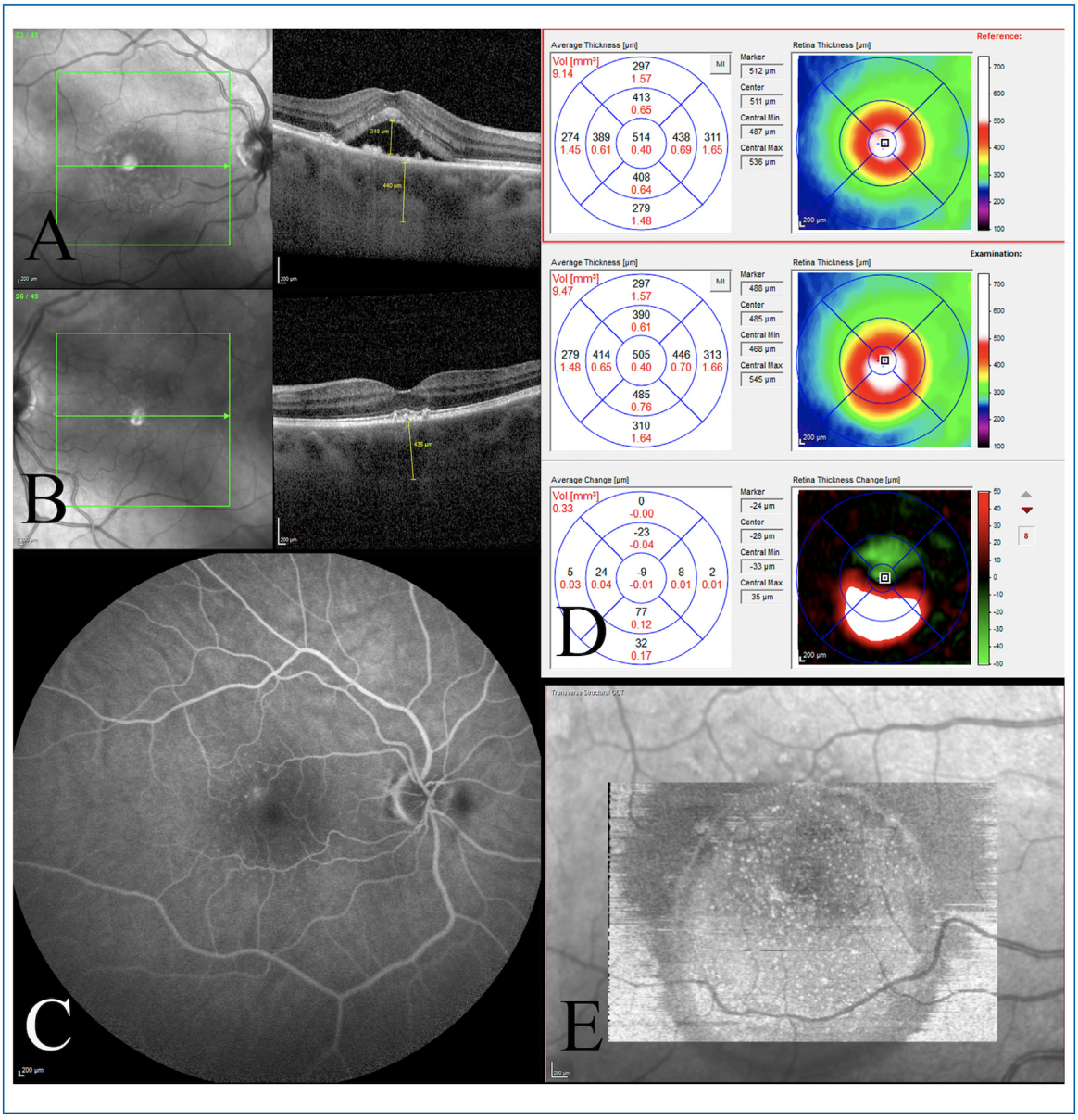

Figure 3. Multimodal imaging of patient 3. A. Right eye EDI-OCT on presentation demonstrated a SFCT of 440 µm, SRF, hyper-reflective foci at the outer retina and drusen. B. Left eye on presentation demonstrated SFCT of 435 µm and drusen. C. Late-stage FA demonstrated focal leakage superotemporal to the fovea. D. Worsening of SRF thickness inferior to fovea two months after presentation. E. En-face OCT of the outer nuclear layer demonstrated numerous hyper-reflective foci.

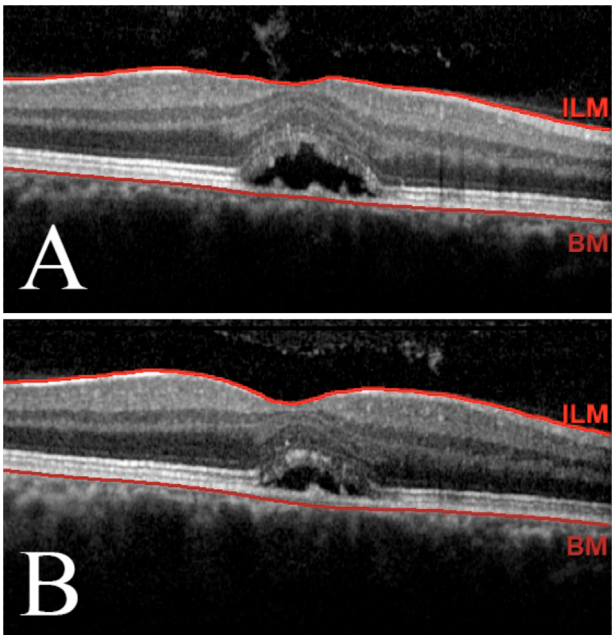

Figure 4. OCT of patient 4. A. Right eye OCT on presentation demonstrated SRF and hyper-reflective foci at the outer retina. B. Improvement of SRF one month following presentation.

Funding

None.

Disclosure of interest

The authors declare that they have no competing interest.

References

[1] Arbel R, Moore CM, Sergienko R, Pliskin J. How many lives do COVID vaccines save? Evidence from Israel. Am J Infect Control 2022;50:258—61, http://dx.doi.org/10.1016/j.ajic.2021.12.019. OPT: Epub 2021 Dec 29.
[2] Bar-On YM, Goldberg Y, Mandel M, Bodenheimer O, Freedman L, Kalkstein N, et al. Protection of BNT162b2 vaccine booster against COVID-19 in Israel. N Engl J Med 2021;385:1393—400.
[3] Barda N, Dagan N, Cohen C, Hernán MA, Lipsitch M, Kohane IS, et al. Effectiveness of a third dose of the BNT162b2 mRNA COVID-19 vaccine for preventing severe outcomes in Israel: an observational study. Lancet 2021;398:2093—100.
[4] Gurwitz D. COVID-19 vaccine hesitancy: lessons from Israel. Vaccine 2021;39:3785—6.
[5] van Rijssen TJ, van Dijk EHC, Yzer S, Ohno-Matsui K, Keunen JEE, Schlingemann RO, et al. Central serous chorioretinopathy: towards an evidence-based treatment guideline. Prog Retin Eye Res 2019;73:100770.
[6] Nicholson B, Noble J, Forooghian F, Meyerle C. Central serous chorioretinopathy: update on pathophysiology and treatment. Surv Ophthalmol 2013;58:103—26.
[7] Bouzas EA, Karadimas P, Pournaras CJ. Central serous chorioretinopathy and glucocorticoids. Surv Ophthalmol 2002;47:431—48.
[8] Scarinci F, Ghiciuc CM, Patacchioli FR, Palmery M, Parravano M. Investigating the hypothesis of stress system dysregulation as a risk factor for central serous chorioretinopathy: a literature mini-review. Curr Eye Res 2019;44:583—9.
[9] Abrishami M, Daneshvar R, Shoeibi N, Saeedian N, Heidarzadeh HR, Hosseini SM. Pachychoroid spectrum disorder findings in patients with coronavirus disease 2019. Case Rep Ophthalmol Med 2021;2021:4688764.
[10] Goyal M, Murthy SI, Annum S. Retinal manifestations in patients following COVID-19 infection: a consecutive case series. Indian J Ophthalmol 2021;69:1275—82.
[11] Mahjoub A, Dlensi A, Romdhane A, Ben Abdesslem N, Mahjoub A, Bachraoui C, et al. Bilateral central serous chorioretinopathy post-COVID-19. J Fr Ophtalmol 2021;44:1484—90.
[12] Sanjay S, Gowda PB, Rao B, Mutalik D, Mahendradas P, Kawali A, et al. 'Old wine in a new bottle — post COVID-19 infection, central serous chorioretinopathy and the steroids. J Ophthalmic Inflamm Infect 2021;11:14.
[13] Tohamy D, Sharaf M, Abdelazeem K, Saleh MGA, Rateb MF, Soliman W, et al. Ocular manifestations of post-acute COVID-19 syndrome, upper Egypt early report. J Multidiscip Healthc 2021;14:1935—44.
[14] Foster BS, Agahigian DD. Central serous chorioretinopathy associated with anthrax vaccination. Retina 2004;24:624—5.
[15] Palacios AI, Rodríguez M, Martín MD. Central serous chorioretinopathy of unusual etiology: a report of 2 cases. Arch Soc Esp Oftalmol 2014;89:275—8.
[16] Rosen E. The significance of ocular complications following vaccination. Br J Ophthalmol 1949;33:358—68.
[17] Jhaveri R. The COVID-19 mRNA vaccines and the pandemic: do they represent the beginning of the end or the end of the beginning? Clin Ther 2021;43:549—56.
[18] Delbarre M, Maréchal M, Froussart-Maille F. Central serous chorioretinopathy following Pfizer-BioNTech COVID-19 vaccine: a case report. J Fr Ophtalmol 2022;45:e1—2, http://dx.doi.org/10.1016/j.jfo.2021.11.003. Epub 2021 Dec 10.
[19] Lee DY, Wu HJ, Cheng KC, Chang YC. Disc edema in one eye and central serous chorioretinopathy in the other eye shortly after AstraZeneca COVID-19 vaccination. Kaohsiung J Med Sci 2022;38:283—5, http://dx.doi.org/10.1002/kjm2.12473. Epub 2021 Nov 16.
[20] Spaide RF, Klancnik Jr JM. Fundus autofluorescence and central serous chorioretinopathy. Ophthalmology 2005;112:825—33.
[21] Wang M, Sander B, la Cour M, Larsen M. Clinical characteristics of subretinal deposits in central serous chorioretinopathy. Acta Ophthalmol Scand 2005;83:691—6.
[22] Vogel RN, Langlo CS, Scoles D, Carroll J, Weinberg DV, Kim JE. High-resolution imaging of intraretinal structures in active and resolved central serous chorioretinopathy. Invest Ophthalmol Vis Sci 2017;58:42—9.
[23] Rabinovitch T, Ben-Arie-Weintrob Y, Hareuveni-Blum T, Shaer B, Vishnevskia-Dai V, Shulman S, et al. Uveitis after the BNT162b2 mRNA vaccination against SARS-CoV-2 infection: a possible association. Retina 2021;41:2462—71.
[24] Bolletta E, Iannetta D, Mastrofilippo V, De Simone L, Gozzi F, Croci S, et al. Uveitis and other ocular complications following COVID-19 vaccination. J Clin Med 2021;10:5960, http://dx.doi.org/10.3390/jcm10245960.