Since January 2020 Elsevier has created a COVID-19 resource centre with free information in English and Mandarin on the novel coronavirus COVID-19. The COVID-19 resource centre is hosted on Elsevier Connect, the company's public news and information website.

Elsevier hereby grants permission to make all its COVID-19-related research that is available on the COVID-19 resource centre - including this research content - immediately available in PubMed Central and other publicly funded repositories, such as the WHO COVID database with rights for unrestricted research re-use and analyses in any form or by any means with acknowledgement of the original source. These permissions are granted for free by Elsevier for as long as the COVID-19 resource centre remains active.

American Journal of Ophthalmology Case Reports 26 (2022) 101522

Contents lists available at ScienceDirect

American Journal of Ophthalmology Case Reports

journal homepage: www.ajocasereports.com/

CRVO associated with COVID-19 and MTHFR mutation in a 15-year-old male

Patrick C. Staropoli [a], Alison Payson [b], Catherin I. Negron [a], Supalert Prakhunhungsit [a,c], Pablo Laufer [b], Audina M. Berrocal [a,*]

[a] Department of Ophthalmology, Bascom Palmer Eye Institute, University of Miami Miller School of Medicine, 900 NW 17th Street. Miami, FL, 33136, USA
[b] Department of Pediatrics, Nicklaus Children's Hospital, 3100 SW 62nd Ave. Miami, FL, 33155, USA
[c] Department of Ophthalmology, Siriraj Hospital, Mahidol University, 2 Thanon Wang Lang, Siri Rat, Bangkok Noi, Bangkok, 10700, Thailand

ARTICLE INFO

Keywords:
COVID-19
Central retinal vein occlusion
MTHFR
Gene
Mutation
Neuroretinitis

ABSTRACT

Purpose: To report a case of a central retinal vein occlusion (CRVO) associated with COVID-19 in a patient predisposed to clotting due to a genetic mutation in methylenetetrahydrofolate reductase (MTHFR).

Observations: A 15-year-old male presented with 1 day of painless blurry vision in the left eye. Exam disclosed trace anterior chamber cell, anterior vitreous cell, optic nerve head edema, temporally displaced macular star, dilated tortuous veins, and diffuse intraretinal hemorrhages. Exam and FA was consistent with CRVO, however the macular star and OCT were suggestive of a neuroretinitis.

The patient then presented to a children's hospital for further evaluation. A routine screen for COVID-19 via nasopharyngeal swab was positive with a high viral load. He also had a known history of an MTHFR mutation. Extensive laboratory and neuroradiologic evaluation excluded other infectious, inflammatory, and coagulopathic etiologies.

Conclusions and Importance: This is a case of CRVO associated with COVID-19 infection and an underlying systemic hypercoagulable mutation, with an initial presentation that mimicked neuroretinitis. This case provides valuable diagnostic learning points and expands our knowledge of possible ocular complications of COVID-19.

1. Introduction

The association between COVID-19 and hypercoagulability has been well described.[1] The virus, which has totaled 172.7 million cases worldwide and 3.7 million deaths as of June 2021,[2] can lead to acute respiratory distress syndrome (ARDS) and multi-organ failure. Venous thromboembolism has been noted in severe cases, likely due to a combination of endothelial injury, stasis, and hypercoagulability in a severe inflammatory state.[3] While pulmonary embolism (PE) and deep vein thrombosis (DVT) are the most common coagulopathic complications, there is also an increased risk of stroke, myocardial infarction, and limb ischemia.

Methylenetetrahydrofolate reductase (MTHFR) is a gene responsible for an enzyme that helps metabolize folate. In genetic variants that significantly compromise MTHFR function, homocysteine accumulates systemically. This can lead to abnormal clotting, developmental delay, seizures, intellectual disability, and microcephaly.[4]

Central retinal vein occlusion (CRVO) is a common cause of unilateral vision loss associated with age, hypertension, diabetes, and glaucoma. More rarely, CRVO can occur in young people, typically in association with a hypercoagulable state.[5]

We present the case of a 15-year-old male with acute COVID-19 infection, MTHFR mutation, and unilateral CRVO.

2. Case report

A 15-year-old male presented with 1 day of painless blurry vision in the left eye upon awakening. He was born at 36 weeks via emergent c-section due to placental detachment and stayed in the neonatal ICU for 2 weeks with pneumothorax. He is homozygous for a methylenetetrahydrofolate reductase (MTHFR) mutation carried by both of his parents. His paternal grandmother had a pulmonary embolism. Otherwise the past medical, surgical, and developmental history was unremarkable. Last eye exam 5 months prior was normal. There were several stray cats in his neighborhood, and history of a scratch by his dog. Initial exam disclosed 20/20 vision in the right eye and "E" at 2 feet in the left eye. No

* Corresponding author. Bascom Palmer Eye Institute, 900 NW 17th Avenue, Miami, FL, 33136, USA.
E-mail address: aberrocal@med.miami.edu (A.M. Berrocal).

https://doi.org/10.1016/j.ajoc.2022.101522
Received 20 July 2021; Received in revised form 13 March 2022; Accepted 1 April 2022
Available online 20 April 2022
2451-9936/© 2022 Published by Elsevier Inc. This is an open access article under the CC BY-NC-ND license (http://creativecommons.org/licenses/by-nc-nd/4.0/).

afferent pupillary defect was noted; Ishihara testing was normal, and motility was full. Exam was normal in the right eye. The left eye had trace anterior chamber cell, 2+ anterior vitreous cell, 4+ optic nerve head edema with diffuse peripapillary flame hemorrhages, temporally displaced macular star, dilated tortuous veins, and diffuse intraretinal hemorrhages (Fig. 1). MRI showed enhancement of the left optic nerve head and possible bilateral FLAIR abnormalities (Fig. 2). Optical coherence tomography (OCT) demonstrated exudate, intraretinal fluid, and subretinal fluid (Fig. 1). Fluorescein angiography (FA) showed delayed arteriovenous transit time, hyperfluorescence of the disc, vessel wall staining, and capillary nonperfusion (Fig. 1). Doxycycline 100mg twice daily was started empirically as well as prednisolone drops 4 times daily. Complete blood count, comprehensive metabolic panel, syphilis titers (RPR/FTA), and quantiferon gold were negative. Bartonella titers were obtained and pending.

The patient presented one day later to a children's hospital for further evaluation. He was COVID-19 positive on a routine reverse transcription-polymerase chain reaction (RT-PCR) screen for SARS-CoV-2 from a nasopharyngeal swab. He had no fever, respiratory symptoms, or known exposures. However, his cycle threshold (CT) was 23.4, indicating a high viral load. He was admitted to the COVID unit. MRA, MRV, and MRI spine were noncontributory. Further lab workup was negative, including: COVID-19 IgG, homocysteine, angiotensin converting enzyme, lyme, toxoplasma (IgM/IgG), toxocara, cytomegalovirus (IgM/IgG), epstein barr virus, platelets, partial thromboplastin time (PTT), prothrombin time/international normalized ratio (PT/INR), factor V leiden, protein C, protein S, prothrombin gene mutation, anticardiolipin, antithrombin III, and D-dimer. The patient was discharged on prophylactic enoxaparin sodium dosing and doxycycline was discontinued when initial Bartonella titers returned negative. He followed up 2 weeks later in the ophthalmology clinic and received 1.25mg/0.05mL intravitreal bevacizumab for persistent macular edema (Fig. 3). Doxycycline was restarted and continued until repeat Bartonella serology was negative. The patient's family also obtained a negative bartonella serology on their dog. At last follow up, vision improved to 20/200, macular edema resolved (Fig. 3), and the decision was made to observe.

3. Discussion

This case is unique due to its novel presentation and diagnostic dilemmas. It was presumed that the intraretinal fluid and nerve edema must have been more chronic than the symptoms given that a macular star had already formed. In addition, there was significantly more subretinal fluid on OCT than normally expected for a CRVO. Given these findings, the working hypothesis was an underlying neuroretinitis caused chronic nerve head edema, ultimately leading to a CRVO with a sharp decrease in vision that prompted initial presentation. Neuroretinitis associated CRVO is a known, but rare, entity.[6] There is also a high rate of false negative bartonella titers at disease onset. For this reason, doxycycline was continued until repeat titers were confirmed negative. The family also obtained negative bartonella serologies on their dog. Dogs are reservoirs for multiple strains of human-pathogenic bartonella, however transmission to humans has not been documented.[7] The questionable FLAIR abnormalities on initial MRI (Fig. 2) were later confirmed to be normal variants likely representing terminal zones of myelination. Further imaging, including MRI spine, was negative for a demyelinating process. The patient had no other risk factors for CRVO. He had a normal BMI (23.72 kg/m^2), was not taking contributory medications (i.e. diuretics, sympathomimetics, or antipsychotics), and had no hypertension, hyperlipidemia, or smoking history.

With alternative etiologies ruled out, this CRVO may have been due to acute COVID-19 infection in a patient with an MTHFR mutation that predisposed him to clotting. Several studies have reported on presumptive ocular complications of COVID-19, including conjunctivitis,[8] paracentral acute middle maculopathy (PAMM),[9] cotton wool spots, and microhemorrhages.[10] However, CRVO associated with COVID-19 is rare. Reports about it have mostly relied on a temporal relationship between systemic symptoms and vision loss. For example, Yahalmoi et al. (2020) documented a 33-year-old healthy male with CRVO two weeks after upper respiratory symptoms and a positive SARS-CoV-2 IgG.[11] Walinjkar et al. (2020) reported a 17-year-old female with CRVO three weeks after fever and cough with a positive SARS-CoV-2 IgG and ground glass opacities on CT chest.[12] Finally, Raval et al. (2021) described a 39-year-old febrile male with CRVO one week after testing positive on RT-PCR.[13] In all of these cases, the hypercoagulable workup

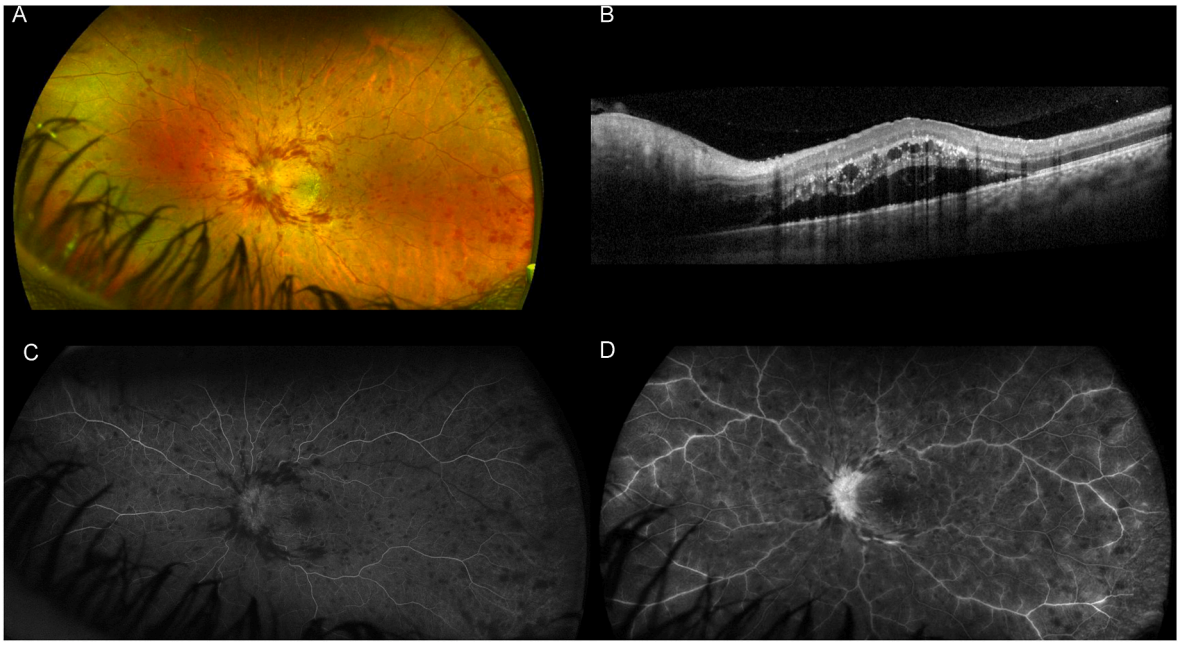

Fig. 1. Presentation (A) Fundus photograph of the left eye with 4+ optic nerve head edema, peripapillary flame hemorrhages, macular star, dilated tortuous veins, and diffuse intraretinal hemorrhages. (B) OCT with exudate, intraretinal, and subretinal fluid with prominent posterior hyaloid. (C) FA at 28.6 seconds showing delayed arteriovenous transit time. (D) Late FA with hyperfluorescence of the disc, vessel wall staining, and capillary nonperfusion.

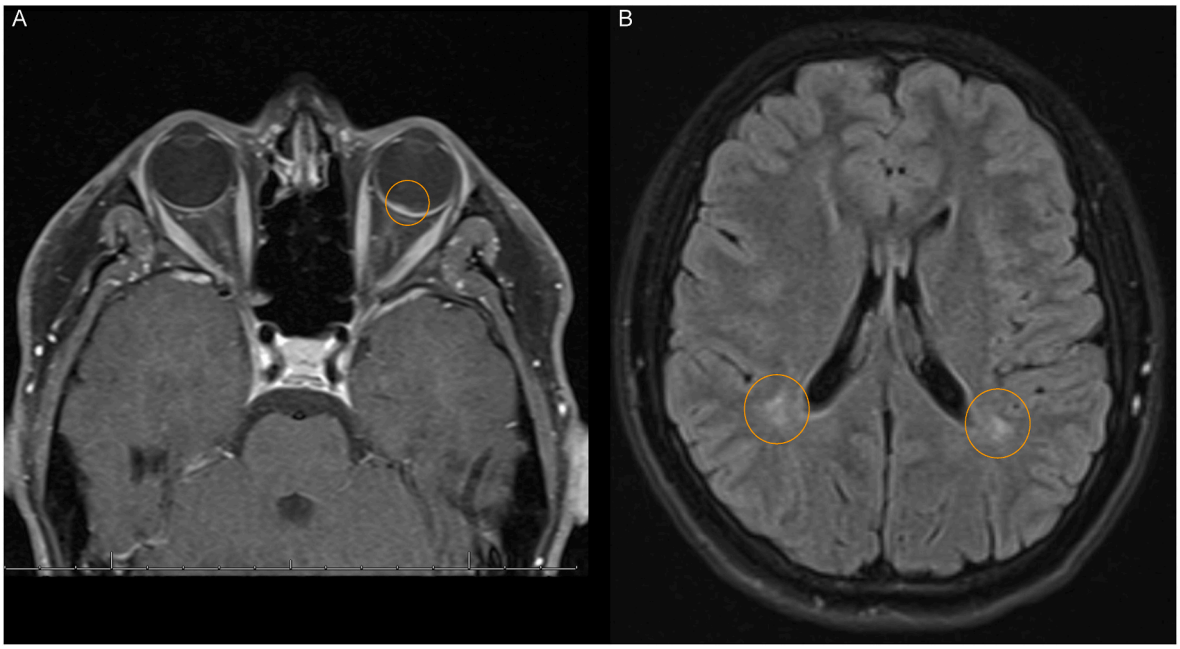

Fig. 2. Neuroimaging (A) Axial post-contrast T1 MRI Orbits with fat suppression showing enhancement of the left optic nerve head (circled). (B) Axial FLAIR sequence showing bilateral FLAIR signal abnormalities (circled) likely a normal variant of terminal zones of myelination.

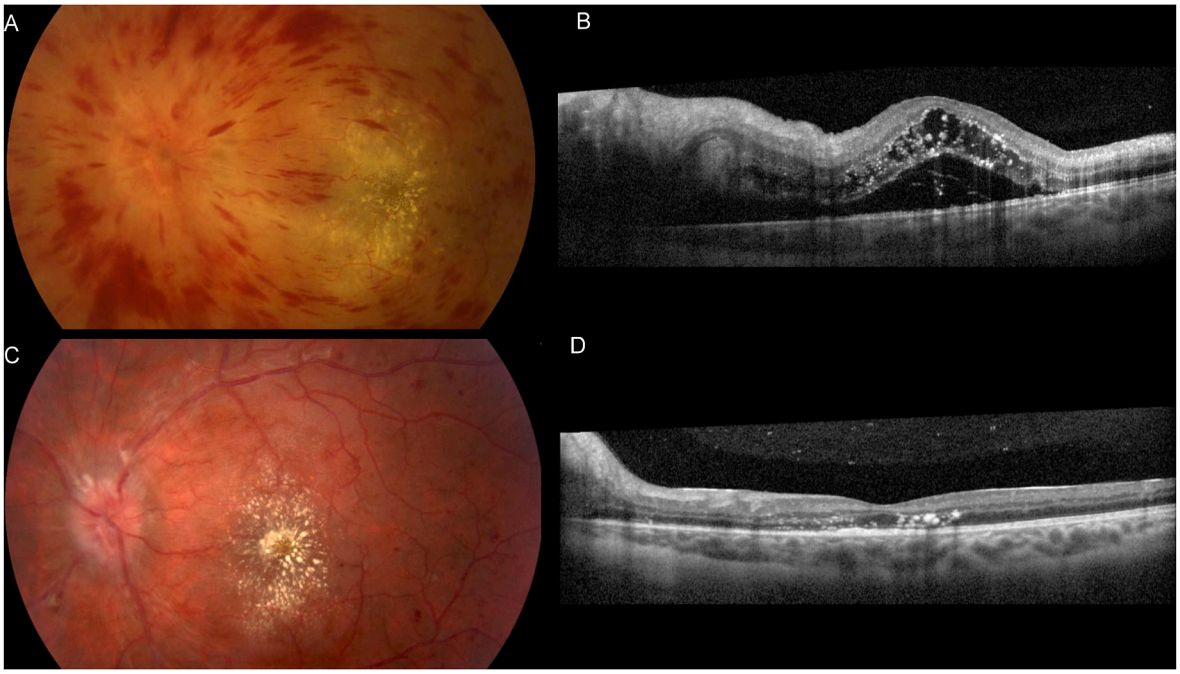

Fig. 3. Follow-up (A + B) Fundus photograph and OCT 2 weeks after presentation demonstrating persistent macular edema and subretinal fluid. (C + D) Fundus photograph and OCT 4 weeks after intravitreal bevacizumab with improvement in nerve edema, venous dilation, and retinal hemorrhages. There is consolidation of the macular star and corresponding resolution of intraretinal and subretinal fluid on OCT.

was negative. Similarly, our patient did not have an increased D-dimer, thrombocytosis, alteration in PT/PTT/INR, or evidence of DVT or PE as reported in COVID-19 patients with coagulopathic sequelae.[3] However, the current case is unique because our patient presumably had an acute infection, suggested by a very high viral load on RT-PCR and negative SARS-CoV-2 IgG. In addition, he had a genetic mutation in which one would expect elevated homocysteine levels, but they were normal. Different mutations in MTHFR can have varying effects on enzymatic function and homocysteine levels (in addition to possible fluctuations with time). If homocysteine was elevated, it would help confirm the mutation as a contributory factor; yet the fact that it was normal does not completely exclude it.

In regards to anticoagulation in CRVO, the ophthalmic literature suggests that antiplatelet and anticoagulant therapies do not prevent ocular complications of vein occlusions and may actually portend a worse visual outcome.[14] However, the hematology-oncology service started the patient on prophylactic lovenox due to suspicion for systemic hypercoagulability induced by COVID-19 and the MTHFR mutation. The

patient has not had any further coagulopathic sequelae. In terms of ophthalmic treatment, the macular edema improved after one injection of bevacizumab. However, extensive exudative changes cause the visual prognosis to be guarded at this time.

This is a case of CRVO associated with acute COVID-19 infection, an underlying systemic hypercoagulable mutation, and an initial presentation that mimicked neuroretinitis. This case adds to the literature on possible ocular complications of COVID-19 and provides several high-yield learning points given the initial diagnostic uncertainty.

Patient consent

The patient's parent/legal guardian consented to publication of the case in writing/orally.

Funding

This work was partially supported by the Heed Foundation. The funding source had no role in the study design; in the collection, analysis and interpretation of data; in the writing of the report; and in the decision to submit the article for publication.

Authorship

All authors attest that they meet the current ICMJE criteria for Authorship.

CRediT authorship contribution statement

Patrick C. Staropoli: Conceptualization, Writing – original draft, Writing – review & editing. **Alison Payson:** Conceptualization, Writing – review & editing. **Catherin I. Negron:** Conceptualization, Writing – review & editing. **Supalert Prakhunhungsit:** Conceptualization, Writing – review & editing. **Pablo Laufer:** Supervision, Conceptualization, Writing – review & editing. **Audina M. Berrocal:** Supervision, Conceptualization, Writing – review & editing.

Declaration of competing interest

None.

Acknowledgements

None.

References

1. Abou-Ismail MY, Diamond A, Kapoor S, Arafah Y, Nayak L. The hypercoagulable state in COVID-19: incidence, pathophysiology, and management. *Thromb Res*. 2020;194:101–115.
2. COVID-19 Dashboard by the Center for Systems Science and Engineering (CSSE) at Johns Hopkins University (JHU). ArcGIS. Johns Hopkins University. Available at https://coronavirus.jhu.edu. Accessed June 5, 2021.
3. Bilaloglu S, Aphinyanaphongs Y, Jones S, Iturrate E, Hochman J, Berger JS. Thrombosis in hospitalized patients with COVID-19 in a New York city health system. *JAMA*. 2020;324(8):799.
4. Undas A, Brozek J, Szczeklik A. Homocysteine and thrombosis: from basic science to clinical evidence. *Thromb Haemostasis*. 2005;94(5):907–915.
5. Lahey JM, Tunç M, Kearney J, et al. Laboratory evaluation of hypercoagulable states in patients with central retinal vein occlusion who are less than 56 years of age. *Ophthalmology*. 2002;109(1):126–131.
6. Ghadiali Q, Ghadiali LK, Yannuzzi LA. Barontella henselae neuroretinitis associated with central retinal vein occlusion, choroidal ischemia, and ischemic optic neuropathy. *Retin Cases Brief Rep*. 2020;14(1):23–26.
7. Chomel BB, Boulouis HJ, Maruyama S, Breitschwerdt EB. Bartonella spp. in pets and effect on human health. *Emerg Infect Dis*. 2006;12(3):389–394.
8. Ozturker ZK. Conjunctivitis as sole symptom of COVID-19: a case report and review of literature. *Eur J Ophthalmol*. 2021;31(2):161–166.
9. Virgo J, Mohamed M. Paracentral acute middle maculopathy and acute macular neuroretinopathy following SARS-CoV-2 infection. *Eye*. 2020;34:2352–2353.
10. Marinho PM, Marcos AA, Romano AC, Nascimento H, Belfort R. Retinal findings in patients with COVID-19. *Lancet*. 2020;395(10237):1610.
11. Yahalomi T, Pikkel J, Arnon R, Pessach Y. Central retinal vein occlusion in a young healthy COVID-19 patient: a case report. *Am J Ophthalmol Case Rep*. 2020;20, 100992.
12. Walinjkar JA, Makhija SC, Sharma HR, Morekar SR, Natarajan S. Central retinal vein occlusion with COVID-19 infection as the presumptive etiology. *Indian J Ophthalmol*. 2020;68(11):2572–2574.
13. Raval N, Djougarian A, Lin J. Central retinal vein occlusion in the setting of COVID-19 infection. *J Ophthal Inflamm Infect*. 2021;11:10.
14. Hayreh SS, Podhajsky PA, Zimmerman MB. Central and hemicentral retinal vein occlusion: role of anti-platelet aggregation agents and anticoagulants. *Ophthalmology*. 2011;118(8):1603–1611.