DOI:10.14744/bej.2021.60590
Beyoglu Eye J 2022; 7(1): 39-46

Original Article

Multifocal Electroretinogram Alterations after Intravitreal Ranibizumab Treatment in Diabetic Macular Edema

Sema Tamer Kaderli,[1] Dicle Hazirolan,[2] Guner Uney,[2] Ahmet Kaderli,[1] Nurten Unlu,[2] Mehmet Akif Acar,[2] Firdevs Ornek[2]

[1]Department of Ophthalmology, Mugla Training and Research Hospital, Mugla, Turkey
[2]Department of Ophthalmology, University of Health Sciences Ankara Training and Research Hospital, Ankara, Turkey

Abstract

Objectives: To assess multifocal electroretinogram (mf-ERG) values in patients with diabetic macular edema (DME) who were treated with intravitreal ranibizumab (IVR).

Methods: Thirty eyes of patients with DME, who underwent three consecutive monthly injections of IVR and as required thereafter, were evaluated. Best corrected visual acuity (BCVA) (log MAR), optical coherence tomography (OCT) features [diameters of cyst and subretinal fluid, hyperreflective dots (HRDs)], and mf-ERG were evaluated at baseline, 1 month, and 6 months throughout the follow-up period. The correlation of mf-ERG values and OCT features, BCVA, and the duration of disease were investigated.

Results: In the study group, the baseline P1 and N1 amplitudes were significantly lower than the control group, and P1 and N1 implicit times were significantly higher in patients with DME than in the control group in all rings (All $p<0.05$) The mean response density (P1 amplitude, nV/deg^2) values increased over 6 months in rings 1, 2, and 3 ($p<0.001$, $p=0.003$, $p=0.006$). There was a negative correlation between the diameter of the cyst and the initial response density of P1 (for horizontal diameter: $r=-0.658$, $p=0.03$; for vertical diameter: $r=-0.597$, $p=0.037$; for the area of the cyst, $r=-0.603$, $p=0.021$). There was a significant negative correlation between the subretinal fluid and HRD reduction and the response density of P1 increase (all $p<0.05$). At baseline and 6 months, the correlation between BCVA and the P1 and N1 amplitude of the central ring was significant (for baseline P1: $r=-0.649$, $p=0.01$; for N1: $r=-0.575$, $p=0.02$; for 6-month P1, $r=-0.603$, $p<0.001$; for N1: $r=-0.591$, $p=0.005$).

Conclusion: The combination of OCT and mf-ERG can be used to evaluate the functional recovery in DME.

Keywords: Diabetic macular edema, multifocal electroretinogram, optical coherence tomography, ranibizumab

Introduction

Diabetic macular edema (DME) is one of the main causes of low visual acuity in patients with diabetic retinopathy (DR) (1). Intravitreal injection of bevacizumab (2, 3), ranibizumab (4), and aflibercept (5) were recommended for the treatment of DME, which often achieved a better visual acuity gain. The anatomical healing could be monitored via optical coherence tomography (OCT) (6). However, despite the anatomical success and decrease of macular edema, some patients have a poor functional recovery.

Multifocal electroretinography (mf-ERG) allows us to assess the retinal electrophysiological activity and present a topographic map. It can record focal electroretinography re-

How to cite this article: Tamer Kaderli S, Hazirolan D, Uney G, Kaderli A, Unlu N, Acar MA, et al. Multifocal Electroretinogram Alterations after Intravitreal Ranibizumab Treatment in Diabetic Macular Edema. Beyoglu Eye J 2022; 7(1): 39-46.

Address for correspondence: Sema Tamer Kaderli, MD. Mugla Eğitim ve Arastirma Hastanesi, Mugla, Turkey
Phone: +90 507 411 01 29 **E-mail:** sematamerkaderli@hotmail.com

Submitted Date: January 26, 2021 **Accepted Date:** December 16, 2021 **Available Online Date:** February 18, 2022

©Copyright 2022 by Beyoglu Eye Training and Research Hospital - Available online at www.beyoglueye.com
OPEN ACCESS This work is licensed under a Creative Commons Attribution-NonCommercial-ShareAlike 4.0 International License.

sponses concurrently from different regions in the central 40° to 50° of the retina (7). It is practiced following the light adaptation to reach an electrophysiological response from the cones (8, 9). Previous studies have shown that mf-ERG parameters were significantly altered in diabetic patients without DR. Bearse et al. expressed a model based on the mf-ERG replies to predict the progress of DR (10–13).

We assumed that mf-ERG combined with OCT might be used to improve our knowledge of physiological mechanisms associated with the response to treatment by the electrophysiological values of the macula. In this study, we aimed to evaluate the alterations in mf-ERG values before and after intravitreal ranibizumab (IVR) and investigate which of the OCT features represented more functional recovery in DME.

Methods

Type 2 DM patients with naive DME, who were diagnosed with clinically significant macular edema, were included in this study. This cross-sectional observational study was conducted from January 2016 to October 2016. All of the eyes had early DR (mild to moderate nonproliferative DR). Exclusion criteria were corneal opacity, cataract, vitreous opacity, macular ischemia or disruption of the foveal avascular zone (FAZ) in fundus fluorescein angiography (FFA), irregularity of EZ and ELM, vitreomacular traction, vitreous hemorrhage, history of aged-related macular degeneration, retinal vascular occlusions, uveitis, and glaucoma. Demographic information, disease duration, and treatment follow-ups were taken from the individuals' records. Best corrected visual acuity (BCVA) was expressed as the logarithm of the minimum angle of resolution (log MAR).

After three doses of monthly injections, IVR was repeated when there was a decrease of 5 letters in BCVA and/or an increase over 100 µm in central macular thickness (CMT) at OCT. The efficacy of the treatment was assessed by comparing visual acuity and mf-ERG findings before and after 1 month and 6 months of treatments. The correlation between OCT findings and mf-ERG was investigated according to the treatment response.

After ophthalmological examination, including BCVA, slit-lamp biomicroscopy, and fundus examination (90D, Volk lens, Nixon), the macula was examined using OCT (Spectralis®, Heidelberg Engineering, Heidelberg, Germany). FFA (Zeiss, Visucam 500, Germany) was performed to evaluate the perfusion of the macula, the FAZ, or any neovascularization before treatment.

We classified the type of DME as having diffuse, cystic, or with serous retinal detachment as previously described (14). The cyst was represented as round or oval-shaped hyporeflective areas separated by hyperreflective septa. In this study, we used the largest cystoid space within 1000 µm of the foveal center as representative of the most affected region. The horizontal and vertical diameters of the largest cyst, the area of the cyst, and subretinal fluid height were defined in the quantitative outcomes of the study. All measurements were performed by the same researcher with a manual caliper. The number of hyperreflective dots (HRDs) was manually counted (15).

mf-ERG was taped using RETI-scan (Roland Consult, Wiesbaden, Germany). During recording, flat and 50 Hz filters were used. Using the concentric ring analysis, the averages of the P1 amplitude and P1 latency of the "first-order kernel" wave in each ring were calculated. Retina areas of the ring in order from the central to the periphery are as follows: the first ring has an area of 0°–2.1°, the second ring has an area of 1.4°–6.7°, the third ring has an area of 5.7°–12.0° field. We obtained P1 response density (nV/deg^2), P1 amplitude (µV), P1 implicit time (ms), N1 amplitude (µV), and N1 implicit time (ms) values from central three rings. The response density is the amplitude represented per unit of the area measured in nanovolts per square degree (nV/deg^2). It quantifies the amplitude achieved in each ring, considering its size. Ring 1 (foveal region) has the highest cone density, highest response density in healthy eyes, and lowest eccentricity because the cone density is decreased by a similar dimension. The implicit time is the time that leads to reaching the maximum amplitude in the macula examined. The mf-ERG records of the patients were compared with age-matched healthy eyes (control group) and evaluated before, at 1 month, and 6 months after treatment.

SPSS v.14.01 for Windows software (SPSS, Chicago, IL) was used. All values were presented as mean±standard error of the mean. Variables that were quantitative in the form of measurement were checked by the Shapiro–Wilk test for the normality hypothesis. Differences between the control group and the study group were examined using the independent Student's t-test. Repeated-measures analysis of variance and paired t-test were used to estimate the differences among injections. Fischer's exact test was used in cases where the expected number of cells in the 2 × 2 contingency table was less than 5% of the total cells for categorical data. Also, according to the change in the response density of P1 for the mean of the rings, the general linear modeling technique for repeated measurements was used to examine the significance of the change in time for the groups. For significant interaction terms, simple effects analysis was performed with Bonferroni correction as post hoc procedure. For continuous quantitative data, we used Pearson's parametric coefficient. $P<0.05$ was considered statistically significant.

Results

The baseline characteristics of the 30 eyes of 30 enrolled patients are shown in Table 1. All patients had type 2 DM, nonproliferative DR. None of the patients had macular ischemia on FFA images, and all patients had intact FAZ. The mean number of IVR was 4.6±1.1 (min–max: 3–6). The duration of diabetes mellitus ranged from 6 to 20 years. The mean systolic and diastolic blood pressure values were 134.4±11.7 and 82.3±8.7 mmHg, respectively.

Table 1. Demographic data of the patients in the study

Variable	Value
Mean age, y±SD	60.37±10.34
Sex, n (F/M)	16/14
Mean duration of DM±SD	13.7±5.8
Treatment with insulin/only OAD	20/10
Mean HbA1c±SD	7.04±1.7
Systemic hypertension, n	17 (56.6%)
DR level, n	
Mild	18 (60%)
Moderate	12 (40%)

DM: Diabetes mellitus; OAD: Oral antidiabetic; n: Number; SD: Standard deviation; DR: Diabetic retinopathy.

In the study group, the baseline P1 and N1 amplitudes were significantly lower than the control group, and P1 and N1 implicit times were significantly higher in patients with DME than control group in all rings (Table 2). There was a negative correlation between the duration of disease and baseline P1 amplitudes in ring 1 and ring 2 (ring 1: r=−0.657, p=0.04; ring 2: r=−0.565, p=0.05).

BCVA, CMT, and mf-ERG parameters in the study group at specific time points are summarized in Table 3. The CMT decreased from 455.03±16.06 µm to 328.5±10.39 µm, and the mean BCVA score of the patients increased from 0.53±0.08 log MAR to 0.31±0.06 log MAR through 6 months after IVR treatment (p<0.001, p<0.001). The mean response density of the P1 waves in all rings significantly increased through 6 months after IVR treatment. However, implicit time did not change significantly (Table 3). We also observed the healing by means of the trace array on topographical maps of the mf-ERG (Fig. 1). All changes in terms of BCVA, CMT, P1 amplitude, and response density are shown in Figure 2 through the follow-up time. The correlation between the reduction of CMT and the increase of P1 response density was not significant (r=0.022, p=0.908).

Table 2. Comparison of mean mf-Erg values between the patients with DME and control group at baseline

	Baseline	Control	p^B
Ring 1			
P1 Amp(Nv/deg^2)	63.35±22.9	80.85±5.2	<0.001
P1Amp (µv)	0.995±0.37	1.391±0.05	<0.001
P1implicit time (ms)	38.51±3.6	32.71±0.47	<0.001
N1Amp (µv)	0.34±0.18	0.56±0.01	0.003
N1 implicit time (ms)	18.84±3.5	16.44±0.55	0.03
Ring 2			
P1 Amp(Nv/deg^2)	43.32±11.9	50.82±3.1	<0.001
P1Amp (µv)	1.004±0.3	1.324±0.07	<0.001
P1 implicit time (ms)	35.12±2.5	33.02±0.25	0.02
N1Amp (µv)	0.317±0.09	0.747±0.03	0.006
N1 implicit time (ms)	16.70±1.9	15.40±0.37	0.054
Ring 3			
P1 Amp(Nv/deg^2)	26.27±1.1	30.47±1.1	0.001
P1Amp (µv)	0.882±0.21	1.101±0.04	0.051
P1 implicit time (ms)	34.14±2.5	31.84±0.47	0.031
N1Amp (µv)	0.301±0.09	0.383±0.03	0.041
N1 implicit time (ms)	16.66±1.8	16.06±0.34	0.147

mf-ERG: Multifocal electroretinogram; DME: Diabetic macular edema; amp: Amplitude.

Table 3. Mean value changes after IVR treatment in patients with DME

	Baseline	1 month	6 month	p^A
BCVA (log MAR)	0.53±0.08	0.45±0.5	0.31±0.06	<0.001
CMT (μm)	455.03±16.06	388.4±15.09	328.5±10.39	<0.001
Horizontal diameter of the cyst (μm)	312±87	178±92	51±26	0.3
Vertical diameter of the cyst (μm)	273±95	112±74	48±35	0.204
Area of the cyst (mm^2)	0.10±0.14	0.05±0.08	0.03±0.04	0.713
Subretinal fluid (μm)	16.2±10.9	8.7±6.3	1.7±4.5	<0.001
HRD (number)	16±5.2	10.7±9.2	11.7±8.3	0.205
Ring 1				
P1 amp (nV/deg^2)	63.35±22.9	68.55±22.5	74.89±29.5	<0.001
P1 amp (μV)	0.995±0.37	1.05±0.42	1.176±0.48	0.021
P1 implicit time (ms)	38.51±3.6	37.51±3.5	37.19±2.9	0.3
N1 amp (μV)	0.34±0.18	0.36±0.11	0.39±0.2	0.204
N1 implicit time (ms)	18.84±3.5	18.44±3.5	18.63±3.2	0.713
Ring 2				
P1 amp (nV/deg^2)	43.32±11.9	45.82±12.2	47.66±15.5	0.003
P1 amp (μV)	1.004±0.3	1.024±0.3	1.082±0.41	0.185
P1 implicit time (ms)	35.12±2.5	35.02±2.2	34.47±2.5	0.077
N1 amp (μV)	0.317±0.09	0.347±0.12	0.352±0.13	0.094
N1 implicit time (ms)	16.70±1.9	16.40±0.36	16.00±0.40	0.077
Ring 3				
P1 amp (nV/deg^2)	26.27±1.1	27.47±1.1	27.94±1.3	0.006
P1 amp (μV)	0.882±0.21	0.901±0.24	0.92±0.28	0.254
P1 implicit time (ms)	34.14±2.5	33.84±2.7	33.81±2.2	0.187
N1 amp (μV)	0.301±0.09	0.311±0.08	0.323±0.10	0.186
N1 implicit time (ms)	16.66±1.8	16.36±1.6	16.54±1.7	0.598

IVR: Intravitreal ranibizumab; DME: Diabetic macular edema; BCVA: Best corrected visual acuity; MAR: Minimum angle of resolution; CMT: Central macular thickness; HRD: Hyperreflective dot; amp: Amplitude.

According to the presence of cysts on the OCT image, the initial response density in patients without cystoid edema was higher than the patients with cysts, but it was not statistically significant (p=0.339). The mean response density increased from 60.68±22.3 nV/deg^2 to 74.40±22.8 nV/deg^2 in patients with cysts and from 69.60±24.4 nV/deg^2 to 76.04±19.2 nV/deg^2 in patients with diffuse edema in the central ring, and the differences were significant by the general linear modeling technique for repeated measurements (p=0.002). There was a negative correlation between the mean diameters of the cysts and the initial mean response density of P1 (for horizontal diameter: r=−0.658, p=0.03; for vertical diameter: r=−0.597, p=0.037; for area of the cyst, r=−0.603, p=0.021).

The initial presence of subretinal fluid in the fovea correlated with lower response density in the central ring (r=−0.68, p=0.03). The mean response density increased from 65±24.3 nV/deg^2 to 75.9±30.9 nV/deg^2 in patients without subretinal fluid and from 47.7±18 nV/deg^2 to 68.3±25.9 nV/deg^2 in patients with subretinal fluid in the central ring, and the differences were the general linear modeling technique for repeated measurements (p=0.01). At 6 months, only 1 case had subretinal fluid on OCT images, and in other cases, subretinal fluid was resolved. There was a significant difference between patients with subretinal fluid and patients without subretinal fluid in terms of the mean response density at baseline and 6 months (baseline, p=0.001; 6 month, p=0.02).

According to the presence of HRDs on OCT images, the initial response density in patients with HRDs was lower than the patients without HRDs (p=0.03). Correlations between differences in P1 response density and differences in OCT

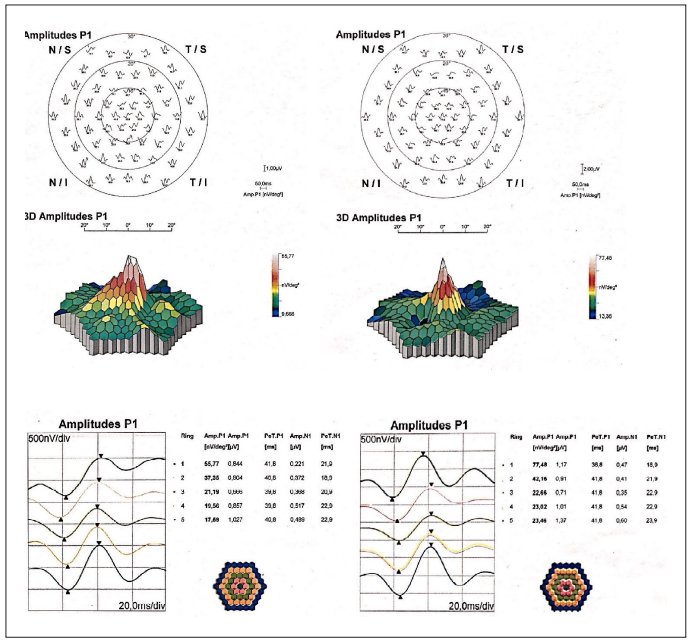

Figure 1. (a) A patient's electrophysiological values studied at baseline and the alterations obtained at 6 months after IVR. The correlation between ETDRS regions of the normal macula in OCT is shown on the upper pictures and mf-ERG field map on the lower pictures. **(b)** mf-ERG parameters of the same patient. The right picture shows the baseline values and the left picture shows values at 6 months. The response density of the P1 wave in ring 1 was increased from 55.77 nV/deg^2 to 77.48 nV/deg^2 after IVR treatment.

features are summarized in Table 4. There was a significant correlation between subretinal fluid and HRD reduction and the response density of P1 increase (Table 4).

At baseline, the correlation between the initial BCVA and the P1 and N1 amplitude was significant (for P1: r=−0.649, p=0.01; for N1: r=−0.575, p=0.02). The correlation between BCVA and P1/N1 implicit time in the central retina was not significant (for P1: r=−0.07, p=0.335; for N1: r=−0.08, p=0.674). At 6 months, the correlation between final BCVA and the P1 and N1 amplitude in ring 1 was significant (for P1: r=−0.603, p<0.001; for N1: r=−0.591, p=0.005). However, the correlation between BCVA and P1/N1 implicit time was not significant (for P1: r=−0.224, p=0.235; for N1, r=−0.53, p=0.783) (Fig. 3).

Discussion

In this study, we observed that the response density of P1 significantly increased over follow-up time in the first three rings after the treatment. At the same time, we also found that as HRDs and subretinal fluid decreased, the P1 response density increased. OCT is a very useful and frequently used imaging method in showing the anatomical structure of edema, but it is insufficient in evaluating the damage caused by edema to cells. mf-ERG is an imaging method that through concurrent stimulation of various areas of the retina, the retinal function can be mapped in the macula (16).

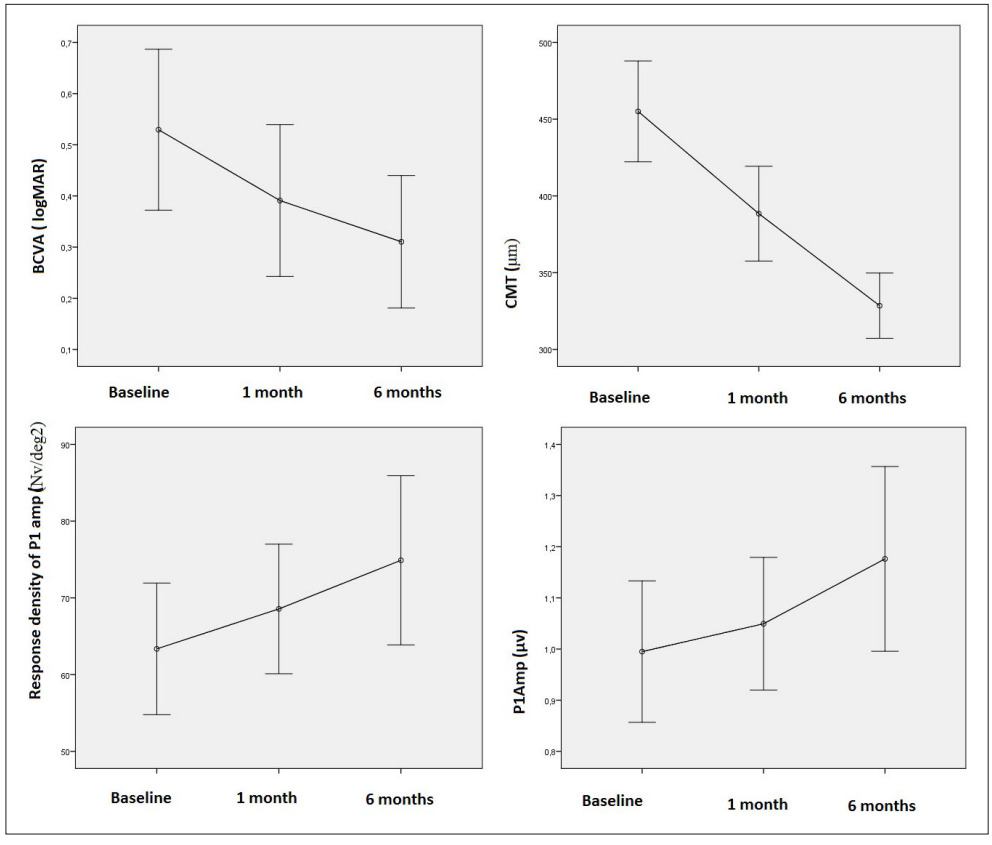

Figure 2. Change in the mean BCVA, CMT, P1 amplitude, and response density over time after IVR.

Table 4. Correlations between differences in mean change P1 response density and OCT features

	Difference between 6 months and baseline characteristics (mean±SD)	r	p
CMT (μm)	−126.53±86.7	0.022	0.908
Vertical diameter of the cyst (μm)	−152±18	−0.045	0.703
Horizontal diameter of the cyst (μm)	−185±23	−0.124	0.344
Area of the cyst (μm^2)	−0.07±0.02	0.017	0.402
Subretinal fluid (μm)	−14.57±9.2	−0.848	0.016
HRDs (number)	−4.2±3.8	−0.683	0.014

The differences were calculated by subtracting the baseline values from the 6th-month values. OCT: Optical coherence tomography; CMT; Central macular thickness, SD; Standard deviation; HRDs: Hyperreflective dots.

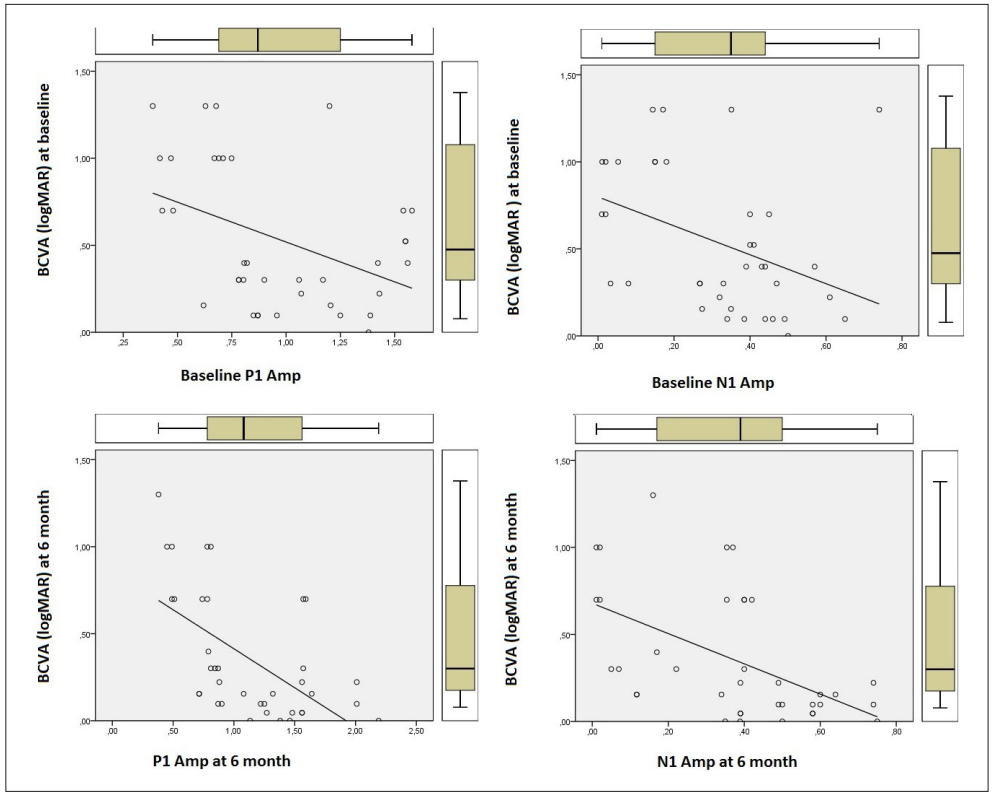

Figure 3. Scatter plot for the association at baseline and 6 months.

Our outcomes are consistent with the results of previous studies on the correlation between the change of mf-ERG values and visual acuity after IVR treatment. The response density of P1 was significantly increased compared with baseline, after IVR. Previous studies demonstrated the effect of intravitreal anti-VEGF treatments on mf-ERG in DME and the increments of P1 amplitudes in the central ring with IVR treatment (17–19). Similar to their results, a positive correlation between visual acuity and the P1 amplitude was reached at 6 months of the treatment in our study (16). Furthermore, our study focused on structure outcomes of OCT image (subretinal fluid and cyst diameters) and correlations between mf-ERG parameters and BCVA.

P1 is estimated to be produced by Müller and bipolar cells, and N1 is produced by photoreceptors. Therefore, a reduction in P1 amplitude essentially reveals functional injury in the inner layer, and a reduction in N1 amplitude reflects damage in the outer layer of the retina (20–22). Our results

revealed that the effect of macular edema in patients with DM was especially linked to P1 and N1 amplitudes on mf-ERG. Similar to other studies, the outcomes revealed that DME generates damage to the inner and outer layers of the retina, but the inner damage was more prominent (19, 22). The results showed that IVR both reduced macular edema and helped improve inner retinal cell function.

Regarding the presence of cyst in DME, the response density of P1 in cystoid type macular edema was lower compared with diffuse edema (19). This may be because large liquid vacuoles can have more destructive and interfering effects on photoreceptors and bipolar cells. It has been presumed that large intraretinal cysts may cause more cone dysfunction in a toxic and anatomical way. Although P1 amplitude increased in both types of DME after IVR treatment, the final response density of P1 was lower in cystoid DME than diffuse (spongioform) type.

Macular edema with subretinal fluid initially showed a worse prognosis with a limited increment in the response density. Various pathways may be involved, for example, inflammatory molecules in subretinal fluid may affect the delivery of stimuli to photoreceptors, bipolar cells, and also block their response to the electrodes. We observed significantly lower P1 amplitude in patients with subretinal fluid. In previous studies, a much greater dysfunction of both blood–retinal barriers in the serous detachment type has been demonstrated and the lower response density and amplitudes were observed in DME with subretinal fluid (19, 23).

In our study, the presence of HRDs was linked to lower baseline P1 response density, and HRD reduction was correlated with the gain of P1 response density. Previous studies have shown that in patients with DME, visual acuity decreases as the number of HRDs and the amount of subretinal fluid increase. With intravitreal anti-VEGF treatments, the number of HRD and the amount of subretinal fluid decrease, and visual acuity increases. The negative correlation between these OCT markers and visual acuity has also been demonstrated in previous studies (24, 25). Similar to previous studies, we observed in our study that the decrease in the number of HRDs and subretinal fluid not only increased visual acuity but also led to an improvement in mf-ERG. These OCT markers can be a critical prognostic factor in DME research. On the other hand, opposing views exist in the literature suggesting that higher number of HRDs correlate with better prognosis (26, 27).

Khojasteh et al. (28) showed that in DME, differences in mf-ERG values in means of P1 and N1 amplitudes have a significant correlation with the structural OCT abnormalities in the corresponding points of the thickness map and BCVA. We found a significant relationship between the presence of cysts and a lower central P1 amplitude similar to their results.

Holm et al. (29) reported that visual acuity increased after IVR, but there were no significant changes in terms of mf-ERG values through follow-up time in DME. They also found that implicit times significantly decreased after the IVR. It is known that age and fasting blood glucose levels may influence mf-ERG results (30). Therefore, we compared outcomes with age-matched control group, and all patients' fasting blood glucose levels were stationary between the examinations in our study. The changeable results in mf-ERG studies might be related to the inclusion of different stages among the patients with DME. The before-mentioned variations may be due to substantial differences in research designs and study population, following different treatment protocols, DM duration, and HbA1c levels.

This study was limited because of its retrospective nature and lower sample sizes. The strength of the study is it included a homogeneous sample of DM type 2 patients with DME who have been observed with the mf-ERG and OCT after treatment with ranibizumab.

In conclusion, the increment in BCVA and mf-ERG values and reduction in cyst diameters were observed through 6 months in our study. BCVA was correlated with P1 and N1 amplitude based on mf-ERG. The presence of HRDs and subretinal fluid may be a critical prognostic factor for recovery of visual acuity as an essential outcome in researches on DME. It is essential to improve our knowledge of DME to provide more detailed recommendations about treatment and monitoring. The functional alterations in patients with DME evaluated by mf-ERG can complement OCT findings. Long-term investigations and larger sample sizes are required for more reliable documentation.

Disclosures

Ethics Committee Approval: Ankara Training and Research Hospital review board/ethics committee, (09.11.2016/ 5550).

Peer-review: Externally peer-reviewed.

Conflict of Interest: None declared.

Authorship Contributions: Involved in design and conduct of the study (STK, DH, MA); preparation and review of the study (STK, AK,NU, FO); data collection (STK, GU, DH); and statistical analysis (STK, AK, MA).

References

1. Moss SE, Klein R, Klein BE. The 14-year incidence of visual loss in a diabetic population. Ophthalmology 1998;105:998–1003.
2. Haritoglou C, Kook D, Neubauer A, Wolf A, Priglinger S, Strauss R, et al. Intravitreal bevacizumab (Avastin) therapy for persistent diffuse diabetic macular edema. Retina 2006;26:999–1005.
3. Arevalo JF, Fromow-Guerra J, Quiroz-Mercado H, Sanchez JG, Wu L, Maia M, et al; Pan-American Collaborative Retina Study G. Primary intravitreal bevacizumab (Avastin) for diabetic macular edema: results from the Pan-American Collaborative

Retina Study Group at 6-month follow-up. Ophthalmology 2007;114:743–50.
4. Brown DM, Nguyen QD, Marcus DM, Boyer DS, Patel S, Feiner L, et al. Long-term outcomes of ranibizumab therapy for diabetic macular edema: the 36-month results from two phase III trials: RISE and RIDE. Ophthalmology 2013;120:2013–22.
5. Do DV, Schmidt-Erfurth U, Gonzalez VH, Gordon CM, Tolentino M, Berliner AJ, et al. The DA VINCI Study: phase 2 primary results of VEGF Trap-Eye in patients with diabetic macular edema. Ophthalmology 2011;118:1819–26.
6. Alkuraya H, Kangave D, Abu El-Asrar AM. The correlation between optical coherence tomographic features and severity of retinopathy, macular thickness and visual acuity in diabetic macular edema. Int Ophthalmol 2005;26:93–9.
7. Hood DC. Assessing retinal function with the multifocal technique. Prog Retin Eye Res 2000;19:607–46.
8. Marmor MF, Fulton AB, Holder GE, Miyake Y, Brigell M, Bach M; International Society for Clinical Electrophysiology of Vision. ISCEV Standard for full-field clinical electroretinography (2008 update). Doc Ophthalmol 2009;118:69–77.
9. Abstracts of the 50th ISCEV (International Society for Clinical Electrophysiology of Vision) International Symposium. June 3-7, 2012. Valencia, Spain. Doc Ophthalmol 2012;124:1–68.
10. Bearse MA Jr, Han Y, Schneck ME, Adams AJ. Retinal function in normal and diabetic eyes mapped with the slow flash multifocal electroretinogram. Invest Ophthalmol Vis Sci 2004;45:296–304.
11. Shimada Y, Li Y, Bearse MA Jr, Sutter EE, Fung W. Assessment of early retinal changes in diabetes using a new multifocal ERG protocol. Br J Ophthalmol 2001;85:414–9.
12. Lung JC, Swann PG, Chan HH. Early local functional changes in the human diabetic retina: a global flash multifocal electroretinogram study. Graefes Arch Clin Exp Ophthalmol 2012;250:1745–54.
13. Palmowski AM, Sutter EE, Bearse MA Jr, Fung W. Mapping of retinal function in diabetic retinopathy using the multifocal electroretinogram. Invest Ophthalmol Vis Sci 1997;38:2586–96
14. Otani T, Kishi S, Maruyama Y. Patterns of diabetic macular edema with optical coherence tomography. Am J Ophthalmol 1999;127:688–93.
15. Framme C, Schweizer P, Imesch M, Wolf S, Wolf-Schnurrbusch U. Behavior of SD-OCT-detected hyperreflective foci in the retina of anti-VEGF-treated patients with diabetic macular edema. Invest Ophthalmol Vis Sci 2012;53:5814–8
16. Yamamoto S, Yamamoto T, Hayashi M, Takeuchi S. Morphological and functional analyses of diabetic macular edema by optical coherence tomography and multifocal electroretinograms. Graefes Arch Clin Exp Ophthalmol 2001;239:96–101.
17. Comyn O, Sivaprasad S, Peto T, Neveu MM, Holder GE, Xing W, et al. A randomized trial to assess functional and structural effects of ranibizumab versus laser in diabetic macular edema (the LUCIDATE study). Am J Ophthalmol 2014;157:960–70.
18. Maheshwary AS, Oster SF, Yuson RM, Cheng L, Mojana F, Freeman WR. The association between percent disruption of the photoreceptor inner segment-outer segment junction and visual acuity in diabetic macular edema. Am J Ophthalmol 2010;150:63–7.e1.
19. Baget-Bernaldiz M, Romero-Aroca P, Bautista-Perez A, Mercado J. Multifocal electroretinography changes at the 1-year follow-up in a cohort of diabetic macular edema patients treated with ranibizumab. Doc Ophthalmol 2017;135:85–96.
20. Murakami T, Nishijima K, Akagi T, Uji A, Horii T, Ueda-Arakawa N, et al. Optical coherence tomographic reflectivity of photoreceptors beneath cystoid spaces in diabetic macular edema. Invest Ophthalmol Vis Sci 2012;53:1506–11.
21. Hood DC, Odel JG, Chen CS, Winn BJ. The multifocal electroretinogram. J Neuroophthalmol 2003;23:225–35.
22. Fu Y, Wang P, Meng X, Du Z, Wang D. Structural and functional assessment after intravitreal injection of ranibizumab in diabetic macular edema. Doc Ophthalmol 2017;135:165–73.
23. Bronson-Castain KW, Bearse MA Jr, Han Y, Schneck ME, Barez S, Adams AJ. Association between multifocal ERG implicit time delays and adaptation in patients with diabetes. Invest Ophthalmol Vis Sci 2007;48:5250–6.
24. Hwang HS, Chae JB, Kim JY, Kim DY. Association between hyperreflective dots on spectral-domain optical coherence tomography in macular edema and response to treatment. Invest Ophthalmol Vis Sci 2017;58:5958–67.
25. Chatziralli IP, Sergentanis TN, Sivaprasad S. Hyperreflective foci as an independent visual outcome predictor in macular edema due to retinal vascular diseases treated with intravitreal dexamethasone or ranibizumab. Retina 2016;36:2319–28.
26. Schreur V, Altay L, van Asten F, Groenewoud JMM, Fauser S, Klevering BJ, et al. Hyperreflective foci on optical coherence tomography associate with treatment outcome for anti-VEGF in patients with diabetic macular edema. Plos One 2018;13:e0206482.
27. Kang JW, Chung H, Chan Kim H. Correlation of optical coherence tomographic hyperreflective foci with visual outcomes in different patterns of diabetic macular edema. Retina 2016;36:1630–9.
28. Khojasteh H, Riazi-Esfahani H, Khalili Pour E, Faghihi H, Ghassemi F, Bazvand F, et al. Multifocal electroretinogram in diabetic macular edema and its correlation with different optical coherence tomography features. Int Ophthalmol 2020;40:571–81.
29. Holm K, Schroeder M, Lovestam Adrian M. Peripheral retinal function assessed with 30-Hz flicker seems to improve after treatment with Lucentis in patients with diabetic macular oedema. Doc Ophthalmol 2015;131:43–51.
30. Klemp K, Larsen M, Sander B, Vaag A, Brockhoff PB, Lund-Andersen H. Effect of short-term hyperglycemia on multifocal electroretinogram in diabetic patients without retinopathy. Invest Ophthalmol Vis Sci 2004;45:3812–9.