PROC (BAYL UNIV MED CENT)
2022;35(2):229–231
Copyright © 2021 Baylor University Medical Center
https://doi.org/10.1080/08998280.2021.1995107

Taylor & Francis
Taylor & Francis Group

Multifactorial jaundice and pigmented choledocholithiasis secondary to warm autoimmune hemolytic anemia and alcoholic cirrhosis

Colten Watson, MS[a], Mazen Hassan, MD[b], and Grant Breeland, MD[b]

[a]Texas A&M Medical School Dallas Campus, Dallas, Texas; [b]Department of Internal Medicine, Baylor University Medical Center, Dallas, Texas

ABSTRACT

A 67-year-old man with a history of alcoholic cirrhosis presented with acute abdominal pain. His total bilirubin was 43.8 mg/dL and fractionated to a direct bilirubin of 32.7 mg/dL. A warm agglutinin IgG1 antibody was positive, and abdominal magnetic resonance imaging detected an obstructing stone at the level of the sphincter of Oddi. Two pigmented gallstones were removed by endoscopic retrograde cholangiopancreatography. His total bilirubin decreased to 24.6 mg/dL the following day, and he was initiated on 20 mg of prednisone for his autoantibody.

KEYWORDS alcoholic cirrhosis; pigmented choledocholithiasis; warm autoimmune hemolytic anemia

In warm autoimmune hemolytic anemia (w-AIHA), the body creates the autoantibodies IgG1 and IgG3 that can bind and lyse red blood cells, causing anemia.[1] These autoantibodies, called hemolysins, can be detected with a Coombs test and confirmed with a direct antiglobulin test. Alcoholic cirrhosis presents with several of the same features, such as extreme jaundice and constitutional symptoms. It usually presents in the fifth to sixth decade of life in the setting of excessive chronic ethanol ingestion. Most evidence supporting ethanol consumption as an etiology for cirrhosis has come from epidemiological studies. The overwhelming cause of acute jaundice in patients with alcohol abuse is acute alcoholic hepatitis. The pathogenesis of alcoholic hepatitis is attributed mainly to the expression of cytokines, oxidative stress, reactive oxygen species, and SREBPs and SREBP-1, which impair fatty acid oxidation. Abstinence remains the most effective treatment method.[2] The combination of alcoholic cirrhosis with w-AIHA in patients is not well documented in the medical literature.

CASE DESCRIPTION

A 67-year-old man presented to the emergency department with complaints of worsening jaundice and colorless stool over the past 3 weeks and a 2-day history of periumbilical pain radiating to his back. He had a past medical history of alcohol abuse (with abstinence for the past 6 years), alcoholic cirrhosis, spontaneous bacterial peritonitis, hypertension, atrial fibrillation, and blood transfusion. Relevant surgical history included a transcatheter aortic valve replacement. He reported a 40-pound weight loss over the previous month, pruritus on his ankles and feet, as well as blurred vision, eye redness, cloudy urine, and fatigue. He denied vomiting, cough, sore throat, loss of taste and smell, melena, dizziness, headache, or tremors.

Upon admission, the patient's skin was highly jaundiced with a measured bilirubin of 43.8 mg/dL and a blood pressure of 104/50 mm Hg. Acute diffuse abdominal pain was present on palpation. Some shortness of breath was noted with rhonchi and abdominal distention. A rectal exam was guaiac positive and showed occult blood. His hemoglobin was 6.3 g/dL, resulting in the immediate transfusion of 4 units of packed red blood cells on his first day of admission. His total bilirubin of 43.8 mg/dL was fractionated, and direct bilirubin measured 32.7 mg/dL. The blood bank laboratory tests also had several findings; an antibody screen was positive and was confirmed with a direct Coombs test. The

Corresponding author: Colten Watson, MS, Texas A&M Medical School Dallas Campus, 821 Allen St., Apt. 748, Dallas, TX 75204 (e-mail: Colten.d.watson@gmail.com)
The authors report no conflicts of interest. The patient gave permission for this case to be published.
Supplemental data for this article are available online at https://doi.org/10.1080/08998280.2021.1995107
Received August 21, 2021; Revised October 7, 2021; Accepted October 11, 2021.

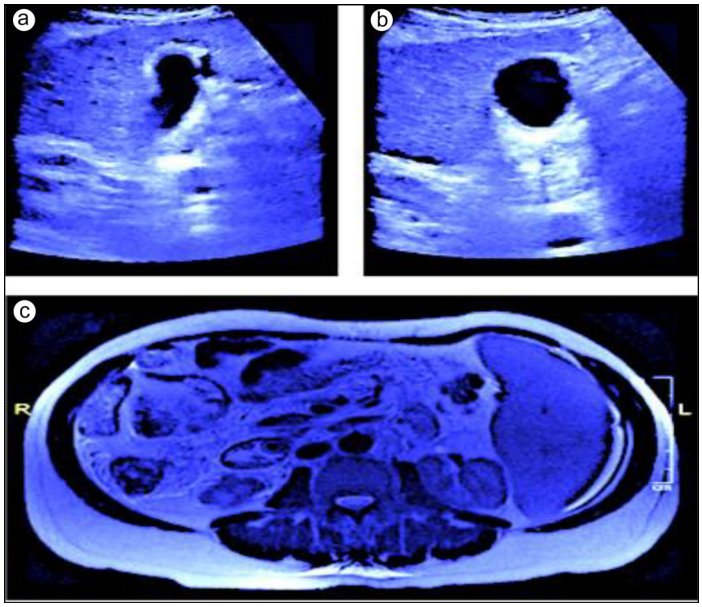

Figure 1. **(a, b)** Abdominal ultrasound showing cirrhotic appearance of the liver with echogenic foci, which likely represents scar tissue, as well as intrahepatic ductal dilation and a thickened gallbladder wall without evidence of acute cholecystitis. **(c)** Abdominal MRI showing an obstructing stone at the level of the sphincter of Oddi resulting in mild dilation of the common bile duct and minimal intrahepatic ductal dilation and cirrhotic liver morphology. Questionable focal enhancement within the right hepatic lobe was found.

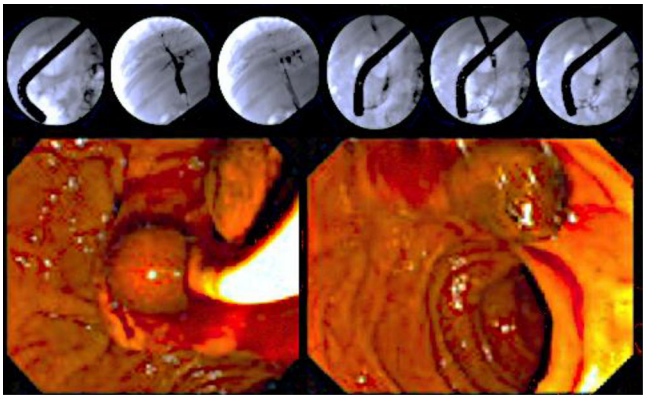

Figure 2. Endoscopic retrograde cholangiopancreatography procedure showing pigmented choledocholithiasis. Complete removal was accomplished by biliary sphincterotomy and balloon extraction.

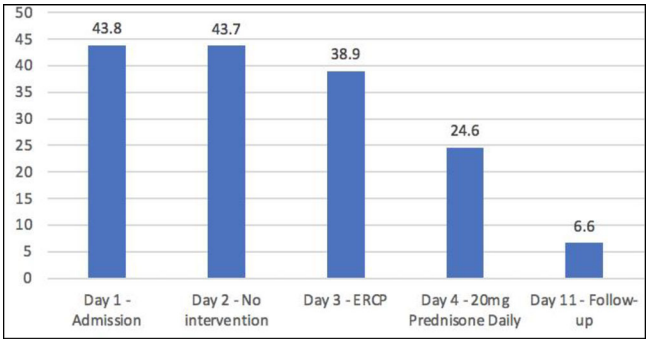

Figure 3. Bilirubin trend.

lab then discovered a warm agglutinin IgG antibody through a direct antiglobulin test. Other notable laboratory data included a lipase level of 390 U/L, elevated lactate dehydrogenase, decreased haptoglobin, and 1+ schistocytes (Supplemental Table).

A chest x-ray revealed no acute processes, but an abdominal ultrasound showed intrahepatic ductal dilation and a thickened gallbladder wall *(Figure 1)*. His common bile duct was 8 mm in diameter. A filling defect was found distally, measuring approximately 7 mm at the level of the sphincter of Oddi. Endoscopic retrograde cholangiopancreatography was performed based on the MRI impression *(Figure 2)* and led to complete removal of two pigmented gallstones via sphincterotomy and balloon extraction, as well as hemostasis of a bleeding lesion in the gastric antrum with argon plasma coagulation and ablation of an arteriovenous malformation in the gastric fundus. The final diagnosis was multifactorial jaundice and pigmented choledocholithiasis secondary to w-AIHA and alcoholic cirrhosis. Other diagnoses included acute gastrointestinal bleed in the gastric antrum and an arteriovenous malformation of the gastric fundus. The patient's total bilirubin decreased to 24.6 mg/dL the following day *(Figure 3)*, and he was initiated on 20 mg of prednisone. He was discharged with instructions to follow-up with hematology and hepatology within 7 days.

DISCUSSION

Our case shows a rare manifestation of w-AIHA directly contributing to acute, chronic decompensation of cirrhosis. w-AIHA affects 1 to 3 of 100,000 people,[3] and alcoholic cirrhosis could have been the major risk factor for this process. Currently, 50% of cases of w-AIHA are considered idiopathic.[3] What is especially interesting is that the patient's underlying cirrhosis ultimately led to frequent infections (spontaneous bacterial peritonitis or otherwise), which

eventually resulted in w-AIHA that exacerbated his decompensation. After all, the patient reported abstinence from alcohol for 6 years. This case brings awareness to the downstream effects of uncontrolled autoantibodies combined with the symptoms present with a cirrhotic liver as a result of chronic alcohol consumption (>4 drinks/day).

This case raises the question of whether the two disease processes are linked. There are several case reports of Zieve syndrome[4] addressing hemolytic anemia in alcoholic cirrhosis with prolonged abstention from alcohol, but no reports have presented definitive research on the mechanism involved or examined if there are multiple etiologies for the manifestation of autoimmune hemolytic anemia in the setting of cirrhosis.

ACKNOWLEDGMENTS

The authors thank the patient described in this case study; Dr. Ranjeeta Bahirwani, MD, Hepatology and Liver Transplantation of Baylor University Medical Center, for her advice and guidance; and Texas A&M Medical School, Dallas Campus, and Baylor University Medical Center, Dallas, Texas.

1. Freedman J. Autoimmune hemolysis: a journey through time. *Transfus Med Hemother*. 2015;42(5):278–285. doi:10.1159/000437195.
2. Grant BF, Dufour MC, Harford TC. Epidemiology of alcoholic liver disease. *Semin Liver Dis*. 1988;8(1):12–25. doi:10.1055/s-2008-1040525.
3. Liu MX, Wen XY, Leung YK, et al. Hemolytic anemia in alcoholic liver disease: Zieve syndrome: A case report and literature review. *Medicine*. 2017;96(47):e8742. doi:10.1097/MD.0000000000008742.
4. Liang R, Liu A, Perumpail RB, Wong RJ, Ahmed A. Advances in alcoholic liver disease: an update on alcoholic hepatitis. *World J Gastroenterol*. 2015;21(42):11893–11903. doi:10.3748/wjg.v21.i42.11893.

Avocations



"Dallas Zoo—I'll Walk the Line" by Jay Hoppenstein, MD. Dr. Hoppenstein (e-mail: navigato@aol.com) is a surgeon who was on the medical staff at Baylor University Medical Center at Dallas from 1971 until his retirement in 2005. He also served as chairman of the Department of Surgery at Presbyterian Hospital of Dallas.