Since January 2020 Elsevier has created a COVID-19 resource centre with free information in English and Mandarin on the novel coronavirus COVID-19. The COVID-19 resource centre is hosted on Elsevier Connect, the company's public news and information website.

Elsevier hereby grants permission to make all its COVID-19-related research that is available on the COVID-19 resource centre - including this research content - immediately available in PubMed Central and other publicly funded repositories, such as the WHO COVID database with rights for unrestricted research re-use and analyses in any form or by any means with acknowledgement of the original source. These permissions are granted for free by Elsevier for as long as the COVID-19 resource centre remains active.

Journal of Pediatric Surgery Case Reports 78 (2022) 102173

Contents lists available at ScienceDirect

Journal of Pediatric Surgery Case Reports

journal homepage: www.elsevier.com/locate/epsc

Premature twin neonates with a Coronavirus-19 positive mother present with an unusual pattern of intestinal ischemia

Christopher T. Retajczyk [a], Ian M. Jaffee [b], Kevin J. McKim [a], Paige J. Retajczyk [c], Claudia M. Mueller [d,*]

[a] Department of Pediatrics, California Pacific Medical Center, San Francisco, CA, USA
[b] Department of Pathology, California Pacific Medical Center, San Francisco, CA, USA
[c] Neonatal Special Services, California Pacific Medical Center, San Francisco, CA, USA
[d] Department of Surgery, Stanford University School of Medicine, Stanford, CA, USA

ARTICLE INFO

Keywords:
COVID-19 in pregnancy
Intestinal ischemia
Intestinal perforation

ABSTRACT

COVID-19 infection during pregnancy is associated with premature rupture of membranes, preterm delivery, and low birth weight. It has also been associated with hypercoagulability and vasculitis in certain patients. This article reports two premature twins born from a COVID-19 mother who presented with an unusual pattern of ileal ischemia and perforation within 24 hours of each other. We suggest that maternal infection with the novel coronavirus might lead to this atypical distribution of intestinal pathology.

Abbreviations

CRP	C-reactive protein
CPAP	Continuous positive airway pressure
COVID-19	Coronavirus disease 2019
DCDA	Dichorionic diamniotic
ECHO	Echocardiogram
ETT	Endotracheal tube
ELBW	Extremely low birth weight
FFP	Fresh frozen plasma
HFOV	High-frequency oscillatory ventilation
IV	Intravenous
IVH	Intraventricular hemorrhage
IUGR	Intrauterine growth restriction
KUB	Kidney-ureter-bladder
NICU	Neonatal intensive care unit
NIMV	Non-invasive intermittent mandatory ventilation
NPO	Nothing by mouth
NAA	Nucleic acid amplification

* Corresponding author. Division of Pediatric Surgery, Stanford University, 401 Quarry Road, Stanford, CA, USA, 94305.
E-mail address: Mueller4@stanford.edu (C.M. Mueller).

https://doi.org/10.1016/j.epsc.2021.102173
Received 28 December 2021; Accepted 31 December 2021
Available online 29 January 2022
2213-5766/© 2022 The Authors. Published by Elsevier Inc. This is an open access article under the CC BY-NC-ND license (http://creativecommons.org/licenses/by-nc-nd/4.0/).

PDA	Patent ductus arteriosus
PPROM	Preterm premature rupture of membranes
PEEP	Positive and-expiratory pressure
PH	Pulmonary hemorrhage
PRBCs	Red blood cells
RT-PCR	Reverse transcription-polymerase chain reaction
SPI	Spontaneous intestinal perforation
SIMV	Synchronized intermittent mandatory ventilation
VLBW	Very low birth weight

1. Introduction

While the effects of COVID-19 during pregnancy are not yet completely understood, there have been several reports which suggest that when an active infection with this virus occurs in pregnant women, it can result in a host of negative outcomes for neonates even when these babies themselves test negative for the disease [1,2].

Preterm birth (39%), intrauterine growth restriction (IUGR; 10%), and miscarriage (2%) have been observed as important fetal complications of COVID-19 during the third trimester in febrile pregnant women (38.1–39.0 °C) [3,4]. In addition, although results from samples of the placenta, the umbilical cord, and blood from previously infected mothers and their infants indicate that the virus rarely crosses from mother to fetus, when it does, placental damage and fetal injury can occur [5,6]. IgM has been found on neonates from mothers infected during pregnancy, bringing the hypothesis that this antibody might be produced by the fetus itself, indicating the possibility of past exposure and vertical transmission of SARS-CoV-2 [7].

Whether or not the virus itself is transmitted to the fetus, since COVID-10 infection during pregnancy has been well-documented to lead to preterm delivery [4], some of the negative health effects may be related to prematurity itself. For instance, pulmonary complications such as bronchopleural disease related to lung immaturity are very common in extremely premature babies. Similarly, intestinal disease leading to perforation either from necrotizing enterocolitis (NEC) or spontaneous intestinal perforation (SIP) is a frequent complication of prematurity.

In this report, we describe the case of twin girls who were born at 26 weeks' gestation after their mother contracted COVID-19 at 16 weeks. Both twins suffered typical effects of prematurity, including pulmonary issues. In addition, both presented with intestinal perforation which required surgical intervention. However, intra-operatively, the appearance of the bowel wall did not fit the classic presentation of neonatal bowel disease.

Patients with NEC generally present with patchy areas of ischemia or necrosis which can occur throughout the small and large bowel [8,9]. Patients who present with SIP, meanwhile, typically have a single area of perforation, usually within the terminal ileum, with sparing of the rest of the bowel [10,11]. Both patients described here had short segments of ischemia located in the mid ileum, neither of which conformed to NEC or SIP. We suggest that this unusual intestinal condition might be related to a COVID19-related process that affected fetal development during this pregnancy.

2. Case presentation

2.1. History of the mother

A 31-year-old G5P3A2 woman pregnant with dichorionic diamniotic (DCDA) female twins was hospitalized with COVID-19 pneumonia five days after she developed respiratory symptoms at home at 16 weeks' gestation. Her diagnosis was made via

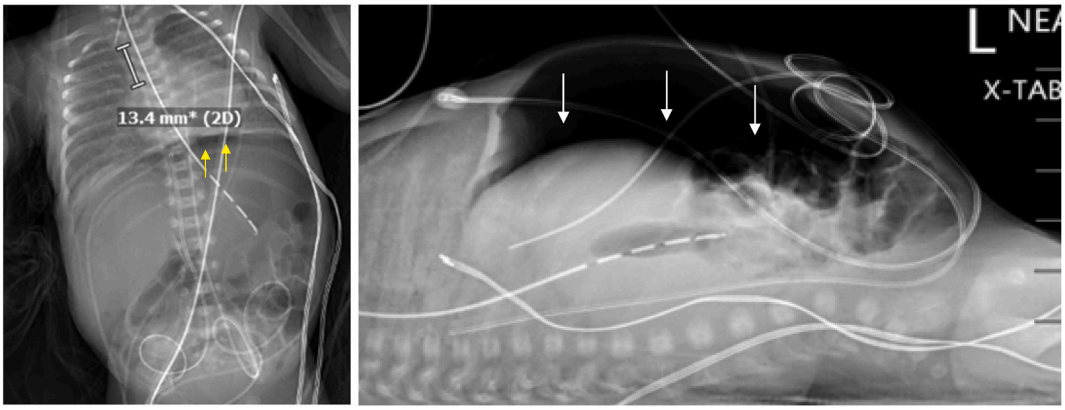

Fig. 1. 1A. Presence of free air over the liver (yellow arrow) seen in a kidney-ureter-bladder radiograph. 1B Presence of free intraperitoneal air outlining most of the abdominal wall (white arrow) demonstrated on a cross-table lateral view radiograph.

nucleic acid amplification (NAA) reverse transcription polymerase chain reaction (RT-PCR). During her two-day hospital stay, the patient was both tachypneic and tachycardiac but did not require oxygen supplementation. She did receive fluid boluses and convalescent plasma.

The patient then presented at 26 weeks' gestation in the emergency room with preterm premature rupture of membranes (PPROM). Betamethasone for fetal lung maturation, magnesium sulfate for tocolysis, azithromycin, and ampicillin were administrated to the patient 2 h prior to delivery. Group B strep and COVID-19 NAA were negative. Due to the breech presentation of both twins, the patient was taken to C-section for delivery.

2.2. Twin a history

A 1040 g female neonate was delivered with low tone and Apgar scores of 5, 5, and 7 at one, five, and 10 min, respectively. For this reason, the neonate was intubated at birth, received surfactant, and was transported to a tertiary neonatology center.

Covid tests via NAA RT-PCR were performed at birth, nine, and thirteen days of life and were all negative.

In spite of being diagnosed with a Grade 4 left intraparenchymal hemorrhage at DOL2, the patient was extubated to continuous positive airway pressure (CPAP) on DOL7. The patient was noted to have abdominal distention as well as brown emesis on DOL9. Kidney-ureter-bladder (KUB) radiograph was performed and noted to have free air over the liver (Fig. 1), demonstrating intestinal perforation. The patient was re-intubated and underwent an exploratory laparotomy which revealed a three-centimeter area of ischemia with perforation of the mid-ileum (Fig. 2). A resection and primary anastomosis were performed. The remaining bowel appeared to be well-perfused. There were no surgical complications, and the patient eventually recovered and was discharged home.

2.2.1. Histopathological examination of twin A

Ileum resection showed ischemic necrosis and features consistent with perforation. Upon opening of the bowel (0.1–0.2 cm in thickness), the mucosal surface was diffusely hemorrhagic with demonstrated loss of mucosa and transmural hemorrhage (Fig. 3A) and acute necrosis and inflammation within the ileum (Fig. 3B) observed by light microscopy (hematoxylin and eosin).

2.3. Twin B history

A 1020 g female neonate was delivered with low tone and poor respiratory effort, (APGARS) leading to intubation and placement in a conventional ventilator with stable blood gases. Two doses of curosurf and ampicillin/gentamicin regimen were administered.

As with twin A, covid tests NAA RT-PCR were performed at birth, nine and thirteen days of life and all were negative.

A large PDA was identified on DOL2 and the patient received an indomethacin regimen for four days with subsequent closure of the PDA.

The patient was extubated on DOL6, but reintubated on DOL10 after pneumoperitoneum was noted on KUB (Fig. 4). At exploratory laparotomy, a three-centimeter segment of necrosis with perforation was identified at a dilated portion of the mid-ileum. A second three-centimeter area of dilated bowel with ischemia was noted at the proximal ileum (Fig. 5). Both areas were resected, an end-to-end primary anastomosis was created distally, and the proximal bowel was brought as an ileostomy with mucus fistula. There were no surgical complications, and the stoma was closed before the patient's discharge from the hospital.

2.3.1. Histopathological examination of twin B

Marked luminal dilation and early ischemia with reactive epithelial changes were identified within the ileum (Fig. 6). In addition, reactive serosal changes consistent with perforation were observed within the proximal ileum resection.

Fig. 2. 2A. Dilated distal ileum. 2B. Three cm resected necrotic ileum.

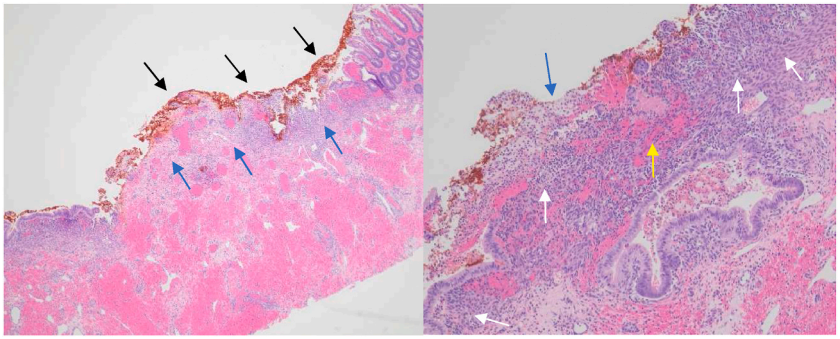

Fig. 3. 3A Ischemic small bowel with denuded mucosa (blue arrows) and surface hemorrhage (black arrows). 3B. Acute ischemic bowel necrosis with loss of surface epithelium (blue arrows), presence of inflammatory cells (white arrows), and ectasia of blood vessels (yellow arrow).

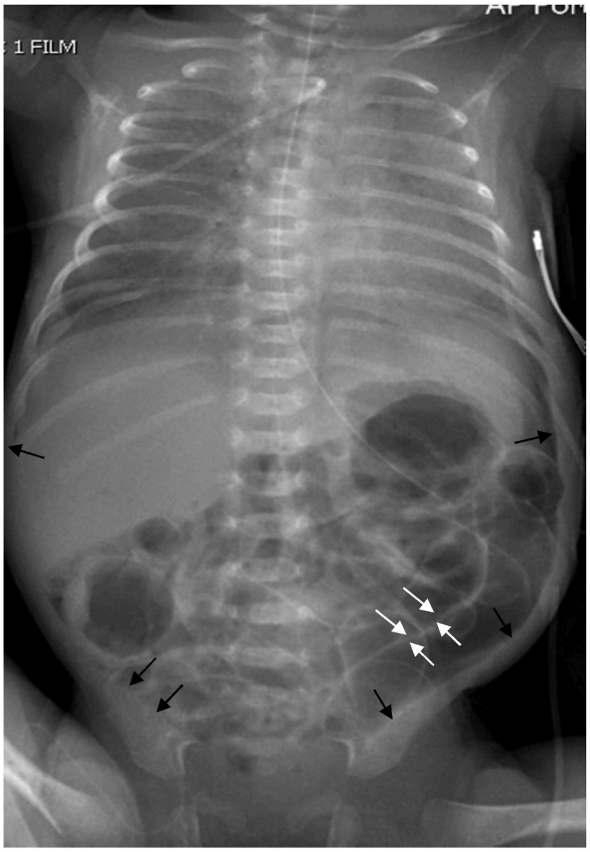

Fig. 4. Supine radiograph of twin B demonstrating presence of air on both sides of the bowel (wall Rigler sign) (white arrows) and the football sign (black arrows) compatible with pneumoperitoneum.

3. Discussion

Necrotizing enterocolitis (NEC) and SIP are two common causes of intestinal disease seen in preterm VLBW neonates, with a 2% risk of perforation in VLBW neonates [12,13]. However, the patients we describe in this paper showed evidence of intestinal ischemia that did not correspond to the typical presentation of either of these entities intra-operatively. During operation, one patient had a single short segment of ischemia in the mid-ileum while her sister had two short segments in the proximal as well as the mid-ileum. This finding would be quite unusual for either NEC or SIP in ischemia length and location. Our intra-operative findings lead us to wonder whether maternal COVID19 infection during pregnancy might lead to unique patterns of intestinal ischemia and necrosis.

COVID-19 has been linked to gastrointestinal disease in adults [14], with several reports of perforation throughout the small and large bowel [15–17]. In many of these cases, intestinal necrosis and perforation have been ascribed to thrombo-embolic events caused by COVID-related hypercoagulability [18,19]. In addition to hypercoagulability, SARS-CoV-2 has been demonstrated to affect the

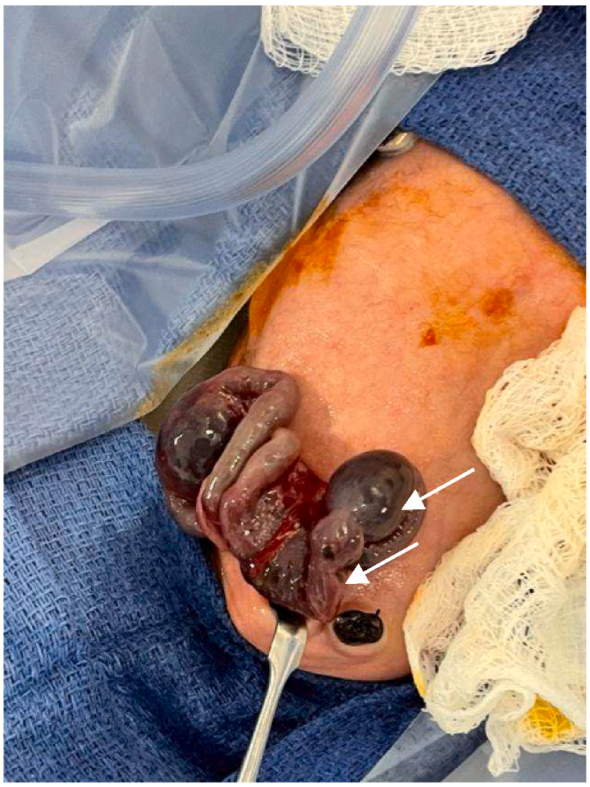

Fig. 5. Ileum with two areas of ileal dilation of approximately 3 cm in length each with localized necrosis (white arrow).

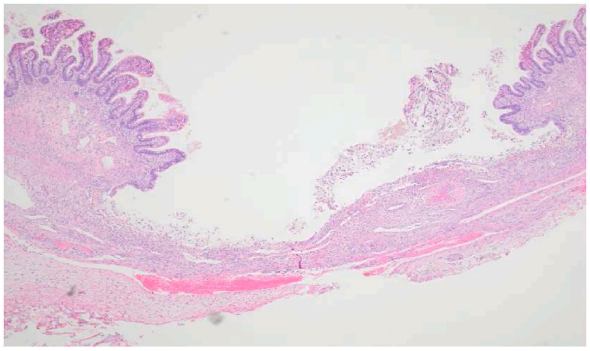

Fig. 6. Early ischemic necrosis of small bowel wall with loss of surface mucosa.

vascular system, probably due to the role the spike protein plays in damaging the vascular endothelial cells, which can lead to vasculitis with possible resulting intestinal complications [20].

Within neonates, we were able to identify three reports of intestinal perforation who were born after maternal exposure to COVID-19. Although the cases are described as NEC [21,22] and SIP [23], the described pattern of ischemia was not completely typical of these entities. Therefore, it is certainly possible that these cases might actually be similar to the perforation pattern demonstrated in our patients. Further investigation is needed to determine whether maternal exposure to COVID-19 might result in an atypical presentation of intestinal ischemia, leading to necrosis and perforation, for neonates.

Here, we report the cases of female twins who were born from a mother who was COVID-19 positive during her second trimester. We suggest that secondary effects from maternal COVID infection may have resulted in ischemia in the intestine, possibly related to vasculitis or thrombo-embolic events, of both twins during fetal development.

4. Conclusion

While there is still no definite evidence of the existence of an association between COVID-19 infection during pregnancy and

intestinal ischemia in the newborn, we believe that vigilance for, and early identification of, possible perforation in these patients is crucial to their overall care.

Funding

No funding or grant support.

Patient consent

Patient's family gives permission for patient information to be published in a scientific journal anonymously.

Authorship

All authors attest that they meet the current ICMJE criteria for Authorship.

Declaration of competing interest

The authors declare that they have no known competing financial interests or personal relationships that could have appeared to influence the work reported in this paper.

References

[1] Rasmussen SA, Smulian JC, Lednicky JA, Wen TS, Jamieson DJ. Coronavirus disease 2019 (COVID-19) and pregnancy: what obstetricians need to know. Am J Obstet Gynecol 2020. https://doi.org/10.1016/j.ajog.2020.02.017.
[2] Wu Y-T, Liu J, Xu J-J, et al. Neonatal outcome in 29 pregnant women with COVID-19: a retrospective study in Wuhan, China. PLoS Med 2020;17:e1003195.
[3] Dashraath P, Wong JLJ, Lim MXK, et al. Coronavirus disease 2019 (COVID-19) pandemic and pregnancy. Am J Obstet Gynecol 2020;222(6):521–31. https://doi.org/10.1016/j.ajog.2020.03.021.
[4] Karasek Deborah, Baer Rebecca J, McLemore Monica R, Bell April J, Blebu Bridgette E, Casey Joan A, Coleman-Phox Kimberly, Costello Jean M, Felder Jennifer N, Flowers Elena, Fuchs Jonathan D, Gomez Anu Manchikanti, Karvonen Kayla, Kuppermann Miriam, Liang Liang, McKenzie-Sampson Safyer, McCulloch Charles E, Oltman Scott P, Pantell Matthew S, Piao Xianhua, Prather Aric A, Schmidt Rebecca J, Scott Karen A, Spellen Solaire, Stookey Jodi D, Tesfalul Martha, Rand Larry, Jelliffe-Pawlowski Laura L. The association of COVID-19 infection in pregnancy with preterm birth: a retrospective cohort study in California. Lancet Reg. Health – Am. 2021;2. https://doi.org/10.1016/j.lana.2021.100027.
[5] 6 Schwartz DA, Graham AL. Potential maternal and infant outcomes from (Wuhan) coronavirus 2019-nCoV infecting pregnant women: lessons from SARS, MERS, and other human coronavirus infections. Viruses 2020;12(2):194. https://doi.org/10.3390/v12020194.
[6] Karimi-Zarchi M, Neamatzadeh H, Dastgheib SA, Abbasi H, Mirjalili SR, Behforouz A. Vertical transmission of coronavirus disease 19 (COVID-19) from infected pregnant mothers to neonates: a review. Fetal Pediatr Pathol 2020;39(3):246–50. https://doi.org/10.1080/15513815.2020.1747120 [PMC free article] [PubMed] [CrossRef] [Google Scholar].
[7] Ben-Hur H, et al. Transport of maternal immunoglobulins through the human placental barrier in normal pregnancy and during inflammation. Int J Mol Med 2005;16:401–7.
[8] Balance WA, Dahms BB, Shenker N, Kliegman RM. Pathology of neonatal necrotizing enterocolitis: a ten-year experience. J Pediatr 1990;117. S6–S13. [PubMed] [Google Scholar] [Ref list].
[9] Sylvester KG, Liu GY, Albanese CT. Necrotizing enterocolitis. Pediatr Surg 2012:1187–207. https://doi.org/10.1016/B978-0-323-07255-7.00094-5.
[10] Holland AJ, Shun A, Martin HC, et al. Small bowel perforation in the premature neonate: congenital or acquired? Pediatr Surg Int 2003;19(6):489–94. https://doi.org/10.1007/s00383-003-0967-8.
[11] Meyer CL, Payne NR, Roback SA. Spontaneous, isolated intestinal perforations in neonates with birth weight less than 1,000 g not associated with necrotizing enterocolitis. J Pediatr Surg 1991 Jun;26(6):714–7. https://doi.org/10.1016/0022-3468(91)90017-n. PMID: 1941464.
[12] Tiwari C, Sandlas G, Jayaswal S, Shah H. Spontaneous intestinal perforation in neonates. J Neonatal Surg 2015;4(2):14.
[13] Hyginus EO, Jideoffor U, Victor M. Gastrointestinal perforation in neonates: aetiology and risk factors. J Neonatal Surg 2013;2(3):30 [PMC free article] [PubMed] [Google Scholar.
[14] Lin L, Jiang X, Zhang Z, Huang S, Zhang Z, Fang Z, et al. Gastrointestinal symptoms of 95 cases with SARS-CoV-2 infection. Gut 2020;69(6):321013.
[15] Soeselo DA, Hambali W, Theresia S. Bowel necrosis in patient with severe case of COVID-19: a case report. BMC Surg 2021;21:97. https://doi.org/10.1186/s12893-021-01104-7.
[16] Gartland RM, Velmahos GC. Bowel necrosis in the setting of COVID-19. J Gastrointest Surg 2020;59:1–2.
[17] Jin X, Lian JS, Hu JH, Gao J, Zheng L, Zhang YM, et al. Epidemiological, clinical and virological characteristics of 74 cases of coronavirus-infected disease 2019 (COVID-19) with gastrointestinal symptoms. Gut 2020;69(6):1002–9.
[18] Bikdeli B, Madhavan MV, Jimenez D, Chuich T, Dreyfus I, Driggin E, et al. COVID-19 and thrombotic or thromboembolic disease: implications for prevention, antithrombotic therapy, and follow-up: JACC state-of-the-art review. J Am Coll Cardiol 2020;5(23):2950–73.
[19] Dane B, Smereka P, Wain R, Kim D, Katz DS. Hypercoagulability in COVID-19: identification of arterial and venous thromboembolism in the abdomen, pelvis, and lower extremities. Am J Roentgenol 2020;9:1–2.
[20] O'Neill M. COVID-19 is a vascular disease: coronavirus' spike protein attacks vascular system on a cellular level. SciTechDaily; 2021, May 4. https://scitechdaily.com/covid-19-is-a-vascular-disease-coronavirus-spike-protein-attacks-vascular-system-on-a-cellular-level/.
[21] Mehl S, Whitlock R, Marcano, et al. Necrotizing enterocolitis-like pneumatosis intestinalis in an infant with COVID-19. Pediatr Infect Dis 2021;40:e85–86.
[22] Gupta K, Thakur A, Kler N, et al. Gastric perforation and necrotizing enterocolitis associated with COVID antibodies. Indian J Pediatr 2021. https://doi.org/10.1007/s12098-021-03945-9.
[23] Harahap A, Harianto A, Etika R, et al. Spontaneous Ileum Perforation in a premature twin with Coronavirus-19 positive mother. J. Pediat. Surg. Case Rep. 2021; 67:101807. https://doi.org/10.1016/j.epsc.2021.101807.