Original Article

Long-Term Clinicoradiological Outcomes of Cervical Fusion With Polyether Ether Ketone versus Cervical Disc Arthroplasty in a Double-Blinded Randomized Control Trial

Vijay Kumar Gupta, Neeraj Basantani[1], Ajay Sebastian Carvalho[2], Ekata Gupta[3]

Department of Neurosurgery, National Institute of Medical Sciences (NIMS) University, [3]Health Care Clinic Jaipur, Rajasthan, [1]Department of Neurosurgery, Ram Raghu Hospital, Agra, Uttar Pradesh, [2]Department of Neurosurgery, Armed Forces Medical College and Command Hospital Southern Command, Pune, Maharashtra, India

Abstract

Introduction: In this double-blinded randomized controlled trial, we compare the long-term clinicoradiological effects of anterior cervical discectomy and fusion with polyether ether ketone implant (ACDF with PEEK) versus artificial cervical disc (cervical disc arthroplasty [CDA]) in patients with single and bilevel cervical degenerative disc disease (CDDD). **Aims:** We aimed to compare the pain scores, cervical kinematics, and radiological outcomes in patients undergoing CDA and ACDF for single and bilevel CDDD over 5 years. **Settings and Design:** This study was carried out from 2010 to 2019 in the Neurosurgery Department of a Tertiary Care Hospital attached to a Medical College in India. **Subjects and Methods:** We enrolled 30 patients in each group. Clinical and radiological assessments were carried out for all patients over a period of 5 years. **Statistical Analysis Used:** Wilcoxon Signed-rank test, Mann–Whitney *U*-test, and Fischer's exact test were used for comparing the preoperative and follow-u*P* values. R software version 3.6.0 was used for statistical analysis. **Results:** A significant improvement in the cervical range of motion, sagittal range of motion (ROM), and functional spinal unit (FSU) was observed in the CDA group at final follow-up, while the PEEK group reported a significant decrease in the ROM and FSU and the difference between the two groups was also found to be statistically significant. **Conclusions:** When assessed over 5 years following surgery, we found CDA to be superior with respect to ROM, FSU, overall cervical alignment, and maintenance of disc height when compared to ACDF with PEEK implant.

Keywords: *Anterior cervical discectomy and fusion, cervical disc arthroplasty, cervical arthrodesis, cervical arthroplasty, cervical degenerative disc disease, polyether ketone*

Introduction

Anterior cervical discectomy and fusion (ACDF) and cervical disc arthroplasty (CDA) are both acknowledged as equally effective treatments for patients of cervical degenerative disc disease (CDDD). However, there are very few randomized controlled trials (RCTs) in literature comparing the two modalities. Both procedures have their own set of advantages and disadvantages. The common complications of ACDF include screw backout, dysphagia, and plate fracture and development of adjacent-level disc degeneration. On the other hand, CDA which may prevent the complications of anterior cervical plating and cervical immobilization has its own side effects of implant migration or subsidence, and heterotopic ossification, though the more recent implants show fewer complications.[1-4]

While several studies have compared the immediate and short-term clinical and radiological outcomes of both these procedures, however, to the best of our knowledge, there have been few studies comparing long-term clinical and radiological outcomes of these patients. In this study, we compare the long-term clinical and radiologic outcomes of patients who underwent ACDF with polyether ether ketone (PEEK) implant versus CDA with Artificial cervical Disc (CDA) in single and bilevel CDDD.

Subjects and Methods

Study setting, patient population, and indication for surgery

This study was carried out from 2010 to 2019 in the Neurosurgery department of a tertiary care hospital attached to a

This is an open access journal, and articles are distributed under the terms of the Creative Commons Attribution-NonCommercial-ShareAlike 4.0 License, which allows others to remix, tweak, and build upon the work non-commercially, as long as appropriate credit is given and the new creations are licensed under the identical terms.

For reprints contact: WKHLRPMedknow_reprints@wolterskluwer.com

How to cite this article: Gupta VK, Basantani N, Carvalho AS, Gupta E. Long-term clinicoradiological outcomes of cervical fusion with polyether ether ketone versus cervical disc arthroplasty in a double-blinded randomized control trial. Asian J Neurosurg 2021;16:725-31.

Submitted: 11-Aug-2020 **Revised:** 02-Oct-2020
Accepted: 06-Oct-2020 **Published:** 18-Dec-2021

Address for correspondence:
Dr. Vijay Kumar Gupta, K-301, Pearl Green Acres, Shree Gopal Nagar, Gopal pura Bypass, Jaipur - 302 019, Rajasthan, India.
E-mail: drvijaygupta.neurosurg@gmail.com

Access this article online

Website: www.asianjns.org

DOI: 10.4103/ajns.AJNS_345_20

Quick Response Code:

medical college in India. Patients with prolapsed cervical intervertebral disc requiring decompression, between the age group of 18–65 years, admitted to the center constituted the study population. The inclusion criteria were (i) CDDD requiring surgical treatment at one level or two levels from C3-T1 for symptoms or signs of cervical radiculopathy and/or myelopathy, with or without axial neck pain and (ii) failed conservative treatment lasting at least 6 weeks for disc herniation with a radiculopathy or disc herniation with myelopathy or compressive lesion confirmed by magnetic resonance imaging (MRI). The exclusion criteria were postlaminectomy with kyphotic deformity, translational instability, ankylosing spondylitis, rheumatoid arthritis, ossification of the posterior longitudinal ligament or diffuse hyperostosis, patients with insulin-dependent diabetes miletus, pregnancy, metabolic bone disease, and nondiscogenic pain sources. The included patients were randomly allocated to Arthroplasty (AD) or Anterior cervical discectomy and fusion with PEEK implant group. All patients signed informed consent and agreed to participate in this study.

Randomization

A total of 60 patients were included in the study and randomized into the two groups in a one-to-one fashion. Allocation concealment was ensured by using sealed envelope for allocating treatment group to the selected study participants. Though patients could not be masked about type of surgery, outcome was measured by independent trained observers and data analysts were blinded to the type of surgery undergone by the patients. Five patients were lost to follow-up in each group and finally, 25 patients in each group were included in the final analysis. The patients were followed up at fixed intervals postsurgery and continued to be in follow-up and final evaluation was done 5-year postsurgery. In this present study, we evaluate the clinical and radiological findings preoperatively and at final follow-up (5-year postsurgery).

Clinical and radiological evaluation

Relevant clinical and radiological evaluation was done for all patients before surgery and also at fixed intervals postoperatively and last follow-up examination was done 5-year postsurgery. Visual Analogue Pain Scale (VAPS) was used to measure pain intensity and Neck disability Index (NDI) was used to measure neck-specific disability both preoperatively and thereafter at routine follow-up. cervical range of motion (CROM) goniometer was used to record active CROM. Preoperative evaluation was done to rule out cardiac, hepatic, renal, and respiratory disease and to grade the patient's fitness for surgery.

Radiological evaluation (radiography, MRI) was done to confirm the diagnosis and extent/level of involvement. Thereafter postsurgery lateral cervical spine radiograph with flexion and extension views was used at each follow-up and finally at 5 years to compare long-term radiological outcome in both the groups.

Surgical procedure

All procedures were performed by a single surgeon and were completed through a transverse skin incision made on the right side of the neck. Under general anesthesia, ACDF with PEEK implant (filled with autogenous bone) without anterior cervical plating or implantation or the Prestige® artificial disc prosthesis was performed. Patients in the PEEK group were given a soft/hard neck collar for 6-week postsurgery.

Statistical analysis

Numerical variables were summarized by median and inter-quartile range and categorical variables were summarized by proportions. Wilcoxon signed-rank test was used to compare preoperative and follow-u*P* values of numerical variables. Median of differences between preoperative and follow-up values with 95% confidence intervals were also calculated. The difference in change in numerical variables between two groups-CDA and PEEK were compared by Mann Whitney U Test. Categorical variables were compared by Fisher's exact test. Two-tailed tests were used and $P < 0.05$ was considered to be statistically significant. R-3.6.0 software version (Windows) was used for statistical analysis.

Results

Baseline characteristics and clinical scores

There were no significant differences in demographic factors or the presence of myelopathy between the two groups. The mean age of patients in the CDA group was 34 years (29.25–39.50) while those in the PEEK group were 41 years (33–57 years). There were 6 females and 19 males in the CDA group while the PEEK group had 04 females and 21 males. In our study, 32% of the patients in the CDA group and 28% in the PEEK group had myelopathy [Table 1].

The median preoperative VAS scores were 8.3 and 8.0 for CDA and PEEK groups, respectively. At the last follow-up (5 years postsurgery), the median VAS scores decreased to 3.6 in the CDA group and 3.9 in the PEEK group ($P < 0.001$). The median VAS scores

Table 1: Baseline characteristics in the two groups

	CDA group	PEEK group	*P*
Age, median (IQR)	34 (29.25-39.50)	41 (33-57)	0.026
Sex, *n* (%)			
Female	6 (24)	4 (16)	0.725
Male	19 (76)	21 (84)	
Myelopathy, *n* (%)	8 (32)	7 (28)	0.99

CDA - Cervical disc arthroplasty; PEEK - Polyether ether ketone; IQR - Interquartile range

at 5-year follow-up were significantly lower compared to the preoperative VAS scores in both groups. Though the reduction in scores was more for the CDA group than the PEEK group, however, this difference was not significant ($P = 0.203$) [Table 2].

The mean preoperative NDI scores were 26 for both the CDA and PEEK groups, and this reduced to 07 for both the groups when assessed at the last follow-up. While both groups demonstrated a significant difference in the follow-up scores when compared to their preoperative scores ($P < 0.05$) [Table 2], however, the difference between the groups was not significant.

The CROM for cervical, lateral flexion, and rotational motion has been compared in Table 3 and Figure 1. The median range of motion (ROM) increased postoperatively in the CDA group for all forms of ROM. This increase was found to be statistically significant ($P < 0.0001$). However, in the PEEK group, a significant decrease in motion was observed in all forms/types of ROM at 5 years of follow-up. The change between the two groups was also found to be significant in all the forms of ROM.

Radiological outcomes

Sagittal ROM was compared preoperatively and at follow-up both within the two groups and between the groups [Table 4 and Figure 2]. The preoperative median sagittal ROM in the CDA group was 9.10, 8.80, and 12.60 in the three levels, namely upper, lower, and implanted level ROM, and it increased to 9.90,9.30 and 13.0, respectively. This change was found to be statistically significant in all three levels. However, in the PEEK group, a reduction in the sagittal ROM values was noted at the final follow-up in all three levels. This change between the two groups was found to be highly significant ($P < 0.0001$).

Median functional spinal unit (FSU) values decreased postoperatively in both groups [Table 5], however, the decrease was significantly more in the PEEK group. The FSU flexion reduced from 8.20 to 6.60 in the CDA group, FSU range of movement also decreased from 14.10 to 11.20 in the FSU range of movement for the CDA group. A larger reduction in the FSU was noticed in the PEEK group.

We assessed overall cervical alignment (OCA) in both the groups [Table 6]. The median OCA flexion, extension, and ROM values preoperatively in the CDA group were 25.40, −25.10, and 50.70. On follow-up, these increased for both flexion and ROM (26.20 and 52.30, respectively) and only showed a decline (−26) for OCA extension. The changes in all three planes were significant. However, in the PEEK group, there was a significant decrease in the follow-up median OCA values for flexion and ROM. The difference in OCA between the two groups was also found to be statistically significant.

Table 2: Comparison of clinical findings in the cervical disc arthroplasty and polyether ether ketone group

	CDA group	Change median (95% CI), *P*	PEEK group	Change median (95% CI), *P*	*P* (difference in change)
VAS scores, median (IQR)					
Preoperative	8.3 (7.7-8.9)	−4.65 (−4.95-−4.35), <0.001	8.0 (7.6-8.7)	4.40 (−4.50-−4.30), <0.001	0.203
Follow-up	3.60 (3.20-4.10)		3.90 (3.00-4.40)		
NDI scores, median (IQR)					
Preoperative	26.0 (24.0-27.0)	−18.50 (−19.00-−17.50), <0.001	26.0 (24.0-27.0)	−19.00 (−19.50-−18.00), <0.001	0.490
Follow-up	7.0 (6.0-8.0)		7.0 (6.0-8.0)		

CDA - Cervical disc arthroplasty; PEEK - Polyether ether ketone; IQR - Interquartile range; CI - Confidence interval; VAS - Visual Analogue Scale; NDI - Neck disability index

Table 3: Comparison of cervical range of motion in cervical disc arthroplasty and polyether ether ketone group

	CDA group		PEEK group		*P* (difference in change)
	Values median (IQR)	Change median (95% CI), *P*	Values median (IQR)	Change median (95% CI), *P*	
CROM					
Preoperative	88.00 (84.00-96.00)	8.50 (7.00-10.00), <0.001	83.00 (77-87)	−13.00 (−14.50-−12.00), <0.001	<0.001
Follow-up	97.00 (96.00-102.00)		68.00 (66.00-71.00)		
Lateral flexion ROM					
Preoperative	71.00 (66.00-74.00)	9.50 (9.00-11.00), <0.001	71.00 (68.00-74.00)	−14.00 (−15.00-−12.00), <0.001	<0.001
Follow-up	79.00 (77.00-83.00)		57.00 (56.00-58.00)		
Rotational ROM					
Preoperative	112.00 (103.00-122.0)	30.50 (27.00-33.50), <0.001	112.00 (102.00-120.0)	−19.00 (−22.00-−16.50), <0.001	<0.001
Follow-up	142.00 (140.00-148.00)		91.00 (84.00-100.00)		

CDA - Cervical disc arthroplasty; PEEK - Polyether ether ketone; ROM - Range of motion; CROM - Cervical ROM; CI - Confidence interval; IQR - Interquartile range

Table 4: Comparison of radiological findings in cervical disc arthroplasty and polyether ether ketone groups

	CDA group		PEEK group		*P* (difference in change)
	Values median (IQR)	Change median (95% CI), *P*	Values median (IQR)	Change median (95% CI), *P*	
Sagittal ROM-upper level					
Preoperative	9.10 (7.30-10.10)	0.75 (0.65-0.80), <0.001	9.80 (8.3-10.7)	−0.25 (−0.35-−0.15), <0.001	<0.001
Follow-up	9.90 (8.10-10.70)		9.50 (7.9-10.70)		
Sagittal ROM-lower level					
Preoperative	8.80 (7.10-10.30)	0.65 (0.55-0.75), <0.001	13.2 (10.3-14.0)	−2.00 (−2.55-−1.50), <0.001	<0.001
Follow-up	9.30 (7.70-10.90)		10.0 (8.6-11.80)		
Sagittal ROM-implanted level					
Preoperative	12.60 (11.40-13.90)	0.30 (0.25-0.40), <0.001	13.2 (12.2-14.4)	−11.80 (−12.60-−11.15), <0.001	<0.001
Follow-up	13.00 (11.70-14.30)		1.60 (1.50-1.80)		

CDA - Cervical disc arthroplasty; PEEK - Polyether ether ketone; CI - Confidence interval; ROM - Range of motion; IQR - Interquartile range

Table 5: Comparison of functional spinal unit in cervical disc arthroplasty and polyether ether ketone groups

	AD group		PEEK group		*P* (difference in change)
	Values median (IQR)	Change median (95% CI), *P*	Values median (IQR)	Change median (95% CI), *P*	
FSU flexion					
Preoperative	8.20 (6.90-8.90)	−1.20 (−1.60-−1.19), <0.001	7.90 (6.90-9.00)	−5.85 (−6.35-−5.45), <0.001	<0.001
Follow-up	6.60 (5.60-7.70)		2.10 (1.80-2.40)		
Follow-up	−4.30 (−4.50-−3.80)		−2.00 (−2.40-−1.80)		
FSU range of movement					
Preoperative	14.10 (12.30-14.90)	−2.70 (−2.85-−2.65), <0.001	14.10 (13.00-15.10)	−10.05 (−10.65-−9.45), <0.001	<0.001
Follow-up	11.20 (9.10-12.20)		3.80 (3.60-4.70)		

PEEK - Polyether ether ketone; CI - Confidence interval; FSU - Functional spinal unit; IQR - Interquartile range; AD - Arthroplasty

Table 6: Comparison of overall cervical alignment in cervical disc arthroplasty and polyether ether ketone group

	AD group		PEEK group		*P* (difference in change)
	Values median (IQR)	Change median (95% CI), *P*	Values median (IQR)	Change median (95% CI), *P*	
Overall cervical alignment-flexion					
Preoperative	25.40 (23.90-27.40)	1.00 (0.80-1.15), <0.001	22.80 (20.90-24.90)	−7.90 (−9.15-−6.90), <0.001	<0.001
Follow-up	26.20 (24.30-28.40)		14.70 (13.60-15.40)		
Overall cervical alignment-ROM					
Preoperative	50.70 (46.60-55.40)	1.85 (1.50-2.20), <0.001	50.50 (49.10-52.40)	−16.80 (−18.70-−14.60), <0.001	<0.001
Follow-up	52.30 (48.30-56.30)		34.10 (31.20-35.40)		

IQR - Interquartile range; AD - Arthroplasty; PEEK - Polyether ether ketone; CI - Confidence interval; ROM - Range of motion

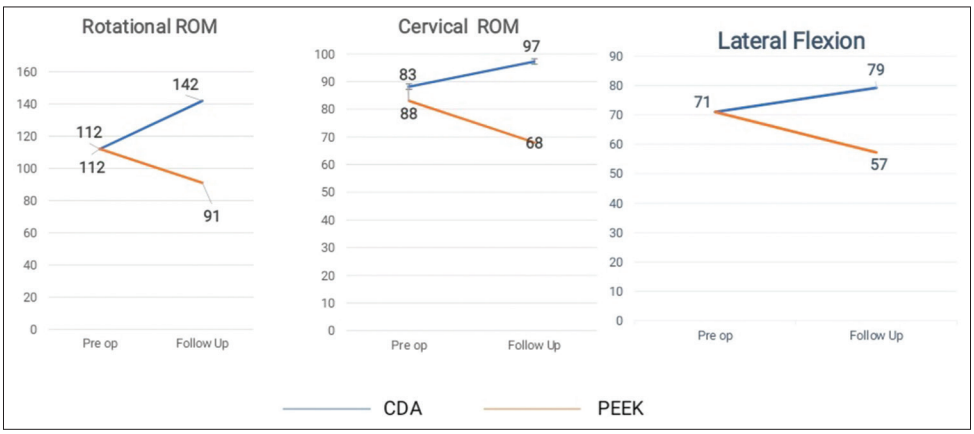

Figure 1: Comparison of range of motion in the two groups

Table 7: Comparison of disc height in cervical disc arthroplasty and polyether ether ketone group

	CDA group		PEEK group		*P* (difference in change)
	Values median (IQR)	Change median (95% CI), *P*	Values median (IQR)	Change median (95% CI), *P*	
Disc height-implanted level (posterior intervertebral height)					
Preoperative	2.92 (2.52-4.59)	−0.01 (−0.02-0.02), 0.647	4.00 (3.78-4.84)	0.83 (0.70-0.97), 0.001	<0.001
Follow-up	2.90 (2.50-4.59)		5.10 (4.18-5.58)		
Disc height-lower level (posterior intervertebral height)					
Preoperative	4.50 (3.22-5.08)	−0.01 (−0.03-0.00), 0.051	4.38 (3.82-5.02)	−0.39 (−0.46-−0.34), <0.001	<0.001
Follow-up	4.49 (3.21-5.10)	−0.01 (−0.03-0.00), 0.051	3.94 (3.43-4.70)	−0.39 (−0.46-−0.34), <0.001	<0.001
Disc height-upper level (anterior intervertebral height)					
UL-AIH-pre	4.90 (3.28-5.04)	0.00 (−0.02-0.01), 0.855	4.32 (3.96-5.02)	−0.51 (−0.62-−0.39), <0.001	<0.001
UL-AIH-FU	4.76 (3.28-5.01)		4.01 (3.18-4.50)		
Disc height-lower level (anterior intervertebral height)					
LL-AIH-pre	4.76 (3.18-5.12)	−0.01 (−0.03-0.00), 0.066	4.36 (3.88-5.11)	−0.36 (−0.41-−0.31), <0.001	<0.001
LL-AIH-FU	4.79 (3.16-5.06)		4.01 (3.40-4.78)		

CDA - Cervical disc arthroplasty; PEEK - Polyether ether ketone; CI - Confidence interval; IQR - Interquartile range; AIH - Anterior intervertebral height; UL - Upper Level; LL - Lower Level; AIH - anterior intervertebral height

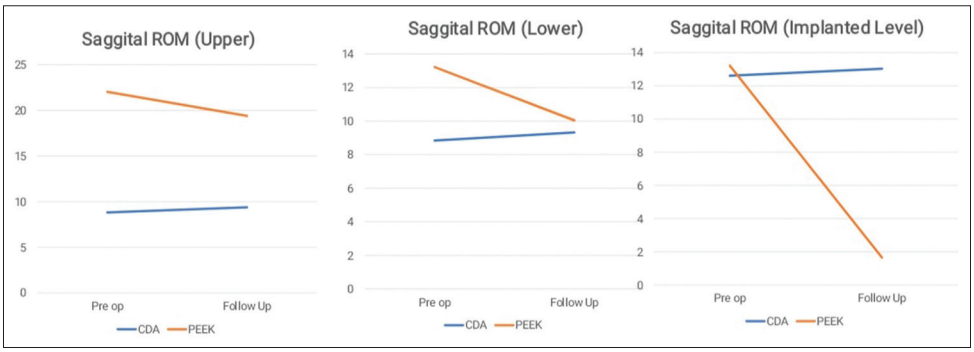

Figure 2: Comparison of sagittal range of motion in cervical disc arthroplasty and polyether ether ketone group

The disc height between the two groups is compared in Table 7. In the CDA group, we noticed that the disc height was maintained at all the levels measured (Posterior intervertebral height at the Implanted level and lower level and Anterior Intervertebral height at the upper and lower level) while in the PEEK group there was a significant decrease in the disc heights at all the levels measured.

Discussion

A meta-analysis of published RCTs which compared CDA with ACDF for patients with CDDD found that CDA was an effective and safe surgical procedure for the treatment of one-level CDDD, and CDA group had significantly better ROM and rate of neurological success, significantly lower neck pain scores, and lower arm pain scores at 24 months postoperatively than the ACDF group.[5] A similar study by Rao *et al*., which also included two level CDDD, reported similar findings.[6]

Our study compares the long-term clinical and radiological outcomes of CDA versus PEEK in patients with cervical disc degenerative disease. While the VAS and NDI scores improved in both subsets of patients, however, no difference could be observed between the two groups for both these scores. Similar findings were reported from China by Xinlin Gao *et al*. and Shi J S *et al*. However, in another similar study by Zeng *et al*., better improvement in NDI scores was reported in the CDA group as compared to the ACDF group.[4,7,8]

When we compared the CROM in the two groups of patients, we found significantly better ROM in patients undergoing CDA as compared to those in the PEEK group. A similar result was reported by Xinlin Gao *et al*. with preservation of ROM of the C2-C7 level in the CDA group, whereas in the ACDF group decrease in ROM was noted postoperatively. Several RCTs comparing the ROM in these two groups have also reported similar findings.[9-11]

When the sagittal ROM was compared between the two groups, the PEEK group showed a reduction in the sagittal ROM, while an increase in the sagittal ROM in all planes was noticed in the CDA group. Similar results have been reported by Parish JM *et al.* from Spain, Radcliff K *et al*. from China, and also by Janssen ME *et al.* in a published meta-analysis of RCTs comparing ACDF versus CDA for two contiguous levels of cervical disc degenerative disease.[9,11,12]

The FSU showed a steeper decline in the PEEK group as compared to the CDA group. Similar findings have been reported in RCTs from China and Korea.[13,14] We also report a significant decrease in OCA in the measured planes for the PEEK group, while the CDA group shows showed an increase in both planes. Several other authors have also reported an improvement in the cervical lordosis in patients who underwent CDA as compared to ACDF.[7,8] This assumes importance due to the correlation reported by authors between restoration of cervical lordosis and delay/prevention in anterior segmental pathology.[15]

When we compared the disc height between the two groups, we observed that the disc height was more or less maintained in the CDA group, while those in the PEEK group demonstrated a significant decrease in the disc height. Several other authors have also reported similar findings, underlining the better long-term radiological outcome in patients who undergo CDA for cervical disc disease.[8,13,16,17]

Our study has the advantage of being one of the few long-term follow-up studies in patients undergoing CDA and ACDF in India. Further being a closely monitored group of patients, there were no dropouts among the subjects which could have affected the results of our study.

However, we acknowledge that possible limitations of our study include a small sample size in each group, a single observer for interpreting the results of the two groups, and the confounding factor of heterogeneity of single and bilevel cases of CDDD in both the groups.

Conclusions

We conclude that although there was no long-term significant difference in the VAPS and NDI between the two groups, CDA offers better results in terms of cervical kinematics and radiological outcomes as compared to ACDF in patients of CDDD. We thus feel that CDA may be a more close to physiological state than ACDF in regard to preserving ROM and maintaining disc height, thus preventing adjacent segment disease in the future in patients with uni and bilevel CDDD.

Financial support and sponsorship

Nil.

Conflicts of interest

There are no conflicts of interest.

References

1. Pimenta L, McAfee PC, Cappuccino A, Cunningham BW, Diaz R, Coutinho E. Superiority of multilevel cervical arthroplasty outcomes versus single-level outcomes: 229 consecutive PCM prostheses. Spine (Phila Pa 1976) 2007;32:1337-44.
2. Hilibrand AS, Carlson GD, Palumbo MA, Jones PK, Bohlman HH. Radiculopathy and myelopathy at segments adjacent to the site of a previous anterior cervical arthrodesis. J Bone Joint Surg Am 1999;81:519-28.
3. Chin-See-Chong TC, Gadjradj PS, Boelen RJ, Harhangi BS. Current practice of cervical disc arthroplasty: A survey among 383 AOSpine International members. Neurosurg Focus 2017;42:E8.
4. Shi JS, Lin B, Xue C, Zhang HS, Chen ZD, Zhao ZS. Clinical and radiological outcomes following hybrid surgery in the treatment of multi-level cervical spondylosis: Over a 2-year follow-up. J Orthop Surg Res 2015;10:185.
5. Gao F, Mao T, Sun W, Guo W, Wang Y, Li Z, *et al.* An updated meta-analysis comparing artificial Cervical Disc Arthroplasty (CDA) versus Anterior Cervical Discectomy and Fusion (ACDF) for the treatment of Cervical Degenerative Disc Disease (CDDD). Spine (Phila Pa 1976) 2015;40:1816-23.
6. Rao MJ, Nie SP, Xiao BW, Zhang GH, Gan XR, Cao SS. Cervical disc arthroplasty versus anterior cervical discectomy and fusion for treatment of symptomatic cervical disc disease: A meta-analysis of randomized controlled trials. Arch Orthop Trauma Surg 2015;135:19-28.
7. Zeng J, Liu H, Wang B, Deng Y, Ding C, Chen H, *et al.* Clinical and radiographic comparison of cervical disc arthroplasty with Prestige-LP Disc and anterior cervical fusion: A minimum 6-year follow-up study. Clin Neurol Neurosurg 2018;164:97-102.
8. Gao X, Yang Y, Liu H, Meng Y, Zeng J, Wu T, *et al*. A comparison of cervical disc arthroplasty and anterior cervical discectomy and fusion in patients with two-level cervical degenerative disc disease: 5-year follow-up results. World Neurosurg 2019;122:e1083-9.
9. Radcliff K, Davis RJ, Hisey MS, Nunley PD, Hoffman GA, Jackson RJ, *et al.* Long-term evaluation of cervical disc arthroplasty with the Mobi-C© cervical disc: A randomized, prospective, multicenter clinical trial with seven-year follow-up. Int J Spine Surg 2017;11:31.
10. Weinreb JH. Cervical disc arthroplasty versus anterior cervical discectomy and fusion; utilization and perioperative outcomes. J Spine 2014;03;178.
11. Parish JM, Coric D. Cervical arthroplasty: Long-term outcomes of FDA IDE trials. Glob Spine J 2020;10 Suppl 2:61S-4.
12. Janssen ME, Zigler JE, Spivak JM, Delamarter RB, Darden BV 2nd, Kopjar B. ProDisc-C total disc replacement versus anterior cervical discectomy and fusion for single-level symptomatic cervical disc disease: Seven-year follow-up of the prospective randomized U.S. Food and Drug Administration Investigational Device Exemption Study. J Bone Joint Surg Am 2015;97:1738-47.
13. Kim SW, Limson MA, Kim SB, Arbatin JJ, Chang KY, Park MS, *et al.* Comparison of radiographic changes after ACDF versus Bryan disc arthroplasty in single and bi-level cases. Eur Spine J 2009;18:218-31.
14. Hou Y, Liu Y, Yuan W, Wang X, Chen H, Yang L, *et al.* Cervical

kinematics and radiological changes after Discover artificial disc replacement versus fusion. Spine J 2014;14:867-77.

15. Lee SE, Jahng TA, Kim HJ. Correlation between cervical lordosis and adjacent segment pathology after anterior cervical spinal surgery. Eur Spine J 2015;24:2899-909.
16. Wu TK, Wang BY, Deng MD, Hong Y, Rong X, Chen H, *et al*. A comparison of anterior cervical discectomy and fusion combined with cervical disc arthroplasty and cervical disc arthroplasty for the treatment of skip-level cervical degenerative disc disease: A retrospective study. Medicine (Baltimore) 2017;96:e8112.
17. Zou S, Gao J, Xu B, Lu X, Han Y, Meng H. Anterior cervical discectomy and fusion (ACDF) versus cervical disc arthroplasty (CDA) for two contiguous levels cervical disc degenerative disease: A meta-analysis of randomized controlled trials. Eur Spine J 2017;26:985-97.