Spinal Intradural Extramedullary Capillary Hemangioma with Coexistent Spinal Edema and Syringomyelia Successfully Treated by Tumor Removal and Cervical Laminoplasty

Motohiro Takayama[1,2], Yoshinori Maki[2,3]

[1]Department of Neurosurgery, Otsu City Hospital, [2]Department of Neurosurgery, Biwako Ohashi Hospital, [3]Department of Rehabilitation, Hikari Hospital, Shiga, Japan

Abstract

Capillary hemangioma (CH) is usually found in pediatric patients and is located in soft tissue of the neck or head. As uncommon location of CH, spinal intradural extramedullary space has been reported; however, coexistent spinal edema or syringomyelia with spinal intradural extramedullary CH seems rare manifestations on preoperative magnetic resonance imaging. Laminectomy and tumor resection have been often performed for spinal intradural extramedullary CH. An 83-year-old man was referred to our hospital, complaining of nocturia and motor weakness of the lower extremities. Magnetic resonance imaging revealed a mass at the level of T1, which was homogeneously enhanced on gadolinium-enhanced T1-weighted images. The lesion was accompanied by spinal edema and syringomyelia. An intradural extramedullary tumor was first considered. We thought that the coexistent spinal edema and syringomyelia could have been caused by spinal stenosis. Preoperative angiography revealed that the mass was fed by the radicular artery of C5–C6. To improve the clinical symptoms of the patient, tumor removal and cervical laminoplasty were performed. The spinal edema and syringomyelia regressed postoperatively. The histopathological diagnosis was CH. This is the first reported case of cervical intradural extramedullary CH with spinal edema and syringomyelia successfully treated by cervical laminoplasty and tumor removal.

Keywords: *Angiography, intradural extramedullary capillary hemangioma, laminoplasty, spinal edema, syringomyelia, tumor removal*

Introduction

Capillary hemangioma (CH), a benign vascular tumor, is mostly found in the soft tissue of the head and neck such as skin, subcutaneous, or mucosal tissue in pediatric cases.[1,2] Spinal intradural extramedullary CH has been previously reported, but this entity is still considered to be rare.[3-6] Radiculopathy or myelopathy can result from the occupation of the spinal canal space by spinal CH.[4,7] Spinal intradural extramedullary CH shows varying intensity on T1- and T2-weighted magnetic resonance imaging (MRI) but usually demonstrates strong homogeneous enhancement with gadolinium contrast agent.[4] Coexistent spinal edema or syringomyelia with spinal intradural extramedullary CH has been previously described; however, the reported cases are still limited.[8-12]

Regarding to surgical treatment for spinal intradural extramedullary CH, laminectomy and tumor resection seem to be usually performed.[4] To the best of our knowledge, there has not been mentioned any case of spinal intradural extramedullary CH with coexistent spinal edema and syringomyelia successfully treated laminoplasty and tumor resection.[8-10,12,13]

Here, we report a rare case of cervical intradural extramedullary CH accompanied by spinal edema and syringomyelia treated with laminoplasty and tumor resection.

Case Report

An 83-year-old man was introduced to our department of neurosurgery. The patient was complaining of motor weakness of the bilateral lower extremities, which had gradually worsened. The motor weakness was observed mostly in the right leg and resulted in gait disturbance. The patient also mentioned numbness of the bilateral lower extremities, and thermal nociception was

Address for correspondence:
Dr. Motohiro Takayama,
2-9-9 Motomiya, Otsu,
Shiga 520-0804, Japan.
E-mail: gara1016@hotmail.com

Access this article online

Website: www.asianjns.org

DOI: 10.4103/ajns.AJNS_51_21

Quick Response Code:

This is an open access journal, and articles are distributed under the terms of the Creative Commons Attribution-NonCommercial-ShareAlike 4.0 License, which allows others to remix, tweak, and build upon the work non-commercially, as long as appropriate credit is given and the new creations are licensed under the identical terms.

For reprints contact: WKHLRPMedknow_reprints@wolterskluwer.com

How to cite this article: Takayama M, Maki Y. Spinal intradural extramedullary capillary hemangioma with coexistent spinal edema and syringomyelia successfully treated by tumor removal and cervical laminoplasty. Asian J Neurosurg 2021;16:854-71.

Submitted: 02-Feb-2021 **Revised:** 30-Apr-2021
Accepted: 23-May-2021 **Published:** 18-Dec-2021

© 2021 Asian Journal of Neurosurgery | Published by Wolters Kluwer - Medknow

dull under the bilateral inguinal region. The muscle tendon reflex of the lower extremities was bilaterally exacerbated, and Babinski reflex was positive. The patient was bothered by nocturia as well.

We first suspected lumbar spinal canal stenosis. MRI revealed, however, a lesion at the level of T1, which was homogeneously enhanced on gadolinium-enhanced T1-weighted image [Figure 1a and b]. The lesion was accompanied by spinal edema spreading from C1 to T8 and syringomyelia from the C5 to T6 [Figure 1c-e]. There were no findings of flow voids. The lesion was first considered an intradural extramedullary tumor, such as a meningioma or schwannoma. We thought that the coexistent spinal edema and syringomyelia could have resulted from cervical spinal stenosis. Therefore, we planned tumor removal and cervical laminoplasty. To evaluate the vascularity of the tumor, computed tomography angiography (CTA) was performed. The lesion seemed to be fed by the radicular artery of C5–C6 and drain to the venous plexus [Figure 1f]. On cerebral angiography performed for further examination of the tumor vascularity, the right radicular artery of C5–C6 was recognized as a single feeder [Figure 1g]. The tumor was not fed by the left ascending cervical artery or the vertebral arteries.

After we performed CTA and cerebral angiography, we reconsidered that the lesion could be a vascular tumor. However, we did not think that we had to alter the surgical planning. Prior to the ooeration. We obtained informed consent from the oatient.

Operation

The patient was placed in the supine position. Transcranial motor-evoked potential was intraoperatively monitored. A 4-Fr sheath was inserted into the right femoral artery, and a catheter was introduced in the right radicular artery to inject intraoperatively indocyanine green. Mild

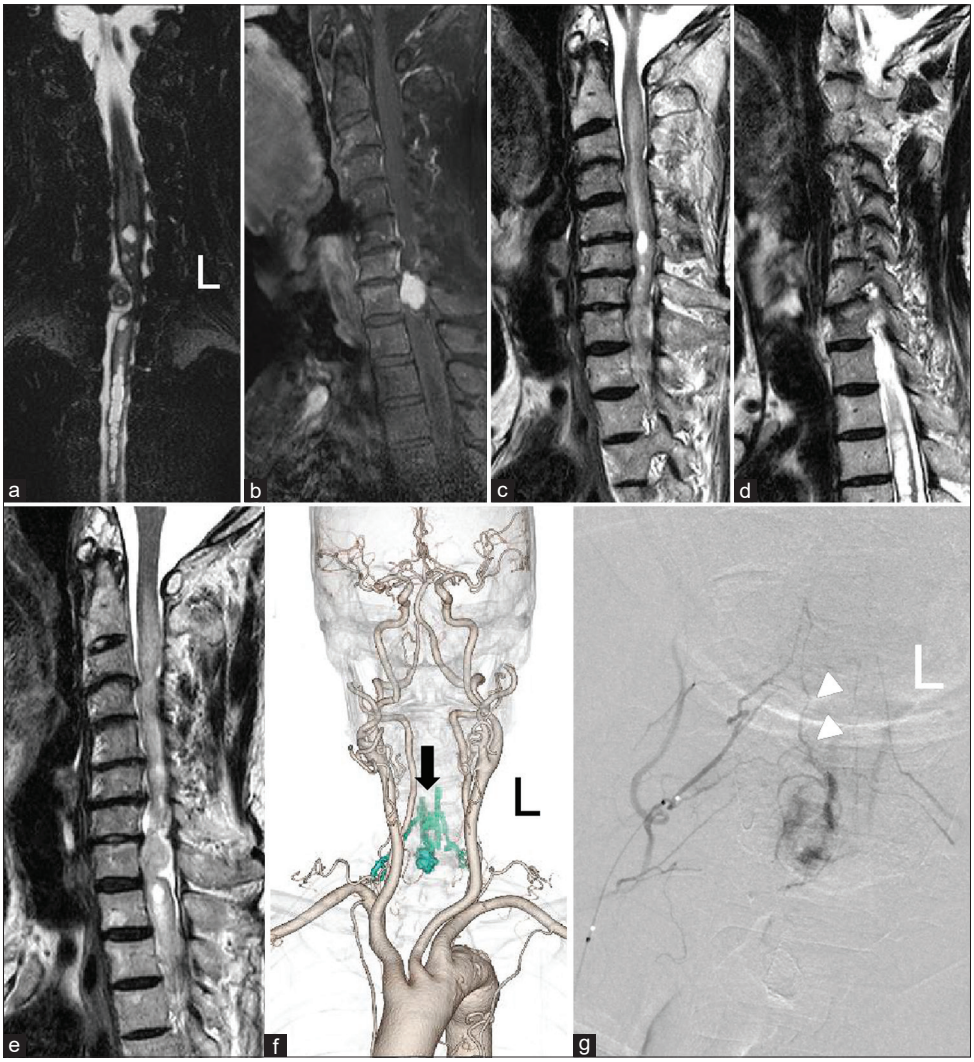

Figure 1: Preoperative imaging (L: Left). (a) T2-weighted MRI; (b) Gadolinium-enhanced T1-weighted MRI) an intradural extramedullary tumor was suspected. The tumor was homogeneously enhanced. (c-e) Spinal edema and syringomyelia are observed on T2-weighted MRIs. (f) Three-dimensional reconstructed CTA showing that the lesion is fed by a right radicular artery of C5–C6 (black arrow). (g) A right vertebral angiogram showing that the right radicular artery of C5-6 is a feeder of the lesion (white arrow heads). MRI – Magnetic resonance imaging; CTA – Computed tomography angiography

heparinization was intraoperatively performed to avoid embolic complications. The patient was then set in the prone position. Following a midline skin incision and the detachment of the paraspinal muscle from the vertebrae at the level of C3–T1, the vertebral arch was opened, and the dura was exposed. The dura was medially opened, and then a mass was observed [Figure 2a]. The lesion was then evaluated with indocyanine green. The lesion was superficially enhanced after the feeder was visualized [Figure 2b]. The lesion was detached from the caudal side and partially thrombosed. The tumor was entirely detached from the spine and the feeder was finally cut [Figure 2c]. Intraoperative bleeding from the lesion did not occur. Indocyanine green was intra-arterially injected again, and we confirmed that the tumor was not apparently residual [Figure 2d]. Then, cervical laminoplasty was performed [Figure 2e and f]. No remarkable change was observed in the motor-evoked potentials.

Postoperative course

Disappearance of the spinal edema and regression of syringomyelia were confirmed on postoperative MRI [Figure 3]. The patient's postoperative course was uneventful. Preoperative symptoms were resolved, and the patient was discharged from the hospital on postoperative day 15. He is now followed in an outpatient clinic. The spinal edema and syringomyelia disappeared without apparent recurrence of the vascular tumor on MRI performed 3 years and 2 months after the surgery [Figure 4].

Histopathological findings

On hematoxylin and eosin staining, the tumor was observed to be composed of a lobular aggregation of increased vessel epithelium. The tumor was partially enveloped by the meninges and hyalinized connective tissue. Nerve tissue was found along the outer margin of the tumor. Red blood cells were observed in the vessels. Immunohistologically, the tumor was positive for CD31, CD34, and αSAM. Any malignant findings were identified. These findings corresponded to CH [Figure 5].

Discussion

Here, we presented a rare case of spinal intradural extramedullary CH accompanied by spinal edema and syringomyelia. Our case was successfully treated with tumor removal and laminoplasty.

CH is generally found in pediatric cases.[3] The typical locations of CH are the skin, the subcutaneous tissue, or the mucosa in a head or neck lesion.[3-6] When CH develops in the spine, CH is usually found in the vertebral body, and extraosseous lesions of the spine seem to be rare.[14] Spinal CH can be seen as an intradural extramedullary lesion when CH appears in the neuroaxis.[4,10] Spinal intradural extramedullary CH with detailed description has been previously reported [Table 1].[1,3,4,6-13,15-36] An adult case of spinal intradural extramedullary CH was first reported by Hanakita *et al*.[24] The clinical symptoms related to spinal intradural extramedullary CH are chronic progressive myelopathy or radiculopathy resulting in motor or sensory deficits, though acute neurological aggravation due to intratumoral bleeding of intradural extramedullary CH has been reported.[10,31,34] Neurological deficits in our case were gradually progressing as typical manifestations of spinal intradural extramedullary CH.

Regarding the radiological features in our case, homogeneous enhancement of the tumor on gadolinium-enhanced T1-weighted MRI was observed. We first thought that the tumor was a common intradural extramedullary tumor such as meningioma or neurinoma, but a vascular tumor was successfully found on CTA and cervical angiography preoperatively performed to evaluate the vascularity of the tumor.

Spinal intradural extramedullary CH can show different intensities on T1-weighted or T2-weighted MRIs and

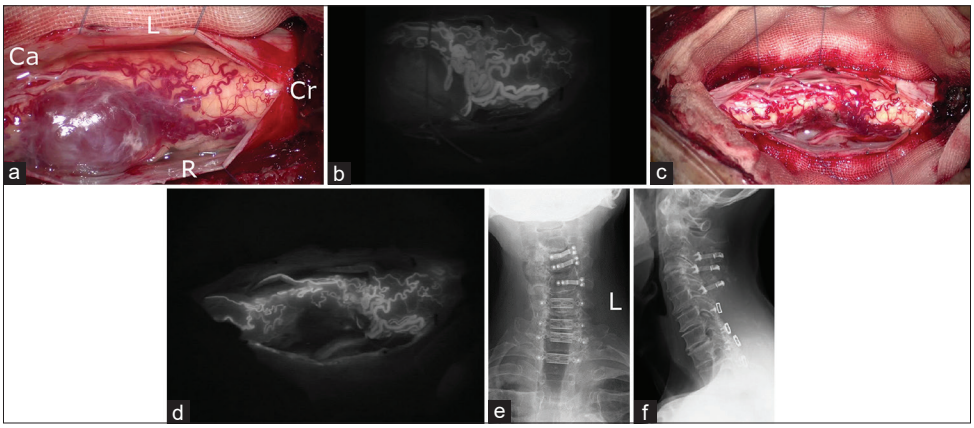

Figure 2: Intraoperative imaging (L: Left). (a) After opening the dura, the intradural extramedullary tumor was detected. The tumor is compressing the spinal cord (Ca: Caudal; Cr: Cranial; R: Right). (b) The tumor feeder and drainer are visualized with indocyanine green. (c) The tumor is removed. (d) Total removal of the tumor is confirmed with indocyanine green. (e) Posterior-anterior projection of X-ray; (f) Lateral projection of X-ray. Laminoplasty from C3 to T2 was also performed

Figure 3: Postoperative MRI. Spinal edema and syringomyelia regressed postoperatively. MRI – Magnetic resonance imaging

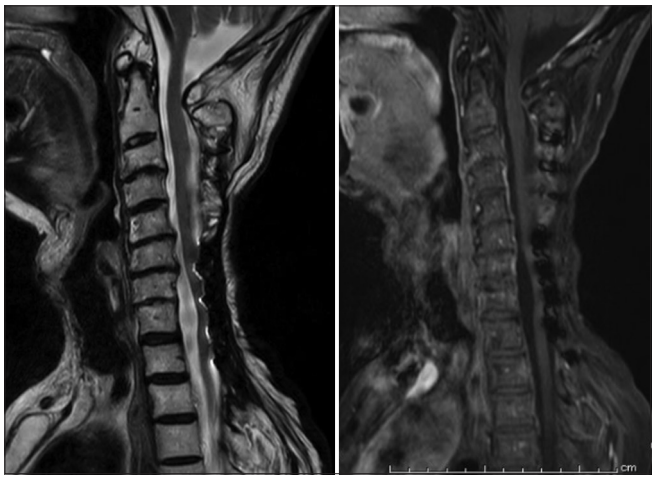

Figure 4: Follow-up MRI (3 years and 2 months after the surgery). Spinal edema and syringomyelia resolved. The recurrence of the tumor was not apparent (left: T2-weighted MRI; right: Gadolinium-enhanced T1-weighted MRI). MRI – Magnetic resonance imaging

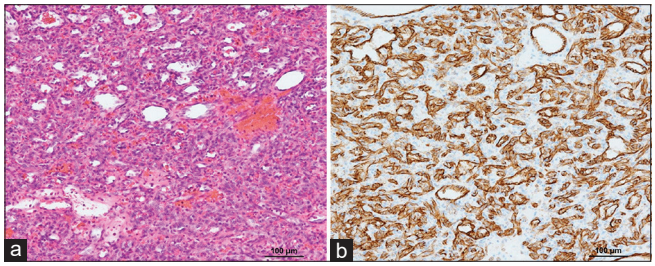

Figure 5: Pathological findings. Lobular structure composed of increased epithelium of capillary vessels is observed. Fibroblast-like cells, lymphocytes, and macrophages are recognized among the capillary vessels. Atypical cells are not observed (a). The tumor is positive for CD31 (b)

shows strong homogeneous enhancement with gadolinium contrast agent.[4,7,12] Neurinoma or meningioma can also show strong enhancement on MRI, so neurinoma without cystic change or necrosis cannot be easily differentiated from spinal CH.[7] The dural tail sign, considered a typical feature of meningioma, cannot completely rule out spinal CH because spinal intradural extramedullary CH can arise from the inner surface of the dura mater.[7] Thus, MRI findings alone are not sufficient to differentiate spinal intradural extramedullary CH from neurinoma or meningioma. Preoperative angiography can be useful for preoperative possible diagnosis, as in our case. As we suspected a spinal vascular tumor, we intraoperatively evaluated the feeder and drainers of the tumor with indocyanine green injected through a catheter placed in the feeder. Intradural extramedullary vascular tumors need to be differentiated from arteriovenous malformations.[7] Due to the lack of flow void on preoperative MRI, arteriovenous malformation seemed not to be possible in our case. Hemangioendothelioma is reported to be rare, although it shows similar radiological findings on MRI to spinal CH.[7]

In addition to the radiological findings of spinal CH on MRI, the preoperative radiological findings, spinal edema and syringomyelia, are of interest in our case. Among the previously reported cases of spinal intradural extramedullary CH, coexistent spinal edema or syringomyelia was disclosed on preoperative MRI in five cases.[8-12] In the case reported by Lee *et al*., preoperative syringomyelia on the conus medullaris and arachnoiditis were confirmed on MRI.[9] Lee *et al*. speculated that the disturbed circulation of cerebrospinal fluid below spinal intradural extramedullary CH and possible minute bleeding from spinal intradural extramedullary CH could have been causative for syringomyelia and arachnoiditis.[9] In their case, preoperative syringomyelia on the conus medullaris and arachnoiditis aggravated even 1 year after the surgery on MRI. They discussed that intraoperative bleeding could have been responsible for the residual radiological findings.[9] Intraoperative bleeding should be avoided not to result in such complications. In our case, spinal intradural extramedullary hemangioma was partially thrombosed and the single feeder was preoperatively detected. These conditions in our case could be favorable to prevent from bleeding of spinal intradural extramedullary CH.

Our patient was treated successfully with removal of spinal intradural extramedullary CH and laminoplasty, as we thought that his neurological symptoms resulted from spinal intradural extramedullary CH and cervical spinal stenosis. The etiologies of syringomyelia include Chiari malformation, meningitis, intramedullary tumors, hemorrhage, and posttraumatic spinal injuries.[37] However, syringomyelia related to spinal stenosis has been also reported.[37-40] In the previous reported cases, the syringomyelia regressed after surgery. Epidural compression by cervical stenosis has been postulated as a mechanism in the formation of syringomyelia.[37] Thus, spinal canal stenosis could also have been a cause in our case. Syringomyelia associated with spinal arteriovenous fistula has been described as well.[41] In that report, syringomyelia mostly disappeared

Table 1: Past cases of spinal intradural extramedullary capillary hemangioma

Article (author, year)	Age (years), sex	Clinical symptoms	Preoperative MRI findings	Tumor location	Preopetative angiography	Preoperative differential diagnosis	Treatment	Postoperative MRI findings	Outcome	Concomitant lesions
Abdullah *et al*., 2004[15]	32, female	Lower back pain, lower extremity weakness Sensory disturbance at the level of T9	Isointensity on T1-weighted images Hyperintensity on T2-weitghted images Intense enhancement on contrast-enhanced T1-weighted images	T10	Performed after the first operation The tumor fed by the left T11 intercostal artery and radiculomedullary arteries. The draining veins also conformed	Meningioma	T9-T10 laminectomy (the first operation) tumor resection (the second operation)	No residual tumor Spinal edema at the site of tumor resection	Improved	
Alakandy *et al*., 2006[16]	60, male	Lower back pain, motor weakness of both lower limbs Sensory disturbance of right lower limb and below the left knee	Hyperintensity in T2-weighted images with venous flow voids. Enhancement on contrast-enhanced T1-weighted images	T9	Not mentioned	Not mentioned	Tumor resection	Not mentioned	Improved	
Alobaid *et al*., 2015[8]	46, female	Bilateral leg weakness Right side groin numbness and saddle anesthesia	Isointensity on T1-weighted images Hyperintensity on T2-weitghted images Homogeneous enhancement on contrast-enhanced T1-weighted images Spinal edema	T11-12	Not mentioned	Meningioma	T11-T12 laminectomy Tumor resection	Not mentioned	Severe sensory ataxia due to posterior cord syndrome Recovered with rehabilitation therapy 3 months after the surgery	Cavemous hemangioma also diagnosed with pathological findings
Andaluz *et al*., 2002[17]	41, male	Severe back pain radiated bilaterally to the posterior thighs	Hyperintensity in T2-weighted images Enhancement on contrast-enhanced T1-weighted images	Conus medullaris	Not mentioned	Meningioma or schwannoma	T11-L1 laminectomy Tumor resection	No tumor recurrence 6 months after operation	Improved	

Contd...

Table 1: Contd...

Article (author, year)	Age (years), sex	Clinical symptoms	Preoperative MRI findings	Tumor location	Preopetative angiography	Preoperative differential diagnosis	Treatment	Postoperative MRI findings	Outcome	Concomitant lesions
Bouali *et al.*, 2016[4]	29, male	Posterior neck pain, numbness of the distal upper extremity, right-sided paresthesia, gait disturbance, motor weakness in the right leg	Isointensity on T1-weighted images Slightly hyperintensity on T2-weitghted images Homogeneous enhancement on contrast-enhanced T1-weighted images	C1	Not mentioned	Neurogenic tumor or meningioma	C1 hemilaminectomy Tumor resection	Not mentioned	Improved	
Cheng and Lu, 2020[18]	54, male	Numbness below the nipples, backache, paralysis and urinary retention	Slightly hyperintensity on T1-weighted images Slightly hyperintensity on T2-weitghted images Significant enhancement on contrast-enhanced T1-weighted images	T3	Not mentioned	Hemangioma	Laminectomy and instrumentation Tumor resection	No recurrence of the tumors 5 years after operation	Only middle backache remained	Concomitant epidural angiolipoma
Choi *et al.*, 2001[7]	28, male	Left gluteal and back pain, motor weakness of lower extremities and paresthesia	Isointensity on T1-weighted images Slightly hyperintensity on T2-weitghted images Strong homogeneous enhancement on contrast-enhanced T1-weighted images	L1	Not mentioned	Not mentioned	Tumor resection	Not mentioned	Not mentioned	

Contd...

Table 1: Contd...

Article (author, year)	Age (years), sex	Clinical symptoms	Preoperative MRI findings	Tumor location	Preopetative angiography	Preoperative differential diagnosis	Treatment	Postoperative MRI findings	Outcome	Concomitant lesions
Choi *et al*., 2001[7]	52, male	Claudication, hypoesthesia, paresthesia and motor weakness of the lower extremities	Isointensity on T1-weighted images hyperintensity on T2-weitghted images strong homogeneous enhancement on contrast- enhanced T1-weighted images Dural tail sign	T5-T6	Not mentioned	Meningioma	Tumor resection	Not mentioned	Not mentioned	
Choi *et al*., 2001[7]	51, male	Claudication, radiating pain of the lower extremities	Isointensity on T1-weighted images Strong homogeneous enhancement on contrast-enhanced T1-weighted images Dural tail sign	T4-T5	Not mentioned	Meningioma	Tumor resection	Not mentioned	Not mentioned	
Chung *et al*., 2010[19]	47, male	Back pain of the lower thoracic area radiating pain down to both legs Sensory impairment below T7	Isointensity on T1-weighted images Heterogeneously isointensity on T2-weitghted images Strong homogeneous enhancement on contrast-enhanced T1-weighted images	T6-T7	Not mentioned	Not mentioned	Laminectomy and laminoplasty of T6-T7 Tumor resection	Not mentioned	Improved	

Contd...

Table 1: Contd...

Article (author, year)	Age (years), sex	Clinical symptoms	Preoperative MRI findings	Tumor location	Preopetative angiography	Preoperative differential diagnosis	Treatment	Postoperative MRI findings	Outcome	Concomitant lesions
Crispino *et al*., 2005[20]	65, male	Paraparesis, upper thoracic back pain, motor weakness of both legs	Isointensity on T1-weighted images Hyperintensity on T2-weitghted images Strong homogeneous enhancement on contrast-enhanced T1-weighted images	T1-T2	Not mentioned	Neurinoma. meningioma, metastasis and hemangioma	C1 hemilaminectomy Tumor resection	No recunence of the tumor 6 months after operation	Improved	
Funayama *et al*., 2010[21]	34, male	Nocturnal mild pain in the lower back, pain and motor weakness in the left leg	Hypointensity on T1-weighted images Hypointensity on T2-weitghted images Homogeneous enhancement on contrast-enhanced T1-weighted images	L4	Not mentioned	Neurinoma	Left L4 hemilaminectomy Tumor resection	No recunence of the tumor 1 year after operation	No symptoms remained 1 year after operation	
Ganapathy *et al*., 2008[22]	17, male	S1 radiculopathy and constipation	Isointensity on T1-weighted images Mild hyperintensity on T2-weitghted images Strong homogeneous enhancement on contrast-enhanced T1-weighted images	L2-L3	Not mentioned	Not mentioned	L2-L3 laminectomy Tumor resection	Not mentioned	Not mentioned	

Contd...

Table 1: Contd...

Article (author, year)	Age (years), sex	Clinical symptoms	Preoperative MRI findings	Tumor location	Preopetative angiography	Preoperative differential diagnosis	Treatment	Postoperative MRI findings	Outcome	Concomitant lesions
Ghazi *et al*., 2006[23]	42, male	Headache, visual obscurations, pulsatile tinnitus lower back pain radiating to the right leg	Ill-defined lesion on T1-weighted images Hypointensity on T2-weitghted images Intense homogeneous enhancement on contrast-enhanced T1-weighted images	L3-L4	Not mentioned	Schwannoma	L3-L4 laminectomy Tumor resection	Not mentioned	Completely resolved	
Hanakita *et al*., 1991[24]	58, male	Severe back pain and leg pain sensory disturbance of left L5 and bilateral S1	Slight hyperintensity on T1-weighted images clear enhancement on contrast- enhanced T1-weighted images	L1-L2	The tumor fed by the left T9 intercostal artery faint tumor stain	Arteriovenous malformation	T12-L2 laminectomy Tumor resection	Not mentioned	Not mentioned	
Holtzman *et al*., 1999[3]	55, female	Right sciatica and low back pain and hypoalgesia in the right S-1 dermatome	Enhancement on contrast-enhanced T1-weighted images	L4	Not mentioned	Not mentioned	L3-L5 laminectomy Tumor resection	No residual tumor	Residual rig hl S1 radiculopathy	
Kaneko *et al*., 2012[1]	48, male	Low back pain, mild motor weakness of the both legs and Romberg's sign positive	Isointensity on T1-weighted image Hyperintensity on T2-weitghted images Intense homogeneous enhancement on contrast-enhanced T1-weighted images	T10-T11	Not mentioned	Not mentioned	T10-T11 laminectomy Two sessions of tumor resection (also for recurrence)	Tumor recurrence 6 months after the first operation No recurrence 9 years after the decond operation	Slight persisted numbness of the right thigh Hypoesthesia in the right T10 dermatome	

Contd...

Table 1: Contd...

Article (author, year)	Age (years), sex	Clinical symptoms	Preoperative MRI findings	Tumor location	Preopetative angiography	Preoperative differential diagnosis	Treatment	Postoperative MRI findings	Outcome	Concomitant lesions
Kim *et al*., 2006[25]	59, male	Low back pain, left leg pain and paresthesia in the L4, L5 and S1 dermatome	Hyperintensity on T2-weitghted images Homogeneous enhancement on contrast-enhanced T1-weighted images	L1-L2	Not mentioned	Not mentioned	L1-L2 laminectomy Tumor resection	No residual tumor	Improved	
Lee *et al*., 2017[9]	60, male	Hypoesthesia in the trunk below T4 sensory dermatome, gait disturbance and thoracic girdle pain	Isointensity on T1-weighted images Relatively hyperintensity on T2-weitghted images Intense homogeneous enhancement on contrast-enhanced T1-weighted images Dural tail sign, arachoniditis below the tumor level, flow voids and syrinx in the conus medullaris	T2-T3	Not mentioned	Meningioma	T2 total laminectomy and T3 subtotal laminectomy Tumor resection	Complete resection of the tumor Sustained arachnoiditis and progression of the syrinx	Improved	
Liu *et al*., 2015[26]	53, male	Back pain, motor weakness of the right leg, numbness of the right entire foot, increased urinary frequency and nocturia	Isointensity on T1-weighted images Iso-to mildly hyperintensity on T2-weitghted images Intense homogeneous enhancement on contrast-enhanced T1-weighted images	L3-L4	Not mentioned	Not mentioned	L3-L4 laminectomy En block fashioned tumor resection with sacrifice of a involved nerve	Gross total tumor resection	Improved	

Contd...

Table 1: Contd...

Article (author, year)	Age (years), sex	Clinical symptoms	Preoperative MRI findings	Tumor location	Preopetative angiography	Preoperative differential diagnosis	Treatment	Postoperative MRI findings	Outcome	Concomitant lesions
Mastronardi *et al.*, 1997[27]	41, male	Intermittent low-back pain radiating on the lateral surface of the left inferior limb	Slightly hyperintensity on T1-weighted images Isointensity on T2-weitghted images	L5	Not mentioned	Not mentioned	L5 laminectomy Tumor resection	Not mentioned	Improved except L5 sensory deficit	
Miri *et al.*, 2009[28]	20, male	Low back pain radiating to the legs, urinary retention, impotence, retrograde ejaculation, bilateral motor weakness of the knee and paresthesia of both feet	Isointensity on T1-weighted images Iso- to hyperintensity on T2-weitghted images Remarkable homogeneous enhancement on contrast-enhanced T1-weighted images	L3-L4	Not mentioned	Schwannoma	L3 laminectomy Tumor resection	No evident recurrence 1 year after surgery	Improved	
Nowak *et al.*, 2000[29]	63, female	Hypoesthesia and lumbalgia radiating from the lower back to the ventral surface of the left upper leg	Slightly hyperintensity on T1-weighted images Isointensity on T2-weitghted images Homogeneous enhancement on contrast-enhanced T1-weighted images Vascular structures confirmed	T12- L1	Not mentioned	Not mentioned	T12 laminectomy Tumor removal with sacrifice of two nerves of the cauda equina	Complete resection of the tumor 3 months after surgery	Paresis of the tibialis anterior muscle remained on discharge (4 weeks after operation)	

Contd...

Table 1: Contd...

Article (author, year)	Age (years), sex	Clinical symptoms	Preoperative MRI findings	Tumor location	Preopetative angiography	Preoperative differential diagnosis	Treatment	Postoperative MRI findings	Outcome	Concomitant lesions
Panero *et al*., 2017[10]	58, male	Motor weakness and paresthesias in both legs, urinary and fecal retention	Iso- to hyperintensity on T1-weighted images Iso- to mildly hyperintensity on T2-weitghted images Homogeneous enhancement on contrast-enhanced T1-weighted images Perilesional edema	T10-T11	Not mentioned	Meningioma, neurinoma, or a vascular intradural -extramedullary tumor	T10-T11 laminectomy Tumor en block resection	Not mentioned	Mild gait alteration (18-month follow-up)	
Pignotti *et al*., 2015[30]	45, female	Low-back pain	Intense homogeneous enhancement on contrast-enhanced T1-weighted images	L2	Not mentioned	Not mentioned	L1-L2 laminectomy Removal of the tumor and pathological nerve	Not mentioned	Mild hyposthenia in the left leg (recovered totally 3-month follow-up)	
Roncaroli *et al*., 2000[31]	64, male	Pain and motor weakness of the legs	Not mentioned	T10	Not mentioned	Not mentioned	Surgery	Not mentioned	Recovery at 9 years follow-up	
Roncaroli *et al*., 2000[31]	74, male	Motor weakness of bilateral legs, gait disturbance, urinary frequency and sensory loss in both lower extremities below the knee	Slightly hyperintensity on T1-weighted images Slightly hyperintensity on T2-weitghted images Inhomogeneous enhancement on contrast-enhanced T1-weighted images	Multiple lesions from the lower thoracic level to conus medullaris	Not mentioned	Metastasis, lymphoma or renal cell carcinoma	L2-3 laminectomy Resection of two largest nodules with a segment of involved root	Not mentioned	No remarkably changed	

Contd...

Table 1: Contd...

Article (author, year)	Age (years), sex	Clinical symptoms	Preoperative MRI findings	Tumor location	Preopetative angiography	Preoperative differential diagnosis	Treatment	Postoperative MRI findings	Outcome	Concomitant lesions
Sharma *et al*., 2014[12]	55, male	Pain on the back of head radiating to left upper limb up to the little finger Numbness and paresthesia of left sided limbs and stiffness of left shoulder	Isointensity on T1-weighted images Hyperintensity on T2-weitghted images Intense homogeneous enhancement on contrast-enhanced T1-weighted images Edema (C5-C7)	C7	Not mentioned	Meningioma, schwannoma, metastasis or capillary hemangioma	C5-C7 laminectomy Tumor resection	Not mentioned	Paresthesia and spasticity partially relieved	
Shi *et al*., 2017[11]	73, male	Gait disturbance, motor weakness of the right leg, and paresthesia of both lower limbs	Isointensity on T1-weighted images slightly hyperintensity on T2-weitghted images Homogeneous enhancement on contrast- enhanced T1-weighted images flow voids	T11-T12	Not mentioned	Not mentioned	T11-T12 laminectomy Tumor resection	Total removal of the lesion 4 weeks after surgery	Muscle strength of the lower extremities declined and sensory disturbance below T12 (improved 4 weeks after surgery)	
Shin *et al*., 2000[13]	66, female	Lower back pain and motor weakness of the lower extremities	Isointensity on T1-weighted images Hyperintensity on T2-weitghted images Intense homogeneous enhancement on contrast-enhanced T1-weighted images	T8-T9	Not mentioned	Not mentioned	T8-T9 laminectomy Tumor incomplete resction	No definite residual tumor (6 months follow-up) resolution of the preoperative edema	Improved	Intramedullary component

Contd...

Table 1: Contd...

Article (author, year)	Age (years), sex	Clinical symptoms	Preoperative MRI findings	Tumor location	Preopetative angiography	Preoperative differential diagnosis	Treatment	Postoperative MRI findings	Outcome	Concomitant lesions
			Edema (T4-conus medullaris)							
Sonawane *et al*., 2012[32]	35, male	Back pain, motor weakness in both lower limbs and hypoesthesia below L3	Isointensity on T1-weighted images Hyperintensity on T2-weitghted images Homogeneous enhancement on contrast-enhanced T1-weighted images	T12	Not mentioned	Not mentioned	T11-T12 laminectomy Tumor resection	Not mentioned	Complete recovery	
Takata *et al*., 2014[33]	60, male	Gait disturbance and loss of vibration sensation below the knee	Hypo- to isointensity on T1-weighted images Hyperintensity on T2-weitghted images Strong homogeneous enhancement on contrast-enhanced T1-weighted images Vascular structure	T2	Not mentioned	Neurogenic tumor or vascular malformation	T1-T2 hemilaminectomy Tumor resection	No recunence of the tumor 2 years after operation	Right T3 sensory deficit persisted	
Tunthanathip *et al*., 2017[34]	15, male	Coccygodynia	Isointensity on T1-weighted images Hyperintensity on T2-weitghted images Strong homogeneous enhancement on contrast-enhanced T1-weighted images	L1	The tumor was supplied by the anterior spinal artery	Not mentioned	Embolization T12-L1 laminectomy Tumor resection	Not mentioned	Urinary retention postoperatively which resolved 3-month follow-up	

Contd...

Table 1: Contd...

Article (author, year)	Age (years), sex	Clinical symptoms	Preoperative MRI findings	Tumor location	Preopetative angiography	Preoperative differential diagnosis	Treatment	Postoperative MRI findings	Outcome	Concomitant lesions
Unnithan *et al*., 2016[35]	54, female	Low backache, numbness in the left lateral leg, pain in left L5 dermatome and mild weakness of foot	Isointensity on T1-weighted images Slightly hyperintensity on T2-weitghted images Intense homogeneous enhancement on contrast-enhanced T1-weighted images	L4-L5	Not mentioned	Schwannoma	L4 laminectomy Tumor resection	Complete removal of the tumor	Improved	
Zander *et al*., 1998[36]	51, female	Low back pain, right leg sciatica and mild weakness of right leg dorsireflexion	Heterogenously hyperintensity on T1-weighted images Homogeneously hypointensity on T2-weitghted images	L4-L5	Not mentioned	Disc protrusion	L4-L5 laminectomy Tumor resection	Not mentioned	Not mentioned	
Zhu and He, s 2016[6]	59, female	Backache and right lower limb numbness	Isointensity on T1-weighted images Slightly hyperintensity on T2-weitghted images Markedly homogeneous enhancement on contrast-enhanced T1-weighted images	T8	Not mentioned	Meningioma	T7-T8 laminectomy Tumor resection	No recunence of the tumor 2 years after operation	Symptoms resolved 2 months after surgery	
Present case	83, male	Motor weakness and numbness of the bilateral lower extremities and nocturia	Isointensity on T2-weitghted images	T1	The tumor was supplied by the radicular artery of C5-6	Vascular tumor	C3 to T2 laminoplasty Tumor resection	Disappearance of the spinal edema	Preoperative symptoms resolved	

Contd...

Table 1: Contd...

Article (author, year)	Age (years), sex	Clinical symptoms	Preoperative MRI findings	Tumor location	Preopetative angiography	Preoperative differential diagnosis	Treatment	Postoperative MRI findings	Outcome	Concomitant lesions
			Homogeneous enhancement on contrast-enhanced T1-weighted images Spinal edema from C1 to T8 and syringomyelia from C5 to T6					Regression of the syringomyelia tumor resection		

MRI – Magnetic resonance imaging

6 months after embolization of the spinal arteriovenous fistula. The authors did not determine the relation between the syringomyelia and spinal arteriovenous fistula to be coincidental or causative.[41] However, we think that venous congestion due to spinal arteriovenous fistula could have been a cause for syringomyelia in the reported case, as venous congestion-related hypervascular tumor with arteriovenous shunts has been speculated as a cause of edema and syringomyelia.[42] Syringomyelia in our case was not accompanied by spinal arteriovenous fistula but by spinal intradural extramedullary CH. Venous congestion due to spinal intradural extramedullary CH might have caused the syringomyelia. Preoperative spinal edema might have also resulted from epidural compression by spinal canal stenosis and venous congestion due to cervical intradural extramedullary CH. However, as ours is the first reported case of spinal intradural extramedullary CH accompanied with spinal edema and syringomyelia treated by laminoplasty and tumor resection, further similar case reports are needed to determine the detailed mechanisms.

Concerning management options of spinal intradural extramedullary CH, surgical resection seems to be standard treatment, especially in cases that the spinal cord is strongly compressed by spinal intradural extramedullary CH. As the spinal intradural extramedullary CH in our case was fed by a single feeder, preoperative embolization was not performed. However, if intraoperative bleeding risk is estimated to be high due to hypervascularity of the spinal intradural extramedullary CH, preoperative embolization can be effective.[43] Radiation therapy may be also an option to prevent the recurrence of spinal intradural extramedullary CH.[43] The patient in our case is followed for approximately 3 years without recurrence of the spinal intradural extramedullary CH. In case that the recurrence of the spinal intradural extramedullary CH is confirmed on postoperative images, solely surgical resection or combined management of surgical resection and embolization (or radiation therapy) should be considered according to the size of recurrent spinal intradural extramedullary CH.

Conclusion

We reported a case of spinal intradural extramedullary CH that showed preoperative spinal edema and syringomyelia as rare manifestations. The spinal edema and syringomyelia might have resulted from venous congestion of cervical intradural extramedullary CH and coexistent cervical canal stenosis. Removal of cervical intradural extramedullary CH and laminoplasty were effective in our case.

Acknowledgment

We appreciate Drs. Ryota Ishibashi, Naoko Masuzawa, and Shinshichi Hamada, for their collaboration of this study. We would like to thank Editage (www.editage.com) for English language editing.

Financial support and sponsorship

Nil.

Conflicts of interest

There are no conflicts of interest.

References

1. Kaneko Y, Yamabe K, Abe M. Rapid regrowth of a capillary hemangioma of the thoracic spinal cord. Neurol Med Chir (Tokyo) 2012;52:665-9.
2. Naruke Y, Horie H, Nagai Y, Ando R. Capillary hemangioma involved in filar lipoma: A case report. Clin Neuropathol 2019;38:33-7.
3. Holtzman RN, Brisson PM, Pearl RE, Gruber ML. Lobular capillary hemangioma of the cauda equina. Case report. J Neurosurg 1999;90:239-41.
4. Bouali S, Maatar N, Bouhoula A, Abderrahmen K, Kallel J, Jemel H. Intradural extramedullary capillary hemangioma in the upper cervical spine: First report. World Neurosurg 2016;92:587.e1-7.
5. Nowak DA, Widenka DC. Spinal intradural capillary haemangioma: A review. Eur Spine J 2001;10:464-72.
6. Zhu K, He D. Intradural extramedullary capillary hemangioma: A case report and review of the literature. Oncol Lett 2016;11:2896-8.
7. Choi BY, Chang KH, Choe G, Han MH, Park SW, Yu IK, *et al.* Spinal intradural extramedullary capillary hemangioma: MR imaging findings. AJNR Am J Neuroradiol 2001;22:799-802.
8. Alobaid A, Bennardo MR, Cenic A, Lach B. Mixed capillary-cavernous extramedullary intradural hemangioma of the spinal cord mimicking meningioma: Case report. Br J Neurosurg 2015;29:438-9.
9. Lee JH, Jeon I, Kim SW. Intradural extramedullary capillary hemangioma in the upper thoracic spine with simultaneous extensive arachnoiditis. Korean J Spine 2017;14:57-60.
10. Panero I, Eiriz C, Lagares A, Toldos O, Panero A, Paredes I. Intradural-extramedullary capillary hemangioma with acute bleeding: Case report and literature review. World Neurosurg 2017;108:988.e7-14.
11. Shi CZ, Shen J, Zheng CT, Zhan RY. A case of giant intradural extramedullary capillary hemangioma. Chin Med J (Engl) 2017;130:251-2.
12. Sharma K, Sharma UK, Sigdel B. Cervical capillary haemangioma: A case report. Kathmandu Univ Med J (KUMJ) 2014;12:211-4.
13. Shin JH, Lee HK, Jeon SR, Park SH. Spinal intradural capillary hemangioma: MR findings. Am J Neuroradiol 2000;21:954-6.
14. Cetinkal A, Colak A, Topuz K, Atabey C, Berber U. Capillary hemangioma of the cervical intervertebral disc. Eur Spine J 2011;20 Suppl 2:S157-60.
15. Abdullah DC, Raghuram K, Phillips CD, Jane JA Jr., Miller B. Thoracic intradural extramedullary capillary hemangioma. Am J Neuroradiol 2004;25:1294-6.
16. Alakandy LM, Hercules S, Balamurali G, Reid H, Herwadkar A, Holland JP. Thoracic intradural extramedullary capillary haemangioma. Br J Neurosurg 2006;20:235-8.
17. Andaluz N, Balko MG, Stanek J, Morgan C, Schwetschenau PR. Lobular capillary hemangioma of the spinal cord: Case report and review of the literature. J Neurooncol 2002;56:261-4.
18. Cheng Y, Lu K, Jiang H. Epidural angiolipoma with concomitant intradural extramedullary capillary hemangioma at the same spinal level: A case report. Oncol Lett 2020;20:209-14.
19. Chung SK, Nam TK, Park SW, Hwang SN. Capillary hemangioma of the thoracic spinal cord. J Korean Neurosurg Soc 2010;48:272-5.
20. Crispino M, Vecchioni S, Galli G, Olivetti L. Spinal intradural extramedullary haemangioma: MRI and neurosurgical findings. Acta Neurochir (Wien) 2005;147:1195-8.
21. Funayama T, Sakane M, Murai S, Ochiai N. Multiple capillary hemangiomas of the cauda equina at a level of a single vertebra. J Orthop Sci 2010;15:598-602.
22. Ganapathy S, Kleiner LI, Mirkin LD, Hall L. Intradural capillary hemangioma of the cauda equina. Pediatr Radiol 2008;38:1235-8.
23. Ghazi NG, Jane JA, Lopes MB, Newman SA. Capillary hemangioma of the cauda equina presenting with radiculopathy and papilledema. J Neuroophthalmol 2006;26:98-102.
24. Hanakita J, Suwa H, Nagayasu S, Suzuki H. Capillary hemangioma in the cauda equina: Neuroradiological findings. Neuroradiology 1991;33:458-61.
25. Kim KJ, Lee JY, Lee SH. Spinal intradural capillary hemangioma. Surg Neurol 2006;66:212-4.
26. Liu JJ, Lee DJ, Jin LW, Kim KD. Intradural extramedullary capillary hemangioma of the cauda equina: Case report and literature review. Surg Neurol Int 2015;6:S127-31.
27. Mastronardi L, Guiducci A, Frondizi D, Carletti S, Spera C, Maira G. Intraneural capillary hemangioma of the cauda equina. Eur Spine J 1997;6:278-80.
28. Miri SM, Habibi Z, Hashemi M, Meybodi AT, Tabatabai SA. Capillary hemangioma of cauda equina: A case report. Cases J 2009;2:80.
29. Nowak DA, Gumprecht H, Stolzle A, Lumenta CB. Intraneural growth of a capillary haemangioma of the cauda equina. Acta Neurochir (Wien) 2000;142:463-7.
30. Pignotti F, Coli A, Fernandez E, Montano N. Capillary hemangioma of the cauda equina. Surg Neurol Int 2015;6:133.
31. Roncaroli F, Scheithauer BW, Krauss WE. Capillary hemangioma of the spinal cord. Report of four cases. J Neurosurg 2000;93:148-51.
32. Sonawane DV, Jagtap SA, Mathesul AA. Intradural extramedullary capillary hemangioma of lower thoracic spinal cord. Indian J Orthop 2012;46:475-8.
33. Takata Y, Sakai T, Higashino K, Goda Y, Tezuka F, Sairyo K. Intradural extramedullary capillary hemangioma in the upper thoracic spine: A review of the literature. Case Rep Orthop 2014;2014:604131.
34. Tunthanathip T, Rattanalert S, Oearsakul T, Kanjanapradit K. Spinal capillary hemangiomas: Two cases reports and review of the literature. Asian J Neurosurg 2017;12:556-62.
35. Unnithan AK, Joseph TP, Gautam A, Shymole V. Case report of lumbar intradural capillary hemangioma. Surg Neurol Int 2016;7:S139-41.
36. Zander DR, Lander P, Just N, Albrecht S, Mohr G. Magnetic resonance imaging features of a nerve root capillary hemangioma of the spinal cord: Case report. Can Assoc Radiol J 1998;49:398-400.
37. Badri M, Gader G, Bahri K, Zammel I. Cervicothoracic syringomyelia caused by cervical spinal stenosis: Case report and literature review. Surg Neurol Int 2017;8:288.
38. Bhagavathula Venkata SS, Arimappamagan A, Lafazanos S, Pruthi N. Syringomyelia secondary to cervical spondylosis: Case report and review of literature. J Neurosci Rural Pract 2014;5:S78-82.
39. Kimura R, Park YS, Nakase H, Sakaki T. Syringomyelia caused

by cervical spondylosis. Acta Neurochir (Wien) 2004;146:175-8.

40. Rebai R, Boudawara MZ, Ben Yahia M, Mhiri C, Ben Mansour H. Syringomyelobulbia associated with cervical spondylosis. Pathophysiology and therapeutic implications. Neurochirurgie 2002;48:120-3.
41. Finsterer J, Bavinzski G, Ungersböck K. Spinal dural arteriovenous fistula associated with syringomyelia. J Neuroradiol 2000;27:211-4.
42. Chu BC, Terae S, Hida K, Furukawa M, Abe S, Miyasaka K. MR findings in spinal hemangioblastoma: Correlation with symptoms and with angiographic and surgical findings. AJNR Am J Neuroradiol 2001;22:206-17.
43. Rai RR, Shah S, Deogaonkar K, Dalvie S. Aggressive vertebral hemangioma causing spinal cord compression: Presenting a study of two cases and review of literature. J Orthop Case Rep 2018;8:33-7.