Case Report

Pituitary Apoplexy Following Severe Diabetic Ketoacidosis, with Two Uncommon Complications of Supraventricular Tachycardia and Acute Limb Ischemia, in a Patient with Neglected Pituitary Adenoma and Undiagnosed Diabetes Mellitus: A Rare Clinical Association

Sanjeev Pattankar, Phulrenu Chauhan[1], Farhad Kapadia[2], Milind Sankhe

Departments of Neurosurgery, [1]Endocrinology and [2]Intensive Care, P. D. Hinduja National Hospital and MRC, Mumbai, Maharashtra, India

Abstract

Pituitary apoplexy (PA) is a clinical emergency arising from acute ischemia or hemorrhage of the pituitary gland. A small subset of pituitary adenomas present with an apoplectic crisis, with common symptoms being headache, nausea-vomiting, visual impairment, ophthalmoplegia, altered sensorium, and panhypopituitarism. Though diabetic ketoacidosis (DKA) is an established complication of uncontrolled diabetes mellitus, its association with PA is extremely rare. Likewise, supraventricular tachycardia (SVT) and Acute limb ischemia (ALI) have rare, reported association with DKA. We present one such case of rare associations seen in our clinical practice. A 20-year-old woman was brought to our emergency room with headache, breathlessness, and altered sensorium. Clinical and biochemical evaluation revealed SVT, DKA, and right lower limb ALI. On enquiry, the patient was found to be diagnosed with pituitary adenoma 2 years ago and lost to follow-up. PA was detected on neuroimaging and confirmed histopathologically. Possibility of PA presenting as DKA and its sequelae exists.

Keywords: *Acute limb ischemia, diabetic ketoacidosis, pituitary apoplexy, supraventricular tachycardia, uncontrolled diabetes*

Introduction

Pituitary apoplexy (PA) is a rare life-threatening condition arising from acute ischemia or hemorrhage of the pituitary gland.[1,2] PA commonly occurs in the presence of pituitary adenomas, especially in nonfunctioning adenomas.[1] The incidence of PA in adenomas is underreported, as many cases may remain "clinically silent." Common presenting symptoms of PA include headache, nausea-vomiting, visual impairment, ophthalmoplegia, altered sensorium, and panhypopituitarism. Precipitating factors described for PA include hypertension, diabetes mellitus, pregnancy, radiation, etc.[2] Relative rarity and wide spectrum of nonspecific symptoms seen in PA, makes it a diagnostic challenge.

Diabetic ketoacidosis (DKA) is a common but serious complication of uncontrolled diabetes mellitus. Underlying pathophysiologic cause for DKA is severe insulin deficiency. Hence, DKA is more common in type-1 diabetes mellitus, either as an initial manifestation or resulting from subsequently increased insulin requirement.[3] The spectrum of clinical presentation seen in DKA is nonspecific and vary greatly depending on the severity of the condition. Common symptoms in DKA include polyuria, polydipsia, nausea-vomiting, lethargy, breathlessness, altered sensorium. Supraventricular tachycardia (SVT) and acute limb ischemia (ALI) are extremely rare complications seen in DKA.[4,5] There are only a couple of published case reports on association between DKA and PA. Herein, we report the case of a young woman, known case of pituitary adenoma, presenting as DKA – complicated with SVT and ALI, secondary to PA.

Case Report

A 20-year-old woman was rushed to

This is an open access journal, and articles are distributed under the terms of the Creative Commons Attribution-NonCommercial-ShareAlike 4.0 License, which allows others to remix, tweak, and build upon the work non-commercially, as long as appropriate credit is given and the new creations are licensed under the identical terms.

For reprints contact: WKHLRPMedknow_reprints@wolterskluwer.com

How to cite this article: Pattankar S, Chauhan P, Kapadia F, Sankhe M. Pituitary apoplexy following severe diabetic ketoacidosis, with two uncommon complications of supraventricular tachycardia and acute limb ischemia, in a patient with neglected pituitary adenoma and undiagnosed diabetes mellitus: A rare clinical association. Asian J Neurosurg 2021;16:890-4.

Submitted: 28-May-2021 **Revised:** 09-Jul-2021
Accepted: 09-Aug-2021 **Published:** 18-Dec-2021

Address for correspondence:
Dr. Sanjeev Pattankar, Department of Neurosurgery, P. D. Hinduja National Hospital and MRC, Mahim, Mumbai - 400 016, Maharashtra, India.
E-mail: sanjeev.pattankar@gmail.com

Access this article online

Website: www.asianjns.org

DOI: 10.4103/ajns.ajns_217_21

Quick Response Code:

© 2021 Asian Journal of Neurosurgery | Published by Wolters Kluwer - Medknow

the emergency room with complaints of progressively worsening headache, lethargy, breathlessness, and altered sensorium for 3 days. Due to the severity of symptoms, she was brought in a wheelchair. On arrival, she was found to be tachypnoeic, tachycardic (heart rate 180 beats/min), and drowsy. She had a Glasgow comma scale [GCS] of E3M6V4, with no gross focal deficits (quick assessment). Electrocardiogram revealed an underlying SVT as shown in Figure 1. Emergency cardiology opinion was taken, and she was immediately started on injection Adenosine for cardioversion, after unsuccessful carotid massage. She also sequentially required injection diltiazem and injection amiodarone to get cardioverted. Meanwhile, arterial blood gas analysis revealed severe metabolic acidosis with the following readings: pH 7.083, pCO_2 17.9 mmHg, pO_2 47 mmHg, and HCO_3 5.3 mmol/L. Random blood glucose was 746 mg/dl, and urine was strongly positive for ketone bodies. She was diagnosed to have DKA. Endocrinology team was consulted, and she was started on insulin infusion along with hydration. She received corrective measures for her metabolic derangements.

Within 1 h of being in the emergency room, the patient showed significant neurological deterioration. Repeat detailed neurological assessment revealed GCS of E2M5V1, with gross left-sided hemiparesis (Grade 2/5) and right ophthalmoplegia. In view of her rapidly worsening neurological status and fragile cardiopulmonary condition, she was intubated – ventilated. Simultaneously, she was found to have rapidly worsening renal function leading to acute renal shutdown. After correction of intracellular compartment fluid deficit, she was started on infusion of inotropes and diuretics. Emergency computed tomography (CT) brain (plain) revealed heterogeneous, mixed density, ill-defined lesion in right suprasellar-parasellar region measuring 4.6 cm × 3.8 cm in the largest dimension – suggestive of pituitary adenoma with apoplexy [Figure 2]. She was then transferred from the emergency room to intensive care unit (ICU) for further management.

On detailed inquiry regarding past medical history, parents revealed that the patient had menstrual irregularities and

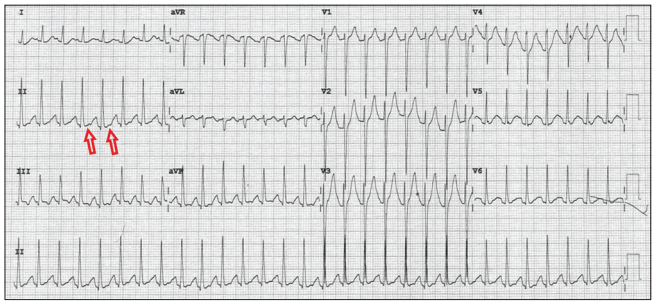

Figure 1: A 12-lead electrocardiogram taken at the time of arrival in the emergency room. Electrocardiogram shows a heart rate of 180 beats/min, regular RR intervals, narrow QRS complexes with few p-waves buried within, and pseudo s waves (red arrow mark). These findings are highly suggestive of atrioventricular node re-entrant tachycardia

episodes of severe headache about 2 years ago. She had consulted an outside physician and had undergone an magnetic resonance imaging (MRI) brain imaging as shown in Figure 3. No hormonal profiling or visual testing was done. The physician had put her on hormone-stabilizing medications (no records available) for few months. This relieved her symptoms to significant extent. She had no history of diabetes, though her parents say she had complaints of polyuria and polydipsia in the last 2–3 months which was not evaluated.

Considering the emergency CT brain findings and the past medical history, the patient's hormonal profiling was done. Her cortisol (8 pm) on arrival to the hospital was 31.8 μg/dl (range 5–25 μg/dl); prolactin was 193 ng/ml (range 0–20 ng/ml); human growth hormone was 30.5 ng/ml (range 0–7 ng/ml); insulin-like growth factor 1 was 231 ng/ml (range 117–323 ng/ml); and free T3 was 4.55 pg/ml (range 1.4–4.4 pg/ml), free T4 was 2.88 ng/dl (range 0.8–2 ng/dl), thyroid stimulating hormone was 0.84 μIU/ml (range 0.3–5 μIU/ml). She was started on injection hydrocortisone supplementation in view of apoplectic status. Owing to the poor general condition, emergency neurosurgical intervention was put on hold.

Within 2–4 h of admission to the ICU, the patient's right leg was found to be cyanosed and cold. Peripheral pulsations in the right leg were not felt from femoral level and below. Emergency Doppler study revealed thrombosis and complete obstruction of right lower limb vasculature, starting from common femoral artery and below, suggestive of ALI. Due to her then fragile status and extensive nature of the clot (no arterial flow restoration was possible as the veins were also blocked), she was not taken up for emergency vascular interventional procedure. Instead, she was started on anticoagulant therapy (low molecular weight heparin) and observed. On day 2 of admission, glycated hemoglobin done was 15.4%-suggestive of undiagnosed diabetic status.

The patient's overall condition started improving from day 4 of admission. DKA was corrected, and acute kidney injury resolved. Her GCS improved to E4M6Vet, with spontaneous movement of right upper limb. She had residual left hemiparesis (Grade 2/5) and right complete ophthalmoplegia. She got extubated on day 6 of admission. In view of the gangrenous changes that had developed in the right leg, right hip disarticulation was done on day 9 [Figure 4]. An MRI brain (Plain and contrast) was done at this point as patient's kidney function normalized, and further neurosurgical plan of action was to be decided [Figure 5]. In view of the large size and significant mass effect of the lesion, patient underwent right frontotemporal craniotomy and radical decompression of the sellar-suprasellar lesion under image guidance. She withstood the procedure well. Histopathological examination confirmed the lesion to be a nonfunctioning

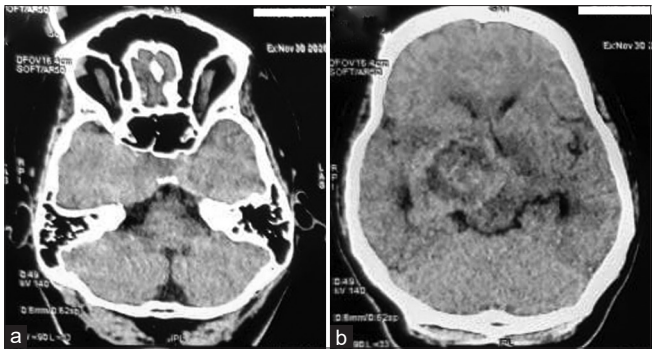

Figure 2: Emergency computed tomography brain (plain) images (a and b) showing heterogenous, mixed density, ill-defined lesion in right suprasellar-parasellar region

Figure 4: Portable X-ray pelvis and both hips-anteroposterior view showing postdisarticulation status of right hip

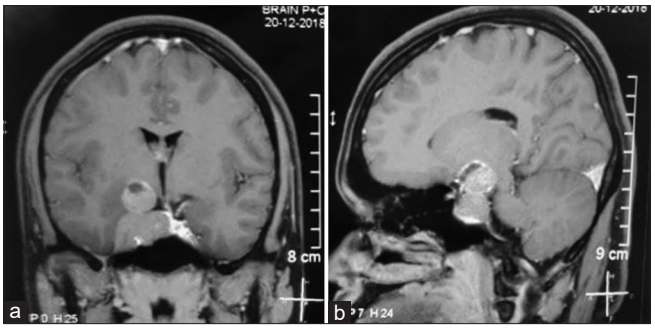

Figure 3: Contrast-enhanced magnetic resonance imaging brain done 2 years ago at an outside hospital. Coronal (a) and sagittal (b) sections show a lobulated, heterogeneously enhancing mass lesion, with areas of nonenhancing cystic/necrotic degeneration, located in sellar-parasellar-suprasellar region. Sellar enlargement and right cavernous sinus invasion seen

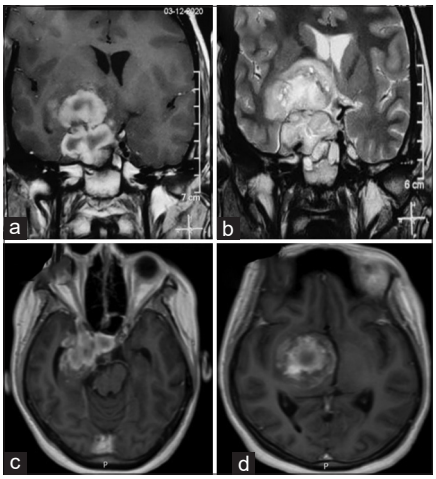

Figure 5: Contrast-enhanced magnetic resonance imaging brain done during the present hospitalization. Lobulated dumbbell shaped mass lesion is seen in sellar-parasellar-suprasellar region. Lesion appears mixed hypo- and hyper-intense on T1 weighted images (a), heterogeneously hyperintense on T2 weighted images (b) with tiny diffuse cystic spaces at the margin of central necrotic area, and heterogeneous contrast enhancement (c and d). Size of the lesion appears significantly increased compared to previous magnetic resonance imaging brain in Figure 3. Findings suggestive of apoplexy in the pituitary macroadenoma

pituitary adenoma with apoplexy. Figure 6 shows the microscopic images of the tumor. Despite the hardships of left hemiparesis and right hip disarticulation, patient is recovering well. She is in neurorehabilitation phase. On insulin therapy for newfound diabetic status. Anti-Glutamic acid decarboxylase and other antibody testing are planned for defining the type of diabetes in the subsequent outpatient follow-ups.

Discussion

PA has a wide range of presentations, and hence, remains a diagnostic challenge. Common reported pathophysiological mechanisms leading to PA in adenomas are: (1) reduced blood supply due to tumor overgrowth or compression of vascular structures or other systemic factors; (2) sudden surge in blood flow due to conditions like malignant hypertension; (3) pituitary gland stimulation in pregnancy or hormonal therapy such as bromocriptine; and (4) anticoagulant states.[2] Although diabetes induced microvasculopathy has been theoretically incriminated in the pathophysiology of PA, available clinical data does not support the same.[2] DKA, on the other hand, has been reported to precipitate apoplectic episodes.[2] There are only two case reports available of PA presenting as a DKA [Table 1]. Jiang *et al*.[6] reported an apoplectic GH-secreting adenoma with DKA, while Camara-Lemarroy *et al*.[4] reported a nonadenomatous PA with DKA.

SVT is a broad terminology used to describe arrhythmias above or involving atrioventricular node (AVN).[11] SVTs are a rare, reported complication of DKA. Factors precipitating SVTs in DKA could be either the severe acidosis or the accompanying electrolyte abnormalities such as hypomagnesemia or hypophosphatemia.[7-9] Our case had AVN re-entrant tachycardia precipitated possibly by severe acidosis, as the magnesium (2 mg/dl) and phosphorus (2.9 mg/dl) levels were normal. Vagal maneuvers and adenosine (AVN blocker) are the mainstay of treatment for SVTs in emergency conditions.[11] Additional usage of antiarrhythmic medications is required in refractory

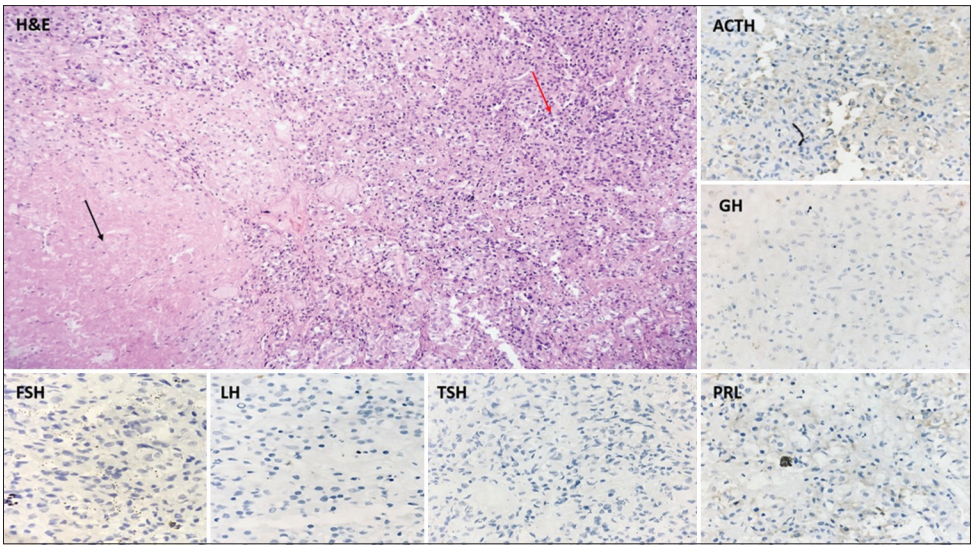

Figure 6: Photomicrographs of the surgical specimen. H and E staining showing monomorphic cell proliferation with round nuclei and chromophobe cytoplasm, indicating pituitary adenoma (red arrow), as well as intra-tumoral hemorrhage/necrosis (black arrow). Immunohistochemistry analysis done for various hormones show negative results, confirming nonfunctional status of the adenoma

Table 1: List of available case reports on the rare clinical association between pituitary apoplexy, diabetic ketoacidosis, and acute limb ischemia

Authors	Reported findings	Special features
Pituitary apoplexy and DKA		
Jiang *et al*., (2013)[6]	A 49-year-old man presenting with DKA was diagnosed with acromegaly and pituitary apoplexy. Due to refusal of treatment, patient had repeat episode of DKA with pituitary apoplexy after 2 months. Later died of B-cell lymphoma in 3 years	GH - secreting pituitary adenoma associated with DKA and apoplexy
Camara-Lemarroy *et al*., (2016)[4]	A 38-year-old woman presenting with altered mental status and DKA was found to have pituitary apoplexy. No evidence of adenoma seen	DKA associated with pituitary apoplexy without underlying pituitary adenoma
DKA and SVT		
Thomas *et al*., (2007)[7]	Two teenage girls (13- and 14-year-old) with diagnosed type-1 diabetes mellitus status presented with DKA and SVT	DKA and SVT in a diagnosed type-1 diabetes
Faruqi *et al*., (2015)[8]	A 12-year-old girl with known type-1 diabetes was admitted with severe DKA and SVT	DKA and SVT in a diagnosed type-1 diabetes
Finn *et al*., (2018)[9]	An 11-year boy with undiagnosed type-1 diabetes presented with DKA and SVT	DKA and SVT in an undiagnosed type-1 diabetes
DKA and ALI		
Zipser *et al*., (2005)[5]	A 52-year-old man presented with acute aortoiliac and femoral artery occlusion as a complication of DKA, caused by the resulting hypercoagulable state	Association between DKA and acute aortoiliac and femoral artery occlusion
Lin *et al*., (2006)[10]	A 33-year-old woman, who was a diagnosed case of diabetes, presented with DKA combined with acute brachial artery thrombosis	First association reported between DKA and acute brachial artery thrombosis

ALI – Acute limb ischemia; DKA – Diabetic ketoacidosis; GH – Growth hormone; SVT – Supraventricular tachycardia

cases. There are only three case reports available of DKA complicated by SVTs in young patients with type 1 diabetes [Table 1].

DKA has been reported to lead to a prothrombotic state, resulting rarely in devastating arterial or venous thrombotic episodes.[5,10] Many postulated underlying mechanisms include dehydration and resulting hyperosmolarity/hypercoagulation state, activation of endothelium, increased platelet aggregation, and impaired fibrinolysis. Various reported vascular thrombotic conditions involved iliac artery, femoral artery, brachial artery, or mesenteric artery. ALI resulting from such a thrombotic episode is seldom seen [Table 1].[5,10]

Our case report documents an amalgamation of the above-mentioned rare clinical associations. It highlights the worst clinical possibilities that can occur in a patient with neglected pituitary adenoma and an uncontrolled diabetes mellitus (diagnosed/undiagnosed). A watchful eye

for the unfolding clinical scenario and an appropriate early treatment can salvage even the rarest and gravest of the cases.

Declaration of patient consent

The authors certify that they have obtained all appropriate patient consent forms. In the form the patient(s) has/have given his/her/their consent for his/her/their images and other clinical information to be reported in the journal. The patients understand that their names and initials will not be published and due efforts will be made to conceal their identity, but anonymity cannot be guaranteed.

Financial support and sponsorship

Nil.

Conflicts of interest

There are no conflicts of interest.

References

1. Briet C, Salenave S, Bonneville JF, Laws ER, Chanson P. Pituitary apoplexy. Endocr Rev 2015;36:622-45.
2. Biousse V. Precipitating factors in pituitary apoplexy. J Neurol Neurosurg Psychiatry 2001;71:542-5.
3. Nyenwe EA, Kitabchi AE. The evolution of diabetic ketoacidosis: An update of its etiology, pathogenesis and management. Metabolism 2016;65:507-21.
4. Camara-Lemarroy CR, Infante-Valenzuela A, Rodriguez-Velver K, Rodriguez-Gutierrez R, Villareal-Velazquez HJ. Pituitary apoplexy presenting as diabetic ketoacidosis: A great simulator? Neuro Endocrinol Lett 2016;37:9-11.
5. Zipser S, Kirsch CM, Lien C, Singh TM, Kang YS. Acute aortoiliac and femoral artery thrombosis complicating diabetic ketoacidosis. J Vasc Interv Radiol 2005;16:1737-9.
6. Jiang HJ, Hung WW, Hsiao PJ. A case of acromegaly complicated with diabetic ketoacidosis, pituitary apoplexy, and lymphoma. Kaohsiung J Med Sci 2013;29:687-90.
7. Thomas N, Scanlon J, Ahmed M. Supraventricular tachycardia in association with diabetic ketoacidosis. Br J Diabetes Vasc Dis 2007;7:244-5.
8. Faruqi TA, Hanhan UA, Orlowski JP, Laun KS, Williams AL, Fiallos MR. Supraventricular tachycardia with underlying atrial flutter in a diabetic ketoacidosis patient. Clin Diabetes 2015;33:146-9.
9. Finn BP, Fraser B, O'Connell SM. Supraventricular tachycardia as a complication of severe diabetic ketoacidosis in an adolescent with new-onset type 1 diabetes. BMJ Case Rep 2018;2018:bcr-2017-222861.
10. Lin KD, Hsieh MC, Hsin SC, Hsaio ZY, Hung WW, Shin SJ. Acute brachial artery thrombosis: A rare complication of diabetic ketoacidosis. Kaohsiung J Med Sci 2006;22:44-8.
11. Sohinki D, Obel OA. Current trends in supraventricular tachycardia management. Ochsner J 2014;14:586-95.