Case Report

Understanding of Pathophysiology and Optimal Treatment for Anterior Circulation Large Vessel Occlusion beyond 24 h from Onset of Stroke

Abstract

We report three cases in which endovascular treatment (EVT) was performed for anterior circulation large vessel occlusion (LVO) beyond 24 h from the onset of stroke. Case 1 experienced left hemispatial neglect and gait disorder due to right internal cerebral artery (ICA) occlusion and underlying atherosclerosis. After percutaneous transluminal angioplasty (PTA), revascularization with mild stenosis was achieved. Case 2 complained of reduced activity, motor aphasia, and right-sided hemiparesis due to left middle cerebral artery occlusion. After thrombectomy using a retrieval stent, revascularization with M1 stenosis and distal perfusion delay was observed, which improved after PTA. Case 3 arrived at our hospital 30 h after the onset of dysarthria and gait disturbance due to left ICA occlusion. Since the symptoms were mild, medical treatment was started; however, the patient's symptoms deteriorated 6 h later, and EVT was required. After thrombectomy using a retrieval stent, revascularization was achieved. LVO pathophysiology beyond 24 h of stroke onset varies and may require multimodal treatment. Preserving the pyramidal tract may lead to favorable outcomes, even in cases of anterior circulation LVO. EVT may be effective for anterior circulation LVO because, in some patients, infarct volume continues to increase >24 h after stroke onset.

Keywords: *Acute ischemic stroke, anterior circulation large vessel occlusion, beyond 24 h from stroke onset, endovascular treatment*

Takashi Mizowaki, Atsushi Uyama[1], Atsushi Fujita[2], Jun Imura, Hiroyasu Shose, Hirotomo Tanaka, Yoshiyuki Takaishi, Takeshi Kondoh

Department of Neurosurgery, Shinsuma General Hospital, Suma-Ku, Kobe, [2]Department of Neurosurgery, Kobe University Graduate School of Medicine, Kusunoki-Cho, Kobe, Hyogo, [1]Department of Neurosurgery, Seisho Hospital, Odawara, Kanagawa, Japan

Introduction

The DAWN (Diffusion-weighted Imaging (DWI) or Computed Tomography Perfusion Assessment with Clinical Mismatch in the Triage of Wake Up and Late Presenting Strokes Undergoing Neurointervention with Trevo)[1] and DEFUSE 3 (Endovascular Therapy Following Imaging Evaluation for Ischemic Stroke[2] trials have demonstrated that endovascular treatment (EVT) is effective in select patients well beyond conventional time windows. However, the effect of EVT for large vessel occlusion (LVO) beyond 24 h from the onset of stroke is unclear.

Materials and Methods

Between May 2017 and July 2020, patients with acute ischemic stroke due to anterior circulation LVO were treated in our hospital. Our eligibility criteria for EVT were as follows: (1) LVO involving the internal cerebral artery (ICA), middle cerebral artery (MCA) segment 1 (M1), and MCA segment 2 (M2) on magnetic resonance angiography (MRA); (2) ischemic changes involving <1–3rd of the MCA territory on magnetic resonance imaging (MRI); and (3) significant mismatch between stroke severity and infarct volume. There was no time limit from stroke onset, or cutoff score using the Alberta Stroke Program Early Computed Tomography Score-Diffusion Weighted Imaging (ASPECTS DWI) and National Institutes of Health Stroke Scale (NIHSS) scores. Based on this, 40 cases of EVT for anterior circulation LVO were performed during the study period. Median age, median ASPECTS-DWI, and median NIHSS score were 83 years, 9, and 19.5, respectively. Three of the 40 cases (7.5%) received EVT after 24 h from stroke onset. Herein, we describe three cases with favorable outcomes.

Case Reports

Case 1

An 80-year-old male known to have dementia without atrial fibrillation (AF)

This is an open access journal, and articles are distributed under the terms of the Creative Commons Attribution-NonCommercial-ShareAlike 4.0 License, which allows others to remix, tweak, and build upon the work non-commercially, as long as appropriate credit is given and the new creations are licensed under the identical terms.

For reprints contact: WKHLRPMedknow_reprints@wolterskluwer.com

How to cite this article: Mizowaki T, Uyama A, Fujita A, Imura J, Shose H, Tanaka H, *et al.* Understanding of pathophysiology and optimal treatment for anterior circulation large vessel occlusion beyond 24 h from onset of stroke. Asian J Neurosurg 2021;16:881-5.

Submitted: 25-Dec-2020 **Revised:** 03-Feb-2021
Accepted: 10-Apr-2021 **Published:** 24-Sep-2021

Address for correspondence:
Dr. Takashi Mizowaki, Department of Neurosurgery, Shinsuma General Hospital, 3-1-14 Kinugake-Cho, Suma-Ku, Kobe 654-0048, Hyogo, Japan. E-mail: mizowakit@yahoo.co.jp

Access this article online

Website: www.asianjns.org

DOI: 10.4103/ajns.AJNS_554_20

Quick Response Code:

arrived at our hospital with a 10-day history of left hemispatial neglect and 3-day history of gait disturbance. He was not taking antithrombotic drugs. His initial examination findings confirmed a left hemiparesis, dysarthria, and left hemispatial neglect, and his initial NIHSS score was 7. MRI-DWI and MRA showed acute ischemic changes in the right parieto-occipital lobe [Figure 1a] with occlusion of the right ICA [Figure 1b]. The pyramidal tract was not severely affected on the initial MRI scan. Urgent EVT with systemic heparinization was performed. Angiography confirmed collateral circulation through the anterior cerebral artery [Figure 1c] and ophthalmic artery [Figure 1d and e]. The occlusion site of the ICA was the petrous portion [Figure 1d and e]. Angiography of the posterior circulation was not performed. Given that the pathophysiology was considered to be LVO with underlying atherosclerosis, a loading dose of aspirin (200 mg) was administered. After four cycles of percutaneous transluminal angioplasty (PTA) [PTA; Figure 1f] using a 2.5-mm balloon (Gateway OTW [Stryker Neurovascular]), revascularization with mild stenosis [Figure 1g and h] was obtained. The next day, NIHSS score reduced to 2, and MRI-DWI and MRA showed no ischemic changes [Figure 1i] and successful revascularization with residual stenosis [Figure 1j]. Antiplatelet drugs were continued after the EVT procedure. Two days later, stenting was performed under local anesthesia for the residual stenosis. Three months later, the patient recovered, with a modified Rankin Scale (mRS) score of 1. No ischemic events or stenotic change in relation to the right ICA lesion occurred during the 1-year follow-up.

Case 2

A 97-year-old wheelchair-bound woman (mRS score 4) with chronic heart failure, dementia, and arteriosclerosis obliterans without AF visited our hospital after a 2-day history of reduced activity and 1 day of motor aphasia and right-sided hemiparesis. She was not taking antithrombotic drugs. Her initial assessment confirmed the presence of a right-sided hemiparesis, motor aphasia, and right hemispatial neglect, and her initial NIHSS score was 18. MRI-DWI and MRA demonstrated acute ischemic changes in the left corona radiata, frontal lobe, and parietal lobe [Figure 2a] with the occlusion of the left MCA [Figure 2b]. The pyramidal tract was not severely affected on the initial MRI. Urgent EVT with systemic heparinization was performed. Given that the pathophysiology of her stroke was considered LVO with underlying atherosclerosis, aspirin (200 mg) and clopidogrel (300 mg) were administered through a nasogastric tube. Anterior angiography confirmed occlusion of the left proximal MCA [Figure 2c] and reduced blood supply to the basal ganglia from the anterior choroidal artery [Figure 2d]. After one thrombectomy using a

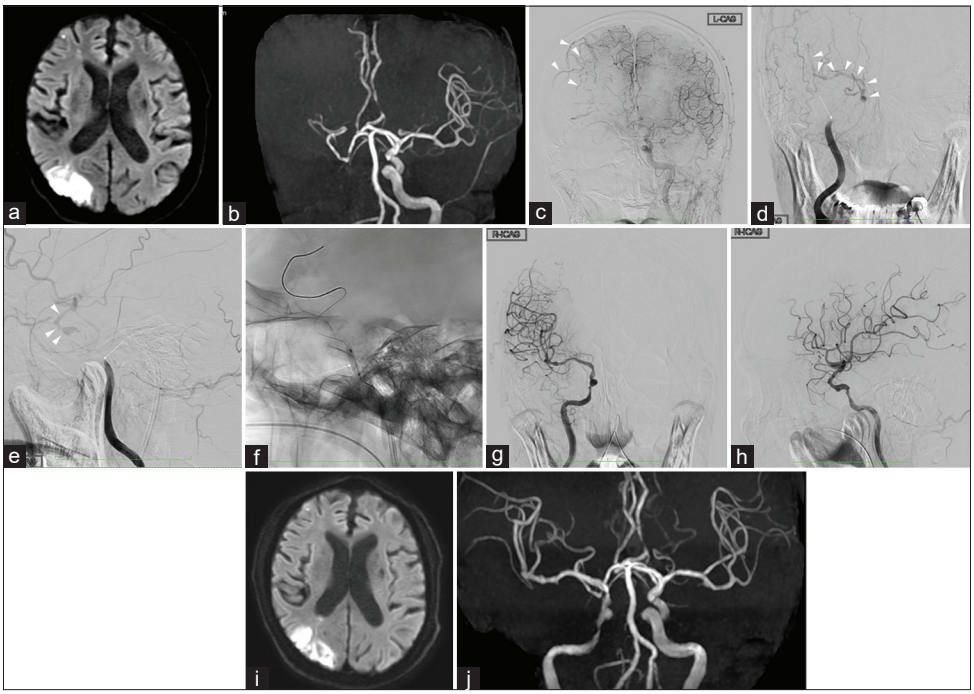

Figure 1: Case 1: (a) Initial magnetic resonance imaging (MRI)-diffusion-weighted images (DWI) show acute ischemic changes in the right parieto-occipital lobe. b) Initial magnetic resonance angiography (MRA) shows right internal cerebral artery (ICA) occlusion. (c) Left internal cerebral angiography shows leptomeningeal collateral flow through the anterior cerebral artery (white arrowheads). (d and e) Right internal cerebral angiography shows occlusion of the petrous portion of the ICA (white arrow) and collateral flow through the ophthalmic artery (white arrow heads). (f) Radiography image shows the percutaneous transluminal angioplasty balloon (white arrow). (g and h) Right internal cerebral angiography shows revascularization of the right ICA with mild stenosis. (i) Posttreatment MRI-DWI show no ischemic change. (j) Posttreatment MRA shows revascularization of the right ICA.

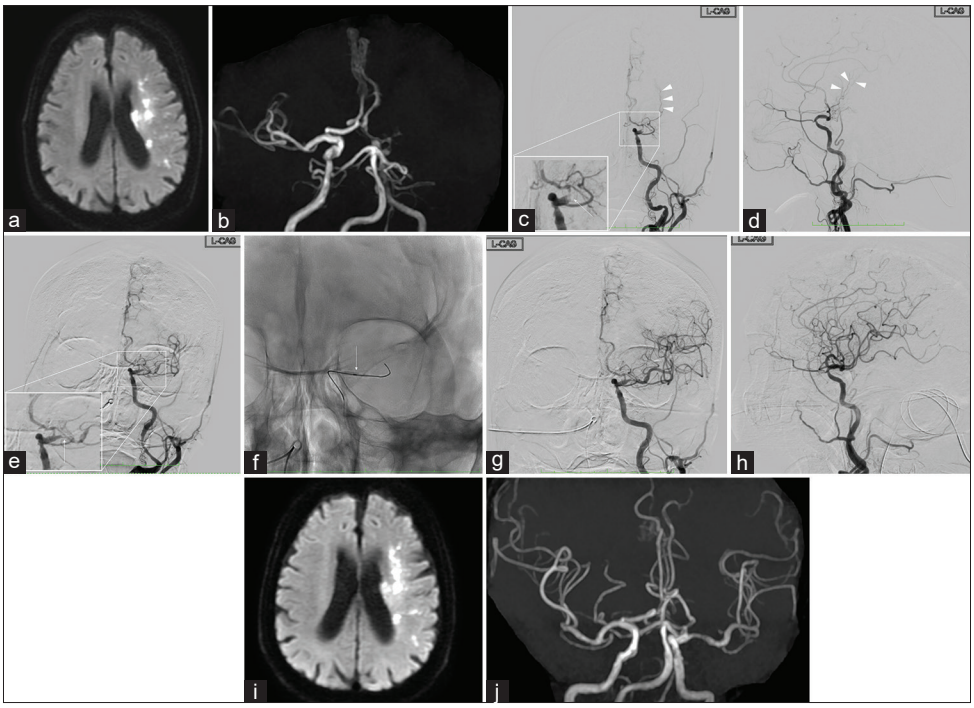

Figre 2: Case 2: (a) Initial magnetic resonance imaging (MRI)-diffusion-weighted images (DWI) show acute ischemic changes in the left corona radiata, frontal lobe, and parietal lobe. (b) Initial magnetic resonance angiography (MRA) shows left middle cerebral artery (MCA) occlusion. (c and d) Left internal cerebral angiography shows the proximal MCA occlusion (white arrow) and blood supply to the basal ganglia through the anterior choroidal artery (white arrow heads). (e) Left internal cerebral angiography shows revascularization of the left MCA with stenosis (white arrow) of the M1 portion and distal perfusion delay. (f) Radiography image shows the percutaneous transluminal angioplasty balloon (white arrow). (g and h) Left internalcerebral angiography shows revascularization of the left MCA with mild stenosis. (i) Posttreatment MRI-DWI show mild ischemic changes. (j) Posttreatment MRA shows revascularization of the left MCA.

4.0-mm retrieval stent (Solitaire 4.0 mm × 40 mm clot retrieval stent [Medtronic, Minneapolis, MN, USA]), revascularization with stenosis of the M1 portion and distal perfusion delay was confirmed [Figure 2e], and a small amount of red clot was retrieved. Subsequently, after three cycles of PTA [Figure 2f] using a 1.5-mm balloon (Gateway OTW [Stryker Neurovascular]), the stenosed artery was revascularized, and distal perfusion improved [Figure 2g and h]. One week after EVT, her NIHSS score reduced to 4, and MRI-DWI and MRA confirmed the presence of minor ischemic changes [Figure 2i] and successful revascularization with mild residual stenosis [Figure 2j]. Antiplatelet drugs were continued after the EVT procedure. Three months later, the patient recovered to prestroke mRS score of 4. No ischemic events or stenotic changes occurred during the 4-month follow-up.

Case 3

A 66-year-old woman with a history of hypertension without AF visited our hospital 30 h after the onset of dysarthria and gait disturbance. She was not taking antithrombotic drugs. The initial assessment confirmed the presence of right-sided hemiparesis and motor aphasia, and her initial NIHSS score was 3. MRI-DWI and MRA showed acute ischemic changes in the left frontal lobe and basal ganglia [Figure 3a] with occlusion of the left ICA [Figure 3b]. The pyramidal tract was not severely affected on the initial MRI. Urgent angiography confirmed occlusion of the left ICA [Figure 3c and d] and blood supply to the left MCA through the anterior communicating artery [Figure 3e]. Since the symptoms were mild, she did not proceed to EVT and was administered 2.5 mg/h argatroban hydrate and 100 mg aspirin daily. However, 6 h later, her hemiparesis and aphasia deteriorated (NIHSS score increased to 8); thus, EVT with systemic heparinization was performed. Initially, ADAPT[3] was planned to avoid crossing lesion of unknown pathology, but thrombectomy using a retrieval stent was ultimately performed because the clot was not aspirated. After one thrombectomy using a 6.0-mm retrieval stent (Solitaire 6.0 mm × 40 mm clot retrieval stent [Medtronic, Minneapolis, MN, USA)]) [Figure 3f], revascularization with a small amount of red clot [Figure 3g and h] was achieved. One day later, NIHSS score reduced to 4, and MRI-DWI and MRA showed no ischemic changes [Figure 3i] as well as successful revascularization [Figure 3j]. Transthoracic echocardiography post-EVT showed no intracardiac thrombus. Transesophageal echocardiography was not available at our hospital. Anticoagulant drugs were initiated, and the cause of the stroke was diagnosed as cryptogenic embolism. Three months later, the patient recovered with an mRS score of 1. No ischemic events or stenotic changes occurred during the 4-month follow-up.

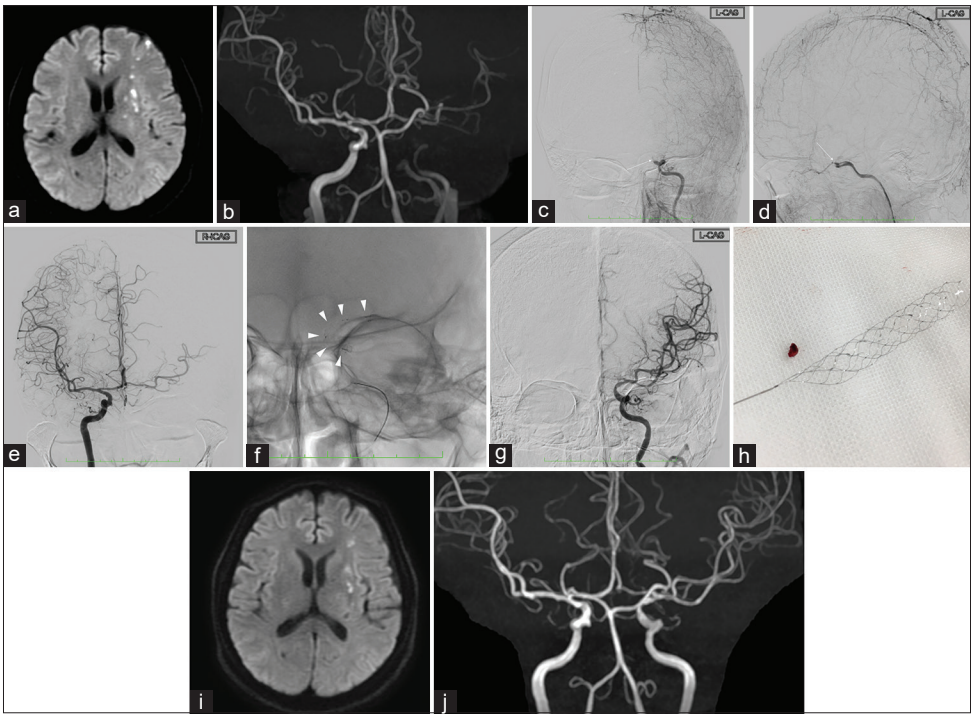

Figure 3: Case 3: (a) Initial magnetic resonance imaging (MRI)-diffusion-weighted images (DWI) show acute ischemic changes in the left corona radiata and frontal lobe. (b) Initial magnetic resonance angiography (MRA) shows the left internal cerebral artery (ICA) occlusion and cross-flow to the left middle cerebral artery (MCA) through the anterior communicating artery. (c and d) Left internal cerebral angiography showing the ICA occlusion (white arrow). (e) Right internal cerebral angiography shows the collateral flow for the left MCA through the anterior communicating artery. (f) Radiography image showing the retrieval stent (white arrowheads). (g and h) Left internal cerebral angiography shows revascularization of the left ICA with a small amount of red clot. (i) Posttreatment MRI-DWI show no ischemic changes. (j) Posttreatment MRA shows revascularization of the left ICA.

Discussion

In the DEFUSE 3 trial,[2] about 20% of patients with MCA or ICA occlusion who presented in an extended time window and were not treated with EVT had a persistent mismatch for at least an additional 24 h.[4] Desai *et al*.[5] reported results of EVT beyond 24 h from stroke onset in 21 patients with ICA or MCA (M1) occlusions, finding a revascularization rate of 81% and a favorable outcome in 43%. However, it is not clear exactly what hemodynamics had a persistent mismatch.

In case 1, the patient had an LVO with underlying atherosclerosis. This condition generally results in lower NIHSS score and smaller infarct volume due to good collateral flow,[6] which we observed. The good collateral flow of the leptomeningeal and ophthalmic arteries was identified on angiography. Since LVO with underlying atherosclerosis was suspected, PTA was performed instead of thrombectomy. The proximal end of the ICA occlusion was 4.0 mm in diameter and a 2.5 mm balloon was chosen as the most suitable size for PTA. A method of using a retrieval stent as the first approach to LVO with underlying atherosclerosis may led to injury of the intima, resulting in re-occlusion and hemorrhagic complications.[7] The use of a retrieval stent as the first approach to LVO with underlying atherosclerosis has been discussed previously.[8-10]

In case 2, the patient received PTA for residual stenosis after thrombectomy. Since the crab crow sign[11] was found at the occlusion site, thrombectomy was initially performed. Although it was unclear whether there was atherosclerosis or a dissection underlying the residual stenosis, PTA was performed secondarily. Although leptomeningeal collateral flow from the posterior circulation could not be evaluated in this case, it is possible that there was a collateral blood supply from the posterior circulation to explain the reduced cortical damage. With regard to postoperative medication, an antiplatelet drug was used to prevent residual stenosis.

Case 3 was a patient with mild neurological symptoms and good cross flow through the anterior communicating artery. Six hours after starting medication, EVT was needed because her symptoms worsened. One-third of patients with mild LVO have neurological symptoms worsening within 24 h without EVT.[12] Since red clots were retrieved by thrombectomy, and no residual stenosis was observed, she received an anticoagulant drug postoperatively.

Kim *et al*.[13] suggested that patients with underlying atherosclerosis had better collateral flow than those with other stroke subtypes, presumably because a longer time is required for complete arterial occlusion, allowing the development of adequate collateral flow before acute stroke onset. Abundant collateral flow is significantly associated with better clinical outcomes. In other words, LVO with

underlying atherosclerosis may be a prognostic predictor of EVT beyond 24 h from the onset of stroke. All 21 cases of EVT for anterior circulation LVO beyond 24 h from the onset of stroke reported by Desai *et al*.[5] had no underlying atherosclerosis. In patients with thromboembolic stroke where the collateral circulation is developed, as was observed in Case 3, favorable outcomes can be expected even when performing EVT beyond 24 h from stroke onset.

In all 3 cases, the damage to the pyramidal tract was relatively minor. Even if the infarct volume is relatively small, or if the pyramidal tract—including the corona radiata—is profoundly affected, a favorable outcome cannot be expected. Salvage of the pyramidal tract through reperfusion was associated with improved outcome, independent of overall salvage of ischemic tissue in anterior circulation stroke.[14] Furthermore, the infarct area was not large in all cases. Intracerebral hemorrhage (ICH) after EVT for ischemic stroke is a well-known complication, with increase in morbidity and mortality. Large infarct volume has been shown to be associated with increased risk of ICH.[15] The symptoms of all three patients in our study continued to worsen from the time of stroke onset. In the DEFUSE 3 trial,[2] the incidence of persistent mismatch in patients who presented 24–40 h after onset with an anterior circulation LVO was as high as 10%.[4] There are reports that the infarct volume continues to expand for several days in cases where revascularization is not achieved.[15,16]

Conclusions

The pathophysiology of LVO beyond 24 h from the onset of stroke varies and may require multimodal treatment. Preserving the pyramidal tract may lead to favorable outcomes, even in cases of anterior circulation LVO beyond 24 h from stroke onset. EVT may be effective because there are cases in which infarct volume continues to increase more than 24 h from anterior circulation LVO onset.

Authors' note

Informed consent has been obtained from the patients for this study and publication of this case report with accompanying images.

Declaration of patient consent

The authors certify that they have obtained all appropriate patient consent forms. In the form, the patients have given their consent for their images and other clinical information to be reported in the journal. The patients understand that name and initials will not be published and due efforts will be made to conceal their identity, but anonymity cannot be guaranteed.

Financial support and sponsorship

Nil.

Conflicts of interest

There are no conflicts of interest.

References

1. Nogueira RG, Jadhav AP, Haussen DC, Bonafe A, Budzik RF, Bhuva P, *et al*. Thrombectomy 6 to 24 hours after stroke with a mismatch between deficit and infarct. N Engl J Med 2018;378:11-21.
2. Albers GW, Marks MP, Kemp S, Christensen S, Tsai JP, Ortega-Gutierrez S, *et al*. Thrombectomy for stroke at 6 to 16 hours with selection by perfusion imaging. N Engl J Med 2018;378:708-18.
3. Turk AS, Frei D, Fiorella D, Mocco J, Baxter B, Siddiqui A, *et al*. ADAPT FAST study: A direct aspiration first pass technique for acute stroke thrombectomy. J Neurointerv Surg 2014;6:260-4.
4. Christensen S, Mlynash M, Kemp S, Yennu A, Heit JJ, Marks MP, *et al*. Persistent target mismatch profile>24 hours after stroke onset in DEFUSE 3. Stroke 2019;50:754-7.
5. Desai SM, Haussen DC, Aghaebrahim A, Al-Bayati AR, Santos R, Nogueira RG, *et al*. Thrombectomy 24 hours after stroke: Beyond DAWN. J Neurointerv Surg 2018;10:1039-42.
6. Kim SJ, Ryoo S, Kim GM, Chung CS, Lee KH, Bang OY. Clinical and radiological outcomes after intracranial atherosclerotic stroke: A comprehensive approach comparing stroke subtypes. Cerebrovasc Dis 2011;31:427-34.
7. Kang DH, Yoon W, Kim SK, Baek BH, Lee YY, Kim YW, *et al*. Endovascular treatment for emergent large vessel occlusion due to severe intracranial atherosclerotic stenosis. J Neurosurg 2018;1:1-8.
8. Luo Y, Huang J, Yang Y, Liu H, Chen X, Li X, *et al*. Effect of direct angioplasty therapy on acute middle cerebral artery occlusion with good leptomeningeal collateral. Clin Neurol Neurosurg 2020;190:105744.
9. Kang DH, Yoon W. Current opinion on endovascular therapy for emergent large vessel occlusion due to underlying intracranial atherosclerotic stenosis. Korean J Radiol 2019;20:739-48.
10. Zhang G, Ling Y, Zhu S, Wu P, Wang C, Qi J, *et al*. Direct angioplasty for acute ischemic stroke due to intracranial atherosclerotic stenosis-related large vessel occlusion. Interv Neuroradiol 2020;26:602-7.
11. Ohshima T, Niwa A, Kawaguchi R, Matsuo N, Miyachi S. Novel technique for detection of actual position of clot during endovascular clot retrieval: Assessment of microcatheter withdrawing angiography. World Neurosurg 2020;137:229-34.
12. Lee VH, Thakur G, Nimjee SM, Youssef PP, Lakhani S, Heaton S, *et al*. Early neurologic decline in acute ischemic stroke patients receiving thrombolysis with large vessel occlusion and mild deficits. J Neurointerv Surg 2020;12:1085-7.
13. Kim SJ, Seok JM, Bang OY, Kim GM, Kim KH, Jeon P, *et al*. MR mismatch profiles in patients with intracranial atherosclerotic stroke: A comprehensive approach comparing stroke subtypes. J Cereb Blood Flow Metab 2009;29:1138-45.
14. Zhou Y, Zhang R, Zhang S, Yan S, Wang Z, Campbell BC, *et al*. Impact of perfusion lesion in corticospinal tract on response to reperfusion. Eur Radiol 2017;27:5280-9.
15. Soize S, Barbe C, Kadziolka K, Estrade L, Serre I, Pierot L. Predictive factors of outcome and hemorrhage after acute ischemic stroke treated by mechanical thrombectomy with a stent-retriever. Neuroradiology 2013;55:977-87.
16. Federau C, Mlynash M, Christensen S, Zaharchuk G, Cha B, Lansberg MG, *et al*. Evolution of volume and signal intensity on fluid-attenuated inversion recovery mr images after endovascular stroke therapy. Radiology 2016;280:184-92.