Case Report

Multiple Cranial Nerve Involvement as a Presentation of Primary Central Nervous System Lymphoma: A Case-Based Review

Tanvi Modi, Mitusha Verma, Deepak Patkar

Department of Radiology, Dr. Balabhai Nanavati Hospital, Mumbai, Maharashtra, India

Abstract

Central nervous system (CNS) lymphoma is of two types: primary and secondary (more common). Primary CNS lymphoma usually presents as parenchymal lesions having characteristic imaging findings and may be associated with leptomeningeal involvement. Involvement of multiple cranial nerves as the initial manifestation of primary CNS lymphoma with the development of typical parenchymal lesions on follow-up is a rare entity. This nerve involvement is termed as neurolymphomatosis. We present the magnetic resonance imaging features of five patients presenting with neurolymphomatosis due to non-Hodgkin's lymphoma.

Keywords: *Cranial nerves, lymphoma, nerve enhancement, neurolymphomatosis*

Introduction

Primary central nervous system (CNS) lymphoma originates in the brain, spinal cord, meninges, or eyes and rarely spreads outside the CNS. It is usually of non-Hodgkin type and accounts for 2%–6% of primary intracranial neoplasms.[1] The common areas of involvement are supratentorial periventricular deep white matter, basal ganglia, corpus callosum, or meningeal surfaces,[1] with a solitary lesion being typical. A rare presentation is diffuse involvement of brain parenchyma, termed lymphomatosis cerebri.[1]

Neurolymphomatosis is a condition characterized by nerve infiltration by neoplastic cells, commonly seen with hematological malignancies such as leukemia or Non-Hodgkin's lymphoma. Typically, there is involvement of cranial nerves, peripheral nerves, nerve roots, and plexuses.[2] Multiple primary CNS malignancies such as glioblastoma and secondary CNS deposits such as breast cancer and melanoma spread through subarachnoid spaces and extend along cranial nerves, commonly involving VII and VIII nerves.[3] Other common causes of thickening and enhancement of cranial nerves include infections such as leptomeningeal tuberculosis, inflammatory conditions such as sarcoidosis and idiopathic hypertrophic cranial pachymeningitis, demyelination, and primary nerve tumors such as schwannomas.[4] Out of these, nodular thickening is common in neurolymphomatosis, neoplasms, and granulomatosis.[4]

In this article, we would like to highlight the involvement of cranial and spinal nerves as the initial presentation of primary CNS lymphoma, its imaging features at presentation and over the course of the disease, and finally the importance of considering neurolymphomatosis as a key differential of enhancing nerve thickening.

Case Reports

Case 1

An 80-year-old male patient presented with complaints of left sided hearing loss. Magnetic resonance imaging (MRI) of the brain with focus on internal auditory meatus revealed enhancing thickening along left VII–VIII nerve complex in the canalicular region [Figure 1a]. Few tiny focal-enhancing lesions were seen in bilateral cerebellar hemispheres which appeared hyperintense on T2 with hypointense areas within and on perfusion imaging appear hypoperfused [Figure 1b].

Address for correspondence:
Dr. Tanvi Modi, Department of Radiology, Dr. Balabhai Nanavati Hospital, Vile Parle (W), Mumbai - 400 056, Maharashtra, India.
E-mail: tanvimodi134@gmail.com

Access this article online

Website: www.asianjns.org

DOI: 10.4103/ajns.AJNS_110_21

Quick Response Code:

This is an open access journal, and articles are distributed under the terms of the Creative Commons Attribution-NonCommercial-ShareAlike 4.0 License, which allows others to remix, tweak, and build upon the work non-commercially, as long as appropriate credit is given and the new creations are licensed under the identical terms.

For reprints contact: WKHLRPMedknow_reprints@wolterskluwer.com

How to cite this article: Modi T, Verma M, Patkar D. Multiple cranial nerve involvement as a presentation of primary central nervous system lymphoma: A case-based review. Asian J Neurosurg 2021;16:835-40.

Submitted: 15-Mar-2021 **Revised:** 30-Apr-2021
Accepted: 22-May-2021 **Published:** 18-Dec-2021

Magnetic resonance (MR) spectroscopy revealed elevated Cho levels with reduced N-acetylasparate (NAA) levels. This patient was operated for the meatal lesions which on histopathology revealed cluster of lymphocytes along nerve bundles and vessels as well as ganglion cells. A repeat MR after 3 months for progressively increasing imbalance revealed increase in size of cerebellar lesions with new lesion in left temporal region [Figure 2a and b], all of which showed restricted diffusion, moderate enhancement, hyperperfusion, Cho peak, and mild-to-moderate perilesional edema. The patient was initiated on systemic chemotherapy. MRI done a year later revealed new bithalamic lesions [Figure 2c] appearing T1 hyperintense and T2 isointense to gray matter with mass effect on 3rd ventricle, and new lesions in right hippocampus and parahippocampal region, all of them showing similar imaging findings to the previous lesions. There was resolution of cerebellar, left temporal lesions, likely due to response to chemotherapy. Fluorodeoxyglucose (FDG)-positron emission tomography (PET) showed increased uptake in bilateral thalami with an SUV MAX of 15 in left thalamus. Biopsy of the left thalamic lesion revealed non-Hodgkin's lymphoma.

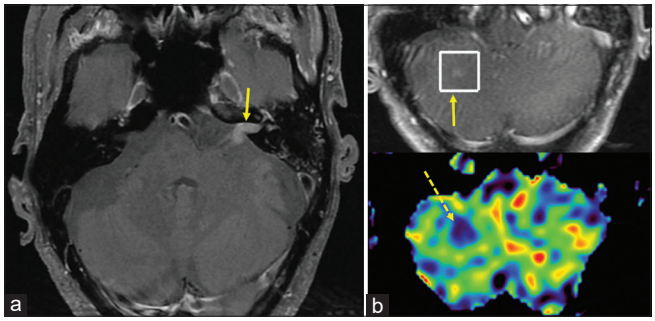

Figure 1: (a) Axial postcontrast magnetic resonance image revealing enhancing thickening along left 7–8 nerve complex, in the cisternal and canalicular segments (arrow). (b) Tiny right cerebellar enhancing lesion (arrow) appearing hypoperfused on arterial spin labeling (dotted arrow)

Case 2

A 48-year-old male patient presented with deviation of angle of mouth on both sides, more so on the left. On MRI, enhancement was seen along bilateral VII–VIII nerve complexes, root entry zones of bilateral trigeminal nerves as well as IX-XI nerves [Figure 3a]. Nonenhancing areas of T2 hyperintensity were seen in bilateral cerebral hemispheres and splenium of corpus callosum [Figure 3b]. Spectroscopy revealed elevated Cho and prominent lipid-lactate peak, and on MR perfusion, these areas appeared hypoperfused. Using cerebrospinal fluid (CSF) flowmetry, the patient was

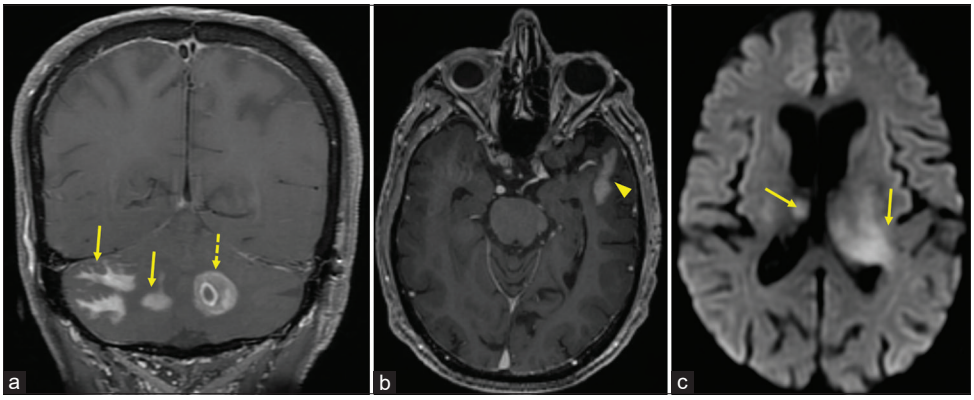

Figure 2: (a) Increase in size of bilateral cerebellar lesions (arrows) with peripheral ring enhancement on the left (dotted arrow) seen on 3-month follow-up magnetic resonance imaging. (b) New enhancing lesion in left anterior temporal region (arrowhead). (c) Repeat magnetic resonance imaging after 1 year reveals the development of new lesions in both thalami (arrows) showing diffusion restriction

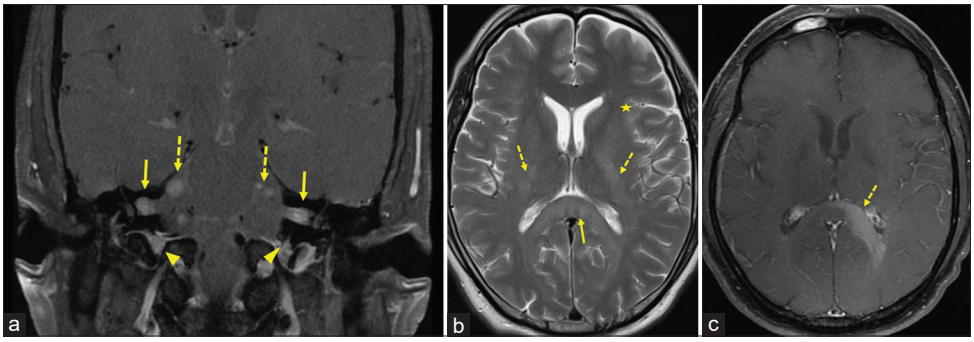

Figure 3: (a) Coronal postcontrast image revealing enhancing thickening of both trigeminal nerve (dotted arrows), both 7–8th nerve complex (arrow), and both 9–11 nerve complexes (arrowheads). (b) Nonenhancing T2 hyperintense areas in splenium of corpus callosum (arrow), posterior limbs of both internal capsules (dotted arrows) and left insula (asterisk). (c) 5-month follow-up showing recurrent lesion in left half of splenium of corpus callosum showing postcontrast enhancement (dotted arrow)

diagnosed to have CNS lymphoma and initiated on systemic chemotherapy. A repeat MR after 3 months revealed good response to treatment, with near complete resolution of findings. 5 months later, the patient developed a new lesion in left half of splenium of corpus callosum [Figure 3c] and few tiny lesions in left cerebral hemisphere, showing similar features as the previous lesions with an additional finding of diffusion restriction. No abnormal nerve root enhancement was seen. These findings represented disease recurrence. The patient was continued on chemotherapy and a repeat MRI 2 months later revealed increase in size of the lesions with reduction in enhancement, representing a combination of residual disease and treatment-induced response.

Case 3

A 38-year-old male presented with headache, diplopia, and deviated angle of mouth. MRI revealed thick, nodular enhancement along bilateral cerebral convexities and middle cerebellar peduncles. Thick nodular enhancement was also seen along cisternal segments of bilateral VII–VIII nerves, prechiasmatic segments of bilateral optic nerves, and optic chiasm [Figure 4]. Similar changes were seen in left trigeminal nerve at root entry zone, within Meckel's cave and cavernous sinus segment. The differential diagnoses considered were neurosarcoidosis and CNS lymphoma. Patient, however, did not take any treatment and a repeat MRI done a year later revealed multiple enhancing T2 hypointense lesions showing restricted diffusion in right frontotemporal region, bilateral cerebellar hemispheres, and left half of medulla with perilesional edema. Similar enhancing lesion was also seen in cervical spinal cord. Lymphoma was suspected, and the patient was started on methotrexate-based systemic chemotherapy. A repeat MRI after 2 months revealed 2 new lesions in bilateral cerebellar hemispheres. These lesions appeared hypoperfused and revealed twin elevated peaks of Cho and lipid, with reduced NAA. No spinal cord lesions were seen on this study. Biopsy correlation was suggested, and the patient was continued on chemotherapy.

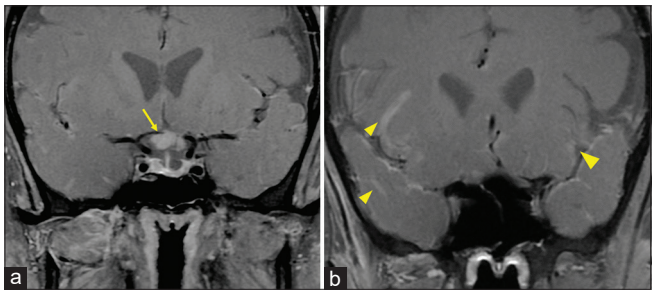

Figure 4: (a) Bulky, nodular enhancing prechiasmatic segments of optic nerves and optic chiasm (arrow). (b) Thick, nodular leptomeningeal enhancement over bilateral frontotemporal convexities (arrowheads)

Case 4

A 25-year-old male presented with complaints of inability to walk, fever, and diplopia for 2 days. He had bilateral facial palsy 2 months back followed by bilateral lower limb weakness. MRI of the brain and whole spine showed the enhancement of cisternal segments of bilateral trigeminal and facial nerves [Figure 5a]. Accentuated enhancement of cauda equina nerve roots was also seen. Enhancing T2 hypointense soft-tissue lesions were noted in anterior and posterior epidural space of dorsolumbar region [Figure 5b and c]. Similar lesions were seen in few cervical and dorsal vertebral bodies. Hepatosplenomegaly was also seen, along with enhancing lesions in left iliopsoas and gluteal muscles. Thus, MRI was suggestive of lymphoproliferative etiology. On PET-computed tomography (CT), uptake was seen in mediastinal lymph nodes and along nerves, suggestive of lymphoma. Bone marrow biopsy showed 30% blast cells suggestive of acute leukemia with lymphoid origin cells. CSF routine showed abnormal lymphocytes with irregular nuclear morphology. On histopathology, Non-Hodgkin's lymphoma of T-cell phenotype, lymphoblastic type was diagnosed, and the patient was initiated on chemotherapy. However, the patient went into septic shock and did not survive.

Case 5

A 40-year-old female presented with diplopia and ptosis for 7 days. MRI of the brain revealed T2, FLAIR hyperintense areas with restricted diffusion in right frontal

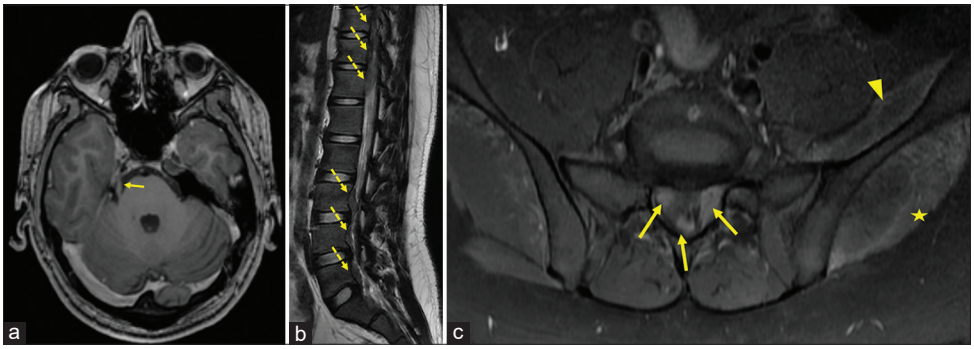

Figure 5: (a) Enhancing thickening of cisternal segment of right trigeminal nerve. (b) T2 hypointense soft-tissue lesions involving anterior epidural space of D10–D12 and L3–L5 (dotted arrows). (c) Thickened, enhancing sacral nerve roots (arrows). Note the enhancing left gluteal (asterisk) and left iliopsoas (arrowhead) muscle lesions

periventricular white matter and adjoining body of corpus callosum [Figure 6a], bilateral thalami, basal ganglia, caudate nuclei, left medial temporal lobe, and midbrain with patchy areas of enhancement within. Infundibulum and both oculomotor nerves [Figure 6b] appeared bulky with intense enhancement. MR spectroscopy in right gangliocapsular lesion revealed elevated Cho and lipid lactate levels, consistent with increased cell membrane turnover and anaerobic metabolism, respectively [Figure 6c]. Suspicion of neoplastic process was given based on MRI and biopsy of the right frontal lesion confirmed the diagnosis of CNS lymphoma. The patient was started on chemotherapy, and a follow-up MRI after 4 months revealed minimal residual disease in the right frontal periventricular white matter and adjoining body of corpus callosum with resolution of the rest of the findings, consistent with treatment response. The patient was on chemotherapy for 6 months. Follow-up MRIs over the course of 4 years revealed nonenhancing hyperintense areas in bilateral corona radiata without hyperperfusion or altered metabolites and were labeled as treatment-induced changes.

Discussion

Neurolymphomatosis accounts for 3% of newly diagnosed non-Hodgkin's lymphoma cases.[5]

We reported five patients with clinical and MRI features of neural involvement due to lymphoma. Majority (4/5) were in the middle to elderly age group ranging from 38 to 80 years, at the time of presentation. Only one young male aged 25 was reported to present with cranial and spinal nerve involvement with lymphoma. Most of the patients were males. Similar findings were reported by the retrospective study conducted by Grisariu *et al*.,[2] where 60% of the patients were males, and the mean age of the patients was 55.5 years.

Clinically, all patients presented with symptoms of cranial nerve involvement, most commonly diplopia and facial palsy. While parenchymal lesions were seen in three out of five patients at initial MRI, they showed no obvious clinical signs of parenchymal involvement (such as cerebellar signs and frontal lobar signs). The cranial nerves involved include optic, oculomotor, trigeminal, facial, vestibulocochlear, glossopharyngeal, vagus, and accessory nerves, out of which the trigeminal and VII–VIII nerve complex was most commonly involved.

Petluri *et al*.[6] in their review concluded that neurolymphomatosis can present as: (a) a painful polyneuropathy (most common), usually involving cauda equina or lumbosacral nerve roots, (b) cranial neuropathy involving facial, abducens, oculomotor, and trigeminal nerves in descending order of frequency, (c) painless neuropathy, and (d) peripheral mono neuropathy, commonly involving sciatic nerve, rarely involving radial, median, or intercostal nerves. Ultimately, it progresses to involvement of CSF, neural parenchyma and spinal cord.[5]

Li *et al*. revealed common involvement of III and VI cranial nerves, with isolated involvement of cranial nerves and meninges without parenchymal lesions.[7] It is also proposed that sites of anastomosis between the nerves can promote tumor spread from one nerve to the other, for example, V and VII nerves.[8] This could explain the high incidence of V and VII–VIII nerve complex involvement predominantly in the cisternal segments.

Cranial nerve involvement on imaging was commonly seen as enhancement, with few cases of nodularity and few of nerve thickening. Grisariu *et al*.[2] conducted a retrospective study in fifty patients with neurolymphomatosis and found that 90% of the involvement was due to non-Hodgkin's lymphoma. While they found peripheral and spinal nerve root involvement to be more common than cranial nerve involvement, this was not true in our case. Nerve involvement was the initial presentation of malignancy in 26% of their cases, while it was the presenting symptom and imaging finding in 100% of our patients. Nearly 76% of their patients showed enhancement of affected nerves, with thickening seen in 53% of the cases and nodularity in 30%.

Studies have reported that, occasionally, there may be enhancement of normal cranial nerves such as the geniculate, tympanic, and mastoid segments of facial nerves due to peri and epineural venous plexuses. However, enhancement of intracanalicular-labyrinthine segment of

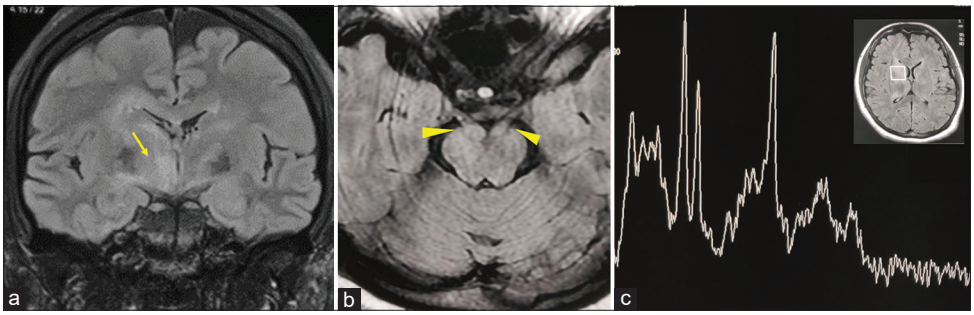

Figure 6: (a) Ill-defined FLAIR hyperintensity (arrow) in right frontal periventricular white matter and right basal ganglia region. (b) Bulky bilateral oculomotor nerves (arrowheads) in their cisternal segments. (c) Single voxel spectroscopy of right gangliocapsular lesion shows elevated choline and lipid lactate peaks. Inset: Spectroscopy localizer

facial nerve or trigeminal nerve and its branches is not physiologically seen.[4] Lymphomatous involvement of peripheral nervous system can mimic chronic inflammatory demyelinating polyneuropathy.[6]

Sixty percent of the patients demonstrated cerebellar lesions at some point during the course of the disease. Most of the patients had multiple lesions at presentation as well as on follow-up. Hyperintensities in parenchyma are commonly seen in lymphoma patients and may be misdiagnosed as inflammatory disease.[7]

Most of the parenchymal lesions depicted the classical imaging appearance of T2 iso to hypointensity and restricted diffusion as is attributed to lymphomatous involvement of the CNS in literature. A few exceptional lesions appeared T2 hyperintense. Variable degrees of homogenous contrast enhancement were noted, ranging from nonenhancing to intensely enhancing, corresponding to the findings described by Haldorsen *et al*.[9]

On spectroscopy, these lesions demonstrated Cho peaks with reduced NAA levels and lipid lactate peaks in some cases, findings similar to those reported by Mansour *et al*.[1]

Almost all the patients developed new lesions on follow-up, in spite of being on chemotherapy. Most of these new lesions were supratentorial. Mansour *et al*.[1] found that majority had a solitary parenchymal lesion, most commonly in the supratentorial hemispheric white matter, while cerebellar lesions were relatively uncommon.

One of the patients could not be followed up due to death as a result of systemic causes. Two out of the four patients that were followed up using MRI showed response to chemotherapy on latest available imaging.

Common treatment modalities include systemic chemotherapy with or without intrathecal chemotherapy or radiotherapy. Some studies have advocated the additional use of rituximab, however no substantial improvement in outcome is noted.[5]

After treatment initiation, there is improvement in 50%, no appreciable change in 25%, and worsening in the remaining 25%, with disease control post chemotherapy ranging from 2 weeks to 9 years as seen by Petluri *et al*. and Gan *et al*.[5,6]

Only one of the patients showed extracranial features associated with lymphoma-hepatosplenomegaly, skeletal lesions, and spinal epidural lesions. The same patient also showed involvement of cauda equina nerve roots. One patient presented with a meningitis-like picture on MRI and was the only case in our series with a spinal cord lesion.

MRI was the imaging modality for diagnosis and follow-up. FDG-PET-CT was not performed in all patients. MRI and PET-CT have been proven to be the most useful imaging modalities for the diagnosis of neurolymphomatosis.[2]

Biopsy, routine CSF study and CSF flow cytometry were the common techniques used to confirm the diagnosis. Non-Hodgkin lymphoma was the most common diagnosis on histopathology. However, one patient was diagnosed to have T-cell lymphoma based on CSF study and blast cells on bone marrow biopsy.

Other studies have reported that, on histopathology, there is infiltration of tumor cells into endoneurium and perineurium. Malignant cells in CSF may be seen in about 20%–40% of cases.[6] Gan *et al*.[5] also concluded that majority of cases with neurolymphomatosis are non-Hodgkin's lymphoma of the B-cell type.

Weiss *et al*.[10] reported that multiple cranial nerve involvement was the initial presentation of systemic T-cell lymphoma.

In summary, we would like to highlight that multiple cranial nerve involvement as well as spinal nerve involvement can be a presenting feature of primary CNS non-Hodgkin lymphoma. Initial MRI presentation of enhancing and thickened nerves can lead to an array of differential diagnosis, especially in the absence of typical parenchymal lesions of CNS lymphoma. We observed that, following chemotherapy, abnormal nerve enhancement subsided in nearly all cases, however most patients developed newer lymphomatous parenchymal lesions.

Declaration of patient consent

The authors certify that they have obtained all appropriate patient consent forms. In the form the patient(s) has/have given his/her/their consent for his/her/their images and other clinical information to be reported in the journal. The patients understand that their names and initials will not be published and due efforts will be made to conceal their identity, but anonymity cannot be guaranteed.

Financial support and sponsorship

Nil.

Conflicts of interest

There are no conflicts of interest.

References

1. Mansour A, Qandeel M, Abdel-Razeq H, Abu Ali HA. MR imaging features of intracranial primary CNS lymphoma in immune competent patients. Cancer Imaging 2014;14:22.
2. Grisariu S, Avni B, Batchelor TT, van den Bent MJ, Bokstein F, Schiff D, *et al.* Neurolymphomatosis: An international primary CNS lymphoma collaborative group report. Blood 2010;115:5005-11.
3. Romano N, Federici M, Castaldi A. Imaging of cranial nerves: A pictorial overview. Insights Imaging 2019;10:33.
4. Saremi F, Helmy M, Farzin S, Zee CS, Go JL. MRI of cranial nerve enhancement. AJR Am J Roentgenol 2005;185:1487-97.
5. Gan HK, Azad A, Cher L, Mitchell PL. Neurolymphomatosis: Diagnosis, management, and outcomes in patients treated with

rituximab. Neuro Oncol 2010;12:212-5.
6. Petluri G, Goyal MK, Singla V, Mittal BR, Nahar U, Modi M, *et al*. Neurolymphomatosis: A rare cause of multiple mononeuropathy. World J Neurosci 2014;2014:190-3.
7. Li JJ, Qiu BS, Chen JX, Liu DW, Xing SH, Chen HB, *et al.* Multiple cranial nerve deficits as preceding symptoms of systemic non-Hodgkin's lymphoma. CNS Neurosci Ther 2019;25:409.
8. Grisold W, Grisold A, Brianai C, Meng S. Lymphoma and the cranial nerves. Clin Oncol 2017;2:1214.
9. Haldorsen IS, Espeland A, Larsson EM. Central nervous system lymphoma: Characteristic findings on traditional and advanced imaging. AJNR Am J Neuroradiol 2011;32:984-92.
10. Weiss GA, Al-Ustwani O, Makdissi R. Multiple cranial nerve palsies as the initial presentation of peripheral T-cell lymphoma. Clin Adv Hematol Oncol 2012;10:620-3.