Original Article

Early Exposure of the Dorsal Surface of M1 Segment via the Distal Transsylvian Approach for Clipping of Anteroinferior-Projecting Middle Cerebral Artery Bifurcation Aneurysms

Kitiporn Sriamornrattanakul, Nasaeng Akharathammachote, Somkiat Wongsuriyanan

Department of Surgery, Division of Neurosurgery, Faculty of Medicine Vajira Hospital, Navamindradhiraj University, Bangkok, Thailand

Abstract

Background: Middle cerebral artery bifurcation (MCAB) aneurysms are common intracranial aneurysms. Anteroinferior-projecting MCAB aneurysms, with the M1 segment usually embedded into the deep part of the Sylvian fissure, cause some surgical challenges. The distal transsylvian approach (DTSA) allows M1 exposure from the dorsal surface for proximal control in the early step. Therefore, this study aimed to demonstrate the efficacy and safety of DTSA for clipping anteroinferior-projecting MCAB aneurysms. **Materials and Methods:** Among 97 patients with MCA aneurysms, 13 with anteroinferior-projecting MCAB aneurysms who underwent aneurysm clipping via the DTSA between June 2018 and January 2021 were retrospectively evaluated for the aneurysm obliteration rate, surgical complications, and outcomes. **Results:** Ten patients (76.9%) had ruptured MCAB aneurysms and three (23.1%) had incidentally discovered unruptured MCAB aneurysms. Favorable outcome was achieved in 100% of patients with good grade. The complete aneurysm obliteration rate was 100% without intraoperative lenticulostriate artery injury. Twelve (92.3%) patients had early identified distal M1 segment for proximal control, and one (7.7%) patient had premature rupture of aneurysm that achieved favorable outcome at 3 months postoperatively. Difficult M1 exposure and premature rupture occurred in the patient with MCAB located above the Sylvian fissure line. Permanent postoperative neurological deficit was detected in one patient due to severe vasospasm. **Conclusions:** DTSA, which simplify the early exposure of the dorsal surface of distal M1, is safe and effective for clipping anteroinferior-projecting MCAB aneurysms without extensive Sylvian fissure dissection. High-positioned MCAB requires careful dissection of the aneurysm neck with consideration of tentative clipping preparation.

Keywords: *Anteroinferior-projecting aneurysm, distal transsylvian approach, middle cerebral artery aneurysm, middle cerebral artery bifurcation aneurysm*

Introduction

The middle cerebral artery bifurcation (MCAB), located at the first major bifurcation of the middle cerebral artery (MCA), is the common location of intracranial aneurysms (18%–20%) and the most common location of MCA aneurysms (80%–85%).[1-3] Majority of previous studies suggested that microsurgical clipping provided better efficacy than endovascular techniques for the management of patients with MCA aneurysm.[4-7]

The traditional pterional approach for MCA aneurysms by Yasargil *et al*. was proposed in 1975. They utilized the microsurgical dissection of the MCA in the proximal to distal fashion (proximal transsylvian approach).[8] Pritz *et al*. proposed the distal transsylvian approach (DTSA) for MCAB aneurysms with good outcomes in 1994.[9] Various projections of MCAB aneurysms required different surgical strategies for clipping. Heros and Fritsch proposed three main approaches for MCA aneurysms: (1) the proximal Sylvian fissure (proximal transsylvian), (2) the distal Sylvian fissure (distal transsylvian), and (3) transcortical superior temporal gyrus approach, which were indicated for different locations and projections of MCA aneurysms. The disadvantage of the proximal approach is that the dissection performed is relatively extensive and risks

This is an open access journal, and articles are distributed under the terms of the Creative Commons Attribution-NonCommercial-ShareAlike 4.0 License, which allows others to remix, tweak, and build upon the work non-commercially, as long as appropriate credit is given and the new creations are licensed under the identical terms.

For reprints contact: WKHLRPMedknow_reprints@wolterskluwer.com

How to cite this article: Sriamornrattanakul K, Akharathammachote N, Wongsuriyanan S. Early exposure of the dorsal surface of M1 segment via the distal transsylvian approach for clipping of anteroinferior-projecting middle cerebral artery bifurcation aneurysms. Asian J Neurosurg 2021;16:797-804.

Submitted: 14-Jul-2021 **Revised:** 12-Aug-2021
Accepted: 17-Aug-2021 **Published:** 18-Dec-2021

Address for correspondence:
Dr. Kitiporn Sriamornrattanakul, Department of Surgery, Division of Neurosurgery, Faculty of Medicine Vajira Hospital, Navamindradhiraj University, Bangkok, Thailand. E-mail: kitiporn6823@gmail.com

Access this article online

Website: www.asianjns.org

DOI: 10.4103/ajns.ajns_275_21

Quick Response Code:

of injury to the Sylvian fissure are high. The important drawback of the distal approach was a late exposure of the M1 segment for the proximal control.[2]

For clipping of the MCAB aneurysms with anteroinferior projection, identification of the proximal and middle parts of M1, which usually course superoposteriorly into the deep part of the Sylvian fissure, is difficult and needs extensive Sylvian fissure dissection carrying a high risk of brain damage. The authors performed the DTSA for clipping of this specific type of MCAB aneurysms. The proximal control, the most important step, was early obtained by accessing the dorsal surface of the distal M1 segment with distal Sylvian fissure dissection [Figure 1]. With this approach, the aneurysm neck was exposed before the aneurysm dome [Figure 2] and the proximal Sylvian fissure dissection was not necessary.

In this study, rates of early exposure of distal M1 and complete aneurysm obliteration were evaluated to determine the efficacy of DTSA. Surgical complications, such as premature aneurysm rupture, postoperative brain contusion, and lenticulostriate artery injury, were also evaluated to identify the safest approach.

Materials and Methods

Patients with anteroinferior-projecting MCAB aneurysms who underwent the DTSA for aneurysm clipping at the Faculty of Medicine Vajira Hospital, Navamindradhiraj University, between June 2018 and January 2021 were retrospectively reviewed. Patient data, aneurysm characteristics, MCAB location, the incidence of premature rupture of aneurysm, completeness of aneurysm obliteration, postoperative complications, and Glasgow outcome score (GOS) at 3 months postoperatively were reviewed and analyzed.

Operative techniques for distal transsylvian approach

After careful evaluation of the preoperative computed tomography (CT) angiography, the surgical approach was planned [Figure 2a-c]. The patient was placed in supine position with the head of the bed tilted approximately 30° above the heart level. The patient's face was turned approximately 40°–45° away from the side of the operation with the vertex parallel to the floor and the neck extended in the sniffing position. The important key that facilitates this approach was the vertex not directed down but parallel to the floor to prevent falling down of the temporal lobe to obscure the Sylvian fissure. Two self-retaining retractors were prepared. After the scalp flap was created, frontotemporal craniotomy was performed to cover the whole length of the Sylvian fissure [Figure 1a]. The sphenoid ridge was drilled until flat. The dura was opened in "U" shape with the base at the sphenoid ridge to cover the proximal and distal Sylvian fissures. When subarachnoid hemorrhage with brain edema was observed, the frontal lobe was gently elevated and the cerebrospinal fluid was released from the carotid cistern and lamina terminalis. The supraclinoid internal carotid artery (ICA) and proximal M1 segment of MCA were secured through the subfrontal route [Figure 2d]. This step should be carefully performed in case the aneurysm dome adheres to the sphenoid wing. Under high magnification of the operating microscope, the distal Sylvian fissure was sharply dissected with micro-scissors using the integrated multi-maneuver dissection technique after the arachnoid membrane was tensed using two retractors [Figure 2e]. The starting point of the dissection was 6–7 cm from the tip of the temporal lobe in the side of no bridging veins [Figure 2f]. Outside-in and inside-out (paperknife) technique was used to dissect the Sylvian fissure with high magnification.[10,11] The key step of this technique is the distal Sylvian fissure dissection deep down to the dorsal surface of distal M1 before dissecting the aneurysm dome. The middle part of the M1 segment, which usually courses in the deep part of the Sylvian fissure, was not necessarily identified. With the meticulous cutting of arachnoid trabeculae and wide opening of the distal Sylvian fissure, both retractor blades were placed on both sides of the Sylvian fissure (intrasylvian retraction) and work as brain holders [Figure 2g]. The spatulas were transitioned in

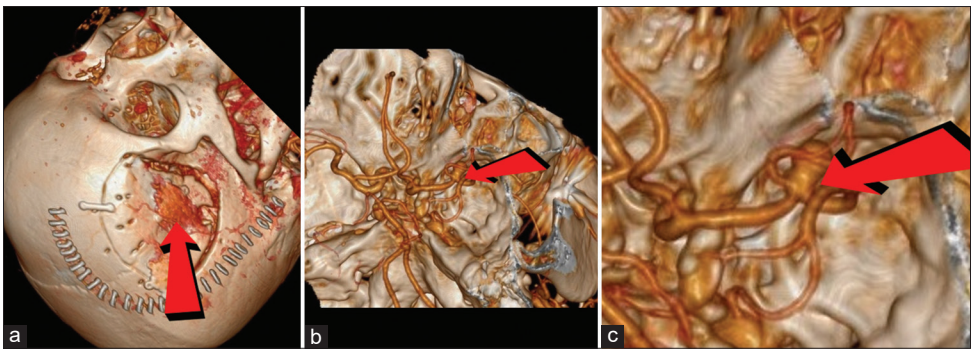

Figure 1: The distal transsylvian approach for the anteroinferior-projecting middle cerebral artery bifurcation aneurysm. (a) Skin incision, skull flap, and direction of the approach (arrow). (b) The direction of the approach to the middle cerebral artery bifurcation and aneurysm neck (arrow). (c) Magnification of (b) demonstrated the direction (arrow) and target of the approach

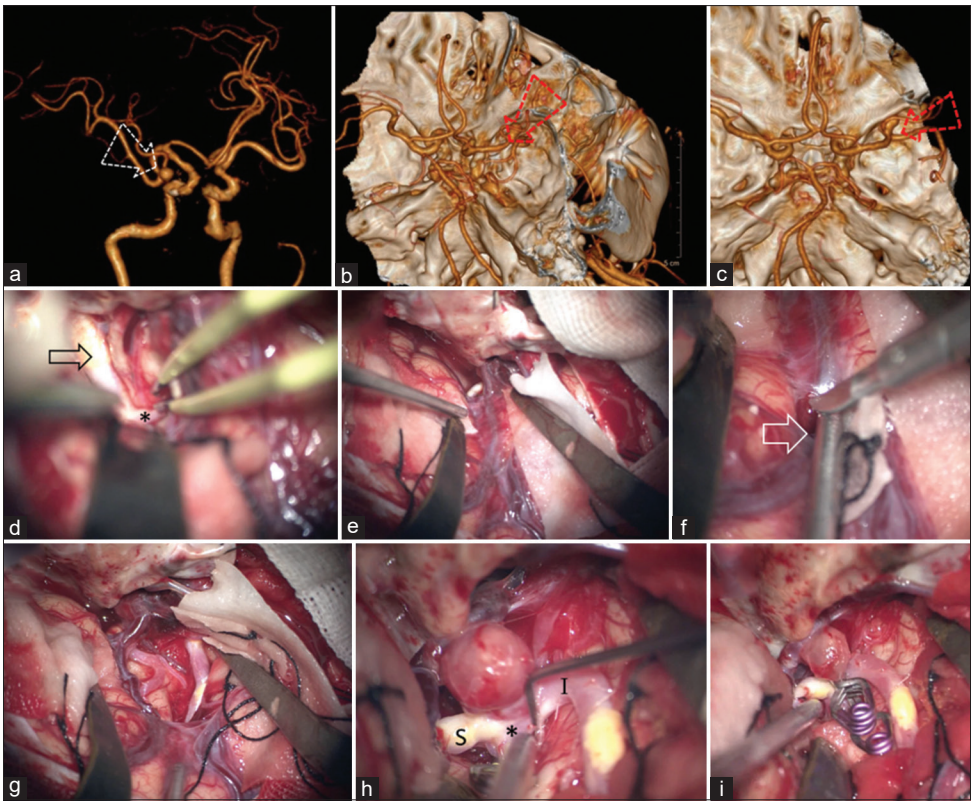

Figure 2: Case No. 2 (a) right anterolateral view of three-dimensional CTA demonstrates an anterior-projecting MCAB aneurysm and direction of the DTSA (arrow). (b and c) 3D CTA with skull base shows the direction of the DTSA approach (arrow) in different views. (d) The right supraclinoid internal carotid artery (arrow) and proximal M1 (asterisk) were exposed through the subfrontal route. (e) The entire right Sylvian fissure was exposed and prepared using two retractors for dissection. (f) The starting point of dissection was 6–7 cm from the tip of the temporal lobe. (g) Wide opening of the distal Sylvian fissure. (h) MCAB (asterisk), superior trunk (S), and inferior trunk (I) of M2 were identified through the DTSA. (i) Final view after a definite aneurysmal clipping. CTA – Computed tomography angiography, DTSA – Distal transsylvian approach, M1 – The first segment of the middle cerebral artery, M2 – The second segment of the middle cerebral artery, MCAB – Middle cerebral artery bifurcation

a "fan-stair" shape in steps according to the Sylvian fissure's profile.[12] The Sylvian veins and their branches should be preserved as much as possible. M4, M3, and M2 segments of MCA were identified respectively, and then the superior or inferior trunk of M2 was followed proximally to MCAB and distal M1 segment before dissection of the aneurysm neck and dome [Figure 2h]. The dorsal surface of M1 was confirmed and prepared for temporally clip placement without damaging the lenticulostriate arteries. Both sides of the aneurysm neck were identified and prepared for neck clipping. In the case of short M1 segment with the distal M1 obscured by limen insulae, exposure of the distal M1 is not easy and the pilot (tentative) clipping on the aneurysm dome should be prepared for premature rupture. The medial retraction of the limen insulae may be performed to identify the distal M1. The hallmark to differentiate the distal M1 from proximal M2 branches was lenticulostriate arteries located on the dorsal wall. After the proximal control at the distal M1 from the dorsal side, the definite clipping of the aneurysm neck should be placed at the ideal closure line [Figures 2i and 3].[13-15] The patency of M1 and both M1 were confirmed using a micro-Doppler and indocyanine green.

Outcome assessment

Surgical outcomes were evaluated at 3 months postdischarge with GOS by direct examinations or telephone interviews. A patient with good grade was defined as having an initial World Federation of Neurosurgical Societies (WFNS) grade of 1–3 in ruptured cases and an intact neurological status at preoperative period in unruptured cases. Patients with an initial WFNS grade of 4–5 in the subarachnoid hemorrhage group and a major neurological deficit in the unruptured group was classified as patients with poor grade.

Postoperative brain contusion, new neurological deficit postoperatively, intraoperative lenticulostriate artery injury, completeness of aneurysm obliteration, premature rupture of aneurysms, and surgical outcome were analyzed. GOS of 4 and 5 was defined as favorable outcomes, whereas GOS of 1–3 was defined as an unfavorable outcome.

Results

Among 97 patients with MCA aneurysms, 13 underwent microsurgical clipping of anteroinferior-projecting MCAB aneurysms using the DTSA [Table 1]. Ten patients (76.9%) suffered from ruptured MCAB aneurysms, including 8 (80%) with initial WFNS grades 1–2 (good grade).

Three patients (23.1%) had unruptured MCAB aneurysms, which are incidentally discovered. Increased size of the aneurysm was detected in the serial imaging in one patient (case No. 1). One patient (case No. 3) with unruptured aneurysm had previous subarachnoid hemorrhage from a contralateral MCAB aneurysm. Another unruptured case (case No. 13), with MCAB aneurysm and anterior temporal artery aneurysm, suffered from A1 injury during removal of large planum sphenoidale meningioma via contralateral pterional craniotomy and need flow augmentation bypass from superficial temporal artery to the anterior cerebral artery.

Ten patients (76.9%) were classified as good grade including eight ruptured and two unruptured cases. Three patients had poor grade (23.1%), including two with ruptured (case No. 6, 9) and one with unruptured aneurysm (case No. 13) who has preoperative paraparesis from the previous surgery. Grade 3 of the modified Fisher grade was detected in 9 patients (90%) with ruptured aneurysm. The average size of the aneurysm was 4.2 mm. Aneurysm projections were anterior in six patients (46.1%), anteroinferior in four (30.8%), inferior in two (15.4%), and anterolateral in one (7.7%). Curvatures of the M1 segment of MCA were posterior in six (46.1%) and posterosuperior in six patients (46.1%). The straight course of the M1 segment was detected in one patient (7.7%).

On the preoperative CT angiography (CTA), the MCAB located at or below the Sylvian fissure line [Figure 4, a straight line from the limen insulae to lateral Sylvian fissure in coronal plane] was detected in all patients [Figure 4a, b and d], except in one patient (case No. 9) with MCAB located above the line [Figure 4c]. The early distal M1 exposure was intraoperatively achieved in all patients, except in one patient (case No. 9) with MCAB located above the line. Premature rupture of the aneurysm occurred in one patient (7.7%, case No. 9) who achieved favorable outcomes at 3 months postoperatively. The lenticulostriate artery injury did not occur intraoperatively in all patients. No brain contusion was demonstrated on postoperative CT scan.

Favorable outcome at 3 months was achieved in 100% and 84.6% of patients with good grade and all patients, respectively. Unfavorable outcome in observed in two patients due to severe vasospasm with hemorrhagic infarction (case No. 6) and preoperative paraparesis from previous surgery (case No. 13). Clinical vasospasm causing postoperative hemiparesis was detected in three patients (23.1%, case No. 6, 8, 9), which all have modified Fisher grade 3. Transient hemiparesis was detected in 2 patients who completely recovered within 3 months. The rate of complete aneurysm obliteration and preservation of both M2 branches was 100%. New postoperative neurological deficit at 3 months postoperatively was detected in one patient (case No. 6) who suffered severe vasospasm with hemorrhagic infarction.

Table 1: Patient data, middle cerebral artery bifurcation aneurysm characteristic, surgical complications, and outcomes

Case number	Sex/age (year)	Rupture	WFNS grade/ modified fisher grade	Aneurysm size (mm)	Aneurysm projection	M1 curvature	MCAB located above sylvian line	Early exposure of distal M1	Premature rupture	Complete aneurysm obliteration	Postoperative cerebral contusion	Lenticulostriate artery injury	Postoperative complications	New postoperative deficits	GOS at 3 months
1	Male/57	No	-/0	6	Anterior	Posterior	No	Yes	No	Yes	No	No	No	No	5
2	Female/67	Yes	1/3	4	Anterior	Posterosuperior	No	Yes	No	Yes	No	No	No	No	5
3	Female/48	No	-/0	4	Anteroinferior	Posterosuperior	No	Yes	No	Yes	No	No	No	No	5
4	Female/68	Yes	1/3	5	AL	Posterosuperior	No	Yes	No	Yes	No	No	No	No	5
5	Female/71	Yes	1/3	5	Inferior	-	No	Yes	No	Yes	No	No	No	No	5
6	Male/55	Yes	5/3	3	Anterior	Posterior	No	Yes	No	Yes	Yes	No	Vasospasm, hemorrhagic infarct	Right hemiparesis, aphasia	3
7	Male/46	Yes	1/3	4	Anteroinferior	Posterosuperior	No	Yes	No	Yes	No	No	No	No	5
8	Female/36	Yes	1/3	4	Anterior	Posterior	No	Yes	No	Yes	No	No	Vasospasm	Left hemiparesis	5
9	Male/47	Yes	4/3	6	Anterior	Posterior	Yes	No	Yes	Yes	No	No	Vasospasm	Right hemiparesis	5
10	Female/64	Yes	2/3	3.5	Anteroinferior	Posterior	No	Yes	No	Yes	No	No	No	No	5
11	Female/50	Yes	1/3	4	Inferior	Posterosuperior	No	Yes	No	Yes	No	No	No	No	5
12	Male/30	Yes	1/1	3	Anterior	Posterior	No	Yes	No	Yes	No	No	No	No	5
13	Female/62	No	.*/0	3	Anteroinferior	Posterosuperior	No	Yes	No	Yes	No	No	No	No	3

*Preoperative paraparesis from the previous surgery. M1 – The first segment of middle cerebral artery; MCAB – Middle cerebral artery bifurcation; WFNS – World Federation of Neurosurgical Societies; GOS – Glasgow outcome score; AL – Anterolateral

Illustrative cases

Case 1

A 67-year-old female patient [case No. 2 in Table 1] suddenly presented with headache and full level of consciousness (WFNS Grade 1). CT and CTA revealed a thick subarachnoid hemorrhage (modified Fisher Grade 3), a 4-mm right MCAB aneurysm with anterior projection, and a posterosuperior curved right M1 segment [Figure 2a-c]. The DTSA was performed for neck clipping without premature aneurysm rupture [Figure 2d to i]. The direction of the approach was depicted by the arrow in Figure 2a-c. Aneurysm clipping was performed in the ideal closure line [Figure 3a]. Postoperative CTA showed complete obliteration of the aneurysm with preservation of both M2 branches [Figure 5a and b]. The postoperative period was uneventful. The patient had a GOS of 5 at 3 months postoperatively.

Case 2

A 47-year-old male patient [case No. 9 in Table 1] presented with sudden alteration of consciousness (WFNS Grade 4). Diffuse thick SAH (modified Fisher Grade 3), a left anterior-projecting MCAB aneurysm, and posterior curved M1 segment were detected on CTA [Figure 6a-c]. The MCAB was located above the Sylvian fissure line [Figure 4c]. The DTSA was performed for aneurysm clipping. The premature aneurysm rupture was occurred before the exposure of the M1 segment. The tentative clipping on the aneurysm dome was immediately performed to stop the bleeding [Figure 6d]. After controlling the M1 segment, the aneurysm neck, superior trunk, and inferior trunk of M2 branches were identified [Figure 6e], and then definite aneurysm clipping was performed [Figure 6f]. Postoperative CTA revealed complete obliteration of the aneurysm with preservation of both M2 branches [Figure 7a and b]. Transient right hemiparesis due to clinical vasospasm occurred in the postoperative period. The patient was discharged with right hemiparesis, and she had a GOS of 5 at 3 months postoperatively.

Discussion

Middle cerebral artery bifurcation aneurysm management: Clip or coil

For MCA aneurysms, several studies showed that the efficacy of the surgical clipping is better than the coiling with regard to the occlusion rate.[4-7,16] However, with regard to the functional outcome and procedural complications, the endovascular approach was comparable to the surgical clipping.[5,7] MCAB aneurysms typically have a wide neck that usually incorporates the origin of one or both M2 branches. As a result of this configuration, surgical clipping played a major role for the treatment of MCAB aneurysms with lower complication and morbidity rates.[17]

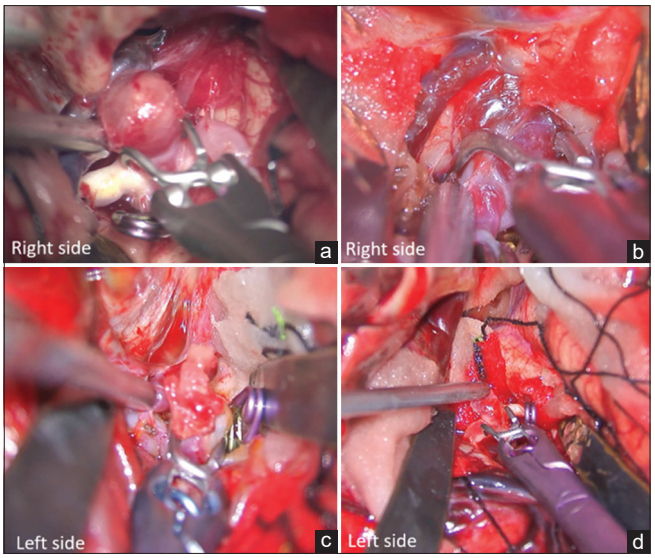

Figure 3: Ideal closure line clipping and direction of clip application in illustrative cases. (a) Right MCAB aneurysm with the anterior projection of case No. 2. (b) Right MCAB aneurysm with the anterior projection of case No. 8. (c) Left MCAB aneurysm with the anterior projection of case No. 9. (d) Left MCAB aneurysm with the anterior projection of case No. 12. MCAB – Middle cerebral artery bifurcation

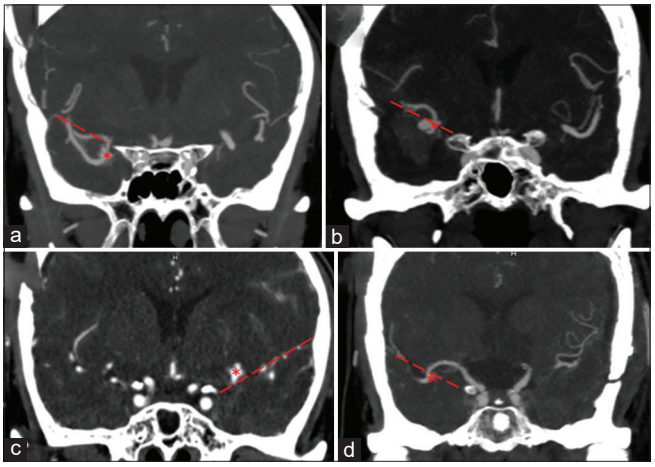

Figure 4: The Sylvian fissure line (dashed line) and MCAB (asterisk) were marked in coronal computed tomography angiography. (a) In case No. 2, the MCAB was located below the Sylvian fissure line. (b) In case No. 4, the MCAB was located at the Sylvian fissure line. (c) In case No. 9, the MCAB was located above the Sylvian fissure line. (d) In case No. 13, the MCAB was located below the Sylvian fissure line. MCAB – Middle cerebral artery bifurcation

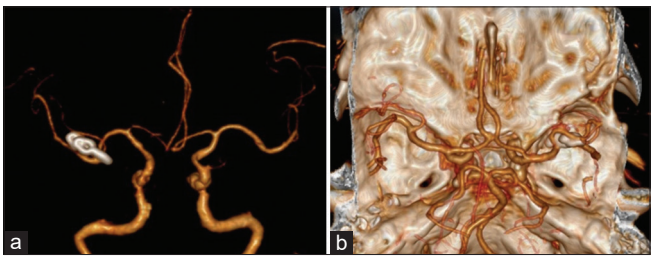

Figure 5: Postoperative CTA of case No. 2. Revealed complete aneurysm obliteration and preservation of both M2 branches. (a) Three-dimensional CTA excluding the base of the skull in anteroposterior view. (b) Three-dimensional CTA including the base of the skull in superior view. CTA – Computed tomography angiography

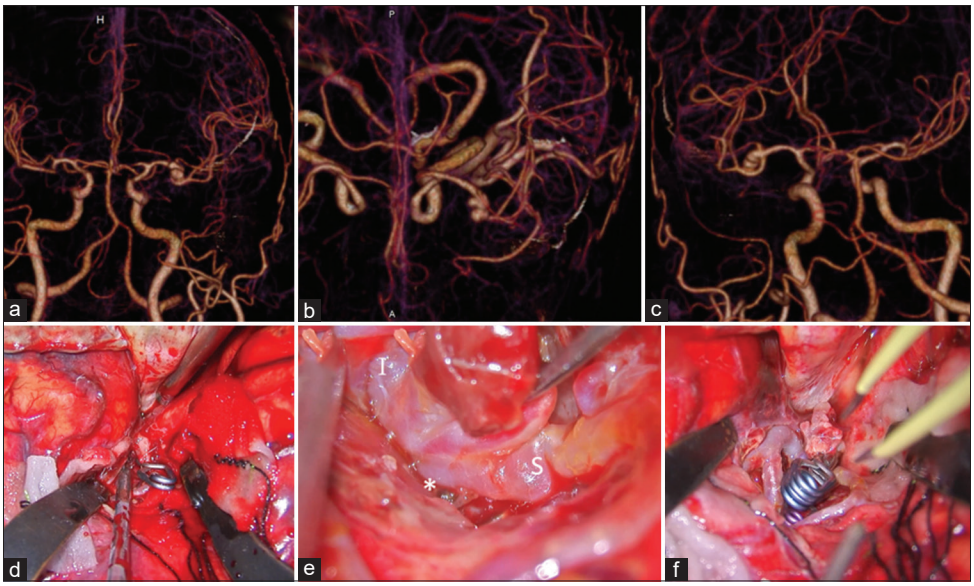

Figure 6: (a-c) Preoperative CTA of case No. 9. showed the anterior-projecting MCAB aneurysm in anteroposterior, superior, and left posterolateral views. (d) Intraoperative images showed the tentative clipping on the aneurysm dome after a premature rupture. (e) The distal M1 segment (asterisk), superior trunk (S), and inferior trunk (I) of M2 were identified. (f) The final view after the definite clipping. MCAB – Middle cerebral artery bifurcation, CTA – Computed tomography angiography

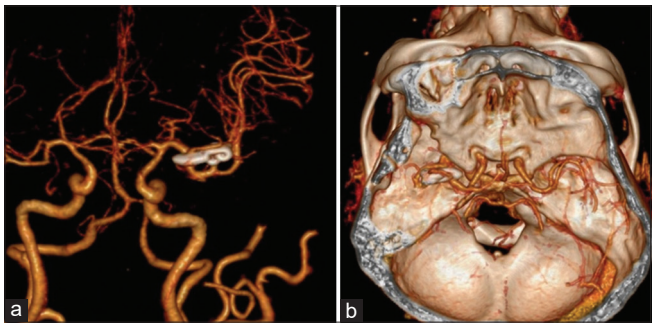

Figure 7: Postoperative CTA of case No. 9 revealed complete aneurysm obliteration and preservation of both M2 branches. (a) Three-dimensional CTA without the base of the skull in anteroposterior view. (b) Three-dimensional CTA with the base of the skull in superior view. CTA – Computed tomography angiography

Surgical approaches for clipping Middle cerebral artery bifurcation aneurysms

The traditional pterional approach by Yasargil *et al*. for MCA aneurysm utilized proximal to distal dissection of the MCA (proximal transsylvian approach).[8] Pritz *et al*. proposed the DTSA for MCAB aneurysms particularly when a long M1 is present without incidence of premature aneurysm rupture. The advantages of this approach include a relatively short length of Sylvian fissure dissection and minimal brain retraction and injury, whereas its important drawback is the lack of early M1 exposure for proximal control.[2,9,18]

The aneurysm projections and the course of the M1 segment affected the selection of surgical approaches. Projections of MCAB aneurysms with hemodynamic relation to the course of M1 segment were divided in three types: (1) inferior projection with superiorly curved M1, (2) superior projection with inferiorly curved M1, and (3) superolateral projection with the oblique course of M1.[2] Dashti *et al*. classified MCAB aneurysms into five types: Superior projection, inferior projection, lateral projection, medial projection, and complex aneurysms. Different surgical strategies were suggested for each type of aneurysms. For the inferior projection aneurysm, they suggested the proximal to distal Sylvian fissure dissection (proximal transsylvian approach). With frontal lobe retraction, the ICA, M1, and frontal M2 branches were sequentially identified. The temporal lobe retraction was suggested to be avoided due to the risk of premature rupture.[1] Elsharkawy *et al*.[19] and Di Bonaventura *et al*.[20] proposed the technique of focused opening of the Sylvian fissure for the microsurgical management of MCA aneurysms. With this technique, a 10–15-mm Sylvian opening was sufficient for proximal control and aneurysm clipping without an extensive Sylvian fissure dissection. The part of the Sylvian fissure planned to be opened should be preoperatively localized from CTA using the relation of the aneurysm neck and sphenoid ridge.

Different surgical approaches and various types of aneurysm projection have been proposed in previous studies; however, the appropriate approach for each type of aneurysm projection has not been clearly suggested and discussed.[1,2,8,9,18] With regard to aneurysm projection and course of M1 segment, the risk of premature rupture due to a lack of early M1 exposure, a disadvantage of DTSA, was high in lateral-or superior-projecting MCAB aneurysms, but low for anteroinferior-projecting aneurysms.

Authors used the DTSA for clipping of anteroinferior-projecting MCAB aneurysms because the

exposure of the M1 trunk, embedded in the deep part of the Sylvian fissure, is difficult, and early exposure of distal M1 from the dorsal surface is easily obtained. In addition, high risk of brain injury from extensive proximal Sylvian fissure dissection and premature aneurysm rupture during frontal lobe retraction, especially in patients with aneurysm that projects anteriorly and adheres to the sphenoid wing, from the proximal transsylvian approach were our rationale for the selection of the DTSA.

Advantages and special considerations of the distal transsylvian approach

With the use of DTSA in the current study, authors used two retractor blades for the frontal and temporal lobe retraction in the intrasylvian retraction manner, and retractor blades were applied as the brain holder after a wide dissection of the Sylvian fissure; therefore, the risk of premature rupture was minimized and the wide operative field provided the sufficient area for the ideal closure line clipping that needs various directions of the aneurysm clip application.[13-15]

For the MCAB aneurysm that projects anteroinferiorly, the course of the M1 segment usually curves superoposteriorly into the deep part of the Sylvian fissure and the frontal and temporal operculum that form the superficial part of the Sylvian fissure usually adhere tightly.[2] With the DTSA, the middle part of the M1 segment, which usually locates in the deep area of the Sylvian fissure, was not required; therefore, brain injury due to extensive Sylvian fissure dissection can be avoided. The distal M1 segment, which is located more superficial in the Sylvian fissure, was able to early identify the proximal control using the distal approach.

The lenticulostriate arteries usually arise from the dorsal surface of the proximal M1 segment and were rarely found to be associated with M1 bifurcation.[3] The DTSA, requiring exposure and proximal control at the distal M1 segment, may provide a low risk of lenticulostriate artery injury as the 0% incidence of the artery injury in the current study; however, the temporary clip on the distal M1 should be carefully placed to avoid damage to these arteries.

Ulm *et al*. reported that the MCAB occurs at/or distal to the genu of MCA in 94% of patients and a majority of MCAB aneurysms were associated with long M1 segment.[3] As the result of the current study, premature aneurysm rupture occurred in one patient with the MCAB located above the Sylvian fissure line (high-positioned MCAB) and underneath the limen insulae. Early exposure of the distal M1 was not achieved in this patient. Therefore, special precaution should be taken when clipping the anteroinferior-projecting MCAB aneurysm with high-positioned MCAB. The proximal M1 should be prepared via the subfrontal route before the distal Sylvian fissure dissection, and a tentative clipping on the aneurysm dome may be performed before dissecting the aneurysm neck and distal M1.

Study limitations

Limitations of this study were its retrospective descriptive nature and small number of participants due to the specific type of aneurysms and specific approach. With our best knowledge, this is the first clinical study regarding the use of early exposure of the dorsal surface of M1 segment via DTSA for anteroinferior-projecting MCAB aneurysms with clinical outcomes.

Conclusions

DTSA, which simplifies the early exposure of the dorsal surface of distal M1, is safe and effective for clipping anteroinferior-projecting MCAB aneurysms without extensive Sylvian fissure dissection. High-positioned MCAB requires careful dissection of the aneurysm neck with consideration of tentative clipping preparation.

Financial support and sponsorship

Nil.

Conflicts of interest

There are no conflicts of interest.

References

1. Dashti R, Hernesniemi J, Niemelä M, Rinne J, Porras M, Lehecka M, *et al.* Microneurosurgical management of middle cerebral artery bifurcation aneurysms. Surg Neurol 2007;67:441-56.
2. Heros RC, Fritsch MJ. Surgical management of middle cerebral artery aneurysms. Neurosurgery 2001;48:780-5.
3. Ulm AJ, Fautheree GL, Tanriover N, Russo A, Albanese E, Rhoton AL Jr., *et al*. Microsurgical and angiographic anatomy of middle cerebral artery aneurysms: Prevalence and significance of early branch aneurysms. Neurosurgery 2008;62:344-52.
4. Alreshidi M, Cote DJ, Dasenbrock HH, Acosta M, Can A, Doucette J, *et al.* Coiling versus microsurgical clipping in the treatment of unruptured middle cerebral artery aneurysms: A meta-analysis. Neurosurgery 2018;83:879-89.
5. Berro DH, L'Allinec V, Pasco Papon A, Emery E, Berro M, Barbier C, *et al*. Clip first policy versus coil first policy for the exclusion of middle cerebral artery aneurysms. J Neurosurg 2020;133:1124-31.
6. Darsaut TE, Keough MB, Sagga A, Chan VK, Diouf A, Boisseau W, *et al.* Surgical or Endovascular management of middle cerebral artery aneurysms: A randomized comparison. World Neurosurg 2021;149:e521-34.
7. Toccaceli G, Diana F, Cagnazzo F, Cannizzaro D, Lanzino G, Barbagallo GM, *et al.* Microsurgical clipping compared with new and most advanced endovascular techniques in the treatment of unruptured middle cerebral artery aneurysms: A meta-analysis in the modern era. World Neurosurg 2020;137:451-64.e1.
8. Yasargil MG, Fox JL. The microsurgical approach to intracranial aneurysms. Surg Neurol 1975;3:7-14.
9. Pritz MB, Chandler WF. The transsylvian approach to middle cerebral artery bifurcation/trifurcation aneurysms. Surg Neurol 1994;41:217-9.

10. Maekawa H, Hadeishi H. Venous-preserving sylvian dissection. World Neurosurg 2015;84:2043-52.
11. Muhammad S, Tanikawa R, Lawton M, Regli L, Niemelä M, Korja M. Microsurgical dissection of Sylvian fissure-short technical videos of third generation cerebrovascular neurosurgeons. Acta Neurochir (Wien) 2019;161:1743-6.
12. Hafez A, Buçard JB, Tanikawa R. Integrated multimaneuver dissection technique of the sylvian fissure: Operative nuances. Oper Neurosurg (Hagerstown) 2017;13:702-10.
13. Dimitriadis S, Qeadan F, Taylor CL, Yonas H, Carlson AP. Middle cerebral artery aneurysm "Neck Overhang": Decreased postclipping residual using the intersecting clipping technique. Oper Neurosurg (Hagerstown) 2018;15:440-6.
14. Ishikawa T, Nakayama N, Moroi J, Kobayashi N, Kawai H, Muto T, *et al.* Concept of ideal closure line for clipping of middle cerebral artery aneurysms--technical note. Neurol Med Chir (Tokyo) 2009;49:273-7.
15. Ota N, Tanikawa R, Noda K, Tsuboi T, Kamiyama H, Tokuda S. The efficiency of the new Yasargil titanium fenestrated mini-clips for ideal clipping of a cerebral aneurysm. Surg Neurol Int 2015;6:S553-9.
16. Xin WQ, Xin QQ, Yang XY. Meta-analysis of clipping versus coiling for the treatment of unruptured middle cerebral artery aneurysms: Direct comparison of procedure-related complications. Neuropsychiatr Dis Treat 2019;15:3387-95.
17. Nussbaum ES, Madison MT, Goddard JK, Lassig JP, Kallmes KM, Nussbaum LA. Microsurgical treatment of unruptured middle cerebral artery aneurysms: A large, contemporary experience. J Neurosurg 2019;130:1498-504.
18. Sturiale CL, La Rocca G, Puca A, Fernandez E, Visocchi M, Marchese E, *et al*. Minipterional Craniotomy for Treatment of Unruptured Middle Cerebral Artery Aneurysms. A Single-Center Comparative Analysis with Standard Pterional Approach as Regard to Safety and Efficacy of Aneurysm Clipping and the Advantages of Reconstruction. Acta Neurochir Suppl 2017;124:93-100.
19. Elsharkawy A, Niemelä M, Lehečka M, Lehto H, Jahromi BR, Goehre F, *et al.* Focused opening of the sylvian fissure for microsurgical management of MCA aneurysms. Acta Neurochir (Wien) 2014;156:17-25.
20. Di Bonaventura R, Sturiale CL, Latour K, Mazzucchi E, Marchese E, Albanese A. Comparison between minipterional craniotomy associated with focused sylvian fissure opening and standard pterional approach with extended Sylvian fissure dissection for treatment of unruptured middle cerebral artery aneurysms. World Neurosurg 2021;146:e1293-300.