Original Article

Microsurgical Anatomy of Middle Cerebral Artery in Northwest Indian Population: A Cadaveric Brain Dissection Study

Abstract

Background: Microsurgical anatomy of the Middle Cerebral Artery (MCA) of the Northwest Indian population has not been described to date. A study of cadaveric brains will add to the existing knowledge of brain vessels. **Objective:** To study and compare the microsurgical anatomy of MCA in Northwest Indian Population with that of the available literature. **Methods and Material:** 15 Formalin Fixed Cadaveric brains, that is 30 vessels from its origin from Internal Cerebral Artery to M5 segment with respect to diameter, length and branching pattern were studied under high magnification (operating microscope) and the data compared with literature. **Results:** The main trunk of MCA was 16±3 mm long with no significant differences between both sides. Its outer diameter was 3±0.1 mm. Among the early branches 58% were destined to the temporal lobe. Distance between the origin of the early branch from MCA origin was 4±2mm on the right side and 4.5±2.5 mm on the left side. The most consistent perforating branch group was the intermediate group. The pattern of branching of the main trunk was bifurcation (73%), single trunk (10%) and trifurcation (10%). Within the bifurcation group, inferior trunk dominance was seen in 50%. Amongst the cortical branches diameter of the angular artery was largest and the temporo-polar was smallest. No significant difference in the data as compared to literature. **Conclusions:** The knowledge of anatomy of MCA and its variations are important for neurosurgical residents' training and neurosurgeons dealing with MCA aneurysm management or bypass surgeries.

Keywords: *Cadaver dissection, microsurgical anatomy, middle cerebral artery*

Rakshith Srinivasa, Kedia Shwetha[1], Salunke Pravin[2], Saini Daisy[3], Basu Eilene[4], Suresh Narain Mathuriya[2], Krishnakutty Muthiraklayil Sareeshkumar[5]

Department of Neurosurgery, [4]MBBS Student, MS Ramaiah Medical College and Hospital, Bengaluru, Karnataka, [1]Department of Neurosurgery, AIIMS, Delhi, Departments of [2]Neurosurgery and [3]Anatomy, PGIMER, Chandigarh, [5]Department of Neurosurgery, Caritas Hospital, Kottayam, Kerala, India

Introduction

The initial descriptions of cerebral vasculature were given by anatomists, such as Thomas Willis in the 16th century, who laid the foundation for neurosurgeons, neurologists, and neuro-radiologists. The middle cerebral artery (MCA), is one of the branches of the circle of Willis that supplies a significant part of the cerebral hemispheres. Saccular aneurysms commonly arise from MCA and most of the arterio-venous malformations (AVM's) receive arterial supply from MCA. Branches of MCA are encountered by neurosurgeons in most supratentorial approaches. Hence a thorough knowledge of microsurgical neuroanatomy with respect to its branching and variation patterns would help the treating neurosurgeon in surgical or endovascular management. The introduction of cadaveric dissection of cerebral vasculature as a part of the neurosurgical training module would help the neurosurgical residents to understand the complex neuroanatomy of the brain vasculature and help gain confidence during the surgical procedure.[1-4]

To the best of our knowledge microsurgical anatomical studies of the MCA have not been done among the Northwest Indian population. Anatomical variations of MCA that have not been described before may come in as a surprise during any surgical intervention. Hence, we intend to record the anatomical variations of the MCA anatomy and its implications in contemporary vascular surgery and neurosurgical practice. The objective of this work was to study and compare the microsurgical anatomy and variations of MCA in northwest Indian cadavers with the available literature.

Methods

Fifteen cadaveric brains (5 cadavers and 10 retrieved formalin preserved brains), that is 30 MCA vessels were dissected

Address for correspondence:
Dr. Rakshith Srinivasa, 371, Anagha, 1st Cross, 2nd Block, R.M.V. Extension 2nd Stage, Sanjaynagar Post, Bengaluru - 560 094, Karnataka, India.
E-mail: drrakshithsrinivas@gmail.com

Access this article online

Website: www.asianjns.org

DOI: 10.4103/ajns.ajns_189_21

Quick Response Code:

This is an open access journal, and articles are distributed under the terms of the Creative Commons Attribution-NonCommercial-ShareAlike 4.0 License, which allows others to remix, tweak, and build upon the work non-commercially, as long as appropriate credit is given and the new creations are licensed under the identical terms.

For reprints contact: WKHLRPMedknow_reprints@wolterskluwer.com

How to cite this article: Srinivasa R, Shwetha K, Pravin S, Daisy S, Eilene B, Mathuriya SN, *et al.* Microsurgical anatomy of middle cerebral artery in Northwest Indian Population: A cadaveric brain dissection study. Asian J Neurosurg 2021;16:785-91.

Submitted: 08-May-2021 **Revised:** 07-Jul-2021
Accepted: 21-Jul-2021 **Published:** 28-Oct-2021

Table 1: Branching pattern of main trunk of middle cerebral artery (M1 Segment)

Branching pattern	*n* (%)
Birfurcation	24 (80)
Superior dominant	7 (29.2)
Inferior dominant	12 (50)
Equal dominance	5 (6)
Single trunk	2 (6)
Trifurcation	3 (10)
Others (more than 3)	0

using an operating microscope (Carl Zeiss) with an optical zoom of × 3 and × 20. The Sylvian fissure was split from lateral to medial, origin of MCA identified, and M1 segment (MCA segment from the origin to genu)[5] was studied with respect to the outer diameter, length, and the pattern of division of the main trunk and classified into, Type 1-bifurcation, Type 2-single trunk, Type 3-trifurcation, and Type 4-others [Table 1]. The outer diameter of each trunk and their respective lengths were measured. The early cortical branches, which arise before the actual division of the main trunk, were studied with respect to point of origin from MCA, outer diameter, the pattern of origin (single branch/stem), and area of supply. The lenticulostriate artery as defined as the branches arising from the medial and inferior aspect of the M1 segment and directed towards anterior perforated substance (APS) were identified under high magnification, their number, pattern of origin, and distance of origin from MCA were studied and classified into, medial, intermediate and lateral groups. At the limen insula where the MCA forms genu and continues into the Sylvian fissure is referred to as the M2 segment (insular segment) up to the circular sulcus of the insula. M2 studied with respect to the outer diameter, length, pattern of division, and the origin of cortical branches, similarly opercular segment (M3) and cortical segment (M4 and M5) were studied. Schematic hand drawings of the MCA segments were done for each vessel, relevant photographs taken and the cortical branches were studied up to the cerebral convexity. The measurements were taken with the help of digital micro calipers and the measurements were compared and confirmed by 2 independent observers.

Observation and Results

The MCA originates at the bifurcation of the internal carotid artery (ICA), lateral to the optic chiasm, and courses laterally and slightly forward under the APS to reach the medial end of the Sylvian fissure. At this point, the artery turns, crosses over the limen insula, and enters the insular area. The main division of the MCA is usually seen before or at the limen insula. The secondary trunks resulting from this division will course over the surface of the insular cortex, giving rise to cortical branches while turning over the opercular cleft, these cortical branches spread out over the cerebral convexity.

Main trunk

The length of the main trunk (M1) from origin to genu, was commonly 16 ± 3 mm, with no significant difference between either side. The shortest length of M1 measured was 8 mm in one cadaver on one side and the longest being 23 mm in one cadaver with Type 3 division. The outer diameter was 3 ± 0.5 mm bilaterally.

Early branches

The cortical branches arising from the main trunk proximal to the division of M1 segment are described as early branches. Among the early branches studied 58% were destined to the temporal lobe and 29% to the frontal lobe. The temporopolar and the anterior temporal artery (ATA), which supply the temporal pole and the anterior portion of the lateral aspect of the temporal lobe, respectively, were the early branches commonly seen [Table 2]. The distance between MCA origin and the first early branch origin was 4 ± 2 mm on the right and 4.4 ± 2.5 mm on the left side. The temporopolar artery, frequently, the first cortical branch seen when the Sylvian fissure is dissected, was seen in 28 of the hemispheres studied (98%). In the 2 hemispheres, where it was absent, the vascular supply to the temporal pole was provided by the collateral branches of the ATA. The uncal artery was seen in 5 hemispheres.

Perforating branches

The medial group was seen in 20 of 30 hemispheres. Predominantly, it arose directly from the M1 segment as 2–5 single twigs, at a distance of 2–4 mm from the MCA origin, and pursued a direct course almost 90° to the APS [Figure 1a and b]. The intermediate group, most consistently seen (26 out of 30 hemispheres), originated from the M1 trunk as a single stem artery which later divided into multiple branches (2–3 branches), at a distance of 5–7 mm from the MCA origin [Figure 2] and took an oblique course to the APS. The lateral group originated from either the main trunk or secondary trunks (mostly superior trunk), was seen in 22 out of 30 hemispheres, at a distance of 7–15 mm from the MCA origin, and took an "S" shape course to the APS.

Main division and secondary trunks

The main trunk of the MCA was classified based on its pattern of division into secondary branches [Table 1]. The trunks arising from the division of MCA's main trunk were called "Secondary trunks." Bifurcation (Type 1): the most common type, seen in 24 of 30 hemispheres (80%) where the main trunk is divided into a superior trunk (frontal) and inferior trunk (temporal) [Figure 3a and b]. Single trunk (Type 2) in 3 out of 30 hemispheres (10%), the cortical branches arose as collateral vessels from a single trunk that ended in the angular artery [Figure 4a and b]. Trifurcation (Type 3) in 3 out of 30 hemispheres (10%), the main trunk divided into, superior, middle, and inferior trunks [Figure 5a and b]. Type 4 (Others), >3

Table 2: Classification based on division of M1 into Secondary trunks. Length, Outer diameter and Number of Cortical Branches from Secondary trunks

Classification	Outer diameter (mm)		Length (mm)		Number of cortical branches
	Right	Left	Right	Length	
Type 1					
Superior trunk	1.9±0.9	1.9±0.3	17.8±2	16.9±2.1	4±2
Inferior trunk	2.3±0.1	2.0±0.2	17.2±0.9	17.0±0.9	4±2
Type 2			Single trunk group		
Single trunk	2.9±0.1		38±10		8±2
Type 3		Trifurcation group			
Superior trunk	1.8±0.2	1.9±0.2	23	18	2±1
Middle trunk	1.9±0.2	2.0±0.1	37	30	2±1
Inferior trunk	2.1±0.1	1.9±1.1	56	40	4±2
Type 4			Non		

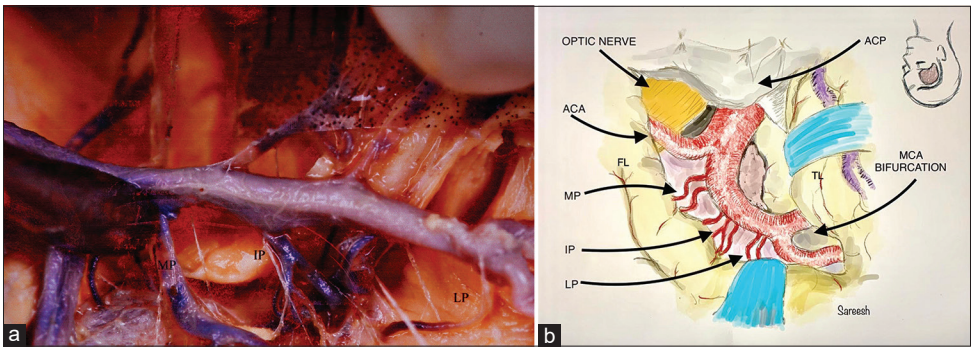

Figure 1: (a) Perforator (b) Schematic sketch diagram: Perforator. MP - Medial perforator; IP - Intermediate perforator; LP - Lateral perforator; ACA - Anterior cerebral artery; FL - Frontal lobe; TL - Temporal lobe; ACP - Anterior clinoid process

Figure 2: IP – Single stem branching into multiple branches. IP - Intermediate perforator

trunks-none in this study. Among the 24 cases in type 1, 5 hemispheres had equal dominance of trunks (20.8%), 12 had inferior trunk dominance (50%) [Figure 6a and b] and 7 had superior trunk dominance (29.1%). The length, outer diameter and division pattern, and number of cortical branches from secondary trunks were studies [Table 2].

Cortical branches

The distribution of the cortical branches of the MCA has been extensively described. In this study, 10 cortical branches were studied near their origin from M1 and M2 segments of the MCA.[6] The cortical branches studied were, temporopolar, anterior, middle, posterior temporal, angular, orbitofrontal, precentral, central, anterior parietal, and posterior parietal arteries. The pattern of origin of cortical branches from M2 [Table 3]. The outer diameter of the cortical branches at their origin and also the distance of origin from the MCA origin was measured [Table 4]. The temporopolar, anterior temporal and orbitofrontal arteries originated relatively close to MCA origin and the angular artery, posterior parietal, and posterior temporal arise distally in the posterior half of the insular area. In Type 1, the cortical branches from the secondary trunks were as follows-the superior trunk gave rise to orbitofrontal, prefrontal, precentral, and central arteries, and the inferior trunk gave rise to anterior temporal, middle temporal, posterior temporal, and angular arteries while the anterior and posterior parietal was seen to arise from the dominant trunk. In Type 3, the superior trunk gave rise to the orbitofrontal, prefrontal, precentral, and central artery. The middle trunk gave rise to anterior parietal, posterior parietal, and angular artery, and the inferior trunk gave rise to the anterior, middle, and posterior temporal arteries. The unusual origin of cortical arteries was not observed.

Stem arteries

The temporopolar and the ATA were the most common vessels arising from a common stem, seen in 90% of

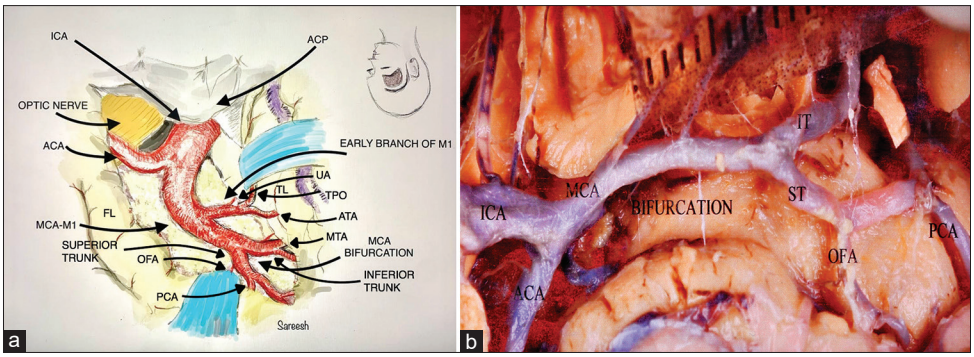

Figure 3: (a): Bifurcation pattern (b) Schematic sketch diagram - Bifurcation pattern. ICA - Internal cerebral artery; MCA - Middle cerebral artery; ACA - Anterior cerebral artery; ST - Superior trunk; MT - Middle trunk; IT - Inferior trunk; ACP - Anterior clinoid process; FL - Frontal lobe; TL - Temporal lobe; OFA - Orbitofrontal artery, PCA - Precentral artery, UA - Uncal artery, TpO - Temperopolar artery, ATA - Anterior temporal artery, MTA - Middle temporal artery

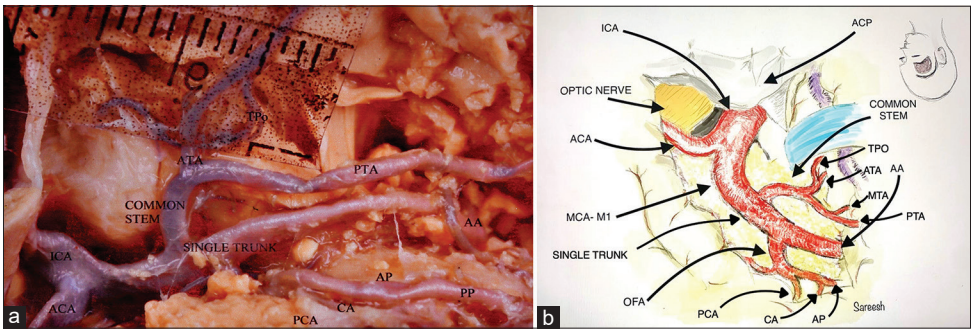

Figure 4: (a) Single trunk. (b) Schematic sketch diagram - Single trunk. ATA - Anterior temporal artery; PTA - Posterior temporal artery, PCA - Precentral artery, CA - Central artery, AP - Anterior parietal artery, PP - Posterior parietal artery, AA - Angular artery; ICA - Internal cerebral artery, MCA - Middle cerebral artery, ACA - Anterior cerebral artery, ACP - Anterior clinoid process, FL - Frontal lobe, TL - Temporal lobe; PTA - Posterior temporal artery

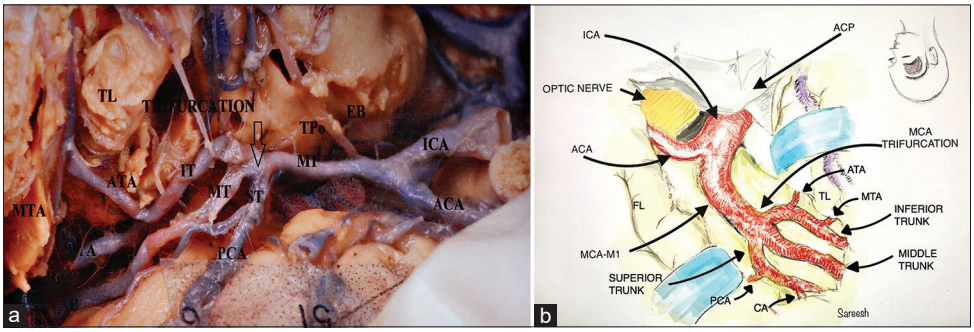

Figure 5: (a) Trifurcation pattern (b) Schematic sketch diagram - Trifurcation pattern. ICA - Internal cerebral artery; MCA - Middle cerebral artery; ACA - Anterior cerebral artery; EB - Early branch; ST - Superior trunk; MT - Middle trunk; IT - Inferior trunk; ACP - Anterior clinoid process; FL - Frontal lobe; TL - Temporal lobe; PCA - Precentral artery; CA - Central artery; ATA - Anterior temporal artery; MTA - Middle temporal artery

hemispheres. Less frequent associations, the anterior temporal, middle temporal and posterior temporal arteries in 5%; anterior temporal and posterior temporal arteries in 5%; posterior temporal, posterior parietal, and central arteries in 2%; central, anterior parietal, and precentral arteries in 4%; precentral, central, and orbitofrontal arteries in 3%; posterior parietal and central arteries in 3%; and orbitofrontal and central arteries in 1%. While commonly 2 stem pattern was observed in the frontal lobe, temporal lobe had 4 stem pattern and the parietal lobe had 2 stem pattern [Table 5].

Cortical arteries

The cortical arteries arose from the stem arteries and supplied the individual cortical areas. Generally, one or less commonly, two cortical arteries passed to each of the 12 cortical areas, the smallest cortical arteries arose at the anterior end of the Sylvian fissure and the largest ones at the posterior limits of the fissure. The cortical branches to the frontal, anterior temporal, and anterior parietal areas were smaller than those supplying the posterior parietal, posterior temporal, temporo-occipital, and angular areas. The smallest arteries supplied the orbitofrontal and temporopolar areas, and the largest ones supplied the temporo-occipital and the angular areas.

Discussion

The main trunk of MCA takes origin from ICA (B), lateral to the optic chiasm, and travels toward the medial end of

Table 3: Origin of early branches and cortical branches

Cortical artery	Early branch (%)	Single trunk (%)	Bifurcation (%)		Trifurcation (%)			Others
			ST	IT	ST	MT	IT	
Temporopolar	73.4	6	-	26.6	-	-	6	-
Anterior temporal	53	6	-	4	-	-	3	-
Middle temporal	20	6	-	8	-	3	-	-
Posterior temporal	-	6	-	13	-	-	3	-
Angular	-	6	3	13	-	-	3	-
Orbitofrontal	26	6	63.3	-	10	-	-	-
Precentral	-	6	83	-	6	3	-	-
Central	-	6	83	-	3	6	-	-
Anterior parietal	-	6	66.6	26.6	-	6	3	-
Posterior parietal	-	6	40.6	53.3	-	3	6	-

ST – Superior trunk; MT – Middle trunk; IT – Inferior trunk

Table 4: Outer diameter of cortical vessels and distance of their origin from middle cerebral artery origin

Cortical branch	Outer diameter		Distance from ICA (B) (mm)
	Right (mm)	Left (mm)	
Temporopolar	0.3±0.2	0.3±0.4	4.5±3
Anterior temporal	0.6±0.3	0.6±0.2	14.6±4
Middle temporal	1.0±1.2	1.2±0.9	24.6±2.4
Posterior temporal	1.3±0.4	1.3±1.0	31±9
Orbitofrontal	0.9±1.0	1.0±0.2	19.4±1.6
Precentral	1.1±0.2	1.0±0.3	26.3±1.3
Central	1.2±0.2	1.2±0.3	29.2±1.3
Anterior parietal	1.2±0.1	1.1±0.2	33±2.3
Posterior parietal	1.3±0.1	1.3±0.2	35±4.1
Angular	1.5±0.4	1.5±0.3	34.8±0.9

ICA – Internal cerebral artery

Table 5: Stem arteries

Lobe	1 stem, *n* (%)	2 stem, *n* (%)	3 stem, *n* (%)	4 stem, *n* (%)	5 stem, *n* (%)
Frontal	4 (13.3)	17 (56.6)	6 (20)	3 (10)	0
Temporal	3 (10)	8 (26.6)	10 (33.3)	9 (30)	0
Parietal	-	6 (20)	14 (46.6)	10 (33.3)	0

Sylvian fissure below the APS.[5,7-9] Bifurcation was seen in 80% of cases in our study similar to other studies[7,9,10] single trunk in 6% and trifurcation in 10%. In a North Indian study,[11] bifurcation was seen in 64%, single trunk in 6%, and trifurcation in 29%. In a South Indian study,[12,13] bifurcation was seen in 90%, trifurcation in 10%, and no single trunk. The mean distance between the origin of the MCA and its main division was 18 ± 2.4 mm (right hemisphere) and 18 ± 2.2 mm (left hemisphere), with no significant difference between the two. In other studies, the mean length of M1 was measured to be 15 ± 1.3 mm,[9] 14–16 mm,[14] and 20 mm.[12] The diameter of M1 at origin was 2–3.5 mm with no significant difference between both sides, in our study. In other studies, the mean diameter of M1 was 3 ± 0.1 mm[9] and 2–4 mm.[12]

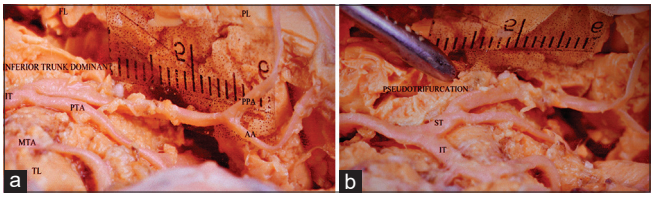

Figure 6: (a) Inferior dominant (b) Pseudotrifurcation. IT - Inferior trunk; MTA - Middle temporal artery; PTA - Posterior temporal artery; PPA - Posterior parietal artery; AA - Angular artery; ST - Superior trunk

The most proximal division (early bifurcation) was seen at 8 mm and the most distal division (late bifurcation) at 25 mm. The more proximal the division, the more likely that the perforating branches would arise from the secondary trunks.[5,7,9] Most saccular aneurysms of the MCA are located near the main division of the artery.[15,16] Thus, while dissecting the aneurysm, the surgeon should be aware of the possibility of finding perforating branches that run in a recurrent course from one of the secondary trunks toward the APS.

Perforators arose M1 in 79%, 15.3% from M2 (superior - 8.5%, middle - 0.9%, inferior - 5.9%); and the remaining 5.7% originated from early branches (early temporal branches, 5.3%, early frontal branches, 0.4%),[9] from M1 79.6% and from M2 in 20.3%.[11,17] In our study, 90% perforating arteries were seen to arise before bifurcation and 10% from secondary trunks (superior trunk 8%, inferior trunk 2%) and 3% from early branches. The number of perforators ranges from 3 to 15 in number.[14,18] In our study, the number varied from 3 to 12. Four patterns of origin of perforators were seen,[14] the most frequent being a single stem artery that then divides into many branches (seen in 40%), two large parallel arteries that immediately divide into numerous branches (30%), and numerous small twigs which arise directly from the inferio-medial side of M1 (30%). The perforators can be divided into medial, intermediate, and lateral groups.[14] The most consistent of the groups was the intermediate group in the current study, seen in 93.3% with the commonest pattern being a single large stem which divided early into

multiple small arteries in its course to APS. The medial group was seen in 80%, commonly arose as 2–4 parallel arteries at an obtuse angle from the parent artery (the angle was however not measured). The lateral group was seen in 88.7%, and arose as multiple small twigs at an acute angle from the parent vessel and took an S shape course to APS. Perforators originated from MCA origin at a distance of 1 ± 0.2 mm (medial group), 4 ± 1 mm (intermediate group), and 10 ± 2 mm (lateral group).

The knowledge of anatomy and the possibility of an early branch is important for the surgical aspect, which would give a pseudo bifurcation appearance and result in misinterpretation of true bifurcation and branches. The commonest early branch seen in our study was the temporopolar artery (73.4%) as compared to 92% in other studies.[9] The uncal artery was seen to arise as an early branch in 5 cases (16%) in our study. It is reported that the uncal artery takes origin mostly from ICA.[14] The commonest vessels arising as a common stem pattern in our study were the temporopolar and ATA (43.3%), similar to other studies.[7,9]

The MCA is one of the most common sites of saccular aneurysms,[15,16,19,20] mostly located on the distal part of the M1 segment at the bifurcation of MCA. Saccular aneurysms rarely arise distal to the proximal portion of the M2 segment. Traumatic aneurysms or bacterial aneurysms are located most commonly in the M4 segment.[21-23] The majority of intracranial AVM's receive part of their blood supply from branches of the MCA.[24] Clinical syndromes associated with occlusion of the individual cortical branches of MCA are rare.[25-28] Embolisms frequently cause occlusion of the MCA than thrombosis.[26-28] EC-MCA anastomosis is a treatment option for distal MCA occlusions and moya-moya disease.[29] The external diameter of 1 mm is the minimum requirement for long-term anastomosis patency.[30] In the temporal zone, an artery with a diameter >1.0 mm was present in 70% of the hemispheres. Chater *et al*.[30] recommended small craniotomy for exposing the cortical branches of the MCA and that it be centered 6 cm above the external auditory canal. The distance between the ear canal and the posterior end of the Sylvian fissure was recorded to be 6.6 cm in length,[9] similar to our study. The outer diameter of the vessels in the insular area was larger than 1 mm, and in the case of the secondary trunks, it was usually >2 ± 0.2 mm in our study, similar to other studies.[7-9] The angular artery, the vessel most appropriate for external carotid-ICA anastomosis, was the largest among cortical branches, 1.4 ± 1 mm in our study, and 1.5 ± 0.2 mm in another study.[7] Anomalies of the MCA are less common.[11,31,32] The anomalies reported are duplication and accessory MCA.[12,17,19] Aneurysm of the accessory MCA has been reported.[33,34] There were no anomalies observed in our study.

Several authors have used different contrast media, which helps in delineating vascular microanatomy better.[5,35,36] In the current study, though initially contrast media (CSD granules) was injected, due to technical reasons, the uptake was not acceptable. Hence, most brains dissected were without prior contrast administration.

Conclusion

Good knowledge of the microsurgical anatomy of MCA and its variations is a prerequisite for a neurosurgeon operating in this area, the frequent mistake of misinterpreting early branch for division of the main branch, can be avoided with knowledge of its occurrence of the same. Cadaveric microsurgical dissection and practice if included as an integral part of neurosurgical training, as in our institute, will improve the neuroanatomical knowledge and understanding during live surgical or endovascular procedures. All neurosurgical training institutes should have a fully equipped microsurgical cadaveric lab and microsurgical dissection should be included as part of the neurosurgical training curriculum.

Financial support and sponsorship

Nil.

Conflicts of interest

There are no conflicts of interest.

References

1. Aboud E, Al-Mefty O, Yaşargil MG. New laboratory model for neurosurgical training that simulates live surgery. J Neurosurg 2002;97:1367-72.
2. Gilbody J, Prasthofer AW, Ho K, Costa ML. The use and effectiveness of cadaveric workshops in higher surgical training: A systematic review. Ann R Coll Surg Engl 2011;93:347-52.
3. Gnanakumar S, Kostusiak M, Budohoski KP, Barone D, Pizzuti V, Kirollos R, *et al*. Effectiveness of cadaveric simulation in neurosurgical training: A review of the literature. World Neurosurg 2018;118:88-96.
4. James HK, Chapman AW, Pattison GT, Griffin DR, Fisher JD. Systematic review of the current status of cadaveric simulation for surgical training. Br J Surg 2019;106:1726-34.
5. Rhoton AL Jr. The supratentorial arteries. Neurosurgery 2002;51:S53-120.
6. Vander Eecken HM. Morphological significance of leptomeningeal anastomoses confined to the territory of cerebral arteries. Acta Neurol Psychiatr Belg 1954;54:525-32.
7. Gibo H, Carver CC, Rhoton AL Jr., Lenkey C, Mitchell RJ. Microsurgical anatomy of the middle cerebral artery. J Neurosurg 1981;54:151-69.
8. Yasargil MG. Intracranial arteries. In: Microneurosurgery. New York: Thieme; 1987. p. 54-164.
9. Umansky F, Juarez SM, Dujovny M, Ausman JI, Diaz FG, Gomes F, *et al*. Microsurgical anatomy of the proximal segments of the middle cerebral artery. J Neurosurg 1984;61:458-67.
10. Ring BA. Middle cerebral artery: Anatomical and radio-graphic study. Acta radiol 1962;57:289-300.
11. Jain KK. Some observations on the anatomy of the middle cerebral artery. Can J Surg 1964;7:134-9.

12. Pai SB, Varma RG, Kulkarni RN. Microsurgical anatomy of the middle cerebral artery. Neurol India 2005;53:186-90.
13. Gunnal SA, Farooqui MS, Wabale RN. Study of middle cerebral artery in human cadaveric brain. Ann Indian Acad Neurol 2019;22:187-94.
14. Yasargil MG, Fox JL. The microsurgical approach to intracranial aneurysms. Surg Neurol 1975;3:7-14.
15. Locksley HB. Natural history of subarachnoid hemorrhage, intracranial aneurysms and arteriovenous malformations. Based on 6368 cases in the cooperative study. J Neurosurg 1966;25:219-39.
16. Rhoton AL Jr. Anatomy of saccular aneurysms. Surg Neurol 1980;14:59-66.
17. Grand W. Microsurgical anatomy of the proximal middle cerebral artery and the internal carotid artery bifurcation. Neurosurgery 1980;7:215-8.
18. Rosner SS, Rhoton AL Jr., Ono M, Barry M. Microsurgical anatomy of the anterior perforating arteries. J Neurosurg 1984;61:468-85.
19. Crompton MR. The pathology of ruptured middle-cerebral aneurysms with special reference to the differences between the sexes. Lancet 1962;2:421-5.
20. Perret G, Nishioka H. Report on the cooperative study of intracranial aneurysms and subarachnoid hemorrhage. Section VI. Arteriovenous malformations. An analysis of 545 cases of cranio-cerebral arteriovenous malformations and fistulae reported to the cooperative study. J Neurosurg 1966;25:467-90.
21. Asari S, Nakamura S, Yamada O, Beck H, Sugatani H. Traumatic aneurysm of peripheral cerebral arteries. Report of two cases. J Neurosurg 1977;46:795-803.
22. Bohmfalk GL, Story JL, Wissinger JP, Brown WE Jr. Bacterial intracranial aneurysm. J Neurosurg 1978;48:369-82.
23. Fleischer AS, Patton JM, Tindall GT. Cerebral aneurysms of traumatic origin. Surg Neurol 1975;4:233-9.
24. Lawton MT, Rutledge WC, Kim H, Stapf C, Whitehead KJ, Li DY, *et al*. Brain arteriovenous malformations. Nat Rev Dis Primers 2015;1:15008.
25. Waddington MM, Ring BA. Syndromes of occlusions of middle cerebral artery branches. Brain 1968;91:685-96.
26. Fisher CM. Clinical syndromes in cerebral thrombosis, hypertensive hemorrhage, and ruptured saccular aneurysm. Clin Neurosurg 1975;22:117-47.
27. Lascelles RG, Burrows EH. Occlusion of the middle cerebral artery. Brain 1965;88:85-96.
28. Lhermitte F, Gautier JC, Derouesné C. Nature of occlusions of the middle cerebral artery. Neurology 1970;20:82-8.
29. Cheikh A, Yasuhiro Y, Kasinathan S, Kawase T, Takao T, Kato Y. Superficial temporal artery: Middle cerebral artery bypass, our series of 20 cases, surgical technique and indications with illustrative cases. Asian J Neurosurg 2019;14:670-7.
30. Chater N, Spetzler R, Tonnemacher K, Wilson CB. Microvascular bypass surgery. Part 1: Anatomical studies. J Neurosurg 1976;44:712-4.
31. Teal JS, Rumbaugh CL, Bergeron RT, Segall HD. Anomalies of the middle cerebral artery: Accessory artery, duplication, and early bifurcation. Am J Roentgenol Radium Ther Nucl Med 1973;118:567-75.
32. Uchiyama N. Anomalies of the middle cerebral artery. Neurol Med Chir (Tokyo) 2017;57:261-6.
33. Handa J, Matsuda M, Okamoto K, Kidooka M. Association between accessory middle artery and cerebral aneurysm. Report of two cases. Acta Neurochir (Wien) 1982;64:151-7.
34. Waga S, Kojima T, Morooka Y, Sakakura M. Aneurysm of the accessory middle cerebral artery. Surg Neurol 1977;8:359-60.
35. Limpastan K, Vaniyapong T, Watcharasaksilp W, Norasetthada T. Silicone injected cadaveric head for neurosurgical dissection: Prepared from defrosted cadaver. Asian J Neurosurg 2013;8:90-2.
36. Soubam P, Mishra S, Suri A, Dhingra R, Mochan S, Lalwani S, *et al*. Standardization of the technique of silicon injection of human cadaveric heads for opacification of cerebral vasculature in Indian conditions. Neurol India 2018;66:439-43.