Since January 2020 Elsevier has created a COVID-19 resource centre with free information in English and Mandarin on the novel coronavirus COVID-19. The COVID-19 resource centre is hosted on Elsevier Connect, the company's public news and information website.

Elsevier hereby grants permission to make all its COVID-19-related research that is available on the COVID-19 resource centre - including this research content - immediately available in PubMed Central and other publicly funded repositories, such as the WHO COVID database with rights for unrestricted research re-use and analyses in any form or by any means with acknowledgement of the original source. These permissions are granted for free by Elsevier for as long as the COVID-19 resource centre remains active.

Journal of Autoimmunity 127 (2022) 102783

Contents lists available at ScienceDirect

Journal of Autoimmunity

journal homepage: www.elsevier.com/locate/jautimm

Leukocytoclastic vasculitis (cutaneous small-vessel vasculitis) after COVID-19 vaccination

G. Fiorillo [a,b,*], S. Pancetti [b,c], A. Cortese [a,b], F. Toso [a,b], S. Manara [c], A. Costanzo [a,d], R. G. Borroni [a,d]

[a] Dermatology Unit, Humanitas Research Hospital - IRCCS, Rozzano, MI, Italy
[b] Humanitas University, Pieve Emanuele, MI, Italy
[c] Pathology Unit, Humanitas Research Hospital - IRCCS, Rozzano, MI, Italy
[d] Department of Biomedical Sciences, Humanitas University, Pieve Emanuele, MI, Italy

ARTICLE INFO

Keywords:
Vaccines adverse reactions
Cutaneous small-vessel vasculitis
Leukocytoclastic vasculitis
COVID-19 vaccine
SARS-CoV-2 vaccine
Vaxzevria vaccine

ABSTRACT

Vaccinations may induce cutaneous adverse events, due to nonspecific inflammation or immuno-mediated reactions. Several types of vasculitis have been observed. We report on a 71-year-old woman who developed cutaneous small-vessel vasculitis after the second dose of Vaxzevria COVID-19 vaccination, showing leukocytoclastic vasculitis on histopathological examination of a skin biopsy.

Cutaneous small-vessel vasculitis is a rare condition which can be idiopathic or secondary to underlying infections, connective tissue disorders, malignancy, and medications. The pathogenesis involves immune complex deposition in small blood vessels, leading to activation of the complement system and recruitment of leukocytes.

Exacerbation of small-vessel vasculitis has been reported following the administration of various vaccines, particularly influenza vaccine. It is expected that SARS-CoV-2 vaccine results in the activation of B- and T-cells and antibody formation. We hypothesize that leukocytoclastic vasculitis caused by immune complex deposition within cutaneous small vessels could be a rare side effect of Vaxzevria COVID-19 vaccination.

1. Introduction

Vaccinations are generally safe and crucial for infectious disease prevention. Adverse events to vaccinations are usually mild and well tolerated and may include cutaneous reactions [1]. These are classified in local reactions, largely due to nonspecific inflammation and irritation at the injection site, and generalized reactions, which are usually immuno-mediated and may be associated with systemic symptoms [1]. Cutaneous adverse events related to the recently approved COVID-19 vaccines have been commonly reported, mostly including delayed large local reactions (indurated, erythematous plaque occurring more than 4 days after vaccination), local injection site reactions, urticaria, morbilliform reactions, erythromelalgia (erythematous, edematous hands and feet with burning sensation), herpes zoster lesions and chilblains [2]. We report on a patient who developed cutaneous small-vessel vasculitis after COVID-19 vaccination.

2. Case presentation

A 71-year-old woman with a history of fibrocystic mastopathy and arterial hypertension treated with atenolol presented to our emergency department for skin lesions associated with burning sensation that appeared one day earlier on both legs. She had received the second dose of Vaxzevria COVID-19 vaccine (AstraZeneca) five days earlier and did not report any known allergy or having introduced new medications in the previous weeks. On physical examination, purpuric macules and papules were present on both lower legs (Fig. 1A). Complete blood count showed 11,880 white blood cells/mm^3 (normal range, 4000–10,000/mm^3) with prevalence of neutrophils. Plasma D-dimer level was 806 ng/ml (normal range, 200–350 mg/dL) and serum C-reactive protein 5.07 mg/dL (normal range, < 0.50 mg/dL). Anti-nuclear antibodies, extractable nuclear antigen and antineutrophil cytoplasmic antibodies were negative. Complement C3 and C4 levels were respectively 83 mg/dL (normal range, 90–180 mg/dL) and <8 mg/dL (normal range, 10–40 mg/dL). Rheumatoid factor (RF) level was 17 UI/mL (normal range, < 15 UI/mL). Doppler ultrasound of lower extremities showed no signs of

* Corresponding author. Dermatology Unit, Humanitas Research Hospital - IRCCS, 20089, Rozzano, MI, Italy.
E-mail address: giovanni.fiorillo@humanitas.it (G. Fiorillo).

https://doi.org/10.1016/j.jaut.2021.102783
Received 21 November 2021; Received in revised form 16 December 2021; Accepted 22 December 2021
Available online 28 December 2021
0896-8411/© 2021 Elsevier Ltd. All rights reserved.

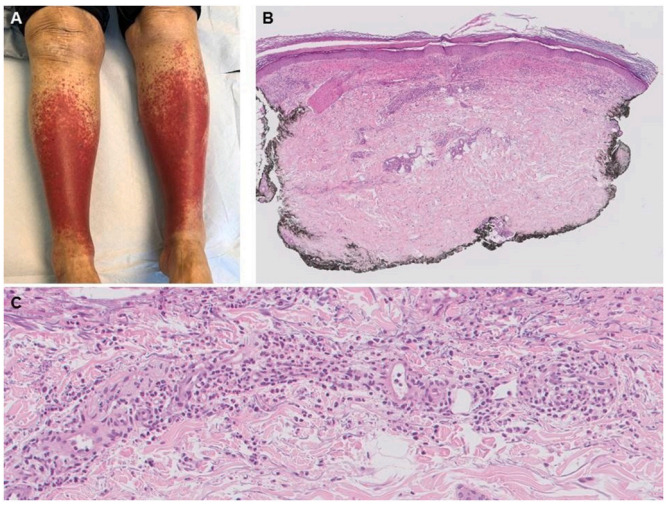

Fig. 1. A. Dermatologic examination. Symmetrically distributed purpuric macules and papules located on the lower legs. **B, C.** Histopathological examination (H&E stain). Sections show a perivascular inflammatory infiltrate predominantly composed of neutrophils (black arrow), fibrinoid necrosis (white arrow) and erythrocyte extravasation (red arrow). Magnification at × 10 (B), magnification at × 40 (C). (For interpretation of the references to colour in this figure legend, the reader is referred to the Web version of this article.)

superficial or deep vein thrombosis. Histopathological examination of a biopsy of a palpable purpuric lesion revealed a perivascular infiltrate predominantly composed of lymphocytes and neutrophils and extravasation of red blood cells in the dermis, with fibrinoid necrosis of small vessels and leukocytoclasia (Fig. 1B and C, 2). Direct immunofluorescence on skin biopsy of a non-palpable lesion showed linear and granular deposition of IgM within small vessels. A diagnosis of cutaneous small-vessel vasculitis (leukocytoclastic vasculitis) was made. The patient was started on oral prednisone 20 mg daily, tapered over 14 days, with complete clinical resolution of the skin lesions.

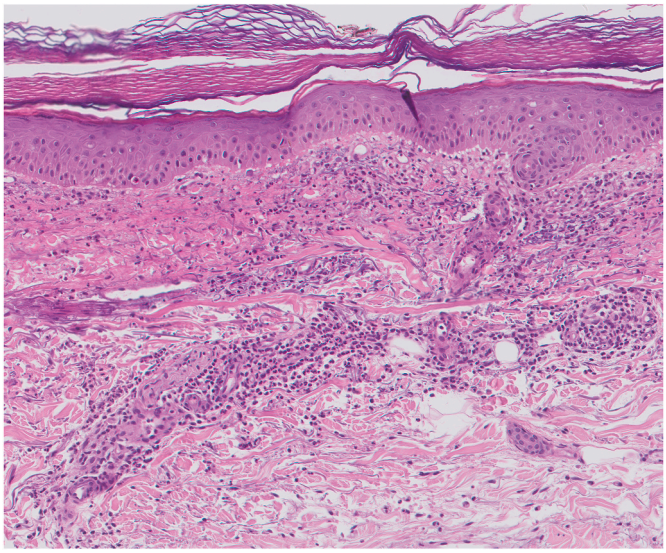

Fig. 2. Histopathological examination (H&E stain x 20). Section shows heavy neutrophilic infiltration, a few lymphocytes, and occasional eosinophils around superficial vessels (black arrow). There is also extravasation of red blood cells in the dermis (red arrow), fibrinoid necrosis of small vessels and leukocytoclasia (white arrow). (For interpretation of the references to colour in this figure legend, the reader is referred to the Web version of this article.)

3. Discussion

The term leukocytoclastic vasculitis (LCV) refers to the pathologic hallmark of small-vessel vasculitis, namely fragmentation of nuclei of neutrophils (leukocytoclasia, also referred to as "nuclear dust") that compose the inflammatory infiltrate in the wall of arterioles, capillaries and postcapillary venules; associated histopathological features include extravasated red blood cells and fibrinoid necrosis of the vessel walls [3,4].

Histological features of LCV can be found in: ANCA-associated vasculitis, immune complex vasculitis, such as cryoglobulinemic vasculitis, IgA-vasculitis (Henoch–Schoenlein purpura), hypocomplementemic urticarial vasculitis (anti-C1q vasculitis) and IgM/IgG immune complex vasculitis (formerly known as hypersensitivity vasculitis), vasculitis associated with systemic diseases (e.g., rheumatoid arthritis, systemic lupus erythematosus and sarcoidosis) and vasculitis secondary to infections, medications, sepsis or cancer [3,4].

Vasculitis precipitation or exacerbation has been reported secondary to different vaccines such as the influenza virus, hepatitis A/B virus, bacillus Calmette-Guerin, human papillomavirus and rotavirus [5–7]. However, LCV associated with COVID-19 vaccine has been very rarely reported to the best of our knowledge, despite the high number of individuals who already underwent this vaccination (Table 1).

The typical clinical presentation of cutaneous LCV consists of symmetrically distributed, non-blanchable purpuric papules, mostly located on the lower legs or on dependent areas. Other clinical presentations of LCV may include ulcers, pustules, and vesicles [4,8]. Cutaneous LCV may be accompanied by systemic symptoms such as fever, malaise or arthralgias and, in less than half of the patients, by vasculitis affecting other organs, mainly the kidneys or the gastrointestinal tract [8]. A dermatologic addendum to Chapel Hill Consensus Conference nomenclature of vasculitides recognizes that LCV may represent the cutaneous manifestation of systemic vasculitis, a skin-limited or skin-dominant expression or variant of a systemic vasculitis, or a single-organ vasculitis that differs from recognized systemic vasculitides [3].

In our patient, complete physical examination and serum biochemistry did not show evidence of extracutaneous involvement, thus supporting the overall safety of COVID-19 vaccination despite the apparently alarming clinical presentation.

The exact pathogenesis of vaccination-associated leukocytoclastic vasculitis has yet to be determined, but SARS-CoV-2 vaccine might result in the activation of autoreactive B/T cells, antibody formation, and immune complex deposition within small vessels, leading to activation of the complement system and recruitment of leukocytes [4,6,7,9,10]. The responsible particle as an antigen for such reactions is unknown, however inflammatory response to vaccine component encoding SARS-CoV-2 spike glycoprotein, targeting endothelium and resulting in small-vessel vasculitis, could be hypothesized [11–13].

Our report adds to the cutaneous adverse events of COVID-19 vaccination, highlighting that leukocytoclastic vasculitis might be a rare, skin-limited adverse reaction to SARS-CoV-2 vaccination.

Author statement

Fiorillo G: conceptualization, literature review, writing, reviewing and editing of the final manuscript. Pancetti S: histopathological analysis, acquisition of pathology results, data collection. Cortese A: investigations, literature review, writing and editing. Toso F: investigations, formal analysis, data collection and reviewing. Manara S: histopathological analysis, supervision, reviewing of the final manuscript. Costanzo A: supervision, contribution to the pathogenesis, reviewing of the final manuscript. Borroni R: conceptualization, methodology, supervision, reviewing and editing of the final manuscript. All authors approved the final manuscript.

Table 1
Summary of the so far published cases of LCV associated with COVID-19 vaccines.

Case	Age, Sex	Comorbidities	Vaccine	Time to onset	Systemic involvement	DIF	Treatment
Sandhu et Al [13].	55, F	No	*Vaxzevria (AstraZeneca):* 1st *dose*	5 days	No	Negative	Oral prednisolone @0.5 mg/kg/day, tapered over 2 weeks
	48, M	Hypertension	*Vaxzevria (AstraZeneca): 2nd* dose	2 days	No	Negative	Oral prednisolone @0.5 mg/kg/day, tapered over 2 weeks
Cohen et Al [6].	46, F	Psoriasis, psoriatic arthritis, irritable bowel syndrome	Comirnaty (Pfizer-BioNTech): 1st and 2nd dose	2 days	No	Not available	Topical steroids and a prednisone taper
Larson et Al [14].	83, F	No	Comirnaty (Pfizer-BioNTech): 2nd dose	5 days	Elevated levels of CRP, ESR and RF, along with hypocomplementemia and detection of cryoglobulin	Fibrinogen	Oral antibiotics and topical steroids
Bostan et Al [7].	33, M	No	Inactivated COVID-19 vaccine: 1st dose	3 days	No	IgA	Topical mometasone furoate twice daily
Kar et Al [11].	46, F	No	Covaxin (Bharat Biotech): 1st dose	5 days	No	Not available	Leg elevation, rest, and antihistamines for 15 days
Bencharattanaphakhi et Al [12].	23, F	No	CoronaVac (Sinovac): 1st dose	36 h	No	C3 and fibrinogen	2 doses of intramuscular and 4 doses of intravenous dexamethasone (4 mg every 8 h) followed by oral prednisolone (10 mg twice a day)
	26, F	No	CoronaVac (Sinovac): 1st dose	4 h	No	IgA, IgM and C3	2 doses of intramuscular and 4 doses of intravenous dexamethasone (4 mg every 8 h) followed by oral colchicine (0.6 mg twice a day) and naproxen (250 mg twice a day) for 4 weeks

M: Male; F: Female; DIF: Direct immunofluorescence; CRP: C-reactive protein; ESR: Erythrocyte sedimentation rate; RF: Rheumatoid factor.

Financial support

This research did not receive any specific grant from funding agencies in the public, commercial, or not-for-profit sectors.

Declarations of competing interest

None.

References

[1] A.E. Rosenblatt, S.L. Stein, Cutaneous reactions to vaccinations, Clin. Dermatol. 33 (3) (2015 May-Jun) 327–332, https://doi.org/10.1016/j.clindermatol.2014.12.009. Epub 2014 Dec 8. PMID: 25889134.

[2] D.E. McMahon, C.L. Kovarik, W. Damsky, M. Rosenbach, J.B. Lipoff, A. Tyagi, G. Chamberlin, R. Fathy, R.M. Nazarian, S.R. Desai, H.W. Lim, B.H. Thiers, G. J. Hruza, L.E. French, K. Blumenthal, L.P. Fox, E.E. Freeman, Clinical and pathologic correlation of cutaneous COVID-19 vaccine reactions including V-REPP: a registry based study, J. Am. Acad. Dermatol. –9622 (21) (2021 Sep 10) S0190, https://doi.org/10.1016/j.jaad.2021.09.002, 02442-7 Epub ahead of print. PMID: 34517079; PMCID: PMC8431833.

[3] P. Fraticelli, D. Benfaremo, A. Gabrielli, Diagnosis and management of leukocytoclastic vasculitis, Intern. Emerg. Med. 16 (4) (2021 Jun) 831–841, https://doi.org/10.1007/s11739-021-02688-x. Epub 2021 Mar 13. PMID: 33713282; PMCID: PMC8195763.

[4] F. Iraji, H. Galehdari, A.H. Siadat, S. Bokaei Jazi, Cutaneous leukocytoclastic vasculitis secondary to COVID-19 infection: a case report, Clin. Case Rep. 9 (2) (2020 Dec 18) 830–834, https://doi.org/10.1002/ccr3.3596. PMID: 33598253; PMCID: PMC7869328.

[5] C. Bonetto, F. Trotta, P. Felicetti, G.S. Alarcón, C. Santuccio, N.S. Bachtiar, Y. Brauchli Pernus, R. Chandler, G. Girolomoni, R.D. Hadden, M. Kucuku, S. Ozen, B. Pahud, K. Top, F. Varricchio, R.P. Wise, G. Zanoni, S. Živković, J. Bonhoeffer, Brighton Collaboration Vasculitis Working Group, Vasculitis as an adverse event following immunization - systematic literature review, Vaccine 34 (51) (2016 Dec 12) 6641–6651, https://doi.org/10.1016/j.vaccine.2015.09.026. Epub 2015 Sep 21. PMID: 26398442.

[6] S.R. Cohen, L. Prussick, J.S. Kahn, D.X. Gao, A. Radfar, D. Rosmarin, Leukocytoclastic vasculitis flare following the COVID-19 vaccine, Int. J. Dermatol. 60 (8) (2021 Aug) 1032–1033, https://doi.org/10.1111/ijd.15623. Epub 2021 Apr 30. PMID: 33928638; PMCID: PMC8239799.

[7] E. Bostan, D. Gulseren, O. Gokoz, New-onset leukocytoclastic vasculitis after COVID-19 vaccine, Int. J. Dermatol. (2021 Jul 9), https://doi.org/10.1111/ijd.15777. Epub ahead of print. PMID: 34241833.

[8] M. Camprodon Gómez, C. González-Cruz, B. Ferrer, M.J. Barberá, Leucocytoclastic vasculitis in a patient with COVID-19 with positive SARS-CoV-2 PCR in skin biopsy, BMJ Case Rep. 13 (10) (2020 Oct 29), e238039, https://doi.org/10.1136/bcr-2020-238039. PMID: 33122236; PMCID: PMC7597471.

[9] V. Doktor, A. Hadi, A. Hadi, R. Phelps, H. Goodheart, Erythema elevatum diutinum: a case report and review of literature, Int. J. Dermatol. 58 (4) (2019 Apr) 408–415, https://doi.org/10.1111/ijd.14169. Epub 2018 Aug 3. PMID: 30074624.

[10] D. Baigrie, P. Bansal, A. Goyal, J.S. Crane, Leukocytoclastic Vasculitis, in: StatPearls [Internet]. Treasure Island (FL), StatPearls Publishing, 2021 Aug 11, 2021 Jan–. PMID: 29489227.

[11] B.R. Kar, B.S. Singh, L. Mohapatra, I. Agrawal, Cutaneous small-vessel vasculitis following COVID-19 vaccine, J. Cosmet. Dermatol. 20 (11) (2021 Nov) 3382–3383, https://doi.org/10.1111/jocd.14452. Epub 2021 Sep 16. PMID: 34529877.

[12] R. Bencharattanaphakhi, P. Rerknimitr, Sinovac COVID-19 vaccine-induced cutaneous leukocytoclastic vasculitis, JAAD Case Rep. 18 (2021 Dec) 1–3, https://doi.org/10.1016/j.jdcr.2021.10.002. Epub 2021 Oct 9. PMID: 34660867; PMCID: PMC8501511.

[13] S. Sandhu, A. Bhatnagar, H. Kumar, P.K. Dixit, G. Paliwal, D.K. Suhag, C. Patil, D. Mitra, Leukocytoclastic vasculitis as a cutaneous manifestation of ChAdOx1 nCoV-19 corona virus vaccine (recombinant), Dermatol. Ther. 34 (6) (2021 Nov), e15141, https://doi.org/10.1111/dth.15141. Epub 2021 Oct 5. PMID: 34546608; PMCID: PMC8646583.

[14] V. Larson, R. Seidenberg, A. Caplan, N.K. Brinster, S.A. Meehan, R.H. Kim, Clinical and histopathological spectrum of delayed adverse cutaneous reactions following COVID-19 vaccination, J. Cutan. Pathol. 49 (1) (2022 Jan) 34–41, https://doi.org/10.1111/cup.14104. Epub 2021 Aug 8. PMID: 34292611; PMCID: PMC8444807.