PROC (BAYL UNIV MED CENT)
2021;34(6):705–707
Copyright © 2021 Baylor University Medical Center
https://doi.org/10.1080/08998280.2021.1936854

Taylor & Francis
Taylor & Francis Group

Isolated ovarian vein thrombosis in COVID-19 infection

Udhayvir Singh Grewal, MD[a], Sreecharan Mavuram, MD[b], Nancy Bai, MD[c], and Poornima Ramadas, MD[b]

[a]Department of Internal Medicine, Louisiana State University Health Sciences Center, Shreveport, Louisiana; [b]Department of Hematology and Oncology, Louisiana State University Health Sciences Center, Shreveport, Louisiana; [c]Department of Radiology, Louisiana State University Health Sciences Center, Shreveport, Louisiana

ABSTRACT

COVID-19 (coronavirus disease-19) is associated with an increased risk for thrombosis due to endothelial dysfunction and hyperactivation of the immune system induced by the virus. Most cases of venous thromboembolism associated with COVID-19 are either pulmonary emboli or deep vein thromboses. Ovarian vein thrombosis is a rare condition most commonly seen in the postpartum period. This report describes a case of COVID-19–associated ovarian vein thrombosis in a nonpregnant woman with no evidence of underlying inherited coagulopathy.

KEYWORDS COVID-19; COVID-19–associated coagulopathy; ovarian vein thrombosis

Most patients infected with the coronavirus disease-19 (COVID-19) present with pulmonary complications, the most severe form being acute respiratory distress syndrome.[1] However, there has been increasing recognition of the thrombotic complications associated with the virus. COVID-19 induces a hyperinflammatory state, which causes a rise in the levels of acute-phase reactants and results in abnormal activation of the immune system, ultimately contributing to COVID-19–related hypercoagulability.[2] Venous thromboembolism (VTE) occurs in 23% of patients with COVID-19 in the intensive care unit and also occurs in other hospitalized patients. This report describes a case of COVID-19–associated ovarian vein thrombosis (OVT).

CASE PRESENTATION

A 44-year-old woman with known hypertension, asthma, hypothyroidism, obesity (body mass index 44 kg/m^2), and uterine fibroids with hysterectomy presented to the emergency department with dyspnea, cough, fever with chills, vomiting, and diarrhea for 5 days and was diagnosed with COVID-19 infection. She was hypoxic, was admitted to the hospital, and was given enoxaparin and dexamethasone. She also had methicillin-sensitive *Staphylococcus aureus* bacteremia and was started on intravenous cefazolin. Her maximum D-dimer level was 897 ng/mL. She was weaned off supplemental oxygen and was discharged home within 7 days.

Five days after discharge, she developed severe right-sided throbbing abdominal pain. Computed tomography (CT) of the abdomen and pelvis showed right-sided partial OVT *(Figure 1)*. Ovarian Doppler ultrasound showed normal flow. She was a nonsmoker with no prior history of thromboembolism, even during seven previous pregnancies. Testing was normal for antiphospholipid antibodies with lupus anticoagulant, protein C, protein S, and antithrombin III levels. Factor V Leiden and prothrombin gene mutation tests were negative. Testing for *JAK2* V617 mutation, *JAK2* exon 12 mutation, and flow cytometry for paroxysmal nocturnal hemoglobinuria were also unremarkable. The patient's unprovoked isolated gonadal vein thrombosis was assumed to have resulted from COVID-19–associated coagulopathy.

DISCUSSION

OVT is a rare condition that, apart from the postpartum period, has been associated with a number of systemic conditions including malignancy, pelvic inflammatory disease, and inflammatory bowel disease, as well as with abdominal or pelvic surgery.[3,4] Most patients with OVT present with pelvic pain, fever, right-sided abdominal pain, or flank pain. Because of the rarity of OVT and its nonspecific clinical presentation, a high index of suspicion aids in establishing a

Corresponding author: Poornima Ramadas, MD, Feist Weiller Cancer Center, 1501 Kings Highway, Shreveport, LA 71103 (e-mail: pramad@lsuhsc.edu)
The authors report no conflicts of interest. The patient gave permission for publication of this report.
Received March 7, 2021; Revised May 24, 2021; Accepted May 24, 2021.

diagnosis. Patients with OVT commonly have an underlying prothrombotic condition.[5] COVID-19 is a known risk factor for thrombosis. COVID-19–associated coagulopathy is related to endothelial dysfunction and hyperactivation of the immune system induced by the virus. *Figure 2* summarizes the various mechanisms involved in the pathogenesis of COVID-19–associated coagulopathy.[6]

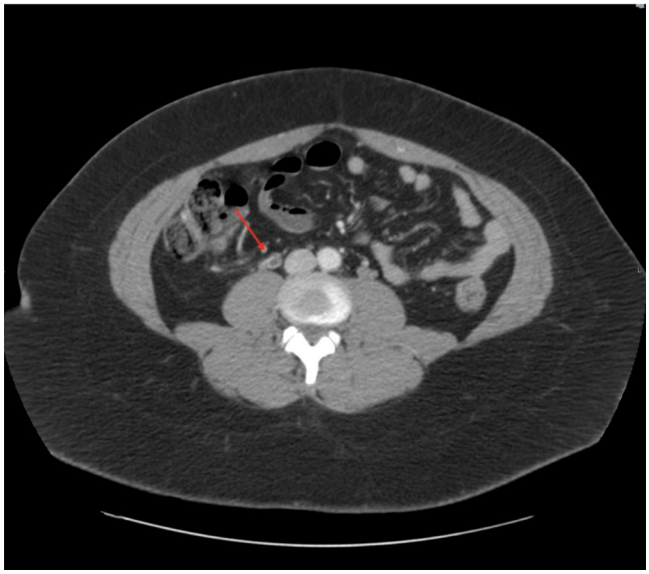

Figure 1. CT of the abdomen and pelvis with contrast showing a filling defect in the right-sided gonadal vein suggestive of ovarian vein thrombosis (red arrow).

To date, two cases of COVID-19–related OVT have been reported. Mohammadi et al reported the case of a 26-year-old woman who was 8 weeks pregnant and had COVID-19 infection who presented with worsening abdominal pain, nausea, and vomiting. She had evidence of right OVT on magnetic resonance imaging. Since pregnancy is the most common risk factor for OVT, this could have been the provoking factor in this patient. In their case description, the authors did not mention initiation of anticoagulation, and there was also no comment on follow-up.[7] Veyseh et al reported a 54-year-old postmenopausal woman with no significant past medical history with COVID-19 infection who presented with sudden onset of sharp abdominal pain. D-dimer was markedly elevated, at >3800 ng/mL, and the patient underwent a CT, which revealed left OVT. CT angiogram of the chest revealed a stable pulmonary embolism. An extensive workup including lupus anticoagulant, protein C, protein S, and antithrombin III was normal. The patient's OVT and pulmonary embolism were determined to be secondary to COVID-19 infection. She was started on 1 mg/kg enoxaparin and eventually transitioned to apixaban for 3 months. The thrombus resolved at 1-month follow-up.[8]

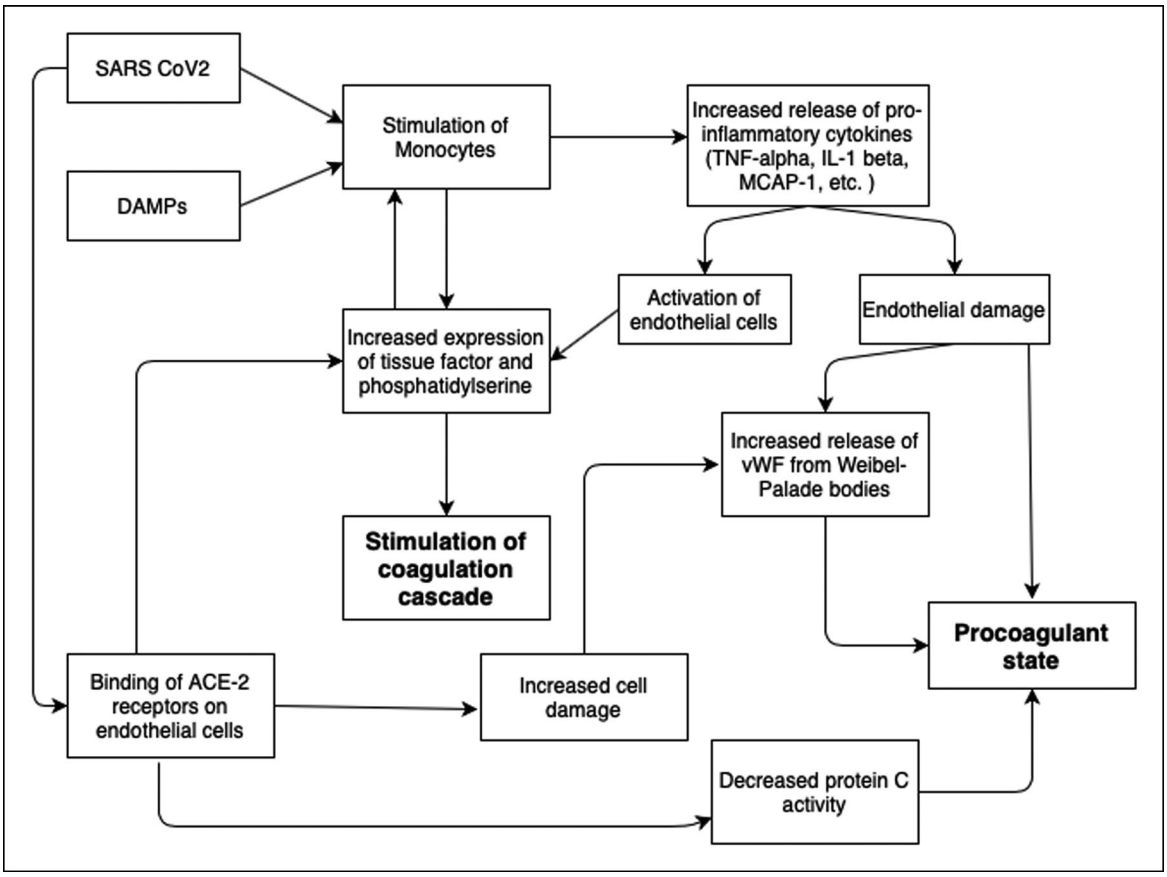

Figure 2. Pathophysiological mechanisms underlying COVID-19–associated coagulopathy. ACE-2 indicates angiotensin-converting enzyme 2; DAMPs, damage-associated molecular patterns; IL-1, interleukin-1; MCAP-1, monocyte chemoattractant protein; SARS CoV2, severe acute respiratory syndrome coronavirus 2; TNF-alpha, tumor necrosis factor-alpha; vWF, von-Willebrand factor.

Although treatments used to manage OVT range across the spectrum of treatments for VTE, there are no established guidelines for management.[9] Reports of spontaneous resolution of OVT have also questioned the need for anticoagulation in these patients.[10] The risk of pulmonary embolism and VTE recurrence in patients with OVT is poorly defined. Since there are no clear guidelines on which patients with OVT should receive anticoagulation, our patient was not initiated on it. At 3-month follow-up, she noted significant improvement in her abdominal pain, which was considered to be due to the thrombus's ongoing resolution.

Most cases of VTE in patients with COVID-19 are pulmonary embolisms or DVTs.[11] The current case is unique because the patient was not critically ill and presented with thrombosis at an unusual site with no other sites of thrombosis. There were no obvious triggers for OVT, and her thrombophilia workup was unremarkable. This case increases attention to the clinical possibility of unusual sites of thrombosis in patients with COVID-19 infection. A high index of suspicion, early diagnosis, and prompt initiation of therapeutic interventions facilitates overall recovery and prevents serious complications.

ORCID

Udhayvir Singh Grewal http://orcid.org/0000-0002-9638-3629

1. Gibson PG, Qin L, Puah SH. COVID-19 acute respiratory distress syndrome (ARDS): clinical features and differences from typical pre-COVID-19 ARDS. *Med J Aust*. 2020;213(2):54–56.e1. doi:10.5694/mja2.50674.
2. Lazzaroni MG, Piantoni S, Masneri S, et al. Coagulation dysfunction in COVID-19: the interplay between inflammation, viral infection and the coagulation system. *Blood Rev*. 2021; 46:100745. doi:10.1016/j.blre.2020.100745.
3. Jacoby WT, Cohan RH, Baker ME, Leder RA, Nadel SN, Dunnick NR. Ovarian vein thrombosis in oncology patients: CT detection and clinical significance. *Am J Roentgenol*. 1990;155(2):291–294. doi:10.2214/ajr.155.2.2115254.
4. Harris K, Mehta S, Iskhakov E, et al. Ovarian vein thrombosis in the nonpregnant woman: an overlooked diagnosis. *Ther Adv Hematol*. 2012;3(5):325–328. doi:10.1177/2040620712450887.
5. Ortín X, Ugarriza A, Espax RM, et al. Postpartum ovarian vein thrombosis. *Thromb Haemost*. 2005;93:1004–1005.
6. Colling ME, Kanthi Y. COVID-19-associated coagulopathy: An exploration of mechanisms. *Vasc Med*. 2020;25(5):471–478. doi:10.1177/1358863X20932640.
7. Mohammadi S, Abouzaripour M, Hesam Shariati N, Hesam Shariati MB. Ovarian vein thrombosis after coronavirus disease (COVID-19) infection in a pregnant woman: case report. *J Thromb Thrombol*. 2020;50(3):604–607. doi:10.1007/s11239-020-02177-6.
8. Veyseh M, Pophali P, Jayarangaiah A, Kumar A. Left gonadal vein thrombosis in a patient with COVID-19-associated coagulopathy. *BMJ Case Rep*. 2020;13(9):e236786. doi:10.1136/bcr-2020-236786.
9. Plastini T, Henry D, Dunleavy K. Ovarian vein thrombus: to treat or not to treat? *Blood Adv*. 2017;1(15):1120–1123. doi:10.1182/bloodadvances.2017006577.
10. Wysokinska EM, Hodge D, McBane RD 2nd. Ovarian vein thrombosis: incidence of recurrent venous thromboembolism and survival. *Thromb Haemost*. 2006;96(08):126–131. doi:10.1160/TH06-03-0151.
11. Porfidia A, Valeriani E, Pola R, Porreca E, Rutjes AWS, Di Nisio M. Venous thromboembolism in patients with COVID-19: systematic review and meta-analysis. *Thromb Res*. 2020;196:67–74. doi:10.1016/j.thromres.2020.08.020.