Since January 2020 Elsevier has created a COVID-19 resource centre with free information in English and Mandarin on the novel coronavirus COVID-19. The COVID-19 resource centre is hosted on Elsevier Connect, the company's public news and information website.

Elsevier hereby grants permission to make all its COVID-19-related research that is available on the COVID-19 resource centre - including this research content - immediately available in PubMed Central and other publicly funded repositories, such as the WHO COVID database with rights for unrestricted research re-use and analyses in any form or by any means with acknowledgement of the original source. These permissions are granted for free by Elsevier for as long as the COVID-19 resource centre remains active.

Clinics and Research in Hepatology and Gastroenterology 46 (2022) 101818

Available online at
ScienceDirect
www.sciencedirect.com

Elsevier Masson France
EM|consulte
www.em-consulte.com

REVIEW

Gastrointestinal, hepatic and pancreatic manifestations of COVID-19 in children

Francesco Pegoraro[a], **Sandra Trapani**[a], **Giuseppe Indolfi**[b,*]

[a] *Department of Health Science, Meyer Children's Hospital, Firenze, Italy*
[b] *NEUROFARBA Department, Meyer Children's Hospital, Firenze, Italy*

Available online 2 October 2021

KEYWORDS
Coronavirus-19;
Gastrointestinal;
Liver;
Pancreas;
Children

Abstract
Severe acute respiratory syndrome coronavirus-2 (SARS-CoV-2) is a well-established respiratory tract pathogen. Recent studies in adults and children have shown an increasing number of patients reporting gastrointestinal manifestations of SARS-CoV-2 infection such as diarrhoea, nausea, vomiting and abdominal pain. SARS-CoV-2 RNA can be detected in faeces for an extended period, even after respiratory samples have tested negative and patients are asymptomatic. However, faecal-oral transmission has not yet been proven. In this article, the latest evidence on gastrointestinal, hepato-biliary, and pancreatic manifestations in children with coronavirus disease-19 and multisystem inflammatory syndrome will be analysed.
© 2021 Elsevier Masson SAS. All rights reserved.

Introduction

Since the outbreak of the coronavirus disease-19 (COVID-19) pandemic, adults and children have shown different patterns of disease involvement. Severe acute respiratory syndrome coronavirus-2 (SARS-CoV-2) infection is less severe in children, ranging from an asymptomatic or mild disease course to some rare, life-threatening conditions [1,2]. Fever and respiratory symptoms are the main clinical manifestations in children. Gastrointestinal (GI) involvement has been described to different extents including diarrhoea, nausea, vomiting and abdominal pain. GI involvement seems extremely relevant in the novel multisystem inflammatory syndrome in children (MIS-C) that follows SARS-CoV-2 infection [3–5]. SARS-CoV-2 RNA can also be detected in faeces by real-time polymerase chain reaction (RT-PCR), but the role of the GI shedding in disease transmission is not clear yet [6]. Moreover, it is not unusual among hospitalised children to detect abnormal liver function tests, and rare cases of severe abdominal organ damage have been described.

Herein, we provide a narrative review of the clinical features of gastrointestinal, hepatic and pancreatic involvement of SARS-CoV-2 infection in children. Furthermore, some unanswered issues, such as the GI involvement in severe disease phenotypes, the role of faecal shedding in SARS-CoV-2 transmission and the significance of laboratory abnormalities are explored.

* Correspondence to: NEUROFARBA Department, Meyer Children's Hospital, Viale Pieraccini 24, Florence 50139, Italy.
E-mail address: giuseppe.indolfi@unifi.it (G. Indolfi).

https://doi.org/10.1016/j.clinre.2021.101818
2210-7401/© 2021 Elsevier Masson SAS. All rights reserved.

Methods

We did a comprehensive narrative literature review using PubMed, EMBASE, and LILACS to identify key studies on gastrointestinal, hepatic, or pancreatic involvement in children with confirmed diagnosis of COVID-19 in the following areas: epidemiology, transmission, natural history, diagnosis, and treatment. A formal, quantitative systematic review was not considered appropriate for this initial comprehensive review. We searched for English language publications with the use of broad search terms: ("COVID-19" OR "SARS-CoV-2" OR "coronavirus") AND ("gastrointestinal symptoms" OR "gut" OR "diarrhoea" OR "vomiting" OR "abdominal"), "liver", or "pancreas" AND ("child" OR "children") from January 2020 to July 2021. The age limit "birth—18 years" was applied. We included randomised controlled trials, observational studies, retrospective studies, meta-analyses, review articles, editorials, and case reports. Animal studies and in-vitro studies were excluded. We included additional studies after evaluating the reference list of the included papers. The final list of eligible studies was based on those of direct relevance to the key topics of this review focusing on: (a) GI manifestations children with COVID-19; (b) hepatic manifestations in children with COVID-19; (c) pancreatic manifestations in children with COVID-19; (d) clinical characteristics of children with MIS-C; (e) viral shedding via the GI tract in children and adults; (f) pathogenesis of SARS-CoV-2 infection; (g) COVID-19 in children with GI, liver, and pancreatic chronic disease; (h) impact of COVID-19 pandemic on paediatric gastroenterology practice. In absence of strong evidence from paediatric studies, also studies including adult patients were included. Titles and abstracts were screened to identify potentially eligible articles. We finally included in the references full-text articles.

Pathogenesis

SARS-CoV-2 infects the cell through the S protein, which binds to membrane receptors and mediates the fusion between the virus and the membrane. Among these receptors, a crucial role is held by the cellular angiotensin converting enzyme 2 (ACE2), which has a higher affinity for SARS-CoV-2 than for other coronaviruses. The transmembrane serine protease 2 (TMPRSS2) is an additional key protein for SARS-CoV-2 infection and the co-expression of ACE2 and TMPRSS2 is considered critical for viral entry (Fig. 1). ACE2 and TMPRSS2 receptors are co-expressed in the gut, from the oesophagus through the colon, especially in epithelial cells from the small intestine, making it highly susceptible to SARS-CoV-2 infection [7].

The putative mechanisms of SARS-CoV-2 induced gut damage are multiple (Fig. 1). A direct injury to the infected enterocytes could be secondary to ACE2-mediated mucosal inflammation. Moreover, new virions are assembled and then released to the GI tract after viral entry, which constitutes the basis for viral RNA shedding in faeces [8]. Systemic inflammation with cytokine storm induced by SARS-CoV-2 infection can additionally contribute to enteral damage. A pilot study on 15 COVID-19 adults showed persistent alterations in the faecal microbiome, compared with controls. The alterations were associated with faecal levels of SARS-CoV-2 and COVID-19 severity [9]. A potential impact of microbiome dysbiosis was also reported in the absence of GI symptoms [10]. The GI flora is known to affect the respiratory tract through the common mucosal immune system, and respiratory tract dysbiosis can also impact the digestive tract, via what is referred to as the "gut-lung axis" [11,12].

To date, no endoscopic and pathologic studies of the digestive tract have been conducted in children with COVID-19. Few endoscopic studies have been done in adults with GI symptoms, showing no mucosal harm in the GI tract. Only an occasional lymphocyte infiltration was found in the oesophageal tract, and an infiltration of plasma cells and lymphocytes with interstitial oedema of the lamina propria in stomach, duodenum, and rectum biopsies [8]. However, the detection of SARS-CoV-2 in endoscopic specimens has been associated with more severe GI symptoms in adults [13]. ACE2 is expressed in more than 50% of cholangiocytes and in a small proportion of hepatocytes [14]. A potential direct damage of SARS-CoV-2 on the liver can be inferred from active viral replication [15], considering also that viral RNA and replicative intermediates were detected in liver tissues [16]. Additional pathomechanisms include immune—mediated liver damage due to systemic inflammation, hypoxia secondary to lung dysfunction, coagulopathy [17] and drug-induced toxicity (Fig. 1). Data on pathological alterations in the liver of COVID-19 patients are scarce and only from adults. Autopsies of deceased adults revealed microvascular and thromboembolic damage, microvescicular steatosis and features of aberrant regeneration.

In the pancreas, ACE2 is expressed in both exocrine glands and islets, [18] and therefore a direct virus-mediated injury can be hypothesised. Systemic inflammation and drug-induced toxicity could contribute to pancreatic damage in severe cases. Pathology data on pancreatic injury are limited.

Gastro-intestinal tract

Since the publication of the first case series, GI involvement of SARS-CoV-2 infection has been described in both adults [19] and children. [1] A summary of the main features of GI involvement in adults is reported in Fig. 2A. In a metanalysis of studies, including 4243 adults from 60 studies, gastrointestinal symptoms were detected in 17.6% of patients [20] and a similar rate was reported by an early systematic review in children [21]. Data from larger paediatric cohorts recently confirmed such findings [1,2,22—31]. Diarrhoea is reported in two to 33% of patients, whereas nausea and/or vomiting is reported at a rate ranging from five to 35% (Table 1). The presence of abdominal pain - though not always reported - ranges from six to 35% (Table 1). In the paediatric COVID-19 U.S. Case Registry [32] - based on more than 6000 cases - vomiting, nausea, diarrhoea and abdominal pain are reported in 12, nine, 11 and 10% of patients, respectively. In two recent metanalysis of paediatric cases involving 55 (4369 patients) [33] and 19 (3907 patients) [34] studies, the pooled prevalence of diarrhoea was 19 and 10%, that of nausea or vomiting was 19 and seven percent, and that of abdominal pain were 20 and four percent, respectively.

Despite increasing evidence of GI involvement, our understanding of the specific features of such symptoms remains weak. Only few studies describe the onset and

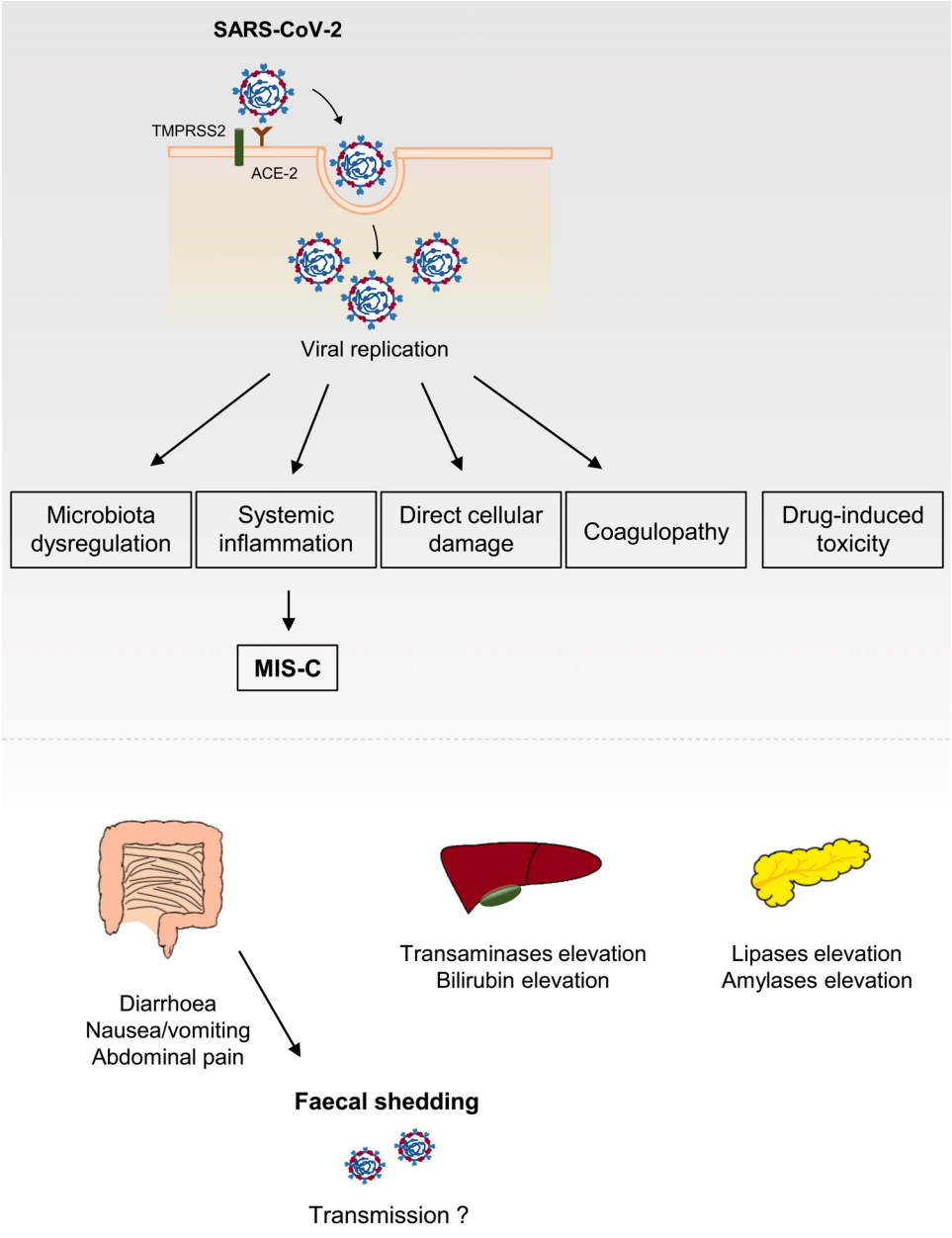

Fig. 1 Visual summary of gastrointestinal, hepatic, and pancreatic manifestations of SARS-CoV-2 in children. Upper panel: pathogenesis of SARS-CoV-2 infection and mechanisms of damage. Lower panel: clinical manifestations of COVID-19 involving the gastrointestinal tract, the liver, and the pancreas.

duration of diarrhoea in children, and stool composition is seldom reported in detail. Moreover, a confounding role of antibiotics was possible when diarrhoea developed during the disease, mostly at the beginning of the pandemic. At that time, whether to screen for SARS-CoV-2 children with isolated GI symptoms was a clinical dilemma. In adults, it was reported that diarrhoea could precede the onset of fever or respiratory symptoms [35]. Early reports in children suggested that diarrhoea usually begins 1-8 days after the disease onset although some patients presented with watery diarrhoea as the first symptom [36]. These findings have been confirmed in a Spanish cohort, where 25 out of 101 patients presented GI symptoms in absence of respiratory symptoms, and GI symptoms were the first disease manifestation in 14% of cases [37].

Vomiting poses a diagnostic challenge as well. The frequency of vomiting episodes has never been described, and it is therefore difficult to define *a priori* how many episodes are needed to rise the clinical suspicion of SARS-CoV-2 infection.

There is little information on other GI symptoms in children. As stated above, data on abdominal pain are reported only in a minority of studies and the characteristics of the pain are rarely documented. Another symptom described in adults is the loss of appetite, which seems to be a very frequent GI manifestation [38]. However, in paediatric cohorts,

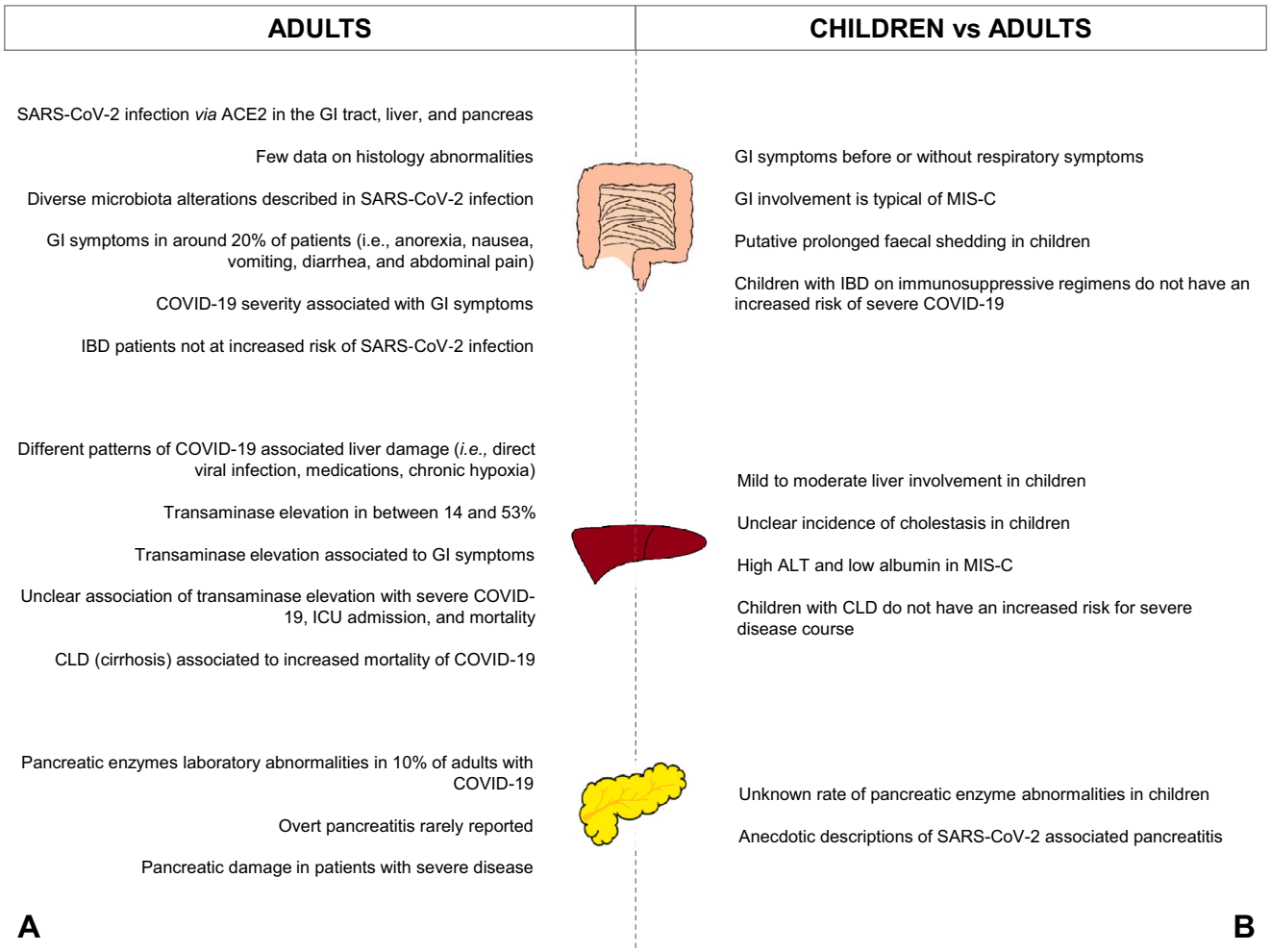

Fig. 2 GI involvement in adults with COVID-19 (A) and differences between adult and paediatric COVID-19 related GI, liver, and pancreatic involvement (B).

Table 1 Proportions of patients presenting with gastro-intestinal involvement among children with SARS-CoV-2. Only studies including 100 or more children are included in the table.

	Included patients, n	Diarrhoea, n (%)	Vomiting, n (%)	Nausea, n (%)	Abdominal pain, n (%)
Swann et al, BMJ 2020	651	98 (15)	179 (32)		107 (16)
Bayesheva et al, Paediatr Int Child Health 2020	650	13 (2)	NR	NR	NR
Götzinger et al, Lancet Child Adolesc Health 2020	582	128 (22)			
Antúnez-Montes et al, Pediatr Infect Dis J 2021	409	101 (25)			
Bialek et al, MMWR 2020	291	37 (13)	31 (11)		17 (6)
Cura Yayla et al, Balkan Med J 2020	220	17 (8)	9 (4)	NR	NR
Lu et al, N Engl J Med 2020	171	15 (9)	11 (6)	NR	NR
Parri et al, Pediatrics 2020	170	19 (11)	24 (14)	12 (7)	13 (8)
Garazzino et al, Euro Surveill 2020	168	22 (13)	9 (5)	NR	NR
van der Zalm et al, Clin Infect Dis 2020	159	22 (14)	18 (11)	NR	NR
Wu et al, JAMA 2020	148	32 (22)		NR	NR
Alsharrah et al, J Med Virol 2020	134	11 (8)			
Giacomet et al, Pediatr Infect Dis J 2020	127	28 (22)	12 (9)	NR	8 (6)
Rabha et al, Rev Paul Pediatr 2020	115	15 (13)	20 (17)		10 (9)
Lu et al, Pediatr Infect Dis J 2020	110	26 (24)			
Gonzalez-Jimenez et al, Pediatr Infect Dis J 2020	101	33 (33)	35 (35)		35 (35)

NR: not reported.

it is not easy to distinguish whether a loss of appetite can be causally correlated to a specific illness, considering the impact on appetite of any disease in children, especially those presenting with fever. Therefore, in our opinion, anorexia should not be considered a GI symptom of COVID-19 in children. Acute appendicitis, phlegmonous ileocolitis, intussusception, pneumatosis intestinalis, protein losing enteropathy, and diffuse mesenteric lymphadenopathy have been reported as anecdotic manifestations of SARS-CoV-2 infection in children [39].

The correlation of GI symptoms with the age of the patients is not clear. In a very large series of 651 children in the UK from Swann *et al* fever and rhinorrhoea were less common whereas nausea, vomiting, and abdominal pain were reported more frequently in older children [2]. Conversely, in a study on 244 children, the clinical phenotype of SARS-CoV-2 infection was compared between children with and without GI involvement, showing that those with GI symptoms presented more frequently with fever and were younger than those without GI involvement [40]. Of note, it has been described in a series of 66 neonates that vomiting or feeding difficulties were — after fever - the most common signs at presentation [41].

A low lymphocyte count at hospital admission has been associated with initial GI involvement and with a higher rate of viral shedding [42]. Similarly, a study comparing COVID-19 patients with and without diarrhoea, showed that not only a reduced lymphocyte count, but also a decrease of gamma-glutamyl transferase (GGT), prealbumin and CD4-T cells might be useful in the diagnosis of GI involvement within SARS-COV-2 infection [43].

Giacomet *et al* first reported that the GI involvement was associated with a more severe phenotype. Interestingly, an association with cardiac impairment was also found [23]. A possible explanation lies in systemic inflammation, which in severe COVID-19 drives damage of both systems. These results conflicted with a previous study reporting an extremely low incidence (2%) of GI symptoms in a cohort of 48 children admitted to the intensive care unit (ICU) [44]. Multiple evidence recently emerged on the association of GI manifestation and disease severity. In a Spanish cohort, children with GI symptoms had higher risk of ICU admission after adjustment for multiple confounding factors [37]. Similarly, in another case series of 74 Spanish children admitted to ICU, more than a half presented with GI involvement [45]. This finding has been recently confirmed by Feldstein *et al* on 577 children and young adults with severe acute COVID-19. Of them, 332 (57.5%) had GI symptoms on presentation [46]. These results are also consistent with findings published in adults [38,47]. Recently, many of the large case series on paediatric COVID-19 confirmed that GI symptoms are significantly associated with a severe course and/or ICU admission [2,25,31]. Only in one of these large series the association of GI symptoms with severe COVID-19 was not confirmed, even though the incidence of GI symptoms in children in the ICU (31%) exceeded that of children not admitted to the ICU (21%) [24]. More specifically, in a recent metanalysis on 55 studies (4369 patients) the presence of diarrhoea was associated with a more severe disease course (OR 3.97), whereas abdominal pain and nausea/vomiting were not associated with disease severity [33].

Overall, it is advisable to consider GI symptoms not only as an indicator of possible SARS-CoV-2 infection, but also as a clinical warning of a severer disease course.

Multisystem inflammatory syndrome in children

MIS-C, which is temporally associated with SARS-CoV-2 infection, is characterized by systemic inflammation, fever and multi-organ dysfunction, including the respiratory tract, the heart, the GI, and the central nervous system [5]. GI symptoms, including abdominal pain, diarrhoea and vomiting are the most frequent presenting features of MIS-C after fever, ranging from 80% to 100% of published cases [3,4,37,46,48—52]. Severe COVID-19 and MIS-C are not always easily distinguishable. Although GI symptoms are far more frequent in MIS-C than in severe COVID-19, when GI involvement is not accompanied by cardiovascular, respiratory, or mucocutaneous involvement, severe COVID-19 should be suspected rather than MIS-C [46].

Patients sometimes present with GI symptoms and fever before the onset of an overt multisystem inflammatory syndrome, thus mimicking viral gastroenteritis or even inflammatory bowel disease [53]. In early reports, MIS-C also mimicked appendicitis and/or peritonitis, requiring in some cases surgical exploration [54]. Mesenteric adenitis and ascites have also been described, implying an overt inflammatory reaction of the gut. The pathomechanisms are unclear but are supposed to be driven by a systemic response rather than a direct viral damage, as SARS-CoV-2 RNA is typically not found in nasal and rectal swabs of children with MIS-C. The lower gut is more commonly involved, but MIS-C can affect any tract of the GI system. The inflammation, which can sometimes lead to wall thickening, responds in most cases to systemic treatments, not requiring surgical intervention except in rare cases of acute obstruction [55].

Faecal shedding

As described above, SARS-CoV-2 virions are assembled in enterocytes and eliminated in faeces. At the beginning of the pandemic, a possible role of faecal shedding in SARS-CoV-2 transmission was hypothesised based on the description of persistently positive rectal swabs in children [6]. Since early reports, it has emerged that SARS-CoV-2 shedding is detectable in faeces longer than in the respiratory tract [56—58]. In a series on 74 children, faecal specimens turned negative five to 23 days after negative conversion in respiratory tract swabs in eight out of 10 tested children [59]. Han *et al* demonstrated that in 11 patients the RNA load in faeces remained high for more than three weeks, whereas that in respiratory tract swab specimens declined [60]. In another series of 9 children, the median duration of SARS-CoV-2 shedding in the nasopharyngeal swabs and the stools was 13 and 43 days, respectively [61]. In some smaller series the duration of faecal specimen positivity after nasal swab turning negative was even longer, ranging from 8 to 25 days [62—64]. A prolonged duration in children, compared to adults was also reported (up to four and one week after discharge, respectively) [65]. In the study form Hua *et al*, faecal specimens were positive in 91.4% (32/35) children, with a prolonged shedding up to 70 days in some cases. Interestingly, a positivity in faecal SARS-CoV-2 detection was not

Table 2 Summary of the studies on SARS-CoV-2 faecal shedding in children.

	Tested patients, n	Positive stool/ rectal swab, n (%)	Duration, days	Comment
Xiong et al, Gut 2020	105	39 (37)	NR	No difference between symptomatic and asymptomatic children
Hua et al, J Med Virol 2020	35	32 (91)	NR (>70 in one child)	51% positive after negative nasal swab
De Ioris et al, J Pediat Infect Dis Soc 2020	22	15 (68)	10 - 14	46% positive at discharge
Han et al, Emerg Infect Dis J 2020	12	11 (96)	>21 in 80%	High viral load in faeces for >3 weeks
Xu et al, Nat Med 2020	10	8 (80)	3—28	All remained positive after negative nasal swab (3—30 days)
Wu et al, Pediatrics 2020	NR	10 (NR)	NR	80% positive after negative nasal swab (5-23 days)
Du et al, J Infect Public Health 2020	10	7 (70)	34 (median)	8-17 days longer than nasal swab
Liu et al, Emerg Microbes Infect 2020	9	8 (89)	28—66	All remained positive after negative nasal swab (14—52 days)
Ma et al, J Microbiol Immunol Infect 2020	27*	6 (NA)	>28 in 3 patients	Longer shedding in children compared to adults
Jiehao et al, Clin Infect Dis 2020	5	6 (83)	18—30	All remained positive after negative nasal swab (11—18 days)
Tan et al, J Clin Virol 2020	4	3 (75)	6—16	
Xing et al, J Microbiol Immunol Infect	3	3 (NA)	6—30	All remained positive after negative nasal swab (8—20 days)
Zhang et al, J Infect 2020	3	3 (NA)	24—31	16—25 days longer than nasal swab
Zhang et al, J Med Virol 2020	3	3 (NA)	29—35	19—24 days longer than nasal swab

NA: not applicable; NR: not reported.
* Include both children and adults.

considered a contraindication to discharge, but no infection was observed in contacts of children with faecal shedding [66].

Both the high rate of positive *RT-PCR* testing in the stool and the long-lasting viral shedding *via* the gastrointestinal tract were further confirmed. In a systematic review based on 69 paediatric cases, 86% of children undergoing stool *PCR* assay, rectal swab or anal swab tested positive. GI shedding persisted for as long as 4 weeks, with a mean duration of viral shedding of 23 days from the onset of symptoms, compared to an 11-day mean duration of respiratory shedding [67]. Similarly, in a metanalysis of paediatric COVID-19, 86% of 106 tested children had a positive faecal specimen, persisting in most cases (71%) after respiratory swabs turned negative. Moreover, faecal testing remained positive in 25 out of 73 patients who were tested two weeks after the respiratory tract specimens turned negative [68].

To better define the role of GI involvement in the infection, a correlation between gastrointestinal symptoms and the presence of SARS-CoV-2 in faeces or of active viral replication need to be demonstrated. The positivity of stool specimens was not associated with the presence of GI symptoms in children [40,69]. Interestingly, in a series of 244 infected children, the rate of stool specimen positivity was similar between patients with (41%) and without (36%) GI symptoms [40]. Similarly, in a metanalysis including 8 studies where SARS-CoV-2 was tested in faeces, faecal shedding was detected in 40% of 407 patients, but only 12% had GI symptoms [70]. Recently, a large metanalysis of 35 studies (1636 patients) showed that a higher proportion of patients with GI symptoms (52.4% vs 25.9%, OR 2.4) had faecal shedding compared with those without GI symptoms. An even stronger association (51.6% vs 24.0%, OR 3) was found with diarrhoea. Twenty-seven percent of the patients had persistent faecal shedding after nasal swab turned negative, with a mean difference of 7.1 days [71].

The detection of SARS-CoV-2 in faeces does not confirm its faecal-oral transmissibility. Viral RNA was also detected in the sewage, but it is not clear if SARS-CoV-2 can survive long enough and maintain concentrations in fomites sufficient for transmission [72].

A summary of studies on faecal shedding in children is reported in Table 2.

Liver and biliary tract

Multiple factors concur to our difficulties in evaluating the impact of SARS-CoV-2 infection on the liver, especially in children. Laboratory markers of hepatic cytolysis are seldom or partially reported in paediatric cohorts. The description of cholestasis indices is even rarer . The degree of liver dysfunction, beyond an increase in transaminases, is unknown. Moreover, the finding in adults of higher levels of aspartate

(AST) than alanine aminotransferases (ALT), frequently accompanied by high creatine kinase and lactate dehydrogenase levels, has risen the suspicion of the confounding effect of viral myositis. Finally, the role of systemic inflammation-induced damage on the liver and the biliary tract needs to be further clarified.

Except for sporadic cases of hepatic failure [73,74], the extent of SARS-CoV-2-related liver involvement is mild to moderate in children. In early paediatric reports, the rate of AST and ALT elevation was around 20% [75]. Later on, in two large studies including 170 [1] and 100 [76] children, the incidence of AST elevation was 50% and 20%, whereas for ALT it was 35% and 14%, respectively. However, these data may be not fully representative since transaminases and liver function tests were reported only in a small proportion of the included patients. A lower incidence of transaminases elevation (5% for ALT and 17% for AST) was found in 110 patients by Lu et al. [77] In another study on 101 children, a mild elevation of liver enzymes was observed in 40% of patients, but only nine of them presented with an increase of more than two folds [37]. Similarly, in a series of 148 children, the values of AST and ALT, reported as median and interquartile range, were only slightly elevated [31]. Nevertheless, both values were found significantly increased in those children with a moderate course when compared to those with a milder course of the disease. No significant increase was detected in cholestasis or liver function markers, though a slight but significant difference in GGT was observed between patients with a mild and a moderate disease course. Similar results came from the largest study published to date on children [2]. Of the 651 included patients about a half was tested for ALT, with a median value of 24 UI/L, whereas in the 66 patients tested for AST, the median value was 40 UI/L. No significant increases in bilirubin and prothrombin time were reported. Despite little information being available on follow-up in children, a normalisation of transaminases has been described at four months in a small cohort [78]. In a recent metanalysis of 19 studies (3907 patients) the pooled incidence of increased ALT was 8% and that of increased AST was 15% [34].

The impact of age on liver disease susceptibility in COVID-19 is questioned. Early reports indicated that children with abnormal transaminases were younger, a finding possibly explained by the immaturity of the liver in infants as well as by the increased expression of ACE2 receptors [79]. A high rate of liver dysfunction - up to 45% - was reported in a cohort of 46 children younger than one year [80]. However, in this cohort the degree of liver dysfunction was not described.

Studies in adults do not diverge significantly on transaminase elevation, which is reported in around 20% of patients [70], often accompanied by mild increases of bilirubin levels [81,82]. Conversely, the elevation in cholestasis markers — uncommon in children - is not rare in adults [83].

The implications of an increase in transaminases are mostly unknown. An increase of AST, unlike ALT, was associated with GI symptoms in adults with COVID-19 [84]. A significant increase in transaminases is described in adults with severe COVID-19 compared with those with a non-severe course [19], and in those patients admitted in ICU [35]. An association with mortality was also reported [85]. Similarly, liver injury seems to be more prevalent in severe cases of COVID-19 [86], as it is for liver function abnormalities and elevated bilirubin. Moreover, in critically ill adults, pathology revealed a hepatocellular injury pattern, in the absence of severe aminotransferases elevation [85,87]. Therefore, it is reasonable to consider a significant increase of liver enzymes as a warning also in children. Nevertheless, it is to be acknowledged that COVID-19 and hepatic damage can co-occur, and an instrumental linkage can hardly be proven. It is therefore important to rule out other potential causes of liver damage. Monitoring transaminases in those patients still having increased values at discharge, seems a reasonable approach.

A decompensation is described following SARS-CoV-2 infection in adults with chronic liver disease (CLD), particularly in those with associated obesity or diabetes [88]. When liver damage is documented, in both MIS-C and severe COVID-19, vascular thrombotic events should be taken into consideration [89]. Finally, monitoring of transaminases should not be overlooked in those patients receiving treatments such as lopinavir, remdesivir and tocilizumab.

Multisystem inflammatory syndrome in children

Systemic inflammation is thought to be the main driver of MIS-C symptoms, and the liver can be targeted by systemic inflammation. In the first series on MIS-C [4] an increase in ALT was described in two thirds of patients and low albumin values in around 80%. More than a half of patients presented with low platelets. Overt hepatitis or hepatomegaly were described in 6% of patients. However, in a series of ICU admitted children with COVID-19, no difference was found in the rate of acute liver dysfunction between patients with or without MIS-C [45]. Liver disfunction in MIS-C could be just a consequence of high systemic inflammation, as can be found in severe COVID-19. Interestingly, a 14-year-old boy was recently reported to develop clinical-laboratory signs of hepatic steatosis at short-term follow-up after MIS-C, including hepatic steatosis as a possible sequela of the disease [90]. Acute liver failure has been described in critically ill children with MIS-C with multi-organ failure. In the same series, half of patients with MIS-C reported persistently elevated liver enzymes one month after discharge [91]. As for the other disease manifestations, long-term follow-up is required to understand the evolution of this condition.

Pancreas

Pancreatic involvement in children with SARS-CoV-2 infection is rarely reported, and possibly underestimated, considering our knowledge from series on adults. Few cases of SARS-CoV-2-related severe pancreatic injury are reported in children. A 7-year old girl presented with an onset of necrotizing pancreatitis two weeks prior to her COVID-19 diagnosis, and therefore it was unclear if the pancreatitis was associated or caused by the infection [92]. A 10-year-old girl presented with acute pancreatitis before rapidly progressing to a multisystem organ dysfunction consistent with MIS-C [93]. Recently, three children with COVID-19 associated pancreatitis were described. All of them presented with abdominal pain and had laboratory and imaging findings consistent with pancreatitis. Two of them also underwent chest imaging, revealing scattered ground-glass opacities and interstitial opacities with peribronchial

thickening, respectively. Only one developed mild respiratory symptoms typical of COVID-19. All had a favourable disease course, being discharged after a few days [94].

Pancreatic involvement — as defined by serum amylase or lipase elevation — is widely described in adults. Mild laboratory pancreatic enzyme abnormalities have been observed in around 10% of COVID-19 adult patients [95] and more frequently in those with severe disease. [18] An increase in lipase was associated with ICU admission in some series [96], but not in others [97]. Additionally, patients with pancreatic abnormalities often present GI symptoms, though rarely including abdominal pain, which would be helpful to classify such abnormalities as acute pancreatitis [95]. Elevated lipase levels are also frequent in COVID-19-associated acute respiratory distress syndrome [98]. However, whether the increase in pancreatic enzymes is accompanied by other signs of acute pancreatitis, is rarely reported. Even when hyperlipasaemia is described, it seldom exceeds three times the normal range and hardly ever results in radiology-confirmed pancreatitis [97].

Altogether, these findings do not completely support the hypothesis of COVID-19 as a novel aetiology for acute pancreatitis. Determining whether a direct viral damage — as can be speculated considering the high expression of ACE2 in the pancreas — or an indirect damage through systemic inflammation is responsible of pancreatic involvement could help to gain a better understanding. Additionally, a possible role of drug-induced pancreas injury cannot be ruled out. It has also to be acknowledged that COVID-19 and acute pancreatitis can co-occur without an established causal link. Therefore, it remains undetermined if an isolated pancreatic injury in the absence of other COVID-19 symptoms can be ascribed to COVID-19 alone, rising the urge to rule out different potential causes of acute pancreatitis, as for those patients without COVID-19. The long-term effects of pancreatic damage are unknown.

Management of children with COVID-19 and pancreatic abnormalities should include what we have learned from adults with COVID-19 and what we already knew on paediatric pancreatitis. In children with GI symptoms, or at least in those with abdominal pain, screening of amylase and lipase levels could be performed. When pancreatic damage is documented, therapeutic management should follow the guidelines on paediatric acute pancreatitis [99]. As for COVID-19, also severe pancreatitis triggers systemic inflammation. Therefore, when pancreatic damage is documented also other organ dysfunctions and vascular thrombotic events should be excluded.

Finally, an involvement of the endocrine pancreas should not be underestimated, considering the known association of diabetes mellitus with increased morbidity and mortality in COVID-19 patients [100] and the possible worsening of glycaemic control through SARS-CoV-2-mediated damage to the pancreatic beta cells. However, analysing the link between COVID-19 and diabetes remains beyond the purposes of the present review.

Present and future challenges

At the beginning of the pandemic limited data were available on the severity of SARS-CoV-2 infection in patients with chronic conditions. Unexpectedly, the first reported paediatric patients with SARS-CoV-2 infection and inflammatory bowel disease (IBD) had a mild and favourable course [101]. More recently, data on 209 children with IBD who contracted SARS-CoV-2 infection were reassuring. Only seven percent of patients required hospitalization, and no deaths were reported. Therapy with steroids or sulfasalazine/mesalamine, and GI symptoms, were associated with an increased risk of hospitalisation and/or death, that was reduced in patients treated with TNF antagonists [102].

A retrospective multicentric study on 542 coeliac patients showed a incidence of SARS-CoV-2 not significantly different from the general population [103]. Similarly a large international study confirmed that the risk of contracting SARS-CoV-2 infection was similar in individuals with and without coeliac disease [104]. Data from the SECURE-CELIAC Registry of children and adults with coeliac disease, indicate that these subjects are not at increased risk of hospitalization or death [105].

Since children with chronic GI disease do not appear to have a higher risk of severe COVID-19, the challenge remains providing them with adequate care. The first waves of the pandemic have had a strong impact on the healthcare systems in terms of interruption of routine clinical care, *e.g.*, the limitation of endoscopy procedures, due to the high risks connected to aerosol formation. In Italy, hospitalisations for diagnostic or follow-up endoscopy and outpatients' visits were significantly reduced, but hospitalisations for relapse and surgery remained stable, as well as infusions of biologic drugs [106]. In the same period, IBD was regularly diagnosed without endoscopy in the UK [107]. Pre-procedure screening, improvement of risk stratification for endoscopy indication, and appropriate use of personal protective equipment can be effective strategies to reduce delays in diagnosis and treatment [108].

It is reported that adults with CLD have a higher risk of COVID-19 related mortality, compared to those without CLD, but these finding have not been confirmed in children. In early reports, the outcome of COVID-19 in patients with CLD, autoimmune liver disease, and liver transplant recipients was favourable [109]. More recently, a multicenter study conducted on children with CLD in Northern Italy reported that the majority of children remained healthy during the outbreak, without differences in the susceptibility to SARS-CoV-2 infection, regardless of the underlying CLD [110]. Similar findings came from studies focusing on children on immunosuppressive treatment [109]. As for IBD, an underlying liver disease does not seem an additional risk factor for severe COVID-19. A study on 47 liver transplant recipients (children or young adults) infected with SARS-CoV-2 found that no patients required mechanical ventilation or died. Almost 30% of them were asymptomatic, whereas the common findings were respiratory symptoms (36%), fever (34%), and GI symptoms (25%) [111]. Therefore, also in the hepatology practice, the major challenge remains the prosecution of treatment and follow-up. Liver transplant recipients and children with autoimmune liver disease are unlikely to be at higher risk of severe complications of SARS-CoV-2 infection, presenting with similar symptoms and a similarly mild disease course as the general paediatric population. However, a modulation of the immunosuppressive regimens might be sometimes required [111].

Table 3 Recent updates on GI, liver, and pancreatic involvement in children with COVID-19 and MIS-C.

COVID-19	GI	Large series and metanalyses report data on GI symptoms in children with SARS-CoV-2 infection
		GI involvement is associated with disease severity
		Underlying IBD is not an additional risk factor for severe COVID-19
	Liver	Children with SARS-CoV-2 infection can have mild to moderate liver involvement
		Transaminase elevation associated to a less mild disease course
		Underlying CLD is not an additional risk factor for severe COVID-19
	Pancreas	Pancreatic involvement might be underestimated
MIS-C		GI symptoms occur in 80-100% of children with MIS-C
		High ALT and low albumin are common in MIS-C
		Severe COVID-19 has to be suspected rather than MIS-C in the presence of GI symptoms without CV, respiratory, or mucocutaneous involvement
		GI symptoms and fever can anticipate overt MIS-C
		MIS-C can mimic other GI diseases
Faecal shedding		Faecal shedding is associated to GI symptoms (diarrhoea)
		Faecal shedding in children can last longer than respiratory shedding

GI: gastrointestinal; MIS-C: multisystem inflammatory syndrome in children; ALT: alanine aminotransferase; CV: cardiovascular; IBD: inflammatory bowel disease; CLD: chronic liver disease.

Effective immunisation programs are ongoing in Western countries, with dramatic results on disease control [112]. Children are gradually being included in these programs. However, a significant proportion of the world population does not have access to vaccination yet. The extension of vaccination programs to low-income countries is a priority, though unlikely to be obtained in the short period. Therefore, many challenges will still have to be faced in such countries. The severity of SARS-CoV-2 infection was reported not to be increased in low and middle-income countries [113]. However, the indirect effects of the pandemic have been concrete. Neglecting child and maternal health preventive programs can affect immunisation rates and nutritional programs, resulting in increased morbidity from other diseases [113,114]. Therefore, to revert the tendency to a reduced health care access due to neglected global health programs and fear of contracting SARS-CoV-2 infection in hospital settings, is a major challenge. Improving testing for SARS-CoV-2 in symptomatic children will also be necessary, as well as the maintaining of social distancing. GI symptoms, in particular diarrhoea, pose an additional challenge in low-income countries, where the incidence of infectious gastroenteritis is dramatically high. Adequate prevention measures are equally mandatory. Recently, it has been estimated that 26% of the global population lacked access to handwashing with available soap and water [115]. Such a finding gains urgency if we consider faecal-oral transmission a potential route for SARS-CoV-2 infection.

Conclusions

Research on COVID-19 is fast progressing, and much is being discovered on children-specific disease phenotypes. A synopsis of the novel finding reported in this manuscript is reported in Table 3. Overall, GI involvement represents an essential aspect of SARS-CoV-2 infection of in both adults and children. However, many issues remain unanswered and pose multiple challenges to the paediatric gastroenterologist. Among them, the role of GI symptoms in the suspicion of SARS-CoV-2 infection, the potential epidemiologic risk of faecal shedding, and the clinical meaning of hepatic and pancreatic abnormalities. Future research in paediatrics should focus on better defining the clinical profiles of the GI involvement in children and understanding the long-term effects of organ involvement. The role of faeces in spreading the pandemic deserves a wider and deeper perspective, as well as the maintenance of health care standards in both high- and low-income countries.

References

[1] Lu X, Zhang L, Du H, et al. SARS-CoV-2 infection in children. N Engl J Med 2020;382:1663–5.
[2] Swann OV, Holden KA, Turtle L, et al. Clinical characteristics of children and young people admitted to hospital with covid-19 in United Kingdom: prospective multicentre observational cohort study. BMJ 2020;370:m3249.
[3] Dufort EM, Koumans EH, Chow EJ, et al. Multisystem inflammatory syndrome in children in New York state. N Engl J Med 2020;383:347–58.
[4] Feldstein LR, Rose EB, Horwitz SM, et al. Multisystem inflammatory syndrome in U.S. children and adolescents. N Engl J Med 2020;383:334–46.
[5] https://www.who.int/publications/i/item/multisystem-inflammatory-syndrome-in-children-and-adolescents-with-covid-19
[6] Xu Y, Li X, Zhu B, et al. Characteristics of pediatric SARS-CoV-2 infection and potential evidence for persistent fecal viral shedding. Nat Med 2020;26:502–5.
[7] Zhang H, Kang Z, Gong H, et al. Digestive system is a potential route of COVID-19: an analysis of single-cell coexpression pattern of key proteins in viral entry process. Gut 2020;69:1010–8.

[8] Xiao F, Tang M, Zheng X, et al. Evidence for gastrointestinal infection of SARS-CoV-2. Gastroenterology 2020;158:1831–3.
[9] Zuo T, Zhang F, Lui GCY, et al. Alterations in Gut microbiota of patients with COVID-19 during time of hospitalization. Gastroenterology 2020;159:944–55.
[10] Zuo T, Liu Q, Zhang F, et al. Depicting SARS-CoV-2 faecal viral activity in association with gut microbiota composition in patients with COVID-19. Gut 2021;70:276–84.
[11] Budden KF, Gellatly SL, Wood DLA, et al. Emerging pathogenic links between microbiota and the gut—lung axis. Nat Rev Microbiol 2017;15:55–63.
[12] Pan L, Mu M, Yang P, et al. Clinical characteristics of COVID-19 patients with digestive symptoms in Hubei, China: a descriptive, cross-sectional, multicenter study. Am J Gastroenterol 2020;115:766–73.
[13] Lin L, Jiang X, Zhang Z, et al. Gastrointestinal symptoms of 95 cases with SARS- - CoV-2 infection. Gut 2020;69:997–1001.
[14] Chai X, Hu L, Zhang Y, et al. Specific ACE2 expression in cholangiocytes may cause liver damage after 2019-nCoV infection. bioRxiv 2020. doi: 10.1101/2020.02.03.93176615.
[15] Wang Y, Liu S, Liu H, et al. SARS-CoV-2 infection of the liver directly contributes to hepatic impairment in patients with COVID-19. J Hepatol 2020;73:807–16.
[16] Kaltschmidt B, Fitzek ADE, Schaedler J, et al. Hepatic vasculopathy and regenerative responses of the liver in fatal cases of COVID-19. Clin Gastroenterol Hepatol 2021. doi: 10.1016/j.cgh.2021.01.044.
[17] Tsutsumi T, Saito M, Nagai H, et al. Association of coagulopathy with liver dysfunction in patients with COVID-19. Hepatol Res 2020;51:227–32.
[18] Liu F, Long X, Zhang B, et al. ACE2 expression in pancreas may cause pancreatic damage. Clin Gastroenterol Hepatol 2020;18:2128–30.e2.
[19] Guan W, Ni Z, Hu Y, et al. Clinical characteristics of Coronavirus disease 2019 in China. N Engl J Med 2020;382:1708–20.
[20] Cheung KS, Hung IFN, Chan PPY, et al. Gastrointestinal manifestations of SARS-CoV-2 infection and virus load in fecal samples from a Hong Kong cohort: systematic review and meta-analysis. Gastroenterology 2020;159:81–95.
[21] Viner RM, Ward JL, Hudson LD, et al. Systematic review of reviews of symptoms and signs of COVID-19 in children and adolescents. Arch Dis Child 2020:1–6.
[22] Götzinger F, Santiago-García B, Noguera-Julián A, et al. COVID-19 in children and adolescents in Europe: a multinational, multicentre cohort study. Lancet Child Adolesc Heal 2020;4:653–61.
[23] Antúnez-Montes OY, Escamilla MI, Figueroa-Uribe AF, et al. COVID-19 and multisystem inflammatory syndrome in Latin American children: a multinational study. Pediatr Infect Dis J 2020;40:1–6.
[24] Bialek S, Gierke R, Hughes M, et al. Coronavirus disease 2019 in children: current status. MMWR Morb Mortal Wkly Rep 2020;69:422–6.
[25] Cura Yayla BC, Ozsurekci Y, Aykac K, et al. Characteristics and management of children with COVID-19 in Turkey. Balkan Med J 2020:341–7.
[26] Parri N, Lenge M, Cantoni B, et al. COVID-19 in 17 Italian pediatric emergency departments. Pediatrics 2020;146:e20201235.
[27] Garazzino S, Montagnani C, Donà D, et al. Multicentre Italian study of SARS-CoV-2 infection in children and adolescents, preliminary data as at 10 April 2020. Eurosurveillance 2020;25:1–4.
[28] van der Zalm MM, Lishman J, Verhagen LM, Redfern A, Smit L, Barday M, et al. Clinical experience with SARS CoV-2 related illness in children - hospital experience in Cape Town, South Africa. Clin Infect Dis 2020. doi: 10.1093/cid/ciaa1666.
[29] Wu H, Zhu H, Yuan C, et al. Clinical and immune features of hospitalized pediatric patients with Coronavirus disease 2019 (COVID-19) in Wuhan, China. JAMA Netw Open 2020;3:e2010895.
[30] Rabha AC, Oliveira FI De, Oliveira TA De, et al. Clinical manifestations of children and adolescents with COVID-19: report of the first 115 cases from Sabará Hospital Infantil. Rev Paul Pediatr 2021;39:e2020305.
[31] Giacomet V, Barcellini L, Stracuzzi M, et al. Gastrointestinal symptoms in severe covid-19 children. Pediatr Infect Dis J 2020;39:E317–20.
[32] Covid-19 U.S. Case registry: https://www.pedscovid19registry.com/current-data.html.
[33] Bolia R, Dhanesh Goel A, Badkur M, et al. Gastrointestinal manifestations of pediatric Coronavirus disease and their relationship with a severe clinical course: a systematic review and meta-analysis. J Trop Pediatr 2021;67(2):fmab051.
[34] Wang J, Yuan X. Digestive system symptoms and function in children with COVID-19: a meta-analysis. Medicine 2021;100 (111):e24897.
[35] Wang D, Hu B, Hu C, et al. Clinical characteristics of 138 hospitalized patients with 2019 Novel Coronavirus-Infected Pneumonia in Wuhan, China. JAMA 2020;323:1061–9.
[36] Liguoro I, Pilotto C, Bonanni M, et al. SARS-COV-2 infection in children and newborns: a systematic review. Eur J Pediatr 2020;179:1029–46.
[37] Gonzalez Jimenez D, Velasco Rodríguez-Belvís M, Ferrer Gonzalez P, et al. COVID-19 gastrointestinal manifestations are independent predictors of PICU admission in hospitalized pediatric patients. Pediatr Infect Dis J 2020;39:E459–62.
[38] Elshazli RM, Kline A, Elgaml A, et al. Gastroenterology manifestations and COVID-19 outcomes: a meta-analysis of 25,252 cohorts among the first and second waves. J Med Virol 2021. doi: 10.1002/jmv.26836.
[39] Puoti MG, Rybak A, Kiparissi F, et al. SARS-CoV-2 and the gastrointestinal tract in children. Front Pediatr 2021;9:617980.
[40] Xiong XL, Wong KK, Chi SQ, et al. Comparative study of the clinical characteristics and epidemiological trend of 244 COVID-19 infected children with or without GI symptoms. Gut 2021;70:436–8.
[41] Gale C, Quigley MA, Placzek A, et al. Characteristics and outcomes of neonatal SARS-CoV-2 infection in the UK: a prospective national cohort study using active surveillance. Lancet Child Adolesc Heal 2021;5:113–21.
[42] Chen W, Zheng KI, Liu S, et al. Virus discharge and initial gastrointestinal involvement are inversely associated with circulating lymphocyte count in COVID-19. Int J Med Sci 2021;18:1137–42.
[43] Wei XY, Jing D, Jia B, et al. Characteristics of in peripheral blood of 70 hospitalized patients and 8 diarrhea patients with COVID-19. Int J Med Sci 2020;17:1142–6.
[44] Shekerdemian LS, Mahmood NR, Wolfe KK, et al. Characteristics and outcomes of children with coronavirus disease 2019 (COVID-19) infection admitted to US and Canadian pediatric intensive care units. JAMA Pediatr 2020;174:868–73.
[45] García-Salido A, de Carlos Vicente JC, Belda Hofheinz S, et al. Severe manifestations of SARS-CoV-2 in children and adolescents: from COVID-19 pneumonia to multisystem inflammatory syndrome: a multicentre study in pediatric intensive care units in Spain. Crit Care 2020;24:666.
[46] Feldstein LR, Tenforde MW, Friedman KG, et al. Characteristics and outcomes of US children and adolescents with multisystem inflammatory syndrome in children (MIS-C) compared with severe acute COVID-19. JAMA 2021;02115:1–14.
[47] Mao R, Qiu Y, He J-S. Manifestations and prognosis of gastrointestinal and liver involvement in patients with COVID-19: a systematic review and meta-analysis. Lancet Gastroenterol Hepatol 2020;5:667–78.
[48] Godfred-Cato S, Bryant B, Leung J, et al. COVID-19-associated multisystem inflammatory syndrome in children - United States, March–July 2020. MMWR Morb Mortal Wkly Rep 2020;69:1074–80.

[49] Belhadjer Z, Méot M, Bajolle F, et al. Acute heart failure in multisystem inflammatory syndrome in children in the context of global SARS-CoV-2 pandemic. Circulation 2020;142:429–36.
[50] Moraleda C, Serna-Pascual M, Soriano-Arandes A, et al. Multi-inflammatory syndrome in children related to SARS-CoV-2 in Spain. Clin Infect Dis 2020:ciaa1042.
[51] Prata-Barbosa A, Lima-Setta F, Santos GR, et al. Pediatric patients with COVID-19 admitted to intensive care units in Brazil: a prospective multicenter study. J Pediatr 2020;96:582–92.
[52] Lima-Setta F, Magalhães-Barbosa MC, Rodrigues-Santos G, et al. Multisystem inflammatory syndrome in children (MIS-C) during SARS-CoV-2 pandemic in Brazil: a multicenter, prospective cohort study. J Pediatr 2021;97(3):354–61.
[53] Miller J, Cantor A, Zachariah P, et al. Gastrointestinal symptoms as a major presentation component of a novel multisystem inflammatory syndrome in children that iss related to Coronavirus disease 2019: a single center experience of 44 cases. Gastroenterology 2020;159:1571–4.
[54] Chen T-H, Kao W-T, Tseng Y-H. Gastrointestinal involvements in children with COVID-related multisystem inflammatory syndrome. Gastroenterology 2020;160(5):1887–8.
[55] Sahn B, Eze OP, Edelman MC, et al. Features of intestinal disease associated with COVID-related multisystem inflammatory syndrome in children. J Pediatr Gastroenterol Nutr 2020;72(3):384–7.
[56] Du W, Yu J, Liu X, et al. Persistence of SARS-CoV-2 virus RNA in feces: a case series of children. J Infect Public Health 2020;13 (7):926–31.
[57] Jiehao C, Jin X, Daojiong L, et al. A case series of children with 2019 novel Coronavirus infection: clinical and epidemiological features. Clin Infect Dis 2020;71(6):1547–51.
[58] Tan YP, Tan BY, Pan J, et al. Epidemiologic and clinical characteristics of 10 children with coronavirus disease 2019 in Changsha, China. J Clin Virol 2020;127:104353.
[59] Wu Q, Xing Y, Shi L, et al. Coinfection and other clinical characteristics of COVID-19 in children. Pediatrics 2020;146(1): e20200961.
[60] Han MS, Seong MW, Kim N, et al. Viral RNA load in mildly symptomatic and asymptomatic children with COVID-19, Seoul, South Korea. Emerg Infect Dis 2020;26(10):2497–9.
[61] Liu P, Cai J, Jia R, et al. Dynamic surveillance of SARS-CoV-2 shedding and neutralizing antibody in children with COVID-19. Emerg Microbes Infect 2020;9:1254–8.
[62] Xing YH, Ni W, Wu Q, et al. Prolonged viral shedding in feces of pediatric patients with coronavirus disease 2019. J Microbiol Immunol Infect 2020;53(3):473–80.
[63] Zhang B, Liu S, Dong Y, et al. Positive rectal swabs in young patients recovered from coronavirus disease 2019 (COVID-19). J Infect 2020;81(2):e49–52.
[64] Zhang T, Cui X, Zhao X, et al. Detectable SARS-CoV-2 viral RNA in feces of three children during recovery period of COVID-19 pneumonia. J Med Virol 2020;92:909–14.
[65] Ma X, Su L, Zhang Y, et al. Do children need a longer time to shed SARS-CoV-2 in stool than adults? J Microbiol Immunol Infect 2020;53(3):373–6.
[66] Hua CZ, Miao ZP, Zheng JS, et al. Epidemiological features and viral shedding in children with SARS-CoV-2 infection. J Med Virol 2020;92:2804–12.
[67] Xu CLH, Raval M, Schnall JA, et al. Duration of respiratory and gastrointestinal viral shedding in children with SARS-CoV-2: a systematic review and synthesis of data. Pediatr Infect Dis J 2020;39:E249–56.
[68] Wang J, Cui H, Tang H, et al. Gastrointestinal symptoms and fecal nucleic acid testing of children with 2019 coronavirus disease: a systematic review and meta-analysis. Sci Rep 2020;10:1–9.
[69] De Ioris MA, Scarselli A, Ciofi Degli Atti ML, et al. Dynamic viral severe acute respiratory syndrome Coronavirus 2 RNA shedding in children: preliminary data and clinical consideration from a Italian Regional Center. J Pediatric Infect Dis Soc 2020;9:366–9.
[70] Parasa S, Desai M, Thoguluva Chandrasekar V, et al. Prevalence of gastrointestinal symptoms and fecal viral shedding in patients with Coronavirus disease 2019: a systematic review and meta-analysis. JAMA Netw open 2020;3:e2011335.
[71] Zhang Y, Cen M, Hu M, et al. Prevalence and persistent shedding of fecal SARS-CoV-2 RNA in patients with COVID-19 infection: a systematic review and meta-analysis. Clin Transl Gastroenterol 2021;12:e00343.
[72] Guo M, Tao W, Flavell RA, et al. Potential intestinal infection and faecal—oral transmission of SARS-CoV-2. Nat Rev Gastroenterol Hepatol 2021;18:269–83.
[73] Esmaeil EH, Mamishi S, Ekbatani MS, et al. Fulminant hepatic failure: a rare and devastating manifestation of Coronavirus disease 2019 in an 11-year-old boy. Arch Pediatr 2020;27:502–5.
[74] Cui Y, Tian M, Huang DW, et al. A 55-day-old female infant infected with 2019 novel coronavirus disease: presenting with pneumonia, liver injury, and heart damage. J Infect Dis 2020;221:1775–80.
[75] Mansourian M, Ghandi Y, Habibi D, et al. COVID-19 infection in children: a systematic review and meta-analysis of clinical features and laboratory findings. Arch Pediatr 2021 S0929-693X(21)00001-4.
[76] Parri N, Lenge M, Buonsenso D. Children with Covid-19 in pediatric emergency departments in Italy. N Engl J Med 2020;383:187–90.
[77] Lu Y, Li Y, Deng W, et al. Symptomatic infection is associated with prolonged duration of viral shedding in mild Coronavirus disease 2019: a retrospective study of 110 children in Wuhan. Pediatr Infect Dis J 2020;39:E95–9.
[78] Denina M, Pruccoli G, Scolfaro C, et al. Sequelae of COVID-19 in hospitalized children: a 4-months follow-up. Pediatr Infect Dis J 2020;39:E458–9.
[79] Zhou YH, Zheng KI, Targher G, et al. Abnormal liver enzymes in children and infants with COVID-19: a narrative review of case-series studies. Pediatr Obes 2020;15:2–5.
[80] Liu X, Tang J, Xie R, et al. Clinical and epidemiological features of 46 children <1 year old with coronavirus disease 2019 in Wuhan, China: a descriptive study. J Infect Dis 2020;222:1293–7.
[81] Yadav DK, Singh A, Zhang Q, et al. Involvement of liver in COVID-19: systematic review and meta-analysis. Gut 2020;70 gutjnl-2020-322072.
[82] Paliogiannis P, Zinellu A. Bilirubin levels in patients with mild and severe Covid-19: a pooled analysis. Liver Int 2020;40:1787–8.
[83] Nardo AD, Schneeweiss-Gleixner M, Bakail M, et al. Pathophysiological mechanisms of liver injury in COVID-19. Liver Int 2021;41:20–32.
[84] Jin X, Lian JS, Hu JH, et al. Epidemiological, clinical and virological characteristics of 74 cases of coronavirus-infected disease 2019 (COVID-19) with gastrointestinal symptoms. Gut 2020;69:1002–9.
[85] Ding Z, Li G, Chen L, et al. Association of liver abnormalities with in-hospital mortality in patients with COVID-19. J Hepatol 2021 S0168-8278(20)33885-X.
[86] Zhang C, Shi L, Wang F-S. Liver injury in COVID-19: management and challenges Published. Lancet Gastroenterol Hepatol 2020;5:428–30.
[87] Gupta A, Madhavan MV, Sehgal K, et al. Extrapulmonary manifestations of COVID-19. Nat Med 2020;26:1017–32.
[88] Sarin SK, Choudhury A, Lau GK, et al. Pre-existing liver disease is associated with poor outcome in patients with SARS

CoV2 infection; the APCOLIS Study (APASL COVID-19 Liver Injury Spectrum Study). Hepatol Int 2020;14:690–700.
[89] Aghayari Sheikh Neshin S, Basirjafari S, Saberi A, et al. Liver abnormality may develop cerebral vein thrombosis in COVID-19. J Neurol Sci 2020;417:117076.
[90] Sica R, Pennoni S, Penta L, et al. New onset of hepatic steatosis post-severe multisystem inflammatory syndrome in children (MIS-C): a case report. Int J Environ Res Public Health 2021;18(13):6961.
[91] Cantor A, Miller J, Zachariah P, et al. Acute hepatitis Is a prominent presentation of the multisystem inflammatory syndrome in children: a single-center report. Hepatology 2020;72:1522–7.
[92] Alloway BC, Yaeger SK, Mazzaccaro RJ, et al. Suspected case of COVID-19-associated pancreatitis in a child. Radiol Case Rep 2020;15:1309–12.
[93] Stevens JP, Brownell JN, Freeman AJ, et al. COVID-19-associated multisystem inflammatory syndrome in children presenting as acute pancreatitis. J Pediatr Gastroenterol Nutr 2020;71:669–71.
[94] Samies NL, Yarbrough A, Boppana S. Pancreatitis in pediatric patients with COVID-19. J Pediatric Infect Dis Soc 2021;10:57–9.
[95] Samanta J, Gupta R, Singh MP, et al. Coronavirus disease 2019 and the pancreas. Pancreatology 2020;20:1567–75.
[96] Barlass U, Wiliams B, Dhana K, et al. Marked elevation of lipase in COVID-19 disease: a cohort study. Clin Transl Gastroenterol 2020;11:1–5.
[97] McNabb-Baltar J, Jin DX, Grover AS, et al. Lipase elevation in patients with COVID-19. Am J Gastroenterol 2020;115:1286–8.
[98] Rasch S, Herner A, Schmid RM, et al. High lipasemia is frequent in Covid-19 associated acute respiratory distress syndrome. Pancreatology 2021;21:306–11.
[99] Párniczky A, Abu-El-Haija M, Husain S, et al. EPC/HPSG evidence-based guidelines for the management of pediatric pancreatitis. Pancreatology 2018;18:146–60.
[100] Guan W, Liang W, Zhao Y, et al. Comorbidity and its impact on 1590 patients with COVID-19 in China: a nationwide analysis. Eur Respirtory J 2020;55:2000547.
[101] Turner D, Huang Y, Martín-de-Carpi J, et al. Paediatric IBD Porto group of ESPGHAN. Corona Virus Disease 2019 and Paediatric Inflammatory Bowel Diseases: Global Experience and Provisional Guidance (March 2020) from the Paediatric IBD Porto Group of European Society of Paediatric Gastroenterology, Hepatology, and Nutrition. J Pediatr Gastroenterol Nutr 2021;70(6):727–33.
[102] Brenner EJ, Pigneur B, Focht G, et al. Benign evolution of SARS-Cov2 infections in children with inflammatory bowel disease: results from two international databases. Clin Gastroenterol Hepatol 2021;19(2):394–6 e5.
[103] Gasbarrini G, Dionisi T, Corazza GR, et al. COVID-19 in celiac disease: a multicentric retrospective cohort study. Eur Rev Med Pharmacol Sci 2021;25(12):4400–4.
[104] Zhen J, Stefanolo JP, Temprano MP, et al. The risk of contracting COVID-19 is not increased in patients with celiac disease. Clin Gastroenterol Hepatol 2021;19(2):391–3.
[105] Uche-Anya E, Husby S, Kaplan GG, et al. An International Reporting Registry of patients with celiac disease and COVID-19: initial results from SECURE-CELIAC. Clin Gastroenterol Hepatol 2021 S1542-3565(21)00644-3.
[106] Arrigo S, Alvisi P, Banzato C, et al. Impact of COVID-19 pandemic on the management of paediatric inflammatory bowel disease: an Italian multicentre study on behalf of the SIGENP IBD Group. Dig Liver Dis 2021;53:283–8.
[107] Ashton JJ, Kammermeier J, Spray C, et al. Impact of COVID-19 on diagnosis and management of paediatric inflammatory bowel disease during lockdown: a UK nationwide study. Arch Dis Child 2020;105(12):1186–91.
[108] Walsh CM, Fishman DS, Lerner DG. Pediatric endoscopy in the era of Coronavirus disease 2019: a North American Society for pediatric gastroenterology, hepatology, and nutrition position paper. J Pediatr Gastroenterol Nutr 2020;70:741–50.
[109] Di Giorgio A, Hartleif S, Warner S, et al. COVID-19 in children with liver disease. Front Pediatr 2021;9:1–13.
[110] Di Giorgio A, Nicastro E, Arnaboldi S, et al. Health status of children with chronic liver disease during the SARS-CoV-2 outbreak: results from a multicentre study. Clin Res Hepatol Gastroenterol 2021;45(2):101610.
[111] Kehar M, Ebel NH, Ng VL, et al. Severe acute Respiratory Syndrome Coronavirus-2 infection in children with liver transplant and native liver disease: an International Observational Registry Study. J Pediatr Gastroenterol Nutr 2021;72:807–14.
[112] Thompson MG, Burgess JL, Naleway AL, et al. Prevention and attenuation of Covid-19 with the BNT162b2 and mRNA-1273 vaccines. N Engl J Med 2021. 10.1056/NEJMoa2107058.
[113] Zar HJ, Dawa J, Bueno G, et al. Challenges ofCOVID-19 in children in low- and middle-income countries Heather. Paediatr Respir Rev 2020;35:70–4.
[114] Sahoo KC, Negi S, Patel K, et al. Challenges in maternal and child health services delivery and access during pandemics or public health disasters in low-and middle-income countries: a systematic review. Healthcare 2021;9(7):828.
[115] Brauer M, Zhao JT, Bennitt FB, et al. Global access to handwashing: implications for COVID-19 control in low-income countries. Environ Health Perspect 2020;128(5):57005.