Since January 2020 Elsevier has created a COVID-19 resource centre with free information in English and Mandarin on the novel coronavirus COVID-19. The COVID-19 resource centre is hosted on Elsevier Connect, the company's public news and information website.

Elsevier hereby grants permission to make all its COVID-19-related research that is available on the COVID-19 resource centre - including this research content - immediately available in PubMed Central and other publicly funded repositories, such as the WHO COVID database with rights for unrestricted research re-use and analyses in any form or by any means with acknowledgement of the original source. These permissions are granted for free by Elsevier for as long as the COVID-19 resource centre remains active.

BBA - Molecular Basis of Disease 1867 (2021) 166248

Contents lists available at ScienceDirect

BBA - Molecular Basis of Disease

journal homepage: www.elsevier.com/locate/bbadis

COVID-19 in pregnancy: What we know from the first year of the pandemic

Anya Lara Arthurs *, Tanja Jankovic-Karasoulos, Claire Trelford Roberts *

Flinders Health and Medical Research Institute, Flinders University, Adelaide, SA 5042, Australia

ARTICLE INFO

Keywords:
COVID-19
SARS-CoV-2
Placenta
Pregnancy

ABSTRACT

The COVID-19 pandemic has infected nearly 178 million people and claimed the lives of over 3.8 million in less than 15 months. This has prompted a flurry of research studies into the mechanisms and effects of SARS-CoV-2 viral infection in humans. However, studies examining the effects of COVID-19 in pregnant women, their placentae and their babies remain limited. Furthermore, reports of safety and efficacy of vaccines for SARS-CoV-2 in pregnancy are limited.

This review concisely summarises the case studies and research on COVID-19 in pregnancy, to date. It also reviews the mechanism of infection with SARS-CoV-2, and its reliance and effects upon the renin-angiotensin-aldosterone system. Overall, the data suggest that infection during pregnancy can be dangerous at any time, but this risk to both the mother and fetus, as well as placental damage, increases during the third trimester. The possibility of vertical transmission, which is explored in this review, remains contentious. However, maternal infection with SARS-CoV-2 can increase risk of miscarriage, preterm birth and stillbirth, which is likely due to damage to the placenta.

1. Introduction

It is over 15 months since the World Health Organisation declared the COVID-19 outbreak a pandemic on the 11th March 2020 [1]. The disease is caused by infection with SARS-CoV-2, a novel β-coronavirus with similarities to MERS-CoV and SARS-CoV [2]. It is characterised by high infectivity and multiple transmission routes [3]. COVID-19 is primarily a respiratory disease and patients typically present with fever, dry cough, shortness of breath and fatigue. However, a recent study reported that around 50% of patients experience gastrointestinal distress, with approximately 10% of cases experiencing only gastrointestinal symptoms [4,5].

COVID-19 can be life-threatening, with approximately 14% of cases evolving to severe pneumonia, and potentially life-threatening acute respiratory distress syndrome (ARDS) requiring admission to intensive care for respiratory support [6]. Importantly, whilst COVID-19 is considered a primarily respiratory infection, it has systemic effects including hypertension [7], thrombocytopenia [8], kidney disease [9], myocardial injury [10] and liver injury [11]. Furthermore, long-term complications after COVID-19 resolution have been reported, including persistent cardiac inflammation, lung function abnormalities, acute kidney injury, neurological and psychiatric changes [12]. While the implications of COVID-19 infection during pregnancy are still being investigated, these systemic effects alone can have adverse effects on both the mother and fetus. A recent systematic review on the effects of COVID-19 on maternal, fetal and neonatal outcomes has found a significant increase in stillbirth and maternal death, and poorer maternal mental health during the pandemic [13]. In this review we aimed to summarise the physiological and immunological effects of SARS-CoV-2 infection on pregnancy health.

2. SARS-CoV-2 and the renin-angiotensin-aldosterone system

SARS-CoV-2 is transmitted through respiratory droplets, aerosols and infected fomites [14–16]. It accesses the host cell through the cell entry receptor angiotensin-converting enzyme 2 (ACE2) [17], a monocarboxypeptidase that is a key enzyme in regulating the renin-angiotension-aldosterone system (RAAS). There are several tissues that have a local renin-angiotensin system (RAS), including the heart, lung, kidney and placenta [18].

In the classical RAAS, the ACE, angiotensin II, angiotensin type 1 receptor (AT_1R) arm causes vasoconstriction plus water retention via aldosterone. ACE2 is a non-classical ACE. ACE2 catalyses the conversion of angiotensin I (Ang-I) to Ang(1–9), and of Ang-II to Ang(1–7) that binds the Mas receptor [19], as well as cleavage of numerous other peptides outside the RAAS [20] (Fig. 1). This arm of the RAAS is

* Corresponding author.
E-mail addresses: anya.arthurs@flinders.edu.au (A.L. Arthurs), claire.roberts@flinders.edu.au (C.T. Roberts).

https://doi.org/10.1016/j.bbadis.2021.166248
Received 24 April 2021; Received in revised form 21 July 2021; Accepted 14 August 2021
Available online 28 August 2021
0925-4439/© 2021 The Author(s). Published by Elsevier B.V. This is an open access article under the CC BY-NC-ND license (http://creativecommons.org/licenses/by-nc-nd/4.0/).

associated with vasodilation reducing blood pressure [21], and is anti-inflammatory and cardioprotective [22]. ACE2/Ang(1–7)/Mas actions are anti-inflammatory and antioxidant, and were shown to protect lung tissue from damage caused by the H5N1 virus [23].

The spike protein of SARS-CoV-2 is known to dock with the membrane ACE2 receptor to access the host cell (Fig. 2). Using the Cryo-EM structure of the spike protein, it was found that it has a 10–20-fold higher affinity for ACE2 in SARS-CoV-2 than is the case for SARS-CoV [24,25]. Furthermore, susceptibility to SARS-CoV infection was positively correlated with ACE2 expression in cell models [26,27].

The SARS-CoV-2 viral spike protein is cleaved by the serine protease TMPRSS2, which facilitates injection of viral RNA into the host cell [17]. Previous studies showed this is essential for lung infection in wild-type mice as SARS-CoV down-regulated ACE2 protein levels [28]. The complex formed by the spike protein and ACE2 is degraded by the lysosomal pathway, effectively destroying ACE2 and preventing it from being shed from the cell surface. ACE2 is normally shed into the lung surface liquid layer by being cleaved by a number of enzymes including ADAM17. The shed soluble ACE2 would then potentially be a sink for SARS-CoV-2 in lung surface liquid preventing host cell infection [29] and is thought to be protective. Importantly, this also results in release of the ACE2 ectodomain into the circulation, as shown by in vitro experiments, allowing further catalysis and bioactivity [30].

Whilst ACE2 is required for SARS-CoV-2 entry into the host cell, its overall systemic expression and circulating levels paradoxically have a protective effect on disease severity. The protective effects of ACE2 are likely due to changes to the ACE:ACE2 ratio in tissues and in circulation, balancing the pro-inflammatory and anti-inflammatory arms of the RAAS. Circulating ACE2 has been shown to mediate against acute lung injury caused by influenza A (H7N9) [34]. Global ACE2 knockdown in mice leads to severe lung damage when infected with H5N1 and treatment with ACE2 reversed some injury [34]. Furthermore, ACE2-mutant mice exhibit reduced lung pathology upon infection with SARS-CoV, and this was reversed when treated with recombinant ACE2 [28]. Treatment with intravenous ACE2 in humans also has protective effects in the context of pulmonary arterial hypertension [35], which is also a symptom of COVID-19.

3. Factors affecting COVID-19 susceptibility and severity

3.1. ACE2 expression

A recent study utilised numerous publicly available datasets to determine patterns in ACE2 expression depending on age, sex and ethnicity [36]. Whilst an excellent resource, limitations of this study were mainly that the data sources did not cover ACE2 levels and polymorphisms in children, nor those in pregnant women. Using data for adults from 20 years of age, the study showed that ACE2 levels are highest in young adults regardless of ethnicity, and these levels decrease with age [36]. High ACE2 levels in young people could elicit protective effects which, if also confirmed in children, could explain the very mild symptoms of the disease mostly seen in children [24]. It has been proposed that increased ACE2 expression (as determined from RNA sequencing, across a variety of tissues) might enable a lower inflammatory state by maintaining a functioning ACE2-Ang(1–7)-Mas system during infection [37]. Furthermore, the immune system in children is immature and thus the cytokine reaction to SARS-CoV-2 infection may be less harmful than in adults. ACE2 receptors on the type II alveolar epithelial cells of the lower respiratory tract can be functionally immature in children, abating SARS-CoV-2 infection potential [38].

This age-dependent decrease in ACE2 expression across tissues is more profound in males than in females. This coheres with reports that COVID-19 severity is greatest in elderly men, who would be expected to have the lowest ACE2 expression [36].

Comorbidities affect ACE2 expression, with significantly decreased levels in type II diabetics. ACE2 was also significantly reduced with inflammatory cytokine treatment, supporting its anti-inflammatory role in the body. ACE2 levels were also positively correlated with estrogen and androgen levels; both of which decrease with age [36].

ACE2 expression is variable as pregnancy proceeds. We have shown that fetal sex can influence pregnancy outcomes, with circulating ACE (which is partially secreted by placenta) higher in women carrying a

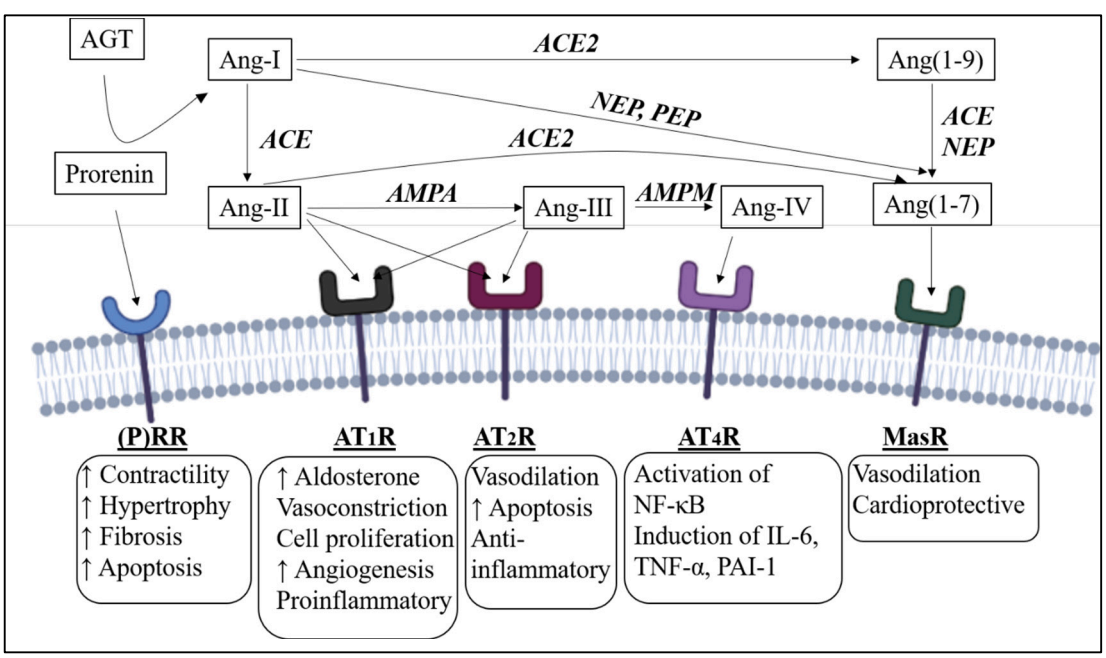

Fig. 1. The activation cascade of the renin angiotensin system. Abbreviations: AGT is Angiotensinogen; Ang-I is angiotensin I; Ang-II is angiotensin II; Ang-III is angiotensin III; Ang-IV is angiotensin IV; Ang(1–9) is angiotensin 1–9; Ang(1–7) is angiotensin 1–7; ACE is angiotensin converting enzyme; ACE2 is angiotensin converting enzyme 2; AMPA is aminopeptidase A; AMPM is aminopeptidase M; NEP is neural endopeptidase; PEP is prolyl-endopeptidase; (P)RR is (pro)renin receptor; AT_1R is angiotensin type 1 receptor; AT_2R is angiotensin type 2 receptor; AT_4R is angiotensin type 4 receptor; NF-κB is nuclear factor-κB; IL-6 is interleukin-6; TNF-α is tumour necrosis factor-α; PAI-1 is platelet activator inhibitor-1.

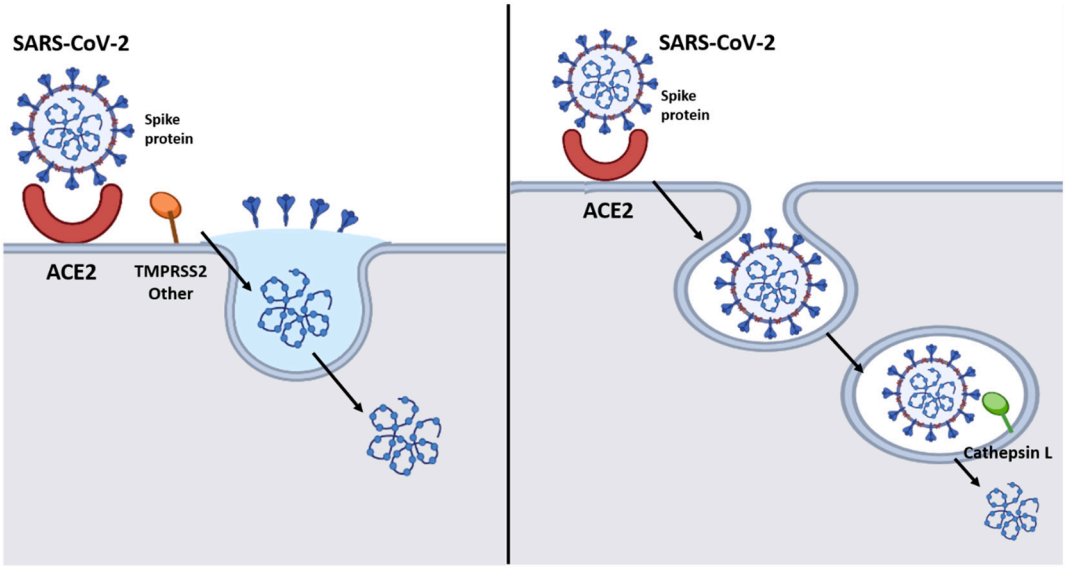

Fig. 2. Cell entry mechanism of SARS-CoV-2 via surface-expressed protein cleavage or cathepsin L endocytosis. Spike proteins on the surface of SARS-CoV-2 virions allow docking to the ACE2 receptor, often utilising host cell surface proteins such as CD147 [31]. **2A:** Surface-expressed proteases such as TMPRSS2 [17] and furin [32] facilitate proteolysis and fusion of viral RNA and entry into the host cell. Cleavage of ACE2 and subsequent shedding can occur via ADAM17 protease activity [30]. **2B:** The virus is endocytosed and cathepsin L mediates proteolysis via endosomal acidification [33], allowing fusion of viral RNA into the host cell.

female fetus than a male at 15 weeks' gestation. This was associated with alterations in maternal blood pressure and an increased risk for having a small for gestational age baby [39]. We have also previously shown that the median ratio of circulating Ang-II:Ang1–7, which are peptides produced by ACE and ACE2 respectively, at 15 weeks' gestation is 2.5 [40]. Furthermore, maternal health plays a role in ACE/ACE2 levels. Reduced ACE2 levels seen in non-pregnant Type 2 diabetes mellitus patients predisposes them to severe lung injury from SARS-CoV-2 infection [41], which may have dangerous implications for mothers with gestational diabetes.

3.2. SNPs in ACE and ACE2

It is possible that genotypic and phenotypic variations also play a role in responses to SARS-CoV-2. For example, East-Asian females have significantly higher expression of ACE2 in a variety of tissues, approximately 30% higher than other ethnic groups, due to highly prevalent SNPs expressed in the ACE2 gene [36]. Genetic factors account for two thirds of the phenotypic variation in circulating ACE2 [42]. Specifically, the ACE2 rs2106809 polymorphism has been suggested to influence overall ACE2 levels [24]. Similarly, we have previously shown that maternal carriage of the ACE A11860G (rs4343) G allele increases circulating ACE at 15 weeks' gestation in a dose-dependent and fetal sex-specific fashion indicating some circulating ACE in pregnancy emanates from the placenta [39]. Circulating ACE was associated with maternal blood pressure [39]. Increased levels of ACE would be predicted to disrupt the ratio of ACE:ACE2 in tissues and circulation, potentially exacerbating inflammation. Moreover, potential for alternative splicing of ACE2 may also play a role in SARS-CoV-2 responses. There are two reported isoforms of the human ACE2 gene in the hg38 genome. Using this knowledge, splice-switching oligonucleotides (which induce isoform switching) are being investigated as a potential treatment for SARS-CoV-2 infection [43].

4. The effect of COVID-19 on pregnant mothers

The main symptoms of COVID-19 are consistent with dysregulation of the RAAS [44,45]; indeed, pregnant women with COVID-19 experience preeclampsia (PE)-like symptoms [46], a disease which is associated with RAAS dysfunction [47]. The syndrome induced by COVID-19 can be distinguished from preeclampsia itself by assessing levels of sFlt-1/PIGF and LDH [46] but the RAAS dysregulation is very similar. One study followed 5 pregnant women with severe COVID-19 infection in their second and third trimesters, who developed PE-like symptoms. However, in 4 of these women sFlt-1/PIGF levels were not abnormal. Furthermore, one pregnancy continued after recovery from COVID-19 and PE-like symptoms spontaneously resolved [46]. PE is also well known to resolve after delivery of the placenta but not before [48].

It is likely that the PE-like syndrome observed in pregnant women with COVID-19 [46] is associated with systemic endothelial dysfunction. A thromboinflammatory state has been reported in infected patients, as well as systemic coagulopathy [49–51]. Maternal infection with COVID-19 is dangerous in pregnancy, and has also been associated with higher incidence rate of actual PE [52], spontaneous preterm birth (sPTB) and maternal morbidity [53] (Fig. 3). Indeed, a recent paper from Brazil reported 124 maternal deaths due to COVID-19 in pregnancy [54]. The risk of developing severe COVID-19 symptoms is significantly increased in pregnant compared with nonpregnant women [55,56], with a significantly greater percentage of pregnant women requiring intensive care unit admission and mechanical ventilation support [55]. Furthermore, women giving birth during the pandemic reported higher stress associated with childbirth, as well as issues bonding with their infants and breastfeeding, compared with women giving birth before the pandemic [57] likely due to fears for their baby and imposed distancing.

Whether the infection with SARS-CoV-2 is symptomatic or asymptomatic also influences maternal and neonatal outcomes. Symptomatic pregnant women have a significantly higher risk of sPTB compared with asymptomatic [58]. Furthermore, acute onset or worsening of symptoms in the perinatal or postnatal period has been noted in mildly symptomatic or asymptomatic pregnant women [59].

COVID-19 symptoms influence decision making about the safest method of delivery. In a study of 241 pregnant women with COVID-19 across multiple New York medical centres, it was reported that 52.4% of women with severe symptoms, and 91.7% of women with critical symptoms, underwent caesarean section to deliver [60]. In the majority of COVID-19 cases in pregnant women, the clinical course taken is similar to that in non-pregnant patients, where distancing between the mother and newborn is enforced [61]. Nevertheless, there have been

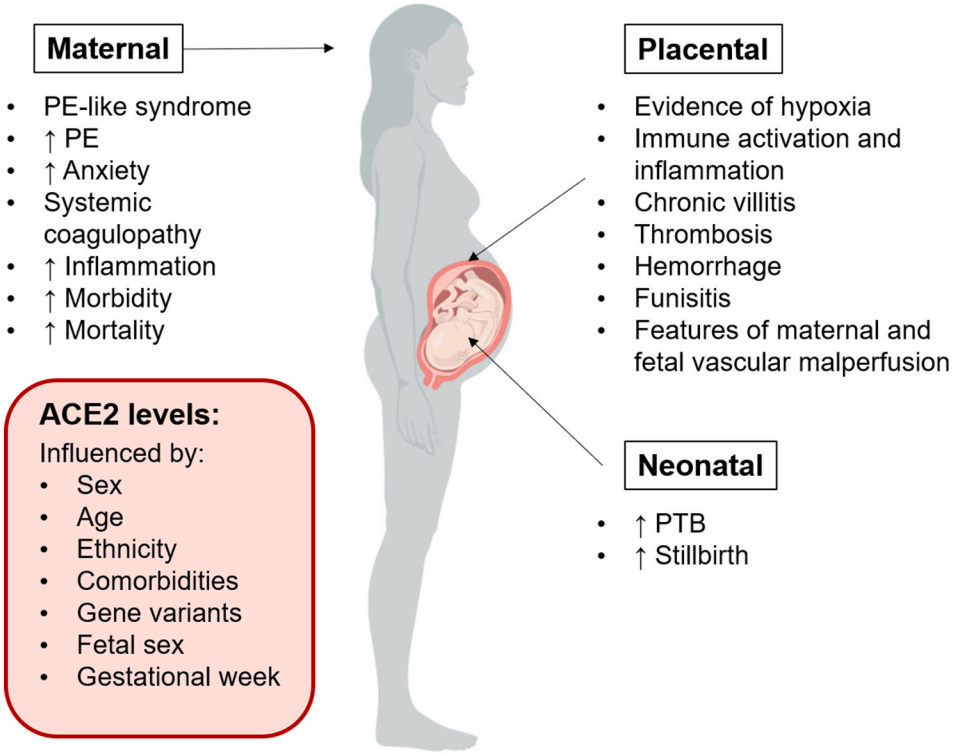

Fig. 3. The effects of SARS-CoV-2 infection in pregnancy, and factors influencing ACE2 levels. SARS-CoV-2 infection in pregnancy is dangerous, with a myriad of reported effects in maternal, placental and neonatal health. It is hypothesised that these effects can be somewhat mitigated by ACE2 expression levels (relative to ACE), which are influenced by sex, age, ethnicity, comorbidities and gene variants in the patient, as well as the fetal sex and gestational week in pregnant patients.

reports of newborns infected with SARS-CoV-2. While the COVID-19 commonly presents with mild or no symptoms [62–64], some babies experience respiratory distress, thrombocytopenia and adverse liver function, with rare cases resulting in death [65]. The mode of viral infection in newborns is still under contention.

5. The effect of COVID-19 on pregnancy health

5.1. Immune response in the placenta

Maternal immune tolerance of the fetus and placenta is complex and involves both the maternal immune system, particularly in the decidua, and the placenta. The immune state of the placenta is highly regulated and changes across pregnancy [66]. The first trimester of gestation can be categorised as a pro-inflammatory phase, which is necessary to allow successful implantation and placentation. The decidua and placenta adopt an anti-inflammatory state to optimise fetal development in the second trimester, which later switches to a pro-inflammatory state for parturition [67]. Once parturition is initiated, immune cell recruitment into the myometrium and cervix creates a proinflammatory environment, stimulating uterine contractions [68].

In healthy pregnancies, the decidua contains a large number of immune cells, including T regulatory cells [69], natural killer cells [70] and macrophages [71]. These cells are necessary for a viable pregnancy [72–74]. T lymphocytes account for up to 10% of decidual immune cells, whilst B cells are not present [75]. However, this state of immune protection for the fetus could potentially be detrimental to pregnancy in COVID-19. The inflammatory response to infection can cause sPTB as a result of inflammatory cytokine release [76], increased prostaglandin production and compromised fetal immune tolerance [38].

Indeed, in pregnant women during the 2009 H1N1 flu pandemic, the activation of the cellular immune response leading to inflammatory cytokine release was shown to cause placental damage [77]. The placenta is also potentially susceptible to SARS-CoV-2 infection, containing all required molecules to allow viral entry into the cells. ACE2 levels in the placenta are highest in early gestation and decrease in mid to late gestation [78]. The expression of ACE2 is particularly high in the decidual cells, villous cytotrophoblasts and syncytiotrophoblast [79,80]. ACE2 and TMPRSS2 co-expression has been established in first trimester syncytiotrophoblast, second trimester extravillous cytotrophoblasts and in third trimester chorioamniotic membranes [81–83].

Furthermore, ACE2 is an interferon-stimulated gene, activated by interferon signalling via the Jak/STAT pathway. It is suggested that SARS-CoV-2 may manipulate species-specific interferon-driven upregulation of ACE2 to augment infection [84]. This is particularly relevant in the context of pregnancy, where interferon expression is highly regulated [85]. Indeed, while ACE2 expression in the placenta usually decreases across gestation and third trimester placentae usually have low ACE2 expression, in placentae taken from term COVID-19 positive women the ACE2 expression is significantly higher [86]. It is therefore possible that ACE2 expression is stimulated by interferon upon SARS-CoV-2 infection.

Placentae from pregnant women infected by SARS-CoV-2 show extensive immune activation, with heavy recruitment of both $CD4^+$ and $CD8^+$ T lymphocytes [87,88]. One study found that in 67% of cases there was evidence of inflammation in the decidua and chorionic villi, with the majority of these showing $CD8^+$ T-cell lymphocytic infiltrate [38]. This is consistent with a diagnosis of chronic villitis [89]. Acute chorionitis and chorioamnionitis are also reported in 33% of SARS-CoV-2 positive placentas from 11 different studies [90].

Maternal immunoglobulin (Ig) G (IgG) antibodies are reported to be detectable within 2 weeks of SARS-CoV-2 infection [91]. Of note, maternal IgG antibodies readily transfer through the placenta to the fetus throughout gestation but this is not the case for maternal IgM antibodies, the presence of which in fetal or cord blood is associated with infection or fetal immune response [92].

Neonatal levels of maternal IgG and IgM antibodies have been tested, purportedly to obtain serological evidence of vertical transmission. One

study found that SARS-CoV-2 IgG antibodies were detectable in cord blood of 87% of newborns born to COVID-19 positive mothers. Cord blood IgG concentrations were positively correlated with those in the mother, as well as duration between the onset of the infection and delivery. However, IgM antibodies were not detected in any cord blood samples [93]. There has been one report of a neonate with elevated IgG and IgM antibodies two hours postpartum, although at no point did the infant test positive for SARS-CoV- 2 by RT-PCR [94]. Overall, at this stage, use of IgG and IgM antibodies to infer vertical transmission (see Section 5.3) appears to be inconclusive.

5.2. Effect of maternal COVID-19 infection on placental function

Many recent studies have reported numerous histopathological differences in placentae from women with COVID-19 compared to control (uninfected) placentae. Maternal infection with SARS-CoV-2 results in placental features of maternal vascular malperfusion [95], including retroplacental hematoma, distal villous hyperplasia, mural hypertrophy, acute atherosis and fibrinoid necrosis [95,96] as well as hemorrhagic necrosis [96]. Features of fetal vascular malperfusion have also been observed, including chorioangiosis [95], thrombosis [49,95] and fibrin deposition [95], as well as chorioamnionitis [95,97], chronic villitis, thrombosis and hemorrhage [38] (Fig. 3). These histopathological changes reflect an inflammatory state in the placenta. An inflammatory infiltrate has been observed in placental chorionic villi which is similar to damage observed in lungs of deceased COVID-19 patients [98]. CD68+ histiocytes have been detected in areas of placental inflammation [97]. Lymphocyte infiltration has been noted surrounding endothelial cells and decidual vessels, and the chorionic villi adjacent to this decidual tissue showed changes consistent with chronic hypoxia [96]. Indeed, vascular abnormalities in the placenta resulting from maternal COVID-19 infection have been associated with maternal and neonatal adverse outcomes [89].

However, it is clear that timing of infection with SARS-CoV-2 during pregnancy is critical when determining the potential harmful effects on the placenta. One study examined placentae from pregnant women who had contracted COVID-19 in their first trimester (Group I) with placentae from women delivering in the acute stage of COVID-19 infection (Group II) and placentae from pregnant women who had recovered from COVID-19 infection in their third trimester (Group III). Placental histopathology was unchanged in Group I compared to placentae from uninfected women. Group II placentae had intervillous and subchorionic fibrin deposition. However, Group III placentae showed widespread thrombotic vasculopathy and the newborns from this group had significantly higher rates of intrauterine growth restriction and were more likely to be small for gestational age [54].

5.3. Possibility of vertical transmission

Whether or not SARS-CoV-2 is able to infect a fetus by vertical transmission is still unknown. There are several notable examples of viruses causing severe complications during pregnancy [99,100]. Patients suffering from SARS-CoV and MERS-CoV whilst pregnant experienced maternal hypoxia, resulting in fetal distress and prematurity [100]. Viruses such as CMV [101] and Zika [102] can cause placental inflammation and are able to cross the placenta and infect the fetus through vertical transmission [103]. In one report, placentae from pregnant women with SARS-CoV underwent histological examination, with increased subchorionic and intervillous fibrin seen in 40% of samples and thrombotic vasculopathy associated with IUGR seen in 28% of samples (similar to effects of SARS-CoV-2 in the placenta). However, chronic villitis was not observed in any samples [104].

Vertical transmission of SARS-CoV-2 from the mother to the fetus via the placenta is possible though reports remain controversial. The proteins required for SARS-CoV-2 entry to placenta cells, ACE2 and TMPRSS2, are highly expressed in term maternal-fetal interface tissues [80]. However, the exact cellular and molecular pathway to transmission of viruses is still unclear for SARS-CoV-2 and many others [105]. Whilst pathogens can cross the barrier via leukocytes and infection of cytotrophoblasts, pathogens are often captured by Hofbauer cells (placental macrophages) [106]. Furthermore, ACE2 is not expressed in the extravillous cytotrophoblasts in first trimester placenta, and there is very low TMPRSS2 activation in the syncytiotrophoblast [80,107]. Hence, further research is required to elucidate the mechanism of vertical transmission.

To date, evidence as to whether neonates have acquired COVID-19 in utero is equivocal. One study reported no evidence of vertical transmission of SARS-CoV-2 in early pregnancy [108]. However, a recent case study of a miscarriage at 13 weeks' gestation shows the presence of viral RNA and SARS-CoV-2 nucleocapsid protein in the placenta, as well as multiple fetal tissues thus confirming vertical transmission [109]. The study also showed evidence of hyperinflammatory processes in multiple fetal organs. Further reports stated that elevated SARS-CoV-2 IgM antibody levels were found in three newborn babies but these results were unable to be substantiated in follow-up tests [110,111]. One report described positive qRT-PCR results for SARS-CoV-2 in both the mother and the neonate, despite delivery via caesarean section and immediate distancing of the baby from the mother. However, the results of swabs from the placenta were negative [112], confounding the suggestion of vertical transmission. Conversely, in another study, SARS-CoV-2 RNA was detected in three separate placental samples from pregnant women with COVID-19 but none of the newborns tested positive for the disease [113].

Other reports remain confident regarding the possibility of vertical transmission. Studies list the incidence of positive SARS-CoV-2 swabs in neonates born to mothers with COVID-19 to range from approximately 3% [108] to 8% [114]. However, the incidence of positive SARS-CoV-2 tests in neonates varies with delivery method, with approximately 0.4–5% incidence in babies delivered via caesarean section [115] but approximately 10–22% incidence in babies delivered vaginally. However, to add confusion these studies have reported no positivity for SARS-CoV-2 in vaginal fluids [116,117].

A meta-analysis of nearly 40 studies which found approximately 3% incidence of SARS-CoV-2 infection in neonates also found approximately 8% incidence of infection in placentae, 3.5% in umbilical cord blood, 10% in anal/rectal swabs and also 3.5% positivity in serological tests. However, no positive tests were found in amniotic fluid [108]. One positive qRT-PCR result for SARS-CoV-2 was reported in a mother, placenta and newborn triad [111]. The study also utilised in situ hybridisation to localise the virus spike protein RNA to the syncytiotrophoblast but was not detected in other chorionic villus cell layers below it. This may indicate a potential first step in vertical transmission but also may reflect the barrier function of syncytiotrophoblast. Furthermore, high IgM levels have been reported in another neonate aged two hours which could be taken as an indicator of intrauterine infection but this neonate never tested positive for the disease [118].

Regardless of whether vertical transmission is possible, the effects of COVID-19 on women during pregnancy are serious. COVID-19 infection can cause hypoxemia and maternal respiratory failure, compromising utero-placental oxygen delivery and triggering miscarriage [119]. Two stillbirths have already been recorded in cases where one pregnant woman experienced ARDS leading to multiple organ failure and another where the mother eventually died [58,120]. Difficulties for mothers with COVID-19 include premature rupture of membranes and fetal distress and there are postnatal reports of tachycardia, shock, thombocytopenia, respiratory distress and death in some neonates, regardless of the newborns testing negative for the virus [15,58,121,122].

6. Effects on the neonate

Maternal SARS-CoV-2 infection has been shown to have serious consequences on neonatal health. Pregnant women with COVID-19 have

high rates of sPTB, with studies reporting rates of 21% [123] and 40% sPTB in their cohorts [53,124] which is 2–4 times higher than the average rate of 10% [125]. Approximately 3% of pregnancies in women with COVID-19 end in stillbirth [126], where the usual rate is <1% [127].

Numerous studies indicate that the placental damage from SARS-CoV-2 infection is sufficient to cause serious morbidity and even mortality in neonates (Fig. 3). There are reports of both stillborn neonates and their placentae testing negative for SARS-CoV-2 infection despite extensive damage to the placenta and funisitis [128–130] (see more detail in Section 5.2). Furthermore, absence of symptoms in an infected mother does not preclude neonatal death. One study reported a SARS-CoV-2 positive, asymptomatic pregnant woman in week 32 of her pregnancy. At 35 weeks' gestation, she had no physical symptoms but the fetal heartbeat was absent. Upon delivery, no abnormalities were detected in her stillborn baby but 75% of the placenta showed extensive fetal vascular malperfusion and parenchymal infarcts [131].

6.1. COVID-19 and breastfeeding

The WHO states that breastfeeding is the optimal form of nutrition for babies and recommends that women infected with COVID-19 should still breastfeed their babies wherever possible [132]. Many studies have not detected any SARS-CoV-2 virus in breastmilk [133,134] and have also confirmed that SARS-CoV-2 antibodies are transmitted through breastmilk [135]. However, there have been recent reports of SARS-CoV-2 virus detected in breastmilk samples. One study detected the virus in a sample taken at one day postpartum but could not detect it after this timepoint [136]. Another case report from a patient with severe COVID-19 symptoms detected viral RNA in breastmilk samples from four days postpartum [137]. Furthermore, one case study posits infection via breastmilk; milk samples from one, three and four days postpartum were positive for SARS-CoV-2 RNA and the neonate did not test positive for COVID-19 until four days postpartum. There are obviously other factors for transmission that should be taken into account [138]. The American Academy of Paediatrics provides breastfeeding recommendations to minimise the risk of transmission from mother to the baby. For women with mild symptoms these recommendations include wearing a surgical mask and washing hands and breasts with soap and water before breastfeeding. Women with more moderate symptoms are required to follow the same recommendations except that they are advised to express milk and for milk to be given to the baby in a separate room [139].

7. Conclusion

Intense research efforts in the last 12 months, together with previous knowledge on other SARS viruses, have yielded a lot of information about SARS-CoV-2 and COVID-19, the disease it causes. With nearly 178 million cases and 3.8 million deaths to date, we can't know enough about this pandemic. Pregnant women have been somewhat neglected with mostly case reports and small studies. CDC data in the United States is mostly for women infected in third trimester with little information on early pregnancy infection and impact on pregnancy outcome. In addition, vaccine trials and rollouts have only recently included pregnant women. However, data to date show that COVID-19 in pregnancy, as with other SARS viral infections and influenza, can be more severe than in non-pregnant women of reproductive age requiring intensive care admission. Although data on vertical transmission are contentious, risks to the baby can include stillbirth and preterm delivery likely mediated by damage to the placenta. Clearly more effort is required to understand the full implications of COVID-19 for maternal and newborn health.

Note: In June 2021 the Royal Australia and New Zealand College of Obstetrics and Gynaecology has recommended that pregnant women be vaccinated at any time in pregnancy to protect them from COVID-19. The US CDC also states that pregnant women can receive the vaccination, while WHO recommends COVID-19 vaccination for pregnant women for whom the benefits outweigh the risks such as health care workers.

Declaration of competing interest

The authors declare that they have no known competing financial interests of personal relationships that could have appeared to influence the work reported in this paper.

Acknowledgements

This work was supported, in part, by a grant from Flinders University, Australia and the Flinders Foundation. CTR is supported by a National Health and Medical Research Council (NHMRC) of Australia Investigator Grant (GNT1174971) and a Matthew Flinders Professorial Fellowship from Flinders University, Australia. Figures were created with Biorender.com.

References

[1] WHO, WHO Director-general's Opening Remarks at the Media Briefing on COVID-19-11 March 2020, Geneva, Switzerland, 2020.
[2] W. Wang, Y. Xu, R. Gao, R. Lu, et al., Detection of SARS-CoV-2 in different types of clinical specimens, Jama 323 (18) (2020) 1843–1844.
[3] F. Xiao, M. Tang, X. Zheng, Y. Liu, et al., Evidence for gastrointestinal infection of SARS-CoV-2, Gastroenterology 158 (6) (2020) 1831–1833.
[4] L. Yang, L. Tu, Implications of gastrointestinal manifestations of COVID-19, Lancet 5 (7) (2020) 629–630.
[5] R. Mao, Y. Qiu, J. He, J. Tan, et al., Manifestations and prognosis of gastrointestinal and liver involvement in patients with COVID-19: a systematic review and meta-analysis, Lancet Gastroenterol. Hepatol. 5 (7) (2020) 667–678.
[6] Z. Wu, J. McGoogan, Outbreak in China: summary of a report of 72 314 cases from the Chinese center for disease control and prevention, in: Characteristics of and Important Lessons From the Coronavirus Disease 2019 (COVID-19) JAMA, 2020.
[7] R. Kreutz, E. Algharably, M. Azizi, P. Dobrowolski, et al., Hypertension, the renin-angiotensin system, and the risk of lower respiratory tract infections and lung injury: implications for COVID-19, Cardiovasc. Res. 116 (10) (2020) 1688–1699.
[8] G. Lippi, M. Plebani, B. Henry, Thrombocytopenia is associated with severe coronavirus disease 2019 (COVID-19) infections: a meta-analysis, Clin. Chim. Acta 506 (2020) 145–148.
[9] Y. Cheng, R. Luo, K. Wang, M. Zhang, et al., Kidney Disease is Associated With Inhospital Death of Patients With COVID-19, Kidney International, 2020.
[10] A. Lala, K. Johnson, J. Januzzi, A. Russak, et al., Prevalence and impact of myocardial injury in patients hospitalized with COVID-19 infection, J. Am. Coll. Cardiol. 76 (5) (2020) 533–546.
[11] Q. Cai, D. Huang, H. Yu, Z. Zhu, et al., Characteristics of liver tests in COVID-19 patients, J. Heptol. 73 (3) (2020) 566–574.
[12] CDC, Long-term effects of COVID-19, 2020.
[13] B. Chmielewska, I. Barratt, R. Townsend, E. Kalafat, et al., Effects of the COVID-19 pandemic on maternal and perinatal outcomes: a systematic review and meta-analysis, Lancet Glob. Health 9 (6) (2021) 759–772.
[14] Q. Li, X. Guan, P. Wu, X. Wang, et al., Early transmission dynamics in Wuhan, China, of novel coronavirus–infected pneumonia, N. Engl. J. Med. 382 (2020) 1199–1207.
[15] S. Amatya, T. Corr, C. Gandhi, K. Glass, et al., Management of newborns exposed to mothers with confirmed or suspected COVID-19, J. Perinatol. 40 (2020) 987–996.
[16] K. Shen, Y. Yang, T. Wang, D. Zhao, et al., Diagnosis, treatment, and prevention of 2019 novel coronavirus infection in children: experts' consensus statement, World J. Pediatr. 16 (3) (2020) 223–231.
[17] M. Hoffmann, H. Kleine-Weber, N. Krüger, M. Müller, et al., The novel coronavirus 2019 (2019-nCoV) uses the SARS-coronavirus receptor ACE2 and the cellular protease TMPRSS2 for entry into target cells, bioRxiv (2020), https://doi.org/10.1101/2020.01.31.929042.
[18] M. Paul, A. Poyan Mehr, R. Kreutz, Physiology of local renin-angiotensin systems, Physiol. Rev. 86 (3) (2006) 747–803.
[19] R. Gomez, V. Norwood, Developmental consequences of the renin-angiotensin system, Kidney Dis. (26) (1995).
[20] C. Vickers, P. Hales, V. Kaushik, L. Dick, et al., Hydrolysis of biological peptides by human angiotensin-converting enzyme-related carboxypeptidase, J. Biol. Chem. 277 (2002) 14838–14843.
[21] S. Patel, E. Velkoska, M. Freeman, B. Wai, et al., From gene to protein-experimental and clinical studies of ACE2 in blood pressure control and arterial hypertension, Front. Physiol. 5 (2014) 227.
[22] M. Chamsi-Pasha, Z. Shao, W. Tang, Angiotensin-converting enzyme 2 as a therapeutic target for heart failure, Curr. Heart Fail. Rep. 11 (1) (2014) 58–63.
[23] Z. Zou, Y. Yan, Y. Shu, R. Gao, et al., Angiotensin-converting enzyme 2 protects from lethal avian influenza A H5N1 infections, Nat. Commun. 5 (2014) 1–7.

[24] E. Ciaglia, C. Vecchione, A. Puca, COVID-19 infection and circulating ACE2 levels: protective role in women and children, Front. Pediatr. 8 (206) (2020).
[25] D. Wrapp, N. Wang, K. Corbett, J. Goldsmith, et al., Cryo-EM structure of the 2019-nCoV spike in the prefusion conformation, Science 367 (2020) 1260–1263.
[26] Y. Nie, P. Wang, X. Shi, G. Wang, et al., Highly infectious SARS-CoV pseudotyped virus reveals the cell tropism and its correlation with receptor expression, Biochem. Biophys. Res. Commun. 321 (2004) 994–1000.
[27] H. Hofmann, K. Pyrc, L. van der Hoek, M. Geier, et al., Human coronavirus NL63 employs the severe acute respiratory syndrome coronavirus receptor for cellular entry, Proc. Natl. Acad. Sci. U. S. A. 102 (2005) 7988–7993.
[28] K. Kuba, Y. Imai, S. Rao, H. Gao, et al., A crucial role of angiotensin converting enzyme 2 (ACE2) in SARS coronavirus-induced lung injury, Nat. Med. 11 (2005) 875–879.
[29] A. Danser, M. Epstein, D. Batlle, Renin-angiotensin system blockers and the COVID-19 pandemic, Hypertension 75 (2020) 1382–1385.
[30] A. Heurich, H. Hofmann-Winkler, S. Gierer, T. Liepold, et al., TMPRSS2 and ADAM17 cleave ACE2 differentially and only proteolysis by TMPRSS2 augments entry driven by the severe acute respiratory syndrome coronavirus spike protein, J. Virol. 88 (2013) 1293–1307.
[31] K. Wang, W. Chen, Z. Zhang, Y. Deng, et al., CD147-spike protein is a novel route for SARS-CoV-2 infection to host cells, Signal Transduct. Target. Ther. 5 (1) (2020) 1–10.
[32] D. Bestle, M.R. Heindl, H. Limburg, O. Pilgram, et al., TMPRSS2 and furin are both essential for proteolytic activation of SARS-CoV-2 in human airway cells, Life Sci. Alliance 3 (9) (2020).
[33] T. Ou, H. Mou, L. Zhang, A. Ojha, et al., Hydroxychloroquine-mediated inhibition of SARS-CoV-2 entry is attenuated by TMPRSS2, PLoS Pathog. 17 (1) (2021), e1009212.
[34] P. Yang, H. Gu, Z. Zhao, W. Wang, et al., Angiotensin-converting enzyme 2 (ACE2) mediates influenza H7N9 virus-induced acute lung injury, Sci. Rep. 4 (2014) 7027.
[35] A. Hemnes, A. Rathinasabapathy, E. Austin, E. Brittain, et al., A potential therapeutic role for angiotensin converting enzyme 2 in human pulmonary arterial hypertension, Eur. Respir. J. 51 (2018).
[36] J. Chen, Q. Jiang, X. Xia, K. Liu, et al., Individual variation of the SARS-CoV-2 receptor ACE2 gene expression and regulation, Aging Cell 19 (7) (2020), e13168.
[37] S. Felsenstein, C. Hedrich, COVID-19 in children and young people, Lancet Rheumatol. 2 (9) (2020) e514–e516.
[38] L. Bertero, F. Borella, G. Botta, A. Carosso, et al., Placenta in SARS-CoV-2 infection: a new target for inflammatory and thrombotic events, Research Square (2020), https://doi.org/10.21203/rs.3.rs-30412/v1.
[39] A. Zhou, G. Dekker, E. Lumbers, S. Leemaqz, et al., The association of maternal ACE A11860G with small for gestational age babies is modulated by the environment and by fetal sex: a multicentre prospective case–control study, Mol. Hum. Reprod. 19 (9) (2013) 618–627.
[40] S. Sykes, K. Pringle, A. Zhou, G. Dekker, et al., The balance between human maternal plasma angiotensin II and I angiotensin 1-7 levels in early gestation pregnancy is influenced by fetal sex, J. Renin-Angiotensin-Aldosterone Syst. 15 (4) (2014) 523–531.
[41] D. Drucker, Coronavirus infections and type 2 diabetes-shared pathways with therapeutic implications, Endocr. Rev. 45 (2020).
[42] G. Rice, A. Jones, P. Grant, A. Carter, et al., Circulating activities of angiotensin-converting enzyme, its homolog, angiotensinconverting enzyme 2, and neprilysin in a family study, Hypertension 48 (2006) 914–992.
[43] S. Rehman, M. Tabish, Alternative splicing of ACE2 possibly generates variants that may limit the entry of SARS-CoV-2: a potential therapeutic approach using SSOs, Clin. Sci. 134 (2020) 1143–1150.
[44] M. Gheblawi, K. Wang, A. Viveiros, Q. Nguyen, et al., Angiotensin converting enzyme 2: SARS-CoV-2 receptor and regulator of the renin-angiotensin system, Circ. Res. 126 (10) (2020) 1456–1474.
[45] P. Liu, A. Blet, D. Smyth, H. Li, The science underlying COVID-19: implications for the cardiovascular system, Circulation 142 (1) (2020) 68–78.
[46] M. Mendoza, I. Garcia-Ruiz, N. Maiz, C. Rodo, *et al.*, Preeclampsia-like syndrome induced by severe COVID-19: a prospective observational study, BJOG (2020).
[47] R. Irani, Y. Xia, The functional role of the reinin-angiotensin system in pregnancy and preeclampsia, Placenta 763 (2008) 71.
[48] J. Roberts, C. Escudero, The placenta in preeclampsia, Pregnancy Hypertens 2 (2) (2012) 72–83.
[49] J. Mulvey, C. Magro, L. Ma, G. Nuovo, et al., Analysis of complement deposition and viral RNA in placentas of COVID-19 patients, Ann. Diagn. Pathol. 46 (2020), 151530.
[50] D. Lillicrap, Disseminated intravascular coagulation in patients with 2019-nCoV pneumonia, J. Thromb. Haemost. 18 (2020) 786–787.
[51] J. Connors, J. Levy, Thromboinflammation and the hypercoagulability of COVID-19, J. Thromb. Haemost. 18 (7) (2020) 1559–1561.
[52] M. Ahlberg, M. Neovius, S. Saltvedt, J. Söderling, et al., Association of SARS-CoV-2 test status and pregnancy outcomes, Jama 324 (17) (2020) 1782–1785.
[53] D. Di Mascio, A. Khalil, G. Saccone, G. Rizzo, et al., Outcome of coronavirus spectrum infections (SARS, MERS, COVID-19) during pregnancy: a systematic review and meta-analysis, Am. J. Obstet. Gynecol. 2 (2) (2020) 100107.
[54] Y. Wenling, Q. Junchao, X. Zhirong, O. Shi, Pregnancy and COVID-19: management and challenges, Rev. Inst. Med. Trop. Sao Paulo 62 (2020).
[55] S. Ellington, P. Strid, V. Tong, K. Woodworth, et al., Characteristics of women of reproductive age with laboratory-confirmed SARS-CoV-2 infection by pregnancy status, Morb. Mortal. Wkly Rep. 69 (2020) 769–775.
[56] e.a. Chen H, Clinical characteristics and intrauterine vertical transmission potential of COVID-19 infection in nine pregnant women: a retrospective review of medical records, Lancet 395 (2020) 809–15.
[57] G. Mayopoulos, T. Ein-Dor, G. Dishy, R. Nandru, et al., COVID-19 is associated with traumatic childbirth and subsequent mother-infant bonding problems, J. Affect. Disord. 282 (2021) 122–125.
[58] Y. Liu, H. Chen, K. Tang, Y. Guo, Clinical manifestations and outcome of SARS-CoV-2 infection during pregnancy, J. Inf. Secur. 163 (20) (2020) 30109–301092.
[59] M. Alzamora, T. Paredes, D. Caceres, C. Webb, et al., Severe COVID-19 during pregnancy and possible vertical transmission, Am. J. Perinatol. 37 (2020) 861–865.
[60] R. Khoury, P. Bernstein, C. Debolt, J. Stone, et al., Characteristics and outcomes of 241 births to women with severe acute respiratory syndrome coronavirus 2 (SARS-CoV-2) infection at five New York city medical centers, Obstet. Gynecol. 136 (2020) 273–282.
[61] P. Dashraath, J.L.J. Wong, M.X.K. Lim, L.M. Lim, et al., Coronavirus disease 2019 (COVID-19) pandemic and pregnancy, Am. J. Obstet. Gynecol. 222 (6) (2020) 521–531.
[62] M. Wei, J. Yuan, Y. Liu, T. Fu, et al., Novel coronavirus infection in hospitalized infants under 1 year of age in China, JAMA 323 (13) (2020) 1313–1314.
[63] P. Brodin, Why is COVID-19 so mild in children? Acta Paediatr. 109 (6) (2020) 1082–1083.
[64] J. Ludvigsson, Systematic review of COVID-19 in children show milder cases and a better prognosis than adults, Acta Paediatr. 109 (6) (2020) 1088–1095.
[65] H. Zhu, L. Wang, C. Fang, S. Peng, et al., Clinical analysis of 10 neonates born to mothers with 2019-nCoV pneumonia, Transl. Pediatr. 9 (1) (2020) 51.
[66] G. Mor, I. Cardenas, The immune system in pregnancy: a unique complexity, Am. J. Reprod. Immunol. 63 (6) (2010) 425–433.
[67] G. Mor, V. Abrahams, Immunology of Implantation, W.B. Saunders Company, Philadelphia, 2002.
[68] R. Romero, J. Espinoza, L. Goncalves, J. Kusanovic, et al., Inflammation in preterm and term labour and delivery, Semin. Fetal Neonatal Med. 11 (2006) 317–326.
[69] A. Zenclussen, CD4(+) CD25(+) T regulatory cells in murine pregnancy, J. Reprod. Immunol. 65 (2005) 101–110.
[70] A. King, Y. Loke, G. Chaouat, NK cells and reproduction, Immunol. Today 18 (1997) 64–66.
[71] G. Mor, S. Straszewski-Chavez, V. Abrahams, Macrophage–trophoblast interactions, Methods Mol. Med. 122 (2006) 149–163.
[72] J. Greenwood, K. Minhas, J. di Santo, M. Makita, et al., Ultrastructural studies of implantation sites from mice deficient in uterine natural killer cells, Placenta 21 (2000) 693–702.
[73] V. Abrahams, Y. Kim, S. Straszewski, R. Romero, et al., Macrophages and apoptotic cell clearance during pregnancy, Am. J. Reprod. Immunol. 51 (2004) 275–282.
[74] S. Blois, J. Ilarregui, M. Tometten, M. Garcia, et al., A pivotal role for galectin-1 in fetomaternal tolerance, Nat. Med. 13 (2007) 1450–1457.
[75] L. Wicherek, P. Basta, K. Pityński, P. Marianowski, et al., The characterization of the subpopulation of suppressive B7H4(+) macrophages and the subpopulation of CD25(+) CD4(+) and FOXP3(+) regulatory T-cells in decidua during the secretory cycle phase, Arias Stella reaction, and spontaneous abortion – a preliminary report, Am. J. Reprod. Immunol. 61 (2009) 303–312.
[76] H. Liu, L. Wang, S. Zhao, J. Kwak-Kim, et al., Why are pregnant women susceptible to COVID-19? An immunological viewpoint, J. Reprod. Immunol. 139 (2020).
[77] W. Meijer, A. Wensing, H. Bruinse, P. Nikkels, High rate of chronic villitis in placentas of pregnancies complicated by influenza A/H1N1 infection, Infect. Dis. Obstet. Gynecol. 2014 (2014), 768380, https://doi.org/10.1155/2014/768380, 5 pages.
[78] K. Pringle, M. Tadros, R. Callister, E. Lumbers, The expression and localization of the human placental prorenin/renin-angiotensin system throughout pregnancy: roles in trophoblast invasion and angiogenesis? Placenta 32 (2011) 956–962.
[79] G. Valdes, L. Neves, L. Anton, J. Corthorn, et al., Distribution of angiotensin-(1-7) and ACE2 in human placentas of normal and pathological pregnancies, Placenta 27 (2006).
[80] M. Li, L. Chen, J. Zhang, C.L. Xiong, X, The SARS-CoV-2 receptor ACE2 expression of maternal-fetal interface and fetal organs by single-cell transcriptome study, PLoS One 15 (4) (2020) e0230295.
[81] D. Cui, Y. Liu, C. Ding, L. Poon, et al., Single-cell RNA expression profiling of ACE2 and TMPRSS2 in the human trophectoderm and placenta, Ultrasound Obstet. Gynecol. 57 (2) (2020) 248–256.
[82] N. Ashary, A. Bhide, P. Chakraborty, S. Colaco, et al., Single-cell RNA-seq identifies cell subsets in human placenta that highly expresses factors driving pathogenesis of SARS-CoV-2, Front. Cell Dev. Biol. 8 (2020).
[83] S. Komine-Aizawa, K. Takada, S. Hayakawa, Placental barrier against COVID-19, Placenta 99 (2020) 45–49.
[84] C. Ziegler, S. Allon, N. Nyquist, I. Mbano, et al., SARS-CoV-2 receptor ACE2 is an interferon-stimulated gene in human airway epithelial cells and is detected in specific cell subsets across tissues, Cell 181 (5) (2020) 1016–1035.
[85] T. Wegmann, H. Lin, L. Guilbert, T. Mosmann, Bidirectional cytokine interactions in the maternal-fetal relationship: is successful pregnancy a TH2 phenomenon? Immunol. Today 14 (7) (1993) 353–356.
[86] A. Lu-Culligan, A. Chavan, P. Vijayakumar, L. Irshaid, *et al.*, SARS-CoV-2 infection in pregnancy is associated with robust inflammatory response at the maternal-fetal interface, medRxiv (2021).

[87] C. Qin, L. Zhou, Z. Hu, S. Zhang, et al., Dysregulation of immune response in patients with coronavirus 2019 (COVID-19) in Wuhan, China, Clin. Infect. Dis. 71 (15) (2020) 762–768.
[88] X. Cao, COVID-19: immunopathology and its implications for therapy, Nat. Rev. Immunol. 20 (5) (2020) 269–270.
[89] G. Boog, Chronic villitis of unknown etiology, Eur. J. Obstet. Gynecol. Reprod. Biol. 136 (2008) 9–15.
[90] Y.P. Wong, T.Y. Khong, G.C. Tan, The effects of COVID-19 on placenta and pregnancy: what do we know so far? Diagnostics 11 (1) (2021) 94.
[91] M. Bohn, T. Loh, C. Wang, R. Mueller, et al., IFCC interim guidelines on serological testing of antibodies against SARS-CoV-2, Clin. Chem. Lab. Med. 58 (12) (2020) 2001–2008.
[92] H. Ben-Hur, P. Gurevich, A.A. Elhayany, I, D. Schneider, *et al.*, Transport of maternal immunoglobulins through the human placental barrier in normal pregnancy and during inflammation, Int. J. Mol. Med. 16(3) (2005) 401–407.
[93] D. Flannery, S. Gouma, M. Dhudasia, S. Mukhopadhyay, et al., Assessment of maternal and neonatal cord blood SARS-CoV-2 antibodies and placental transfer ratios, JAMA Pediatr. 175 (6) (2021) 594–600.
[94] D. Kimberlin, S. Stagno, Can SARS-CoV-2 infection be acquired in utero?: more definitive evidence is needed, Jama 323 (18) (2020) 1788–1789.
[95] N. Jaiswal, M. Puri, K. Agarwal, S. Singh, et al., COVID-19 as an independent risk factor for subclinical placental dysfunction, Eur. J. Obstet. Gynecol. Reprod. Biol. 259 (2021) 7–11.
[96] J. Sanchez, P. Vigil-De Gracia, E. Guerrero, M. Gaitán, et al., Severe acute respiratory syndrome coronavirus 2 detected in placentas of 2 coronavirus disease 2019–positive asymptomatic pregnant women—case report, AJOG Global Reports 1 (1) (2021), 100001.
[97] M. Kirtsman, Y. Diambomba, S. Poutanen, A. Malinowski, et al., Probable congenital SARS-CoV-2 infection in a neonate born to a woman with active SARS-CoV-2 infection, Cmaj 192 (24) (2020) E647–E650.
[98] L. Carsana, A. Sonzogni, A. Nasr, R.S. Rossi, et al., Pulmonary post-mortem findings in a series of COVID-19 cases from northern Italy: a two-centre descriptive study, Lancet Infect. Dis. 20 (10) (2020) 1135–1140.
[99] S. Wong, K. Chow, T. Leung, W. Ng, et al., Pregnancy and perinatal outcomes of women with severe acute respiratory syndrome, Am. J. Obstet. Gynecol. 191 (2004).
[100] J. Tseng, Potential implications of SARS-CoV-2 on pregnancy, Taiwan. J. Obstet. Gynecol. 59 (2020) 464–465.
[101] S. Fisher, O. Genbacev, E. Maidji, L. Pereira, Human cytomegalovirus infection of placental cytotrophoblasts in vitro and in utero: implications for transmission and pathogenesis, J. Virol. 74 (2000) 6808–6820.
[102] C. Winkler, T. Woods, R. Rosenke, D. Scott, et al., Sexual and vertical transmission of Zika virus in antiinterferon receptor-treated Rag1-deficient mice, Sci. Rep. 7 (2017).
[103] A. Hirsch, V. Roberts, P. Grigsby, N.S. Haese, MC, et al., Zika virus infection in pregnant rhesus macaques causes placental dysfunction and immunopathology, Nat. Commun. 9 (2018) 263.
[104] W. Ng, S. Wong, A. Lam, Y. Mak, et al., The placentas of patients with severe acute respiratory syndrome: a pathophysiological evaluation, Pathology 38 (3) (2006) 210–218.
[105] L. Pereira, Congenital viral infection: traversing the uterine-placental interface, annual review of virology 5 (2018) 273–299.
[106] J. Robbins, A. Bakardjiev, Pathogens and the placental fortress, Curr. Opin. Microbiol. 15 (2012) 36–43.
[107] O. Celik, A. Saglam, B. Baysal, Derwig, *et al.*, Factors preventing materno-fetal transmission of SARSCoV- 2, Placenta (2020).
[108] A. Kotlyar, O. Grechukhina, A. Chen, S. Popkhadze, et al., Vertical transmission of COVID-19: a systematic review and meta-analysis, Am. J. Obstet. Gynecol. 224 (1) (2020) 35–53.
[109] M.Y. Valdespino-Vázquez, C.A. Helguera-Repetto, M. León-Juárez, O. Villavicencio-Carrisoza, et al., Fetal and placental infection with SARS-CoV-2 in early pregnancy, J. Med. Virol. 93 (7) (2021) 4480–4487.
[110] H. Zeng, C. Xu, J. Fan, Y. Tang, et al., Antibodies in infants born to mothers with COVID-19 pneumonia, Jama 323 (18) (2020) 1848–1849.
[111] L. Patanè, D. Morotti, M. Giunta, C. Sigismondi, et al., Vertical transmission of COVID-19: SARS-CoV-2 RNA on the fetal side of the placenta in pregnancies with COVID-19 positive mothers and neonates at birth, Am. J. Obstet. Gynecol. 2 (3) (2020) 100145.
[112] S. Wang, L. Guo, L. Chen, W. Liu, et al., A case report of neonatal COVID-19 infection in China, Clin. Infect. Dis. 71 (15) (2020) 853–857.
[113] C. Penfield, S. Brubaker, M. Limaye, J. Lighter, et al., Detection of SARS-COV-2 in placental and fetal membrane samples, Am. J. Obstet. Gynecol. 2 (3) (2020) 100133.
[114] R. Gajbhiye, D. Modi, S. Mahale, Pregnancy outcomes, newborn complications and maternal-fetal transmission of SARS-CoV-2 in women with COVID-19: a systematic review, medRxiv (2020), https://doi.org/10.1101/2020.04.11.20062356.
[115] E. Taglauer, Y. Benarroch, K. Rop, E. Barnett, et al., Consistent localization of SARS-CoV-2 spike glycoprotein and ACE2 over TMPRSS2 predominance in placental villi of 15 COVID-19 positive maternal-fetal dyads, Placenta 100 (2020) 69–74.
[116] P. Cui, Z. Chen, T. Wang, J. Dai, et al., Severe acute respiratory syndrome coronavirus 2 detection in the female lower genital tract, Obstet. Gynecol. 223 (1) (2020) 131–134.
[117] L. Qui, X. Liu, M. Xiao, J. Xie, et al., SARS CoV 2 is not detectable in the vaginal fluid of women with severe COVID 19 infection, Clin. Infect. Dis. 71 (15) (2020) 813–817.
[118] L. Dong, J. Tian, S. He, C. Zhu, et al., Possible vertical transmission of SARS-CoV-2 from an infected mother to her newborn, Jama 323 (18) (2020) 1846–1848.
[119] A. Lamouroux, T. Attie-Bitach, J. Martinovic, M. Leruez-Ville, et al., Evidence for and against vertical transmission for severe acute respiratory syndrome coronavirus 2, Am. J. Obstet. Gynecol. 223 (1) (2020) 91.e1–91.e4.
[120] P. Karami, M. Naghavi, A. Feyzi, M. Aghamohammadi, et al., Mortality of a pregnant patient diagnosed with COVID-19: a case report with clinical, radiological, and histopathological findings, Travel Med. Infect. Dis. (2020), https://doi.org/10.1016/j.tmaid.2020.101665.
[121] H. Chen, J. Guo, C. Wang, F. Luo, et al., Clinical characteristics and intrauterine vertical transmission potential of COVID-19 infection in nine pregnant women: a retrospective review of medical records, Lancet 395 (2020) 809–815.
[122] H. Zhu, et al., Clinical analysis of 10 neonates born to mothers with 2019-nCoV pneumonia, Transl Pediatr 9 (2020) 51–60.
[123] L. Chen, Q. Li, D. Zheng, H. Jiang, et al., Clinical characteristics of pregnant women with Covid-19 in Wuhan, China, N. Engl. J. Med. 382 (25) (2020), e100.
[124] E. Mullins, D. Evans, R. Viner, P. O'Brien, et al., Coronavirus in pregnancy and delivery: rapid review, Ultrasound Obstet. Gynecol. 55 (5) (2020) 586–592.
[125] S. Chawanpaiboon, J. Vogel, A. Moller, P. Lumbiganon, et al., Global, regional, and national estimates of levels of preterm birth in 2014: a systematic review and modelling analysis, Lancet Glob. Health 7 (1) (2019) 37–46.
[126] M. Delahoy, M. Whitaker, A. O'Halloran, S. Chai, et al., Characteristics and maternal and birth outcomes of hospitalized pregnant women with laboratory-confirmed COVID-19 — COVID-NET, 13 states, March 1–August 22, 2020, MMWR Morb. Mortal. Wkly Rep. 69 (2020) 1347–1354.
[127] D. Hoyert, E. Gregory, Cause of fetal death: data from the fetal death report, 2014, in: National Vital Statistics Reports, National Centre for Health Statistics, Hyattsville, MD, 2016.
[128] D. Baud, G. Greub, G. Favre, C. Gengler, et al., Second-trimester miscarriage in a pregnant woman with SARS-CoV-2 infection, Jama 323 (21) (2020) 2198–2200.
[129] E. Shanes, L. Mithal, S. Otero, H. Azad, et al., Placental pathology in COVID-19, Am. J. Clin. Pathol. 154 (1) (2020) 23–32.
[130] R. Richtmann, M. Torloni, A. Otani, J. Levi, et al., Fetal deaths in pregnancies with SARS-CoV-2 infection in Brazil: a case series, Case Reports in Women's Health 27 (2020), e00243.
[131] T. Poisson, G. Pierone, Placental pathology and fetal demise at 35 weeks of gestation in a woman with SARS-CoV-2 infection: a case report, Case Reports in Women's Health (2021), e00289, https://doi.org/10.1016/j.crwh.2021.e00289.
[132] for Centers, Control Disease, et al., Coronavirus Disease (COVID-19) and Breastfeeding, Available online, https://www.cdc.gov/breastfeeding/breastfeeding-special-circumstances/maternal-or-infant-illnesses/covid-19-and-breastfeeding.html.
[133] X. Wang, Z. Zhou, J. Zhang, F. Zhu, et al., A case of 2019 novel coronavirus in a pregnant woman with preterm delivery, Clin. Infect. Dis. 71 (15) (2020) 844–846.
[134] H. Zhu, L. Wang, C. Fang, S. Peng, L. Zhang, G. Chang, S. Xia, W. Zhou, Clinical analysis of 10 neonates born to mothers with 2019-nCoV pneumonia, Transl. Pediatr. 9 (1) (2020) 51.
[135] C. Robertson, S. Lowther, T. Birch, C. Tan, et al., SARS and pregnancy: a case report, Emerg. Infect. Dis. 10 (2004) 345–348.
[136] Y. Wu, C. Liu, L. Dong, C. Zhang, et al., Coronavirus disease 2019 among pregnant Chinese women: case series data on the safety of vaginal birth and breastfeeding, BJOG 127 (2020) 1109–1115.
[137] A. Hinojosa-Velasco, P. de Oca, L. García-Sosa, J. Mendoza-Durán, et al., A case report of newborn infant with severe COVID-19 in Mexico: detection of SARS-Cov-2 in human breast milk and stool, IJID 100 (2020) 21–24.
[138] A. Bastug, A. Hanifehnezhad, C. Tayman, A. Ozkul, et al., Virolactia in an asymptomatic mother with COVID-19, Breastfeed. Med. 15 (2020) 488–491.
[139] J.T.-R. Teo, N.H. Abidin, F.-C. Cheah, Severe acute respiratory syndrome-coronavirus-2 infection: a review of the clinical-pathological correlations of coronavirus disease-19 in children, Malays. J. Pathol. 42 (3) (2020) 349–361.