Case Report

Treatment of vertical maxillary excess without open bite in a skeletal Class II hyperdivergent patient

Cheol-Ho Paik[a]; Hong-Sik Park[b]; Hyo-Won Ahn[c]

ABSTRACT

A 20-year-old woman visited the office complaining of a gummy smile and lip protrusion. She was diagnosed with vertical maxillary excess without open bite and skeletal Class II hyperdivergent pattern. She refused the surgical-orthodontic treatment option, although she wanted to correct the gummy smile and retruded chin. Differential intrusion of anterior and posterior teeth in both arches was necessary to maximize the skeletal treatment effects. In the maxilla, one palatal temporary anchorage device (TAD), an archwire with an accentuated curve of Spee, and a transpalatal arch were applied. In the mandible, an archwire with a reverse curve of Spee and two vertically positioned TADs were used. These simple mechanics contributed to the effective intrusion of the total upper and lower arches, correction of the gummy smile, and mandibular counterclockwise rotation, offering an alternative to orthognathic surgery for this patient. (*Angle Orthod.* 2017;87:625–633)

KEY WORDS: Vertical maxillary excess; Entire arch intrusion; Hyperdivergent; Temporary anchorage device

INTRODUCTION

A gummy smile caused by vertical maxillary excess (VME) cannot be treated satisfactorily with adjunctive surgical approaches such as botulinum toxin injection or a crown lengthening procedure. An ideal treatment option for VME is the reduction of the maxillary vertical dimension by LeFort I osteotomy.[1,2] Some orthopedic appliances, such as high-pull headgear[3] or vertical chin cup,[4] have been suggested as substitutes for orthognathic surgery, but their indications have been limited to young growing patients and their success relies on patient compliance. Recently, temporary anchorage devices (TADs) have been widely used to correct a gummy smile.[5–10]

Clinically, VME is classified according to the presence of anterior open bite. When a patient has VME with anterior open bite, intrusion of the posterior teeth is an important component of treatment. Upper molar intrusion induces counterclockwise rotation of the mandible, thus improving the convex profile. A patient having VME with normal overbite should be treated by intrusion of the total maxillary arch. Only molar intrusion could result in a posterior open bite with traumatic effects on the anterior teeth. Several cases have been reported for entire maxillary intrusion using TADs. However, they have limited clinical application because of attributes such as too many screws[5,6] or complicated design,[7] insufficient amount of attainable intrusion,[8] or additional surgical procedures required for installation on the zygomatic buttress[9] or near the anterior nasal spine.[9,10]

In the case of VME without anterior open bite, intrusion of both entire arches could maximize the orthodontic treatment effects. Vertical control of the mandibular arch is important because the lower teeth often extrude spontaneously while the maxillary teeth are intruded successfully.[7,9,11] Clinicians should plan the amount of intrusion in both dental arches, titrating the amount of anterior and posterior intrusion based on

[a] Clinical Faculty, Department of Orthodontics, School of Dentistry, Seoul National University, Seoul, Korea; and Clinical Faculty, Department of Orthodontics, Kyung Hee University School of Dentistry, Seoul, Korea.

[b] Graduate Student, Department of Dentistry, Graduate School, Kyung Hee University, Seoul, Korea.

[c] Assistant Professor, Department of Orthodontics, Kyung Hee University School of Dentistry, Seoul, Korea.

Corresponding author: Dr Hyo-Won Ahn, Department of Orthodontics, Kyung Hee University School of Dentistry, Kyung Hee Dae-ro 23, Dongdaemun-Gu, Seoul, 02447, Korea
(e-mail: hyowon@khu.ac.kr)

Accepted: January 2017. Submitted: October 2016.
Published Online: March 20, 2017

© 2017 by The EH Angle Education and Research Foundation, Inc.

Figure 1. Pretreatment facial and intraoral photographs.

the rotation of the mandible and advancement of the pogonion desired.

This case report presents simple and effective mechanics for the treatment of vertical maxillary excess with normal overbite in a patient with a hyperdivergent skeletal Class II malocclusion by intrusion of both entire arches using TADs. Patient consent and release was obtained for this presentation.

CASE REPORT

Diagnosis and Etiology

A 20-year-old woman visited our office with a chief complaint of lip protrusion and gummy smile. The patient was mesoprosopic and had a convex profile with a retruded chin. There was excessive gingival display when smiling and incompetent lips. Her dental midline was coincident with the facial midline. There was no significant facial asymmetry. She had no signs or symptoms of temporomandibular disorder. Intraorally, she had a Class III molar relationship, shallow overbite, and mild anterior crowding in both arches. Overjet and overbite were +3.0 mm and +2.0 mm, respectively (Figure 1).

The panoramic radiograph showed no pathology (Figure 2). The lateral cephalometric analysis indicated a skeletal Class II (ANB, 3.5°) with retruded mandible (N per to Pog, −4.5 mm), and hyperdivergent vertical pattern (PFH/AFH, 59.5%; MP-FH, 32.7°). The maxillary incisors were slightly proclined and the inclination of the mandibular incisors was within the normal range (U1 to FH, 120.7°; IMPA, 90.0°). Vertical maxillary excess was evident in both the anterior and posterior dentition (U1-PP, 36.9 mm; U6-PP, 27.9 mm). Maxillary central incisor exposure at rest was relatively excessive (U1 to stomion, 4.8 mm). The occlusal plane angle was within the normal range (OP to FH, 12.8°). In addition, the mandibular vertical height was also longer than normal (L1 to mandibular plane, 47.7 mm; L6 to mandibular plane, 37.0 mm; Table 1).

Treatment Objectives

The following treatment objectives were established: (1) to reduce excessive gingival display,

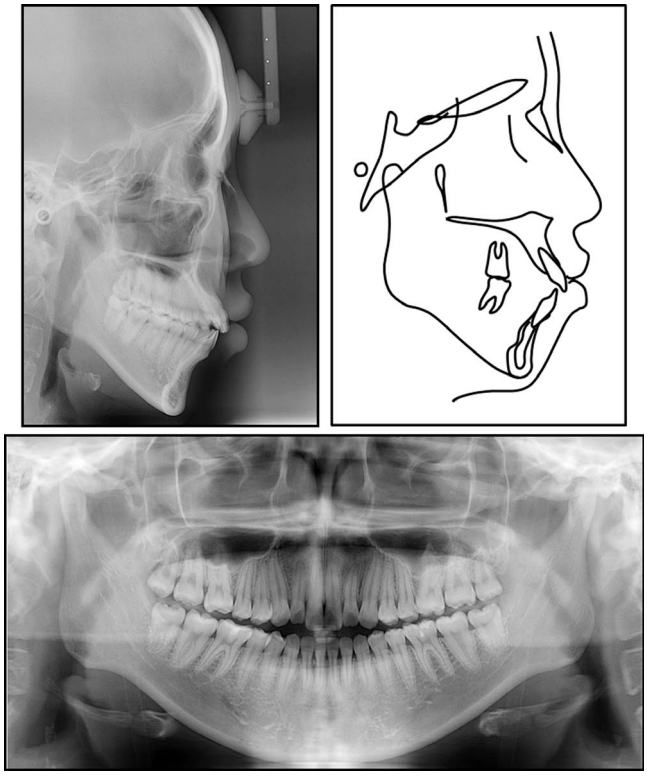

Figure 2. Pretreatment records: lateral cephalogram, cephalometric tracing, and panoramic radiograph.

(2) to improve her facial profile and achieve a competent lip seal, and (3) to achieve functional Class I occlusion with normal overjet and overbite.

Treatment Alternatives

Two treatment options were considered for the patient to reduce vertical maxillary excess: (1) surgical orthodontic treatment, which could relieve vertical maxillary excess and protrusion efficiently with superior and posterior movement of the maxilla by LeFort I osteotomy; In addition, favorable facial profile changes could be achieved by advancement and counterclockwise rotation of the mandible; and (2) nonsurgical orthodontic treatment with extraction of the upper and lower first premolars combined with TADs for total dentition intrusion. To improve lip protrusion, maxillary incisors would be retracted by maximum anchorage. For gummy smile correction, while maintaining the physiological occlusal plane, the entire maxillary dentition needed to be intruded by 3 mm anteriorly and 2 mm posteriorly. To maximize the counterclockwise rotation of the mandible, intrusion of mandibular incisors and first molars by 2 mm and 5 mm, respectively, was required. Because the patient refused surgical treatment, the second option was selected.

Treatment Progress

Before orthodontic treatment, the maxillary and mandibular first premolars were extracted. Conventional edgewise appliances (0.022 × 0.028 inches) were placed on the anterior teeth. For low-friction space closure, the posterior teeth were bonded and banded with passive self-ligating brackets and tubes.[12] Furthermore, a 1.0-mm-diameter, banded transpalatal

Table 1. Cephalometric Measurements at Pretreatment, Posttreatment, and Postretention

Measurement	Korean Female Norm	Pretreatment	Posttreatment	Postretention
Skeletal (anteroposterior)				
SNA, °	81.6	81	80.5	80.5
N perp-point A, mm	0.9	1.5	1.3	1.3
SNB, °	79.2	77.5	79.2	78.9
N perp-Pog, mm	−2	−4.5	−1.5	−2
ANB, °	2.5	3.5	1.8	2.1
Skeletal (vertical)				
SUM, °	393.3	402.7	401.5	401.3
PFHAFH, %	66.8	59.5	60.5	60.2
OP-FH, °	8.8	12.8	13	14.2
MP-FH, °	24.3	32.7	30.6	31.1
Dentoalveolar				
Interincisal angle, °	123.8	117.8	143	144.3
U1-FH, °	116	120.7	111	107.7
IMPA, °	95.9	90	77.8	77.8
U6-palatal plane, mm	24.8	27.9	26	26.4
U1-palatal plane, mm	28.5	36.9	34.1	35.2
U1 exposure, mm	2.0	4.8	2	3.1
L6-MP, mm	34.0	37	35.6	35.4
L1-MP, mm	42.6	47.7	43.5	44.2
Soft tissue				
Upper lip to E-plane	−0.9	3.2	−1.2	−0.8
Lower lip to E-plane	0.6	8.3	1	2

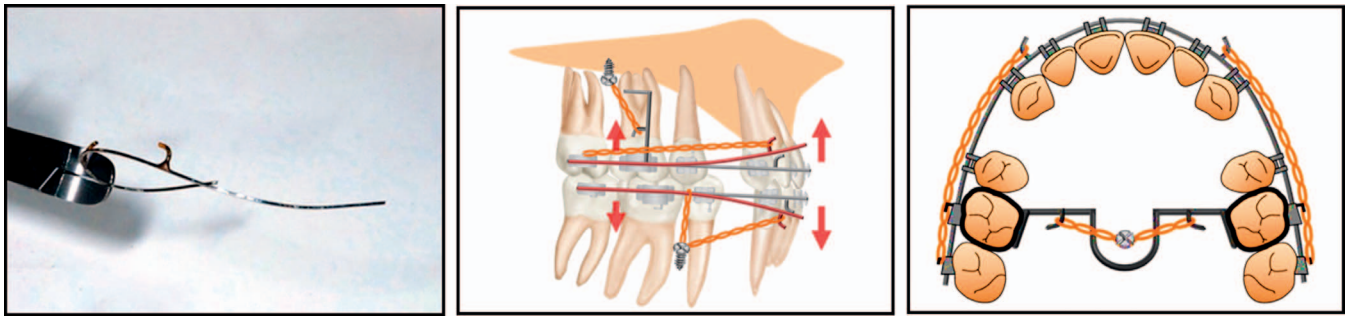

Figure 3. Accentuated and reverse curve of Spee on the maxillary and mandibular archwires, respectively. Upper and lower entire dentition are intruding using temporary anchorage devices (TADs).

arch was placed on the maxillary first molars, 3 mm away from the palatal mucosa, to allow for molar intrusion and to stabilize the transverse width.

After alignment and leveling, simultaneous retraction and intrusion of both arches was performed. In the maxilla, one TAD was inserted on the midpalatal area (diameter, 1.5 mm; length, 6.0 mm; Biomaterials, Seoul, Korea) for intrusion of the entire upper dentition. An 0.019 × 0.025-inch stainless-steel wire with an accentuated curve of Spee was inserted. The elastomeric chain was placed between hooks of the transpalatal arch and the midpalatal TAD. Retraction force was applied from the hooks on the archwire to the maxillary second molars bilaterally for maximum anchorage. In the mandible, TADs were inserted bilaterally between the second premolars and first molars (diameter, 1.3 mm; length, 6.5 mm; Biomaterials). To enhance intrusion more in the anterior than the posterior, the miniscrews were installed more mesially. In a case with anterior open bite, the miniscrew insertion site should move more toward the posterior area. An 0.019 × 0.025-inch stainless-steel wire with a reverse curve of Spee was inserted. Lingual crown torque was added to the lower archwire to prevent buccal tipping of the molars. Then, elastomeric thread (Power Thread™, Ormco, Orange, Calif) exerting 200-g force was tied with complete knots from the anterior teeth to the TADs for retraction and intrusion (Figures 3 and 4).

After 22 months of active orthodontic treatment, the extraction space was completely closed, and the brackets and TADs were removed. Immediately after debonding, wrap-around–type retainers and lingual bonded retainers from canine to canine in both arches were applied.

Treatment Results

The posttreatment records show that the treatment objectives were achieved successfully. The facial

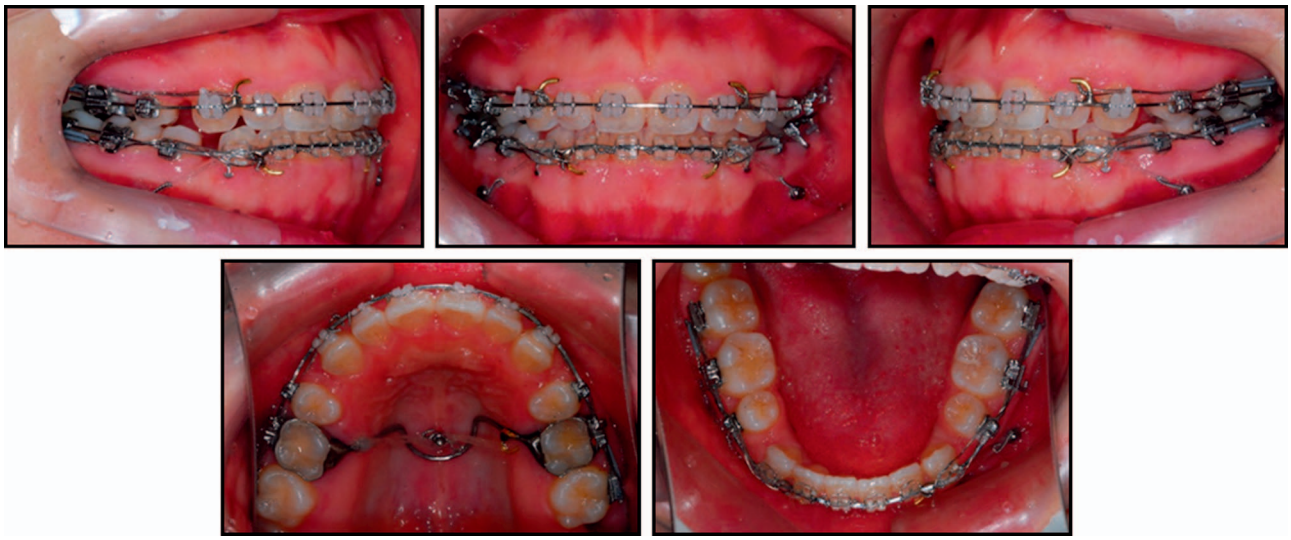

Figure 4. Intraoral photographs during active treatment: After 10 months of treatment, a banded transpalatal arch was placed on the maxillary first molars. Temporary anchorage devices (TADs) were inserted in the midpalatal area and between the mandibular second premolars and first molars on both sides. Maxillary and mandibular intrusion forces were applied.

Figure 5. Posttreatment facial and intraoral photographs.

profile was improved. Lip competence and an esthetic smile were observed (Figure 5). The posttreatment panoramic radiograph showed complete space closure and acceptable root parallelism in both arches with no significant root resorption (Figure 6). The posttreatment lateral cephalometric analysis and superimposition showed that the maxillary anterior and posterior teeth were intruded by 2.8 mm and 1.9 mm, respectively (Figure 7). In the mandible, the anterior and posterior teeth were intruded by 4.2 mm and 1.4 mm, respectively. The maxillary and mandibular incisors were retracted using maximum anchorage. As a result of the intrusion of all teeth in both arches, the mandible rotated counterclockwise (2.1°) and pogonion came forward by 3.0 mm.

After a 1-year retention period, the occlusion and facial profile were well maintained (Figure 8). Superimposition between the posttreatment and postretention images showed a slight extrusion of the upper and lower incisors resulting in increased overbite. There was little change in the position of the upper and lower first molars. (Figures 9 and 10; Table 1).

DISCUSSION

Orthodontic treatment of VME without anterior open bite is a challenging problem and much more difficult to treat than when combined with anterior open bite. Molar intrusion causes counterclockwise rotation of the mandible; thus, anterior open bite is corrected automatically.[13–16] On the other hand, a greater amount of intrusion of the anterior teeth than posterior teeth should be considered for treatment of VME with normal overbite. For that reason, previous case reports on patients with a gummy smile and retruded mandible showed multiple miniscrews[5,6] or bulky devices[7] for intrusion of the entire maxillary dentition. Hong et al.[7] introduced a midpalatal anchorage system for posterior-superior movement of the maxillary dentition. It included one miniscrew connected with four power arms. Lin et al.[5] and Wang et al.[17] used five to six miniscrews on the buccal or palatal side or both sides for intrusion and retraction of the anterior teeth. In addition, some articles[7,18] reported cases with a gummy smile in which autorotation of the mandible did not occur as planned because simultaneous extrusion of the mandibular molar had occurred.

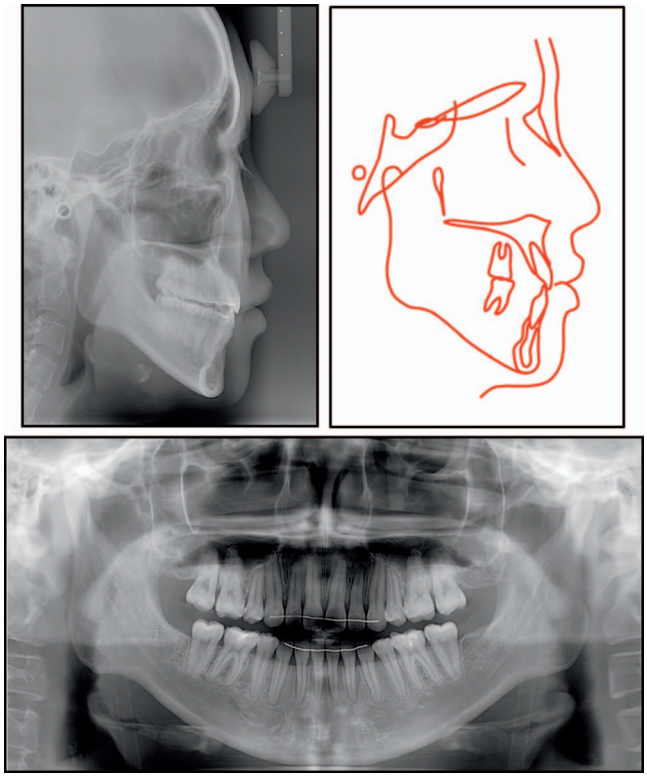

Figure 6. Posttreatment records: lateral cephalogram, cephalometric tracing, and panoramic radiograph.

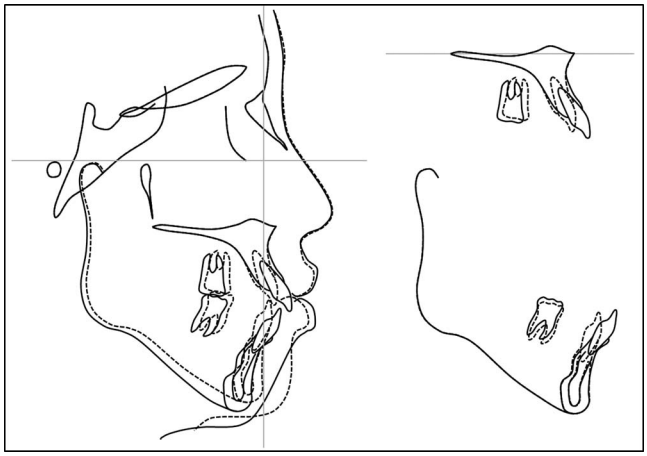

Figure 7. Cephalometric superimpositions between the pretreatment (solid lines) and posttreatment stages (dashed lines): overall, maxilla, and mandible.

When formulating the treatment plan, an important factor to be considered is which teeth should be intruded. Accurate and quantitative treatment goals regarding intrusion and rotation of the mandible should be set before starting treatment. In a patient with skeletal Class II hyperdivergence and a retruded mandible, both upper and lower arch intrusion are essential to obtaining significant skeletal change. If intrusion is performed in the maxillary arch only, compensatory extrusion of the lower molars often negates the ability of the mandible to autorotate. Lin et al.[5,19,20] also reported several cases in which the molars of both arches were intruded and facial profile was improved as a result of mandibular rotation. For intrusion of the maxillary dentition, the following factors should be considered: upper incisor exposure, smile arc, and steepness of the occlusal plane. Maxillary incisor exposure at rest and during smiling determines the amount of intrusion desirable for the anterior teeth. The steepness of the occlusal plane affects the final vertical position of the molars. Smile arc is a good clinical indicator of occlusal plane steepness. In a flat or reverse smile arc, more intrusion of the posterior teeth would be considered favorable for improving smile arc consonance.[21] In the mandible, the amount of intrusion of the anterior and posterior teeth can be determined by the amount of advancement of pogonion preferred. The condyle was considered in this case as the center of rotation of the mandible in establishing the VTO (visual treatment objective).[22] It has been postulated[23] that every 1-mm intrusion of the molars results in about 3 mm of bite closure by means of counterclockwise mandibular rotation. However, careful monitoring is necessary during actual treatment because the center of rotation during mandibular autorotation was reported[24] to show large individual variation.

Paik et al.[16,25,26] introduced simple intrusion mechanics using an archwire incorporating a curve of Spee, conventional transpalatal arch, and miniscrew in the midpalatal area. Since vertical correction was achieved successfully, with an outcome similar to that observed following LeFort I maxillary impaction, they called the procedure "slow impaction."[25] They kept the rigid transpalatal arch 5 mm away from the palate to allow for intrusion of the molars while preventing palatal crown inclination. A large-diameter wire for manufacturing the transpalatal arch is recommended for better torque control of the upper molars. Because the optimal intrusion force necessary on the posterior segment is greater than that required for the anterior teeth, elastomeric chain was connected directly from the miniscrew to the molars only, whereas the anterior segment was effectively intruded by the archwire alone.

If differential intrusion is planned on patients with vertical right-left asymmetries, more intrusion on the excessively erupted side may be achieved by unilateral application of the elastomeric chain on the transpalatal arch hook.[26] Another possible modification to the transpalatal arch may be the anteroposterior position of the transpalatal arch hook and palatal miniscrew, which can affect molar angulation and occlusal plane

Figure 8. Postretention facial and intraoral photographs.

steepness changes. Application of an intrusive force mesial to the center of resistance of the first molars would result in mesial tipping, thereby flattening the occlusal plane and resulting in increased intrusion of the anterior teeth. When intrusion force is applied more distally, a steeper occlusal plane and increased intrusion of the posteriors would be expected. In the present patient, we tried to apply the force through the center of resistance to maintain the occlusal plane and molar angulation.

Regarding posttreatment stability after molar intrusion, previous reports[6,27,28] suggest relapse rates of between 10% and 30%. Sugawara et al.[28] reported that the average relapse rates were 27.2% at the first molars and 30.3% at the second molars. Baek et al.[6] found that the extent of relapse was not related to the amount of molar intrusion but rather was correlated to the amount of overbite correction. They also reported that most relapse occurred during the first year of retention. In this case, a slight relapse tendency was observed in the maxillary anterior teeth. However, the facial profile showed little change, and functional occlusion was still stable during the 1-year retention period.

CONCLUSIONS

- In this patient with vertical maxillary excess without open bite and a skeletal Class II hyperdivergent

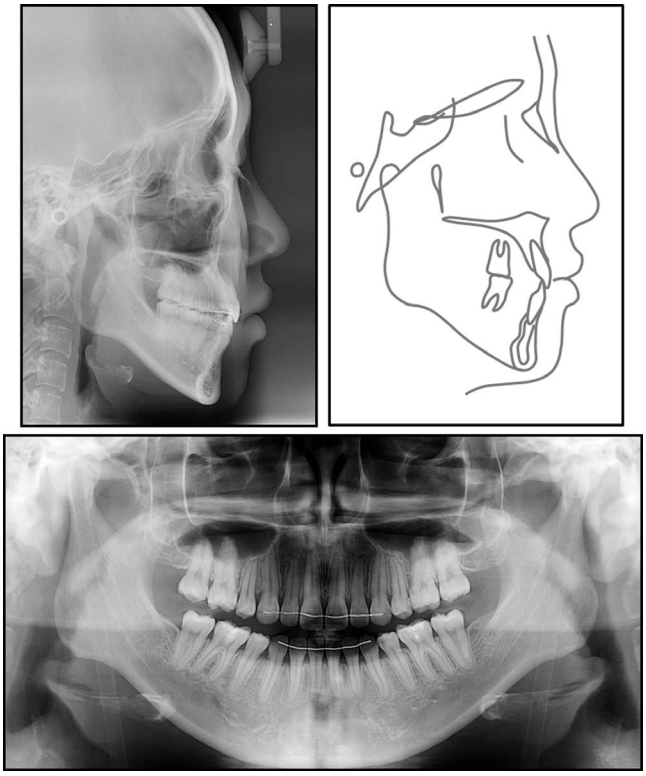

Figure 9. Postretention records: lateral cephalogram, cephalometric tracing, and panoramic radiograph.

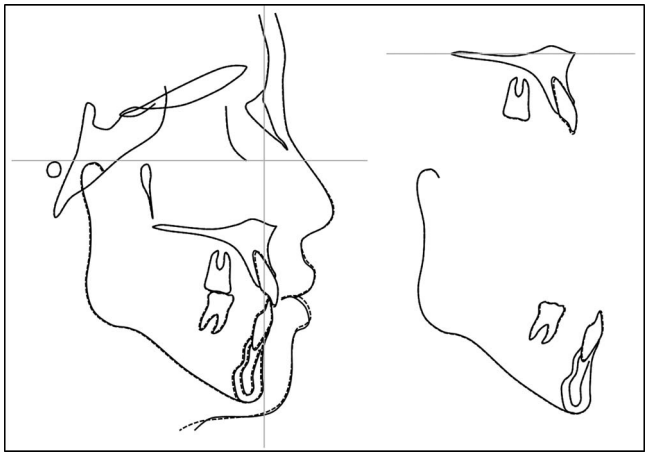

Figure 10. Cephalometric superimpositions between the posttreatment (solid lines) and postretention stages (dashed lines): overall, maxilla, and mandible.

pattern, intrusion of both entire arches and differential intrusion of the anterior and posterior teeth were achieved to maximize the skeletal treatment effects.

- The combination of archwires with an accentuated or a reverse curve of Spee, intrusion force applied to a rigid transpalatal arch, and minimal number of TADs contributed to the effective intrusion of the total arches, correction of a gummy smile, and mandibular counterclockwise rotation.

REFERENCES

1. Epker BN, Fish LC. Surgical-orthodontic correction of open-bite deformity. *Am J Orthod*. 1977;71:278–299.
2. Proffit WR, Phillips C, Dann C IV. Who seeks surgical-orthodontic treatment? *Int J Adult Orthod Orthognath Surg*. 1990;5:153–160.
3. Alexander CD. Open bite, dental alveolar protrusion, Class I malocclusion: a successful treatment result. *Am J Orthod Dentofacial Orthop*. 1999;116:494–500.
4. Beane RA. Nonsurgical management of the anterior open bite: a review of the options. *Semin Orthod*. 1999;5:275–283.
5. Lin JC, Liou EJ, Bowman SJ. Simultaneous reduction in vertical dimension and gummy smile using miniscrew anchorage. *J Clin Orthod*. 2010;44:157–170.
6. Baek MS, Choi YJ, Yu HS, Lee KJ, Kwak J, Park YC. Long-term stability of anterior open-bite treatment by intrusion of maxillary posterior teeth. *Am J Orthod Dentofacial Orthop*. 2010;138:396.
7. Hong RK, Lim SM, Heo JM, Baek SH. Orthodontic treatment of gummy smile by maxillary total intrusion with a midpalatal absolute anchorage system. *Korean J Orthod*. 2013;43:147–158.
8. Kaku M, Kojima S, Sumi H, et al. Gummy smile and facial profile correction using miniscrew anchorage. *Angle Orthod*. 2012;82:170–177.
9. Nishimura M, Sannohe M, Nagasaka H, Igarashi K, Sugawara J. Nonextraction treatment with temporary skeletal anchorage devices to correct a Class II division 2 malocclusion with excessive gingival display. *Am J Orthod Dentofacial Orthop*. 2014;145:85–94.
10. Kim TW, Kim H, Lee SJ. Correction of deep overbite and gummy smile by using a mini-implant with a segmented wire in a growing Class II division 2 patient. *Am J Orthod Dentofacial Orthop*. 2006;130:676–685.
11. Shu R, Huang L, Bai D. Adult Class II division 1 patient with severe gummy smile treated with temporary anchorage devices. *Am J Orthod Dentofacial Orthop*. 2011;140:97–105.
12. Paik CH, Ahn HW, Yang IH, Baek SH. Low-friction space closure with a hybrid bracket-tube system. *J Clin Orthod*. 2010;44:623–627.
13. Sherwood KH, Burch JG, Thompson WJ. Closing anterior open bites by intruding molars with titanium miniplate anchorage. *Am J Orthod Dentofacial Orthop*. 2002;122:593–600.
14. Erverdi N, Keles A, Nanda R. The use of skeletal anchorage in open bite treatment: a cephalometric evaluation. *Angle Orthod*. 2004;74:381–390.
15. Fukui T, Kano H, Saito I. Nonsurgical treatment of an adult with an open bite and large lower anterior facial height with edgewise appliances and temporary anchorage devices. *Am J Orthod Dentofacial Orthop*. 2016;149:889–898.
16. Paik CH, McComb R, Hong C. Differential molar intrusion with skeletal anchorage in open-bite treatment. *J Clin Orthod*. 2016;50:276–289.
17. Wang XD, Zhang JN, Liu DW, Lei FF, Zhou YH. Nonsurgical correction of a severe anterior deep overbite accompanied by a gummy smile and posterior scissor bite using a miniscrew-assisted straight-wire technique in an adult high-angle case. *Korean J Orthod*. 2016;46:253–265.
18. Kim SJ, Kim JW, Choi TH, Lee KJ. Combined use of miniscrews and continuous arch for intrusive root movement of incisors in Class II division 2 with gummy smile. *Angle Orthod*. 2014;84:910–918.
19. Lin JC, Liou EJ, Yeh CL. Intrusion of overerupted maxillary molars with miniscrew anchorage. *J Clin Orthod*. 2006;40:378–383.
20. Lin JC, Yeh CL, Liou EJ, Bowman SJ. Treatment of skeletal-origin gummy smiles with miniscrew anchorage. *J Clin Orthod*. 2008;42:285–296.
21. Sarver DM. The importance of incisor positioning in the esthetic smile: the smile arc. *Am J Orthod Dentofacial Orthop*. 2001;120:98–111.
22. Fish LC, Epker BN. Surgical-orthodontic cephalometric prediction tracing. *J Clin Orthod*. 1980;14:36–52.
23. Kuhn RJ. Control of anterior vertical dimension and proper selection of extraoral anchorage. *Angle Orthod*. 1968;38:340–349.
24. Wang YC, Ko EW, Huang CS, Chen YR. The interrelationship between mandibular autorotation and maxillary

LeFort I impaction osteotomies. *J Craniofac Surg*. 2006;17:898–904.
25. Paik CH, Woo YJ, Boyd RL. Treatment of an adult patient with vertical maxillary excess using miniscrew fixation. *J Clin Orthod*. 2003;37:423–428.
26. Paik CH, Ahn SJ, Nahm DS. Correction of Class II deep overbite and dental and skeletal asymmetry with 2 types of palatal miniscrews. *Am J Orthod Dentofacial Orthop*. 2007;131:S106–S116.
27. Lee HA, Park YC. Treatment and posttreatment changes following intrusion of maxillary posterior teeth with miniscrew implants for open bite correction. *Korean J Orthod*. 2008;38:31–40.
28. Sugawara J, Baik UB, Umemori M, et al. Treatment and posttreatment dentoalveolar changes following intrusion of mandibular molars with application of a skeletal anchorage system (SAS) for open bite correction. *Int J Adult Orthod Orthognath Surg*. 2002;17:243–253.