Since January 2020 Elsevier has created a COVID-19 resource centre with free information in English and Mandarin on the novel coronavirus COVID-19. The COVID-19 resource centre is hosted on Elsevier Connect, the company's public news and information website.

Elsevier hereby grants permission to make all its COVID-19-related research that is available on the COVID-19 resource centre - including this research content - immediately available in PubMed Central and other publicly funded repositories, such as the WHO COVID database with rights for unrestricted research re-use and analyses in any form or by any means with acknowledgement of the original source. These permissions are granted for free by Elsevier for as long as the COVID-19 resource centre remains active.

Journal of Neuroimmunology 358 (2021) 577655

Contents lists available at ScienceDirect

Journal of Neuroimmunology

journal homepage: www.elsevier.com/locate/jneuroim

Short Communication

Complex movement disorders in SARS-CoV-2 infection induced acute disseminated encephalomyelitis

Ritwik Ghosh [a], Souvik Dubey [b], Arpan Mandal [a], Biman Kanti Ray [b], Julián Benito-León [c,d,e,*]

[a] Department of General Medicine, Burdwan Medical College & Hospital, Burdwan, West Bengal, India
[b] Department of Neuromedicine, Bangur Institute of Neurosciences, Kolkata, India
[c] Department of Neurology, University Hospital "12 de Octubre", Madrid, Spain
[d] Centro de Investigación Biomédica en Red sobre Enfermedades Neurodegenerativas (CIBERNED), Madrid, Spain
[e] Department of Medicine, Complutense University, Madrid, Spain

ARTICLE INFO

Keywords:
Acute disseminated encephalomyelitis
ADEM
COVID-19
Movement disorders
SARS-CoV-2
Myoclonus

ABSTRACT

Movement disorders are extremely rare in acute disseminated encephalomyelitis (ADEM) and in the novel severe acute respiratory syndrome coronavirus (SARS-CoV-2) infection. We herein report a 34-years-old previously healthy woman who presented with a febrile illness and a constellation of movement disorders (predominantly myoclonus) followed by encephalopathy. After exclusion of common infectious, autoimmune and paraneoplastic etiologies, she was diagnosed to have COVID-19 induced ADEM, which responded to intravenous methylprednisolone and intravenous immunoglobulin. Our case adds to the tally of cases of post-SARS-CoV-2 infection related movement disorders and to the exceedingly rare list of cases in which movement disorders preceded ADEM.

1. Introduction

Acute disseminated encephalomyelitis (ADEM) is a serious autoimmune demyelinating disorder of the central nervous system (CNS) that often occurs post infectiously (Pohl et al., 2016). Multifocal neurological deficits, headache and encephalopathy usually constitute the clinical spectrum of ADEM (Pohl et al., 2016). Magnetic resonance imaging (MRI) typically demonstrates acute, ill-defined, multifocal and reversible white matter lesions with frequent involvement of basal ganglia, thalamus, brainstem and rarely of the spinal cord.[1] Early immunotherapy is the cornerstone of treatment (Pohl et al., 2016).

Movement disorders are extremely rare in acute disseminated encephalomyelitis (ADEM) (Ha and Sue, 2010; Kabakus et al., 2006; Mehanna and Jankovic, 2013; Park et al., 2016), as well as in the novel severe acute respiratory syndrome coronavirus (SARS-CoV-2) infection (Ghosh et al., 2021; Roy et al., 2021) and have not been reported in the few published cases of the coronavirus infectious disease of 2019 (COVID-19) induced ADEM (de Miranda Henriques-Souza et al., 2021; Novi et al., 2020; Parsons et al., 2020).

We herein report the case of a previously healthy woman who presented with a constellation of movement disorders (predominantly myoclonus) followed by encephalopathy. After exclusion of common infectious, autoimmune and paraneoplastic causes, she was diagnosed as a case of COVID-19 induced ADEM, which responded to immunomodulatory therapies.

2. Case report

A 34-years-old, previously healthy Asian-Indian woman was admitted to the emergency department with sudden onset generalized jerky movements involving all limbs and face, tremulousness and gait unsteadiness. Her past medical history was unremarkable. She was suffering from fever since last eight days along with severe body-ache, anorexia, weakness, headache, and decreased taste sensation. Three days prior to admission, she developed head tremor, abnormal jerk-like movements involving four limbs (mainly in upper limbs), and a tendency to sway around while walking. Her headache worsened day by day. Patient's caregivers also noticed occasional inappropriate and exaggerated startle responses to apparently normal external sounds and often to tactile stimulus. The patient's nasopharyngeal and oropharyngeal swab tests for SARS-CoV-2 by qualitative real-time reverse-transcriptase–polymerase chain-reaction (RT-PCR) were positive. On physical examination, she was fully awake, conscious, and normotensive. Respiratory rate and room-air oxygen saturation were normal.

* Corresponding author at: Department of Neurology, University Hospital "12 de Octubre", Av. de Córdoba S/N, 28041 Madrid, Spain.
E-mail address: jbenitol67@gmail.com (J. Benito-León).

https://doi.org/10.1016/j.jneuroim.2021.577655
Received 23 May 2021; Accepted 28 June 2021
Available online 30 June 2021
0165-5728/© 2021 Elsevier B.V. All rights reserved.

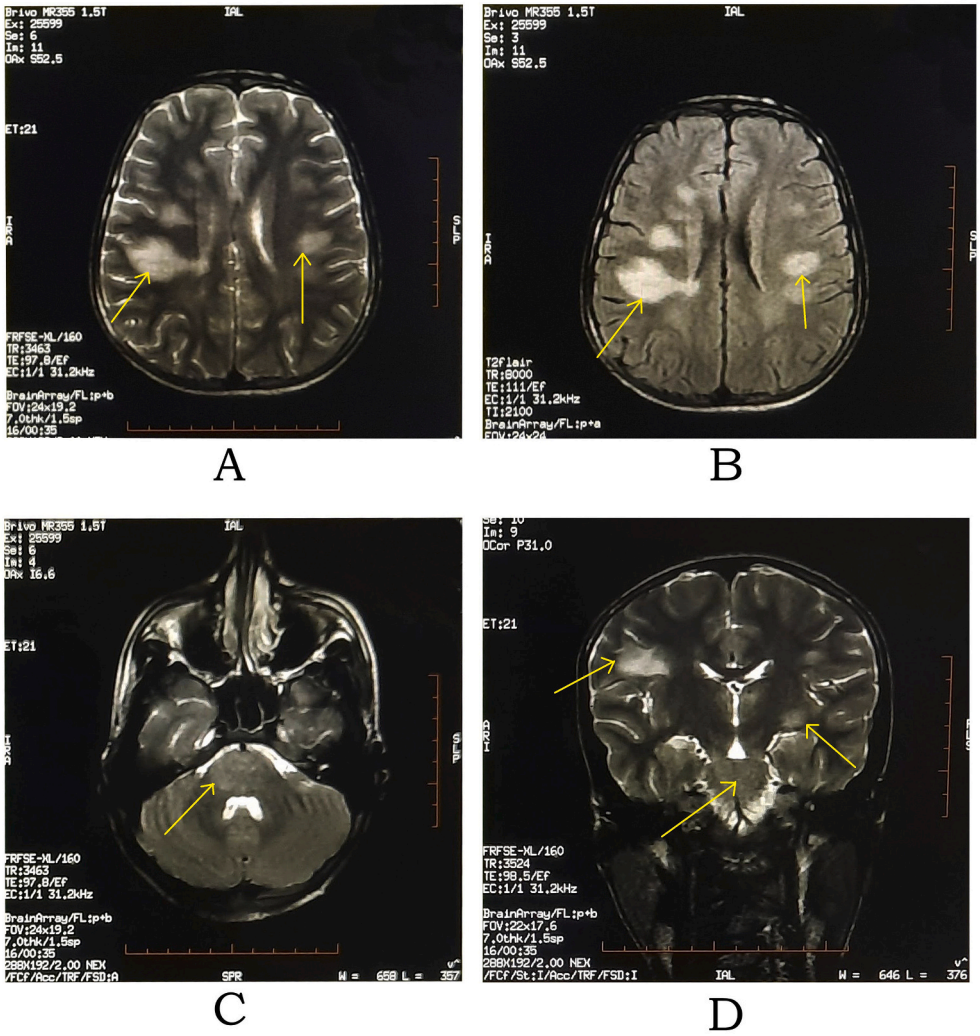

Fig. 1. Brain MRI revealing multifocal, asymmetrical hyperintense signal changes on axial-T2-weighted (A and C), coronal T2-weighted (D), and T2- FLAIR-weighted (B) images, in both fronto-parieto-occipital subcortical regions, extending up to calloso-septal junction (right> left), bilateral thalami, red nuclei and basis pontis of brainstem (all marked by yellow arrows), suggestive of acute demyelination. (For interpretation of the references to colour in this figure legend, the reader is referred to the web version of this article.)

Neurological examination revealed the presence of myoclonus (at rest, action-induced, and stimulus sensitive) involving all limbs and face, which was likely to be associated with tremor (postural and kinetic more than rest) and gait ataxia with intact cognitive functions. She was prescribed ivermectin (12 mg/d), doxycycline (200 mg/day), acetaminophen (650 mg on "as and when needed" basis) and other supportive therapies as well as clonazepam (1 mg/d) for myoclonus and propranolol (80 mg/d) for tremor. None of the symptoms improved; in fact, her headache worsened and gradually she became lethargic, mute and unresponsive to external stimuli over the next three days.

Clinical history and examination initially yielded multiple differential diagnoses including metabolic encephalopathy, viral encephalitis, post-infective autoimmune encephalitis, post-infective ADEM, metabolic encephalopathy, non-convulsive status epilepticus and neurolupus.

Metabolic encephalopathy was ruled out as complete blood cell count, thyroid, liver and kidney functions, electrolytes, arterial blood gas analysis, and HbA1C were normal. In addition, she never had an episode of hypoxia or brady-arrhythmia. Brain MRI revealed multifocal non-enhancing asymmetrical hyperintense signal changes on T2-weighted and fluid attenuated inversion recovery (FLAIR)-weighted images in both fronto-parieto-occipital subcortical regions, extending up to calloso-septal junction (right more than left), bilateral thalami, red nuclei and basis pontis of brainstem, without diffusion restriction or mass effect, suggestive of acute demyelination (Fig. 1). MRI of the spine and orbits were normal. Cerebrospinal fluid (CSF) analyses were otherwise unremarkable, but showed mildly raised protein and lymphocytic pleocytosis (89 mg/dL, cells 9/μl, all lymphocytes), as well as raised intrathecal IgG synthesis. An electroencephalogram ruled out possibility of ongoing non-convulsive status epilepticus.

Differential diagnoses based upon clinic-radiological evidences included post-infective ADEM, post-infective autoimmune encephalitis, AQP-4-antibody-positive astrocytopathy, myelin oligodendrocyte glycoprotein (MOG)-antibody-positive inflammatory demyelinating disease, neurolupus, and CNS vasculitis. CSF and paired sera were tested for relevant viral (including HIV), bacterial and parasitic infections, tuberculosis as well as paraneoplastic encephalitis; all results were negative. The autoimmune encephalitis panel (CSF and serum) were negative including anti-thyroid antibodies. Paired sera for MOG IgG and AQP-4 antibodies were also negative. Connective tissue diseases and vasculitis panel were also unremarkable. The acute onset of presentation after an episode of a viral illness (i.e., SARS-CoV-2 infection), neuroimaging findings and the absence of previous neurological symptoms pointed towards a diagnosis of COVID-19 induced ADEM. She was then put on high dose intravenous methylprednisolone (1 g/day for five consecutive days) on 16th day after admission. After five days of therapy with methylprednisolone, there was a significant improvement of the consciousness, but the movement disorders persisted, particularly upper limbs and orofacial myoclonus. She was then treated with intravenous immunoglobulin 0.4 g/kg/day for five days (on 22nd day of admission). The myoclonus and the gait ataxia improved significantly over the succeeding days. In fact, clonazepam and propranolol were stopped

gradually within one month. After two months of follow-up, the patient was asymptomatic and neurological examination was normal. MRI of the brain after three months of follow-up revealed marked resolution of previous lesions and absence of new lesions.

3. Discussion

ADEM is an autoimmune monophasic multifocal demyelinating disorder of the central nervous system, which is frequently associated with preceding viral infections (Pohl et al., 2016). In recent times, though rarely, SARS-CoV-2 infection has been linked to development of ADEM both in adult and pediatric patients (de Miranda Henriques-Souza et al., 2021; Novi et al., 2020; Parsons et al., 2020). Pathogenetic mechanisms for the development of ADEM following SARS-CoV-2 infection may be either mediated by direct neurotropism or by aberrant immune mediated injury, the latter being the most likely (de Miranda Henriques-Souza et al., 2021; Ghosh et al., 2020; Novi et al., 2020; Parsons et al., 2020; Roy et al., 2021).

Movement disorders, as a presenting manifestation of ADEM, are extremely rare and more so in adults (Ha and Sue, 2010; Kabakus et al., 2006; Mehanna and Jankovic, 2013; Park et al., 2016). Whether a case of ADEM will develop movement disorders or not, will certainly depend upon involvement of areas of brain that control movements (basal ganglia and its connections). Specifically, ataxia, myoclonus, dystonia, chorea and tremor have been reported in ADEM (Ha and Sue, 2010; Kabakus et al., 2006; Mehanna and Jankovic, 2013; Park et al., 2016). On the other hand, movement disorders are sparsely reported in SARS-CoV-2 infection. (Ghosh et al., 2021; Ghosh et al., 2021; Rábano-Suárez et al., 2020; Roy et al., 2021). The most commonly movement disorders reported in COVID-19 have been different types of myoclonus, followed by opsoclonus, ataxia, hypokinetic-rigid syndrome and tremor. (Roy et al., 2021; Ghosh et al., 2021) However, some of the previously reported cases, primarily those with myoclonus, could be ascribed to medication exposures, metabolic disturbances or severe hypoxia, meanwhile others to a post-or para-infectious immune-mediated mechanism.(Rábano-Suárez et al., 2020; Roy et al., 2021; Ghosh et al., 2021)

Neurological manifestations of COVID-19 have attracted attention among neurologists across the world.(Roy et al., 2021) Our case adds to the tally of novel cases of post-SARS-CoV-2 infection related neurological manifestations as well as to the exceedingly rare list of cases in whom a cocktail of complex movement disorders preceded ADEM.

Disclosures

R. Ghosh reports no disclosures relevant to the manuscript.
S. Dubey reports no disclosures relevant to the manuscript.
A. Mandal reports no disclosures relevant to the manuscript.
B.K. Ray reports no disclosures relevant to the manuscript.
J. Benito-León reports no disclosures relevant to the manuscript.

Ethical compliance statement

The authors confirm that approval of an institutional review board was not required for this work. Informed written consent for publication was obtained from the patient. We confirm that we have read the Journal's position on issues involved in ethical publication and affirm that this work is consistent with those guidelines.

Funding sources and conflicts of interest

The authors report no relevant disclosures or conflicts of interest for this manuscript.

Financial disclosures for the previous 12 months

The authors report no financial disclosures for the previous 12 months other than employment from the respective affiliations.

Acknowledgements

J. Benito-León is supported by the National Institutes of Health, Bethesda, MD, USA (NINDS #R01 NS39422), European Commission (grant ICT-2011-287739, NeuroTREMOR), the Ministry of Economy and Competitiveness (grant RTC-2015-3967-1, NetMD—platform for the tracking of movement disorder), and the Spanish Health Research Agency (grant FIS PI12/01602 and grant FIS PI16/00451).

References

de Miranda Henriques-Souza, AM, de Melo, ACMG, de Aguiar Coelho Silva Madeiro, B, Freitas, F, Sampaio Rocha-Filho, PA, Gonçalves, FG, 2021. Acute disseminated encephalomyelitis in a COVID-19 pediatric patient. Neuroradiology. 63, 141–145. https://doi.org/10.1007/s00234-020-02571-0.

Ghosh, R., Biswas, S., Roy, D., Pandit, A., Lahiri, D., Ray, B.K., Benito-León, J., 2021. De Novo Movement Disorders and COVID-19: Exploring the Interface. Mov. Disord. Clin. Pract. https://doi.org/10.1002/mdc3.13224.

Ghosh, R., De, K., Roy, D., Mandal, A., Biswas, S., Biswas, S., Sengupta, S., Naga, D., Ghosh, M., Benito-León, J., 2020. A case of area postrema variant of neuromyelitis optica spectrum disorder following SARS-CoV-2 infection. J. Neuroimmunol. 350 https://doi.org/10.1016/j.jneuroim.2020.577439.

Ghosh, R., Dubey, S., Roy, D., Ray, A., Pandit, A., Ray, B.K., Benito-León, J., 2021. Choreo-ballistic movements heralding COVID-19 induced diabetic ketoacidosis. Diabetes Metab. Syndr. 15 (3), 913–917. https://doi.org/10.1016/j.dsx.2021.04.010.

Ha, A.D., Sue, C., 2010. ADEM presenting as a movement disorder. Mov. Disord. 25, 2464–2466. https://doi.org/10.1002/mds.23229.

Kabakus, N., Taskin, E., Aydin, M., 2006. Segmental myoclonus as the presenting symptom of an acute disseminated encephalomyelitis: a case report. Eur. J. Paediatr. Neurol. 10, 45–48. https://doi.org/10.1016/j.ejpn.2005.11.008.

Mehanna, R., Jankovic, J., 2013. Movement disorders in multiple sclerosis and other demyelinating diseases. J. Neurol. Sci. 328, 1–8. https://doi.org/10.1016/j.jns.2013.02.007.

Novi, G., Rossi, T., Pedemonte, E., Saitta, L., Rolla, C., Roccatagliata, L., Inglese, M., Farinini, D., 2020. Acute disseminated encephalomyelitis after SARS-CoV-2 infection. Neurol. Neuroimmunol. Neuroinflamm. 7, e797. https://doi.org/10.1212/NXI.0000000000000797.

Park, J., Kim, H., Hyun, J.-W., 2016. Acute Disseminated Encephalomyelitis with Tremor as the Initial Symptom.

Parsons, T., Banks, S., Bae, C., Gelber, J., Alahmadi, H., Tichauer, M., 2020. COVID-19-associated acute disseminated encephalomyelitis (ADEM). J. Neurol. 267, 2799–2802. https://doi.org/10.1007/s00415-020-09951-9.

Pohl, D., Alper, G., Van Haren, K., Kornberg, A.J., Lucchinetti, C.F., Tenembaum, S., Belman, A.L., 2016. Acute disseminated encephalomyelitis: Updates on an inflammatory CNS syndrome. Neurology 87 (9 Suppl 2), S38–S45. https://doi.org/10.1212/WNL.0000000000002825.

Rábano-Suárez, P., Bermejo-Guerrero, L., Méndez-Guerrero, A., Parra-Serrano, J., Toledo-Alfocea, D., Sánchez-Tejerina, D., Santos-Fernández, T., Folgueira-López, M. D., Gutiérrez-Gutiérrez, J., Ayuso-García, B., González de la Aleja, J., Benito-León, J., 2020. Generalized myoclonus in COVID-19. Neurology 95 (6), e767–e772. https://doi.org/10.1212/WNL.0000000000009829.

Roy, D., Ghosh, R., Dubey, S., Dubey, M.J., Benito-León, J., Kanti Ray, B., 2021. Neurological and neuropsychiatric impacts of COVID-19 pandemic. Can. J. Neurol. Sci. 48 (1), 9–24. https://doi.org/10.1017/cjn.2020.173.