Since January 2020 Elsevier has created a COVID-19 resource centre with free information in English and Mandarin on the novel coronavirus COVID-19. The COVID-19 resource centre is hosted on Elsevier Connect, the company's public news and information website.

Elsevier hereby grants permission to make all its COVID-19-related research that is available on the COVID-19 resource centre - including this research content - immediately available in PubMed Central and other publicly funded repositories, such as the WHO COVID database with rights for unrestricted research re-use and analyses in any form or by any means with acknowledgement of the original source. These permissions are granted for free by Elsevier for as long as the COVID-19 resource centre remains active.

ELSEVIER

Seminars in NUCLEAR MEDICINE

FDG-PET/CT of COVID-19 and Other Lung Infections

Liesl S. Eibschutz,[*,1] Behnam Rabiee,[*,†,1] Shadi Asadollahi,[‡] Amit Gupta,[§] Majid Assadi,[¶] Abass Alavi,[‡] and Ali Gholamrezanezhad, MD[*]

While not conventionally used as the first-line modality, [^{18}F]-2-fluoro-2-deoxy-D-glucose (FDG) - positron emission tomography/computed tomography (PET/CT) can identify infection and inflammation both earlier and with higher sensitivity than anatomic imaging modalities [including chest X-ray (CXR), computed tomography (CT), and magnetic resonance imaging (MRI)]. The extent of inflammation and, conversely, recovery within the lungs, can be roughly quantified on FDG-PET/CT using maximum standardized uptake value (SUVmax) values. The Coronavirus disease 2019 (COVID-19) pandemic has highlighted the value of FDG-PET/CT in diagnosis, elucidation of acute pulmonary and extrapulmonary manifestations, and long-term follow up. Similarly, many other pulmonary infections such as previously documented coronaviruses, Aspergillosis, Blastomycosis, Candidiasis, Coccidioidomycosis, Cryptococcosis, Histoplasmosis, Mucormycosis, and typical/atypical Mycobacterial infections have all been identified and characterized using FDG-PET/CT imaging. The goal of this review is to summarize the actual and potential benefits of FDG-PET/CT in the imaging of COVID-19 and other lung infections. Further research is necessary to determine the best indications and clinical applications of FDG-PET/CT, improve its specificity, and ultimately ascertain how this modality can best be utilized in the diagnostic work up of infectious pathologies.
Semin Nucl Med 00:1-10 **© 2021 Elsevier Inc. All rights reserved.**

Introduction

For decades, acute lower respiratory tract infections have been one of the three leading causes of mortality in both adult and pediatric populations, creating a substantial burden on the healthcare system. While standard radiologic imaging techniques, mainly chest X ray (CXR) and CT, are the primary imaging modalities to diagnose lung infection, FDG-PET/CT has proven to be effective in cases where conventional imaging falls short. Not only can metabolic imaging identify and track the infection earlier than other methodologies, but it can also provide vital information at the molecular level.[1,2] The high sensitivity of this modality coupled with wider anatomic coverage generates a more comprehensive and complete assessment of the patient's global disease burden, allowing for personalization of treatment strategy.

While the FDG-PET/CT imaging modality has primarily been reserved for imaging of malignancies, many authors have also recognized its value in non-neoplastic processes such as pulmonary infections. This is due to the fact that FDG acts as a glucose analogue, and thus gets taken up by the cell via glucose transporter 1(GLUT-1).[2] After cellular uptake, FDG is phosphorylated by the rate-limiting enzyme hexokinase, trapping FDG-6-phosphate in the cell.[2] This mechanism allows FDG-PET/CT to identify sites with increased glucose utilization and metabolism, which are non-specific but common markers of infection, inflammation, and malignancies.

*Department of Radiology, Keck School of Medicine, University of Southern California (USC), Los Angeles, CA.
†Montefiore Medical Center, Albert Einstein College of Medicine, Bronx, NY.
‡Professor of Radiology, Director of Research Education, Department of Radiology, Hospital of the University of Pennsylvania, Philadelphia, PA.
§Department of Radiology, University Hospital Cleveland Medical Center, Cleveland, OH.
¶Department of Nuclear Medicine, Bushehr University of Medical Sciences, Bushehr, Iran.
Disclosures: None.
Address reprint requests to Ali Gholamrezanezhad, MD, Department of Radiology, Division of Emergency Radiology, Keck School of Medicine, University of Southern California, 1500 San Pablo Street, Los Angeles, CA 90033. E-mail: ali.gholamrezanezhad@med.usc.edu
[1]These authors contributed equally to the work and should be considered as co-first authors.

https://doi.org/10.1053/j.semnuclmed.2021.06.017
0001-2998/© 2021 Elsevier Inc. All rights reserved.

Ultimately, combining the functional aspects of FDG-PET/CT with the structural/anatomic facets of CT has the potential to revolutionize the diagnosis and treatment of pulmonary infections. While not normally utilized as a stand-alone methodology in infectious/inflammatory processes, FDG-PET/CT imaging has great utility when used in conjunction with other imaging techniques, as it provides additional information on the molecular level and can accurately quantify disease burden. This review aims to highlight the value of nuclear imaging in elucidating a variety of lung infections.

Mechanism of Localization of FDG in Inflammatory and Infectious Diseases

The introduction of PET/CT using FDG opens new areas of research in diagnosis of inflammatory and infectious diseases. FDG is a nonspecific tracer, and its level of uptake is proportional to the cellular metabolic rate and the density of glucose transporters, thus FDG accumulates at sites of infection and inflammation.[2-5] It is well established that inflammatory response, focal hyperemia, and increased vascular permeability are correlated with high uptake of FDG, with enhanced tissue blood perfusion leading to greater FDG delivery to the lesion site and local immune response resulting in release of proinflammatory cytokines and migration of inflammatory cells.[6,7] As activated inflammatory cells such as neutrophils, macrophages, lymphocytes, and fibroblasts significantly take up FDG, there is a direct correlation between the FDG uptake and the quantity of inflammatory cells in both acute and chronic inflammation where expression of active glucose transporters is upregulated.[8,9]

FDG avidity has been reported in the development of various pulmonary inflammatory and infectious diseases. In acute infection, FDG is absorbed mainly by activated parenchymal neutrophils, which are highly dependent on anaerobic glycolysis and demand high uptake of glucose. Therefore, FDG accumulates in the interstitial lung tissue and alveolar airspaces, permitting study of the behavior of inflammatory cells in their local microenvironment.[4,10]

COVID-19

Over the past year, the global COVID-19 pandemic caused by severe acute respiratory syndrome coronavirus 2 (SARS-CoV-2), has affected over 170 million people worldwide, resulting in millions of patients developing pulmonary symptoms serious enough to require hospitalization and serial imaging. While reverse transcription-polymerase chain reaction (RT-PCR) CXR, and less commonly chest CT have been the primary tools of diagnosis, FDG-PET/CT may incidentally detect undiagnosed cases of COVID-19 in the early stages of infection, when symptoms are nonspecific. Recent studies have reported incidental FDG-PET/CT findings confirming COVID-19 in asymptomatic patients, including one series of 7 patients with 2 consecutive negative RT-PCR tests.[11] The authors found that the pulmonary lesions displayed significantly increased SUVmax (mean $\pm$ standard deviation, 3.44 $\pm$ 2.03 vs 0.54 $\pm$ 0.19) when compared to the lungs of control subjects.[11] In another study, FDG-PET/CT showed new lung infiltrates in asymptomatic patients roughly 7 days (range of 6.4 $\pm$ 7.8 days) prior to symptom onset.[12] Therefore, routine staging FDG-PET/CT scans may show incidental but typical imaging findings of COVID -19 and help initiate further workup (Fig. 1).

COVID-19 pneumonia is FDG avid, and numerous studies have documented lung uptake in both asymptomatic and symptomatic patients. As is typical on diagnostic CT, on FDG-PET/CT, ground glass opacifications (GGOs) with or without superimposed consolidation are appreciated in a peripheral, basilar, and posterior predominant pattern with increased metabolic activity.[13] Less intense uptake may be seen in lymph nodes and bone marrow.[14] In one of the earliest case reports of PET/CT imaging of COVID-19, Qin et al described 4 presumed cases with pulmonary involvement (a limitation of this case series being that SARS-CoV-2 nucleic acid testing was not done in 3 of the 4 and 1 case was PCR negative). However, at least 2 lobes showed SUVmax values ranging from 4.6 to 12.2 in areas that indicated GGOs on initial CT.[15] In 3 of the 4 cases, FDG-positive supraclavicular and mediastinal nodes were seen with SUVmax ranging between 5.4 and 7.[15] Zou et al[16] reported a case of suspected lung malignancy which after staging with FDG-PET/CT, revealed a right lung FDG-avid mass (SUVmax of 4.9) with additional uptake in the right paratracheal and hilar nodes as well as bone marrow (Fig. 2). Ultimately, the final diagnosis was COVID-19 confirmed by RT-PCR (Fig. 2).[16] Authors have also utilized FDG-PET/CT imaging to quantify the extent of inflammation in the lungs, due to the fact that nuclear imaging can detect inflammation even before anatomic changes are present. For instance, Dietz et al[17] classified COVID-19 induced inflammation based on hypermetabolic volume and SUVmax values; a low level of inflammation was classified by a hypermetabolic volume less than 50 mL and SUVmax less than 7, with any values above those levels considered a high level of inflammation. Therefore, FDG-PET/CT can be utilized in conjunction with clinical assessment to objectively determine the degree of disease severity.

Although there is no primary application for FDG-PET/CT in the diagnostic algorithm of patients with suspected COVID-19, there could be indications for metabolic imaging in the evaluation of residual disease and recovery. As part of the normal healing process, pulmonary infections may result in scar and/or organizing pneumonia, and continue to show radiographic abnormality, which may be indistinguishable from parent infection. This leads to longer and unnecessary follow-up imaging, while in reality, there are no active inflammatory lesions in the pulmonary parenchyma. In these instances, anatomic imaging modalities, including CXR and chest CT remain abnormal, while metabolic and functional imaging modalities, such as FDG-PET/CT, can accurately confirm the resolution of active inflammatory process.[18,19] Moreover, we emphasize the fact that the interpretation of

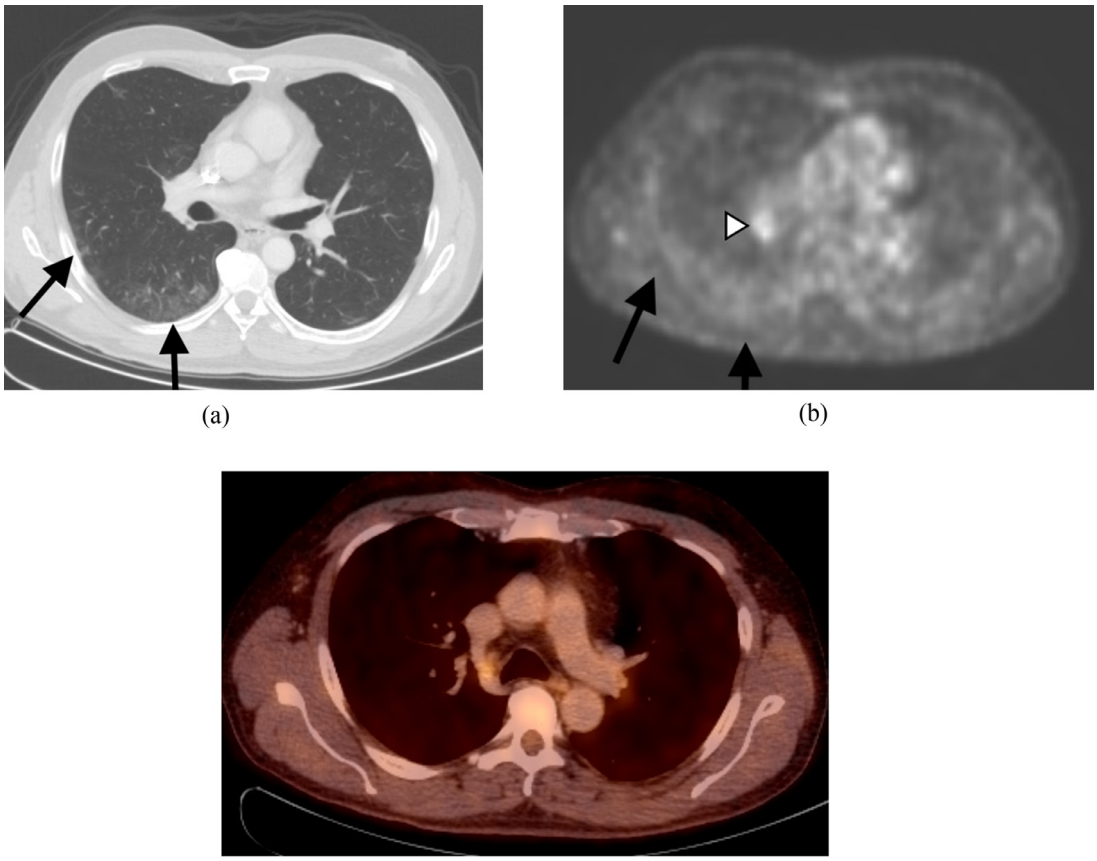

Figure 1 A 53-year-old male with a history of colorectal cancer presented for restaging FDG-PET/CT. Axial low dose CT image (A) showing incidental peripheral ground-glass opacity involving the posterior right lower lobe lung (arrows), with borderline hypermetabolism (SUVmax of 2.2) on corresponding CT attenuation corrected PET image (arrows in B). Additionally, mild uptake (SUVmax of 2.6) was seen in the right hilar region likely representing reactive lymphadenopathy (white arrowhead in B). Given the morphology of lung opacities, equivocal FDG uptake, and clinical suspicion, patient underwent RT-PCR testing and was confirmed to have COVID-19.

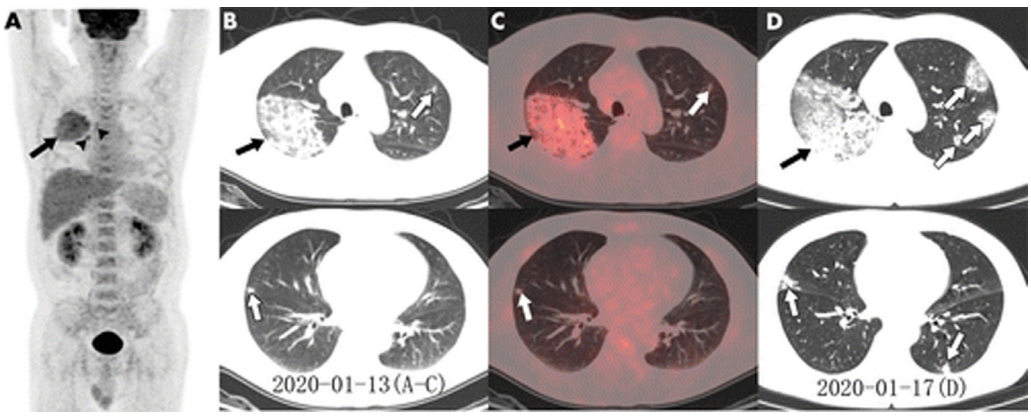

Figure 2 (A) PET maximum intensity projection image shows a fluorine 18 fluorodeoxyglucose (FDG)—avid mass (arrow) with a maximum standardized uptake value of 4.9 in the right lung. Increased accumulation of FDG in the right paratracheal, right hilar lymph nodes (arrowheads), and bone marrow are also noted. (B) Low-dose axial CT scan and, (C) PET/CT fusion image show ground-glass opacities with areas of focal consolidation (black arrow) primarily in the right upper lobe and a focal opacity in the left upper and right middle lobes (white arrows). (D) Follow-up CT scan obtained 4 days later demonstrates progression of lesions in bilateral upper and right middle lobes (arrows) with newly developed focal opacities in the left upper and lower lobes (arrows). Figure 2 reproduced with permission from Zou S, Zhu X. FDG PET/CT of COVID-19. Radiology 2020;296: E118-E118.

FDG-PET/CT should not be limited to the evaluation of oncologic conditions. With the growing evidence of the detection of COVID-19 on FDG-PET/CT studies, radiologists and nuclear medicine physicians should be aware of the features of SARS-CoV-2 infection on FDG-PET/CTs, as this may lead to the detection of crucial nononcologic pathologies. In patients with suspicious FDG-PET/CT findings for COVID-19, we recommend a low threshold for clinical/paraclinical screening and diagnostic testing such as PCR. This will allow earlier recognition, detection, and treatment of this potentially life-threatening and devastating disease, as patients undergoing FDG-PET/CT studies (usually for oncologic indications) are commonly immunocompromised and are more prone to severe disease or complications.[20] On the other hand, early recognition of suspicious patterns on FDG-PET/CT can help ensure optimal postexposure precautions and implementation of recommendations sooner.

FDG-PET/CT and Extrapulmonary Manifestations of COVID-19

COVID-19 is known to be associated with extrapulmonary involvement, such as renal dysfunction, hepatic, vascular, and myocardial injury, as well as neuromuscular and gastrointestinal abnormalities. Arterial and venous thrombosis has also been reported in hospitalized COVID-19 patients, particularly those who are severely ill. A US registry of 1114 COVID-19 patients reported that major arterial or venous thromboembolic complications 30 days from diagnosis occurred in 35.3% of 170 hospitalized intensive care unit (ICU) patients and only 2.6% of 229 hospitalized non-ICU patients.[21] Recent studies note a potential role of FDG-PET/CT imaging in detecting venous thrombosis throughout the body, as clots contain an abundance of activated white blood cells and platelets, which are highly glycolytic.[22-25] Progression of the disease from isolated pulmonary involvement to a systemic condition has a poor prognosis and can result in multiorgan failure[26-31] Thus, many authors have focused on the utilization of FDG-PET/CT for assessment of the extrapulmonary manifestations of COVID-19. Karimi-Galougahi et al[32] noted decreased metabolic activity in the orbitofrontal cortex associated with the COVID-19 induced anosmia (Fig. 3). In addition, these authors used FDG-PET/CT to investigate COVID-19 induced facial nerve palsy, and FDG-PET/CT findings have also indicated reduced neurological radiotracer uptake in several brain areas prior to symptom onset, during active illness, and 6 months after infection.[33-35] The acute reduction in uptake was primarily found in the prefrontal cortex, mimicking the patterns of several neurodegenerative disorders.[33-35] Other authors such as Sollini et al[36] have

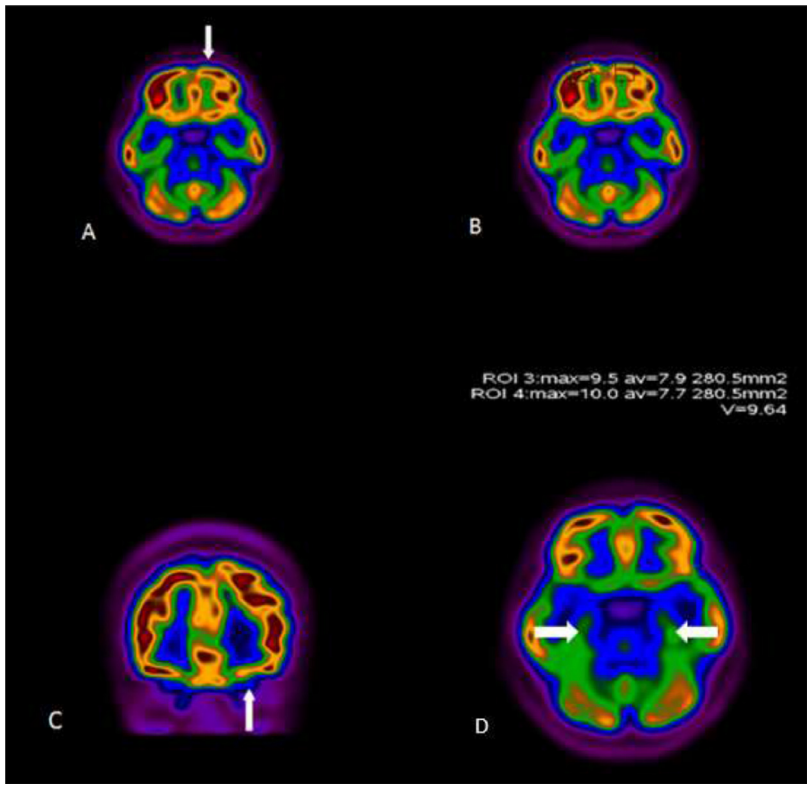

Figure 3 FDG-PET/CT scan of a 27-year-old woman with persistent anosmia and positive PCR for SARS-CoV-2. Representative axial (A, B, D) and coronal (C) images are shown. There was decreased uptake in the left orbitofrontal cortex (arrows). The uptake of temporal lobes were symmetric and normal (arrows, D). Figure 3 reproduced with permission from Karimi-Galougahi M, Yousefi-Koma A, Bakhshayeshkaram M, Raad N, Haseli S. 18FDG PET/CT scan reveals hypoactive orbitofrontal cortex in anosmia of COVID-19. Academic radiology 2020; 27:1042-1043.

identified increased FDG uptake in vasculature in those patients complaining of persistent symptoms postinfection. They found increased uptake in the thoracic aorta, right iliac artery, and femoral arteries, suggesting post COVID-19 vasculitis in symptomatic survivors.[36] Bai et al[11] found increased SUVmax in the liver of COVID-19 patients (4.31 ± 0.91 vs 2.86 ± 0.66, P= 0.017), indicating COVID-19 induced hepatocyte injury, although clinically significant liver injury was uncommon. Halsey et al[37] incidentally found increased gastrointestinal and renal uptake in asymptomatic COVID-19 patients with SUVmax values of 3.85 ± 1.12 and 4.03 ± 0.94 respectively. Though FDG-PET/CT has not been routinely utilized in presumed COVID-19 induced myocarditis, Puntmann et al[38] reported that cardiac MRI (CMR) is abnormal in 78% and ongoing myocardial inflammation in 60% of recently recovered COVID-19 patients at an average of 71 days postdiagnosis, suggesting significant residual disease burden. In this setting, FDG-PET/CT could have potential utility not only in diagnosis but also in differentiating between acute and chronic myocardial injury. Ultimately, further research is necessary to determine the added benefits of FDG-PET/CT imaging in assessing long-term extrapulmonary sequelae of COVID-19.

FDG-PET/CT and COVID-19 Vaccination

A routine FDG-PET/CT, because of its excellent sensitivity, may capture changes related to recent COVID-19 vaccination. Recent research has shown that reactive lymph nodal uptake on FDG-PET/CT may appear within a few days and persist for several weeks post COVID-19 vaccination.[39-41] For instance, Eshet et al[42] reported increased FDG uptake in the ipsilateral axillary lymph node with median SUVmax values of 2.9 ± 1.3, up to 10 weeks after vaccination. Avner et al[43] reported SUVmax values of up to 9.4 in the left axilla, retro pectoral space, and proximal arm 6 days after the second dose of Pfizer COVID-19 vaccine. These findings are not unexpected given previous evidence citing ipsilateral axillary node FDG uptake in influenza vaccine recipients.[44] However, it is imperative that interpreting physicians recognize this manifestation in oncologic patients to avoid unnecessary biopsy and restaging (Fig. 4).[39]

Respiratory Viral Infections

The most common causes of respiratory infection are viral pathogens, including influenza virus, human parainfluenza

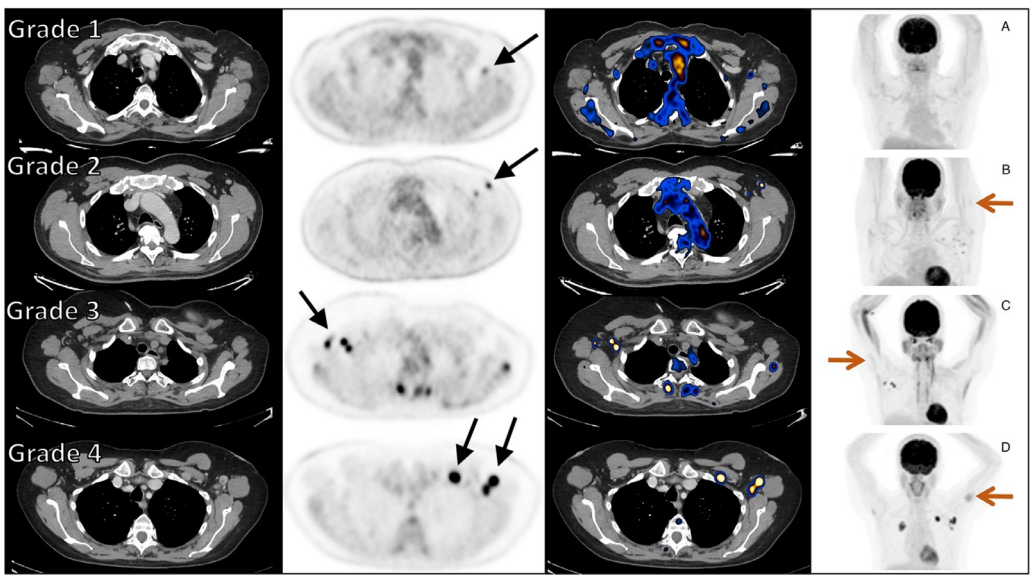

Figure 4 Grading of vaccine-associated hypermetabolic lymphadenopathy based on FDG-uptake intensity and nodal size: Grade 1, mild uptake intensity (SUVmax <2.2); Grade 2, moderate uptake intensity (2.2 ≤ SUVmax <4); Grade 3, high uptake intensity (SUVmax ≥4) in normal-size nodes; and grade 4, high FDG-uptake intensity (SUVmax ≥4) in enlarged nodes. Each row represents one patient. From left to right: CT, PET, and fusion PET-CT axial slices and a MIP image. HLN was identified in the axillary and supraclavicular lymph nodes (most likely due to recent vaccination, as annotated by black arrows) in each of the following patients: Patient A: colon cancer patient referred for staging imaged 9 days following the first vaccine dose (SUVmax of 1.97), Patient B: rectal cancer patient referred for follow-up, imaged 13 days following the second vaccine dose (SUVmax of 3.39), Patient C: prior history of breast cancer referred for follow-up study 10 days following the first vaccine dose (SUVmax of 10.10), and Patient D: right upper lobe lung cancer patient referred for staging 1 day following the booster vaccine dose (SUVmax of 14.34). Lymph node diameter of Patient D was noted to be 14 mm. Brown arrows indicate increased FDG uptake at the vaccine injection site on the MIP images. HLN, hypermetabolic lymphadenopathy; MIP, maximal intensity projection. Figure 4 adapted with permission from Cohen, D., Krauthammer, S. H., Wolf, I., & Even-Sapir, E. (2021). Hypermetabolic lymphadenopathy following administration of BNT162b2 mRNA Covid-19 vaccine: incidence assessed by (18)F-FDG PET-CT and relevance to study interpretation. Eur J Nucl Med Mol Imaging, 48(6), 1854-1863. https://doi.org/10.1007/s00259-021-05314-2. http://creativecommons.org/licenses/by/4.0/.

virus, rhinovirus, respiratory syncytial virus, and adenovirus. On top of that, there have been several regional and global outbreaks of novel respiratory viral infections during the past decades, including severe acute respiratory syndrome (SARS), Middle East respiratory syndrome (MERS), H1N1 and H5N1 influenza, and most recently, COVID-19. CXR and CT are the routinely utilized imaging modalities to investigate pulmonary changes at presentation, as well as to monitor disease progression and response to treatment. The most common CT findings in viral respiratory illnesses include diffuse ill-defined GGOs, consolidation, and interlobular septal thickening.[45] These findings however are highly non-specific and can also be seen in some inflammatory diseases, as well as some nonviral infections.[46]

Acute inflammatory response has been shown to play an important role in the pathogenesis of severe respiratory dysfunction in respiratory viral infections such as H1N1, H5N1, and SARS.[47,48] During the acute inflammatory phase of infection, activated neutrophils heavily utilize anaerobic glycolysis, which leads to increased FDG uptake.[49] Hence, FDG-PET/CT has the potential to assess the degree of inflammatory response in respiratory viral infections.[47] This uptake can be quantified and may be very helpful in delineating the extent of inflammation in lung tissue. Furthermore, it has been shown that increased FDG uptake is present not only in nonaerated portions of the lungs on CT scan, but also areas with preserved aeration. This suggests improved sensitivity and more accurate estimation of inflammation utilizing FDG-PET/CT.[48] Tracking the underlying inflammation could potentially be useful in monitoring disease progression, response to treatment, and confirming resolution of infection.

Pulmonary Fungal Infections

Taking advantage of the quantifiable FDG uptake during the inflammatory response to infections, PET/CT has the potential to be utilized for initial diagnosis, staging of invasive fungal infections, disease progression, and response to treatment.[50-52] Semiquantitative FDG uptake has already been shown to be more accurate in measuring disease activity compared to morphological changes in lesion size visible on anatomic imaging.[53] Once the primary infection resolves, FDG-PET/CT can be useful in confirming inflammatory resolution in the setting of persistent structural abnormalities seen on other modalities.[53] Conversely, an increase in SUVmax has been shown to be associated with disease progression.[53] In addition to establishing diagnosis, FDG-PET/CT can also be useful in localizing occult fungal infections, particularly in immunocompromised patients (Fig. 5).[54]

Aspergillosis

Showing prominent FDG-avidity, pulmonary aspergillosis looks very similar to pulmonary malignancy on FDG-PET/CT, potentially creating confusion for the reading radiologist.[51,55] However, FDG-PET/CT can be effective in differentiating invasive and noninvasive pulmonary aspergillosis, given the higher peak SUV in the former.[14] Imaging manifestations of invasive aspergillosis are defined as multiple hypermetabolic nodules, while in noninvasive aspergillosis, solitary metabolic nodules with halo pattern have been described[14] FDG-PET/CT can also be utilized to investigate response to therapy in pulmonary aspergillosis, and has value in uncovering occult infection in the immunocompromised patient.[56]

Blastomycosis

Pulmonary blastomycosis can also mimic primary and metastatic lung malignancy on FDG-PET/CT, mostly due to high uptake in a nodular pattern.[57,58] Preclinical studies on animal models with blastomycosis showed FDG uptake levels higher than lymphoma.[59] A potential of FDG-PET/CT in pulmonary blastomycosis is the fact that it can show the true extent of active infection by discovering disease sites which are otherwise clinically occult.[59]

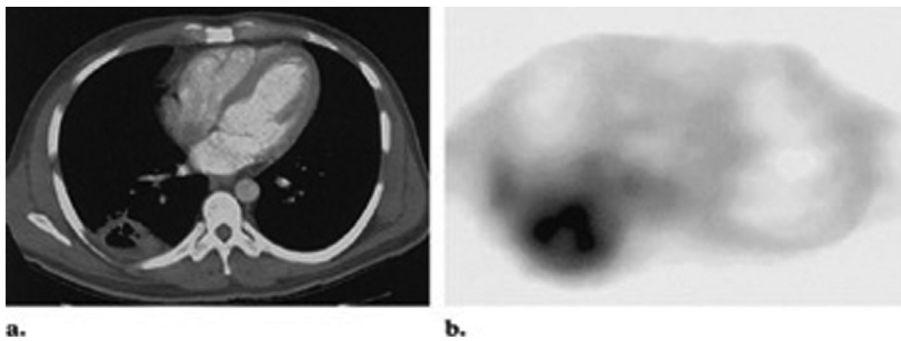

Figure 5 Fungal pneumonia in a 40-year-old man with AIDS and newly diagnosed anaplastic lymphoma. (A) Computed tomographic (CT) scan demonstrates a 6 × 3.5-cm thick- walled cavitary lesion in the posterior segment of the right lower lung. (B) FDG-PET scan demonstrates intense, heterogeneous accumulation of radiotracer in the posterior aspect of the right lower lung, a finding that corresponds to the abnormality identified at CT and that could indicate lymphomatous involvement of the pulmonary parenchyma. The final diagnosis, however, was fungal pneumonia. It was not possible to distinguish lymphoma from infection on the basis of the FDG-PET finding alone. Figure 5 reproduced with permission from Love, C., Tomas, M. B., Tronco, G. G., & Palestro, C. J. (2005). FDG PET of infection and inflammation. Radiographics, 25(5), 1357-1368. https://doi.org/10.1148/rg.255045122.

Candidiasis

Candidiasis lesions show increased FDG avidity on nuclear imaging, thus this modality could be utilized in guiding anticandida therapy.[60] In support of this, Xu et al[53] performed a preliminary study in patients with chronic disseminated candidiasis, and noted that FDG-PET/CT provided utility in antifungal therapy response. FDG-PET/CT can also help in the detection of occult sites of candidiasis in immunocompromised patients [50]

Coccidioidomycosis

Pulmonary coccidioidomycosis lesions have abnormal FDG uptake on PET/CT, but this modality is of limited use due to the difficulty differentiating these lesions from malignancy.[61] Nonetheless, the median SUVmax is often more elevated in malignant lesions relative to coccidioidal nodules with SUVmax of greater than 5.9 suspicious for malignancy.[62] Nia et al[63] reported a case of pulmonary coccidiomycosis with systemic involvement and discussed that FDG-PET/CT has the potential to guide medical management and help with investigating the extent of the disease, as well as response to therapy.

Cryptococcosis and Histoplasmosis

Pulmonary cryptococcus involvement can show variable levels of FDG avidity in PET/CT, ranging from mild to pronounced uptake.[64,65] The most common presentation is a solitary nodule, and less frequently: scattered nodular, clustered nodular, mass-like and bronchopneumonic patterns.[66] However, pulmonary cryptococcosis can show a similar pattern of FDG uptake to that of lung cancer.[67,68] Thus, cryptococcosis should be kept in the differential diagnosis when evaluating lung malignancy with FDG-PET/CT, especially in endemic areas. Thus far, multiple studies have indicated that FDG-PET/CT is unhelpful diagnostically, but may be useful when guiding response to treatment.[51] Pulmonary histoplasmosis also shows FDG avidity in PET/CT, both in the primary pulmonary infection and the mediastinal and hilar lymph nodes.[69] As with many other pulmonary fungal infections, nuclear imaging manifestations are similar to lung malignancy and create false positives, reducing the specificity of FDG-PET/CT in the detection of lung malignancies in endemic areas.[51,70] However, some authors have noted that dual-time FDG-PET/CT may be helpful in discriminating benign from malignant lesions.[71] In chronic histoplasmosis, Nagelschneider et al[72] have described a flip flop fungal sign on FDG-PET/CT that helps differentiate histoplasmosis from malignancy. Mittal et al[73] showed that FDG-PET/CT can be used in initial staging as well as in response to treatment. These authors have suggested the utility of FDG-PET/CT in the early identification of lesions amenable to therapy.

Mucormycosis

In a report, Dang et al[74] described their FDG-PET/CT findings in a case of pulmonary mucormycosis as prominent peripheral uptake in a heterogeneous soft tissue mass. Recent studies have also begun to recognize increased rhino-orbital mucormycosis susceptibility in patients with moderate to severe COVID-19 infection.[75]

Tuberculosis Infections

Tuberculosis (TB) infection of the lung primarily involves formation of a well-structured granuloma, in which immune cells and bacteria aggregate. In approximately 80% of cases, the lungs are the most common site of infection, but tuberculosis can disseminate to nearly any tissue or organ by hematogenous, lymphatic, or contiguous spread.[49]

FDG-PET/CT is a noninvasive tool capable of early detection and assessment of the disease involvement. This imaging modality is also capable of indicating enhanced glycolytic activity in both anaerobic and aerobic cells, thereby broadening its utility. This technique can demonstrate the disease extent, guide biopsy from active lesions, and find distant occult foci.[76] It can also measure treatment response to significantly optimize patient management.

As radiolabeled FDG accumulates in TB-related neutrophils, macrophages, and T-lymphocytes (all present in active granulomatous foci), this imaging method has high precision in identifying active granulomatous sites.[77,78] The ability of FDG-PET/CT to detect changes in metabolic uptake of TB lesions may be considered an accurate complementary tool to conventional anatomical imaging. A study by Stelzmueller et al[79] demonstrated that, while both FDG-PET/CT and CT scanning provide useful diagnostic information at both initial assessment and follow-up, FDG-PET/CT was more accurate and sensitive than CT scanning in the detection of suspicious pulmonary and extrapulmonary TB lesions. Other authors have reported that the addition of nuclear imaging to anatomic modalities such as CT further increased the sensitivity of this modality to identify small lesions, affected lymph nodes, and allowed differentiation between active and inactive lesions.[80,81]

Recent studies have also focused on the utilization of FDG-PET/CT for assessment of treatment effectiveness. Malherbe et al[82] concluded that quantitative metrics of FDG-PET/CT showing mean standardized lesion activity were predictive of treatment outcome. After one year of treatment, there was continuous dynamic reduction of lesions' activity demonstrated by FDG-PET/CT imaging.[82] Ultimately, FDG-PET/CT technique is of great value in determining TB progression, evaluating the efficacy of midterm treatment,[83,84] and in the detection of post-treatment disease recurrence.[85]

While FDG-PET/CT has shown to be effective in assessing metabolic activity of pulmonary lesions, some studies have indicated that FDG-PET/CT is more efficient than CT in assessing extrapulmonary involvement.[86] As 15% of TB patients present with extrapulmonary disease, it is imperative to identify the most sensitive diagnostic techniques, as imaging characteristics can often make M. tuberculosis lesions indistinguishable from tumors.[87] For example, Mao et al[87] have noted that the clinical and traditional imaging features of abdominal tuberculosis can mimic pancreatic cancer, and the location is often difficult to biopsy. In these circumstances, FDG-PET/CT imaging

combined with tuberculin testing or latent TB serology can help elucidate the correct diagnosis and help patients avoid unnecessary procedures.

Nontuberculous Mycobacterial Infections

In addition to TB infection, nontuberculous mycobacterial (NTM) infections can be detected using FDG-PET/CT. NTM infections are caused by a diverse and emerging group of pathogens and are rapidly increasing worldwide.[88] Mycobacterium avium complex (MAC) is the most frequently isolated atypical mycobacterium found in these cases. Similar to TB, the lung is the most common site of involvement leading to nonspecific clinical signs which could remain underdiagnosed.

As FDG collects in granulation tissues formed by activation of macrophages in NTM infection, the amount of FDG accumulation is positively associated with the scope of active inflammatory areas.[89] In a study by Del Giudice et al,[90] FDG-PET/CT was found useful in revealing the activity and extent of disease by monitoring metabolic activity of various pulmonary lesions in NTM disease. Another investigation by Demura et al[91] assessed the role of FDG-PET/CT in the diagnosis and treatment monitoring of NTM infection. They confirmed that after one or two years of therapy for MAC, the FDG uptake associated with disease decreased, in spite of the persistence of lesions on CT scanning.[91]

Another significant feature of FDG-PET/CT imaging is the potential capability in evaluating disease progression and follow-up in NTM patients. Namkoong et al,[92] described an HIV and MAC-infected patient whose FDG-PET/CT findings identified disease progression on follow-up. In addition, this imaging technique was useful for assessing the required duration of anti-mycobacterial therapy. Accordingly, FDG-PET/CT could play a valuable role in patient management, particularly in complicated cases such as HIV, in which TB and NTM infections often result in disseminated disease and tend to relapse even after treatments.

Summary

Pulmonary infectious diseases are a major cause of morbidity and mortality worldwide, thus the utilization of FDG-PET/CT in conjunction with conventional imaging techniques can yield early diagnosis and optimize treatment strategies. Throughout this paper, we have highlighted the added clinical value of FDG-PET/CT for diagnosis, elucidating acute pulmonary/extra-pulmonary manifestations, and tracking treatment effectiveness. FDG-PET/CT imaging allows for a highly sensitive approach to imaging; thus, it has utility in recognizing disease early and guiding medical management. While usually not a first line imaging modality, FDG-PET/CT can be a useful adjunct to traditional imaging techniques to help reduce disease burden and provide vital information at the molecular level. In addition, FDG-PET/CT imaging is in alignment with medicine's shift to a more patient oriented approach.[93] Nuclear imaging has the advantage of allowing histological mapping and a personalized method of treatment, but further research is necessary to fully explore and validate the effectiveness of FDG-PET/CT imaging as a stand-alone modality in the setting of infectious diseases.

Author Contributions

LSE, BR and SA drafted the manuscript with support from AG and AA. AG developed the theory, provided feedback and guidance. All authors reviewed the manuscripts and provided edits prior to submission. LSE finalized the manuscript. LSE and BR contributed equally to the work and should be considered as co-first authors.

References

1. Kashefi A, Kuo J, Shelton DK: Molecular imaging in pulmonary diseases. Am J Roentgenol 197:295-307, 2011
2. Vaidyanathan S, Patel C, Scarsbrook A, et al: FDG PET/CT in infection and inflammation—current and emerging clinical applications. Clin Radiol 70:787-800, 2015
3. Sollini M, Lauri C, Boni R, et al: Current status of molecular imaging in infections. Curr Pharm Des 24:754-771, 2018
4. Love C, Tomas MB, Tronco GG, Palestro CJ: FDG PET of infection and inflammation. Radiographics 25:1357-1368, 2005
5. Treglia G: Diagnostic performance of 18F-FDG PET/CT in infectious and inflammatory diseases according to published meta-analyses. Contrast Media Mol Imaging: 2019, 2019
6. Treglia G, Muoio B: Evidence-Based PET for infectious and inflammatory diseases. Evidence-based Positron Emission Tomography. Cham: Springer, 111-121, 2020
7. Kung BT, Seraj SM, Zadeh MZ, et al: An update on the role of 18F-FDG-PET/CT in major infectious and inflammatory diseases. American journal of nuclear medicine and molecular imaging 9:255, 2019
8. Rahman WT, Wale DJ, Viglianti BL, et al: The impact of infection and inflammation in oncologic 18F-FDG PET/CT imaging. Biomed Pharmacother 117:109168, 2019
9. Ertay T, Eren MS, Karaman M, et al: 18F-FDG-PET/CT in initiation and progression of inflammation and infection. Mol Imaging Radionuclide Ther 26:47, 2017
10. Vass L, Fisk M, Lee S, Wilson FJ, Cheriyan J, Wilkinson I: Advances in PET to assess pulmonary inflammation: A systematic review. Eur J Radiol 2020:109182
11. Bai Y, Xu J, Chen L, et al: Inflammatory response in lungs and extrapulmonary sites detected by [18 F] fluorodeoxyglucose PET/CT in convalescing COVID-19 patients tested negative for coronavirus. Eur J Nucl Med Mol Imaging: 1-12, 2021.
12. Martinez RB, Ghesani M, Ghesani N, et al: Asymptomatic SARS-CoV-2 infection-Incidental findings on FDG PET/CT. J Med Imaging Radiat Sci 2021
13. Jacobi A, Chung M, Bernheim A, Eber C: Portable chest X-ray in coronavirus disease-19 (COVID-19): A pictorial review. Clin Imaging 2020
14. Kim JY, Yoo J-W, Oh M, et al: 18F-fluoro-2-deoxy-D-glucose positron emission tomography/computed tomography findings are different between invasive and noninvasive pulmonary aspergillosis. J Comput Assist Tomogr 37:596-601, 2013
15. Qin C, Liu F, Yen T-C, Lan X: 18 F-FDG PET/CT findings of COVID-19: A series of four highly suspected cases. Eur J Nucl Med Mol Imaging: 1-6, 2020
16. Zou S, Zhu X: FDG PET/CT of COVID-19. Radiology 296:E118, 2020
17. Dietz M, Chironi G, Claessens Y-E, et al: COVID-19 pneumonia: Relationship between inflammation assessed by whole-body FDG PET/CT and short-term clinical outcome. Eur J Nucl Med Mol Imaging 48:260-268, 2021

18. Salehi S, Reddy S, Gholamrezanezhad A: Long-term pulmonary consequences of coronavirus disease 2019 (COVID-19): What we know and what to expect. J Thorac Imaging 35:W87-W89, 2020
19. Shaw B, Daskareh M, Gholamrezanezhad A: The lingering manifestations of COVID-19 during and after convalescence: Update on long-term pulmonary consequences of coronavirus disease 2019 (COVID-19). Radiol Med (Torino): 1-7, 2020
20. Katal S, Aghaghazvini L, Gholamrezanezhad A: Chest-CT findings of COVID-19 in patients with pre-existing malignancies; A pictorial review. Clin Imaging 2020
21. Piazza G, Campia U, Hurwitz S, et al: Registry of arterial and venous thromboembolic complications in patients with COVID-19. J Am Coll Cardiol 76:2060-2072, 2020
22. Hess S, Madsen PH, Basu S, et al: Potential role of FDG PET/CT imaging for assessing venous thromboembolic disorders. Clin Nucl Med 37:1170-1172, 2012
23. Houshmand S, Salavati A, Hess S, et al: The role of molecular imaging in diagnosis of deep vein thrombosis. Am J Nucl Med Mol Imaging 4:406, 2014
24. Kaghazchi F, Borja A, Seraj SM, et al: Venous thromboembolism detected by FDG PET/CT in cancer patients: A life-threatening, yet commonly missed observation. J Nucl Med 61:1600, 2020
25. Kaghazchi F, Borja AJ, Hancin EC, et al: Venous thromboembolism detected by FDG-PET/CT in cancer patients: A common, yet life-threatening observation. American Am J Nucl Med Mol Imaging 11:99, 2021
26. Behzad S, Aghaghazvini L, Radmard AR, et al: Extrapulmonary manifestations of COVID-19: Radiologic and clinical overview. Clin Imaging 2020
27. Kooraki S, Hosseiny M, Myers L, et al: Coronavirus (COVID-19) outbreak: What the department of radiology should know. J Am Coll Radiol 17:447-451, 2020
28. Katal S, Balakrishnan S, Gholamrezanezhad A: Neuroimaging findings in COVID-19 and other coronavirus infections: A systematic review in 116 patients. J Neuroradiol 2020
29. Katal S, Gholamrezanezhad A: Neuroimaging findings in COVID-19: A narrative review. Neurosci Lett 2020:135529
30. Keshavarz P, Rafiee F, Kavandi H, et al: Ischemic gastrointestinal complications of COVID-19: A systematic review on imaging presentation. Clin Imaging 2020
31. Lombardi AF, Afsahi AM, Gupta A, et al: Severe acute respiratory syndrome (SARS), Middle East respiratory syndrome (MERS), influenza, and COVID-19, beyond the lungs: a review article. Radiol Med (Torino): 1-9, 2020
32. Karimi-Galougahi M, Yousefi-Koma A, Bakhshayeshkaram M, et al: 18FDG PET/CT scan reveals hypoactive orbitofrontal cortex in anosmia of COVID-19. Acad Radiol 27:1042-1043, 2020
33. Karimi-Galougahi M, Yousefi-Koma A, Raygani N, et al: 18FDG-PET/CT assessment of COVID-19-induced Bell's palsy. Acad Radiol 28:144, 2021
34. Fontana IC, Souza DG, Pellerin L, et al: About the source and consequences of 18 F-FDG brain PET hypometabolism in short and long COVID-19. Eur J Nucl Med Mol Imaging: 1-2, 2021
35. Fontana IC, Bongarzone S, Gee A, et al: PET imaging as a tool for assessing COVID-19 brain changes. Trends Neurosci 2020
36. Sollini M, Ciccarelli M, Cecconi M, et al: Vasculitis changes in COVID-19 survivors with persistent symptoms: an [18 F] FDG-PET/CT study. Eur J Nucl Med Mol Imaging 48:1460-1466, 2021
37. Halsey R, Priftakis D, Mackenzie S, et al: COVID-19 in the act: incidental 18F-FDG PET/CT findings in asymptomatic patients and those with symptoms not primarily correlated with COVID-19 during the United Kingdom coronavirus lockdown. Eur J Nucl Med Mol Imaging 48:269-281, 2021
38. Puntmann V, Carerj M, Wieters I, et al: Outcomes of cardiovascular magnetic resonance imaging in patients recently recovered from coronavirus disease 2019 (COVID-19). JAMA Cardiol [Internet] 2020. [cited 2020 Aug 30]. Available from:[Europe PMC free article][Abstract][Google Scholar]
39. Smith MV, Yang M: Reactive axillary lymphadenopathy to COVID-19 vaccination on F18-FDG PET/CT. J Nucl Med Technol 2021
40. Nawwar AA, Searle J, Singh R, et al: Oxford-AstraZeneca COVID-19 vaccination induced lymphadenopathy on [18F] choline PET/CT—not only an FDG finding. Eur J Nucl Med Mol Imaging: 1-2, 2021
41. Eifer M, Tau N, Alhoubani Y, et al: Covid-19 mRNA vaccination: Age and immune status and its association with axillary lymph node PET/CT uptake. J Nucl Med 2021
42. Eshet Y, Tau N, Alhoubani Y, et al: Prevalence of increased FDG PET/CT axillary lymph node uptake beyond 6 weeks after mRNA COVID-19 vaccination. Radiology 2021:210886
43. Avner M, Orevi M, Caplan N, et al: COVID-19 vaccine as a cause for unilateral lymphadenopathy detected by 18F-FDG PET/CT in a patient affected by melanoma. Eur J Nucl Med Mol Imaging: 1-2, 2021
44. Shirone N, Shinkai T, Yamane T, et al: Axillary lymph node accumulation on FDG-PET/CT after influenza vaccination. Ann Nucl Med 26:248-252, 2012
45. Gilliland C: Radiological findings in influenza and pneumonia. J Missouri State Med Assoc 16:413-417, 1919
46. Eslambolchi A, Maliglig A, Gupta A, et al: COVID-19 or non-COVID viral pneumonia: How to differentiate based on the radiologic findings? World J Radiol 12:289, 2020
47. Bray M, Lawler J, Paragas J, et al: Molecular imaging of influenza and other emerging respiratory viral infections. J Infect Dis 203:1348-1359, 2011
48. Bellani G, Guerra L, Pesenti A, et al: Imaging of lung inflammation during severe influenza A: H1N1. Intensive Care Med 36:717-718, 2010
49. Capitanio S, Nordin AJ, Noraini AR, et al: PET/CT in nononcological lung diseases: Current applications and future perspectives. Eur Respir Rev 25:247-258, 2016
50. Hot A, Maunoury C, Poiree S, et al: Diagnostic contribution of positron emission tomography with [18F] fluorodeoxyglucose for invasive fungal infections. Clin Microbiol Infect 17:409-417, 2011
51. Sharma P, Mukherjee A, Karunanithi S, et al: Potential role of 18F-FDG PET/CT in patients with fungal infections. Am J Roentgenol 203:180-189, 2014
52. Ankrah AO, Creemers-Schild D, de Keizer B, et al: The added value of [18F] FDG PET/CT in the management of invasive fungal infections. Diagnostics 11:137, 2021
53. Xu B, Shi P, Wu H, G, et al: Utility of FDG PET/CT in guiding antifungal therapy in acute leukemia patients with chronic disseminated candidiasis. Clin Nucl Med 35:567-570, 2010
54. Douglas A, Thursky K, Worth L, et al: FDG PET/CT imaging in detecting and guiding management of invasive fungal infections: A retrospective comparison to conventional CT imaging. Eur J Nucl Med Mol Imaging 46:166-173, 2019
55. Vanfleteren MJ, Dingemans A-MC, Surmont VF, et al: Invasive aspergillosis mimicking metastatic lung cancer. Front Oncol 8:188, 2018
56. Franzius C, Biermann M, Hülskamp G, et al: Therapy monitoring in aspergillosis using F-18 FDG positron emission tomography. Clin Nucl Med 26:232-233, 2001
57. Vahid B, Wildemore B, Nguyen C, et al: Pulmonary blastomycosis masquerading as metastatic disease in the lung: A case report. Medscape Gen Med 8:31, 2006
58. Hussaini SMQ, Madut D, Tong BC, et al: Pulmonary blastomycosis presenting as primary lung cancer. BMC Infect Dis 18:1-6, 2018
59. Bassett CL, Daniel GB, Legendre AM, et al: Characterization of uptake of 2-deoxy-2-[18F] fluoro-D-glucose by fungal-associated inflammation: The standardized uptake value is greater for lesions of blastomycosis than for lymphoma in dogs with naturally occurring disease. Mol Imag Biol 4:201-207, 2002
60. Teyton P, Baillet G, Hindié E, et al: Hepatosplenic Candidiasis imaged with F-18 FDG PET/CT. Clin Nucl Med 34:439-440, 2009
61. Nguyen BD: F-18 FDG PET/CT imaging of disseminated coccidioidomycosis. Clin Nucl Med 31:568-571, 2006
62. Reyes N, Onadeko OO, Luraschi-Monjagatta MDC, et al: Positron emission tomography in the evaluation of pulmonary nodules among patients living in a coccidioidal endemic region. Lung 192:589-593, 2014
63. Nia BB, Nia ES, Osondu N, et al: Tip of the Iceberg: 18F-FDG PET/CT diagnoses extensively disseminated coccidioidomycosis with cutaneous lesions. Southwest JPulm Crit Care 15:28-31, 2017
64. Choe YH, Moon H, Park SJ, et al: Pulmonary cryptococcosis in asymptomatic immunocompetent hosts. Scand J Infect Dis 41:602-607, 2009

65. Huang C-J, You D-L, Lee P-I, et al: Characteristics of integrated 18F-FDG PET/CT in pulmonary cryptococcosis. Acta Radiol 50:374-378, 2009
66. Wang S-y, Chen G, Luo D-l, et al: 18F-FDG PET/CT and contrast-enhanced CT findings of pulmonary cryptococcosis. Eur J Radiol 89:140-148, 2017
67. Igai H, Gotoh M, Yokomise H: Computed tomography (CT) and positron emission tomography with [18F] fluoro-2-deoxy-D-glucose (FDG-PET) images of pulmonary cryptococcosis mimicking lung cancer. Eur J Cardiothorac Surg 30:837-839, 2006
68. LdPGd Farias, Padilha IG, et al: Pulmonary cryptococcosis mimicking neoplasm in terms of uptake PET/CT. Radiol Bras 51:63-64, 2018
69. Kunin JR, Blasco LF, Hamid A, et al: Thoracic endemic fungi in the United States: Importance of patient location. Radiographics 41:380-398, 2021
70. Croft DR, Trapp J, Kernstine K, et al: FDG-PET imaging and the diagnosis of non-small cell lung cancer in a region of high histoplasmosis prevalence. Lung Cancer 36:297-301, 2002
71. Kadaria D, Freire AX, SultanAli I, et al: Dual time point positron emission tomography/computed tomography scan in evaluation of intrathoracic lesions in an area endemic for histoplasmosis and with high prevalence of sarcoidosis. Am J Med Sci 346:358-362, 2013
72. Nagelschneider AA, Broski SM, Holland WP, et al: The flip-flop fungus sign: An FDG PET/CT sign of benignity. Am J Nucl Med Mol Imaging 7:212, 2017
73. Mittal B, Parihar A, Kumar R, et al: 18F-FDG PET/CT in initial staging and response assessment in patients with histoplasmosis. J Nucl Med 60:225, 2019
74. Dang C-J, Li Y-J, Zhan F-H, et al: The appearance of pulmonary mucormycosis on FDG PET/CT. Clin Nucl Med 37:801-803, 2012
75. Ravani SA, Agrawal GA, Leuva PA, et al: Rise of the phoenix: Mucormycosis in COVID-19 times. Indian J Ophthalmol 69:1563-1568, 2021
76. Harkirat S, Anana S, Indrajit L, et al: Pictorial essay: PET/CT in tuberculosis. Indian J Radiol Imaging 18:141, 2008
77. Priftakis D, Riaz S, Zumla A, et al: Towards more accurate 18F-fluorodeoxyglucose positron emission tomography (18F-FDG PET) imaging in active and latent tuberculosis. Int J Infect Dis 92:S85-S90, 2020
78. Naftalin CM, Leek F, Hallinan JT, et al: Comparison of 68Ga-DOTA-NOC with 18F-FDG using PET/MRI imaging in patients with pulmonary tuberculosis. Sci Rep 10:1-9, 2020
79. Stelzmueller I, Huber H, Wunn R, et al: 18F-FDG PET/CT in the initial assessment and for follow-up in patients with tuberculosis. Clin Nucl Med 41:e187-e194, 2016
80. Vorster M, Sathekge MM, Bomanji J: Advances in imaging of tuberculosis: The role of 18F-FDG PET and PET/CT. Curr Opin Pulm Med 20:287-293, 2014
81. Lin PL, Ford CB, Coleman MT, et al: Sterilization of granulomas is common in active and latent tuberculosis despite within-host variability in bacterial killing. Nat Med 20:75-79, 2014
82. Malherbe ST, Chen RY, Dupont P, et al: Quantitative 18F-FDG PET-CT scan characteristics correlate with tuberculosis treatment response. EJNMMI Res 10:8, 2020
83. Shimizu Y, Hashizume Y: PET/CT for monitoring the therapeutic response in a patient with abdominal lymph node tuberculosis after colon cancer resection. Kekkaku:[Tuberculosis] 87:707-712, 2012
84. Sood A, Mittal BR, Modi M, et al: 18F-FDG PET/CT in tuberculosis: Can interim PET/CT predict the clinical outcome of the patients? Clin Nucl Med 45:276-282, 2020
85. Lawal IO, Fourie BP, Mathebula M, et al: 18F-FDG PET/CT as a noninvasive biomarker for assessing adequacy of treatment and predicting relapse in patients treated for pulmonary tuberculosis. J Nucl Med 61:412-417, 2020
86. Sathekge M, Maes A, Van de Wiele C: FDG-PET imaging in HIV infection and tuberculosis. Semin Nucl Med 43:349-366, 2013
87. Mao XB, Li N, Huang ZS, et al: 18F-FDG PET−CT diagnosis of tuberculosis in celiac lymph nodes. Int J Gen Med 13:1335, 2020
88. Hannah CE, Ford BA, Chung J, et al: Characteristics of nontuberculous mycobacterial infections at a Midwestern Tertiary Hospital: A retrospective study of 365 patients. Open Forum Infectious Diseases, 7. Oxford University Press US, ,
89. Ose N, Takeuchi Y, Kitahara N, et al: Analysis of pulmonary nodules caused by nontuberculous mycobacteriosis in 101 resected cases: multicenter retrospective study. J Thorac Dis 13:977, 2021
90. Del Giudice G, Bianco A, Cennamo A, et al: Lung and nodal involvement in nontuberculous mycobacterial disease: PET/CT role. Biomed Res Int: 2015, 2015
91. Demura Y, Tsuchida T, Uesaka D, et al: Usefulness of 18 F-fluorodeoxyglucose positron emission tomography for diagnosing disease activity and monitoring therapeutic response in patients with pulmonary mycobacteriosis. Eur J Nucl Med Mol Imaging 36:632-639, 2009
92. Namkoong H, Fujiwara H, Ishii M, et al: Immune reconstitution inflammatory syndrome due to Mycobacterium avium complex successfully followed up using 18 F-fluorodeoxyglucose positron emission tomography-computed tomography in a patient with human immunodeficiency virus infection: a case report. BMC Med Imaging 15:1-6, 2015
93. Gholamrezanezhad A, Mirpour S, Mariani G: Future of nuclear medicine: SPECT versus PET. J Nucl Med 50:16N, 2009