Flow-Diversion Treatment for Unruptured ICA Bifurcation Aneurysms with Unfavorable Morphology for Coiling

F. Cagnazzo, I. Derraz, C. Dargazanli, P.-H. Lefevre, I. Coelho Ferreira, G. Gascou, C. Riquelme, A. Fanti, R. Ahmed, J. Frandon, A. Bonafe, and V. Costalat

ABSTRACT

BACKGROUND AND PURPOSE: Few reports described flow diversion for ICA bifurcation aneurysms. Our aim was to provide further insight into flow diversion for ICA bifurcation aneurysms difficult to treat with other strategies.

MATERIALS AND METHODS: Consecutive patients receiving flow diverters for unruptured ICA bifurcation aneurysms were collected. Aneurysm occlusion (O'Kelly-Marotta grading scale) and clinical outcomes were evaluated.

RESULTS: Twenty saccular ICA bifurcation aneurysms were treated with the Pipeline Embolization Device deployed from the M1 to the ICA, covering the aneurysm and the A1 segment. All patients presented with an angiographic visualized contralateral flow from the anterior communicating artery. Mean aneurysm size was 6.5 (SD, 3.2) mm (range, 4.5–20 mm). All lesions had an unfavorable dome-to-neck ratio (mean/median, 1.6/1.6; range, 0.8–2.8; interquartile range = 0.5) or aspect ratio for coiling (mean/median = 1.5/1.55; range, 0.8–2.5; interquartile range = 0.6). One was a very large aneurysm (20 mm). Nineteen medium-sized lesions were completely occluded during the angiographic follow-up (13 months). No cases of aneurysm rupture or retreatment were reported. No adverse events were described. Aneurysm occlusion was associated with the asymptomatic flow modification of the covered A1 that was occluded and contralaterally filled among 10 patients (50%), narrowed among 9 patients (45%), and unchanged in 1 subject (5%). There was no difference in the mean initial diameter of the occluded (2.1 [SD 0.4] mm; range, 1.6–3 mm) and narrowed (2 [SD, 0.2] mm; range, 1.7–2.6 mm) A1 segments.

CONCLUSIONS: Medium-sized unruptured ICA bifurcation aneurysms with unfavorable morphology for coiling can be treated with M1 ICA flow diversion. Aneurysm occlusion is associated with flow modifications of the covered A1 that seems safe in the presence of a favorable collateral anatomy through the anterior communicating artery complex.

ABBREVIATIONS: AcomA = anterior communicating artery; ICAbifA = ICA bifurcation aneurysm; OKM = O'Kelly-Marotta grading scale; PED = Pipeline Embolization Device; WEB = Woven EndoBridge

The rapid expansion of the use of flow diversion for the treatment of intracranial aneurysms is quickly outpacing the availability of clinical evidence, and most current use of the flow-diversion strategy is off-label. Given their capability to redirect the flow, these devices can be used to treat bifurcation aneurysms such as ICA bifurcation aneurysms (ICAbifAs). These lesions are relatively uncommon, representing 2%–9% of all intracranial aneurysms[1] and are generally under-represented in the endovascular series.[2] In addition, treatment of ICAbifAs remains challenging: Clipping carries potential morbidity due to the dissection of regional perforators,[3] and coiling has a higher recurrence rate.[4] Advanced endovascular techniques, such as stent-assisted coiling or Y-stent placement, are suitable options for lesions with an unfavorable dome-to-neck ratio or aspect ratio, but they can be technically demanding.[5-7] Intrasaccular flow disruptors such as the Woven Endobridge (WEB; MicroVention)[8,9] or other new devices such as the pCONus aneurysm implant (phenox)[10] and the PulseRider aneurysm neck reconstruction device (Pulsar Vascular)[11] are also promising strategies to treat lesions too complex for simple coiling. Flow diversion on the ICA terminus region has rarely been reported, and very few series focused on the treatment of ICAbifAs with a flow-redirection technique.[12-14] This technique can be an alternative option to treat these lesions. The concept of the flow modification for ICAbifAs was first reported by Nossek et al,[13,14] describing the angiographic results among 4 patients treated with a flow diverter deployed into the ICA M1 segment. We described the

Received April 10, 2020; accepted after revision December 4.

From the Neuroradiology Department (F.C., I.D., C.D., P.-H.L., G.G., C.R., A.F., R.A., A.B., V.C.), University Hospital Güi de Chauliac, Centre Hospitalier Universitaire de Montpellier, Montpellier, France; Neurosurgical Department (I.C.F.), Hospital Santa Lucia, Distrito Federal, Brazil; and Medical Imaging Group (J.F.), Centre Hospitalier Universitaire Nimes, University of Montpellier, Montpellier, France.

Please address correspondence to Federico Cagnazzo, MD, Neuroradiology Department, CHU Gui de Chauliac, 80 Ave Augustin Fliche, 34000 Montpellier, France; e-mail: f.cagnazzo86@gmail.com

Indicates article with online supplemental data.

http://dx.doi.org/10.3174/ajnr.A7125

largest experience of flow diversion for unruptured ICAbifAs, analyzing 20 cases treated with a single PED deployed from the proximal M1 to the distal supraclinoid ICA, covering the A1, for aneurysm treatment.

MATERIALS AND METHODS

Patient Selection

The Montpellier hospital institutional review board approved this retrospective study. Our institutional prospectively maintained data base of Endovascular Treatment of Intracranial Aneurysms was reviewed by 2 and, in case of inconsistency, 3 investigators. All cases of ICAbifAs treated with flow-diverter stents between January 2014 and August 2020 were analyzed. Aneurysm and patient characteristics, as well as treatment-related and clinical outcomes, were collected. A multidisciplinary consensus was performed to select the most appropriate treatment strategy.

Reasons for Flow-Diversion Strategy and Technical Aspects

Technical aspects of flow diversion in the ICA bifurcation region were described in our previously published experience.[15] ICAbifAs were treated with flow diversion mainly for the following reasons: 1) large-neck lesions difficult to treat with coiling; 2) the presence of an unfavorable projection of the aneurysm dome for the microcatheterization and coiling; and 3) unfavorable dome-to-neck ratio and/or aspect ratio (Online Supplemental Data). A dome-to-neck ratio of <2 and an aspect ratio of <1.6 have been considered unfavorable for simple coiling,[16] and flow diversion was evaluated.

Flow diverters were deployed from the proximal M1 to the supraclinoid ICA, covering the aneurysm and the A1 segment of the anterior cerebral artery. Sizing of the device was accurately performed, while choosing the shortest possible PED to avoid, as much as possible, the coverage of the M1 perforators and the ophthalmic artery, with the aim of reducing potential ischemic complications.[17-19] Because of the more distal origin at the level of the supraclinoid ICA, the anterior choroidal artery, was, in general, covered by the device.

During the diagnostic angiography performed before treatment, the presence of a patent anterior communicating artery (AcomA) was tested in all patients through a contralateral ICA angiogram, while the ipsilateral common carotid artery was temporarily occluded by manual compression. Accordingly, we visualized 2 angiographic patterns: 1) patency of the AcomA: the A1 and the MCA ipsilateral to the target aneurysm fully visualized during the contralateral injection; and 2) absence (or stenosis) of the AcomA: the A1 segment ipsilateral to the target lesion not visualized. Flow diversion with the coverage of the A1 was performed only in case of a patent AcomA.[15]

Antiplatelet Therapy

All cases of flow diversion were unruptured. Antiplatelet therapy consisted of daily dual-antiplatelet drugs with aspirin, 75 mg, and clopidogrel, 75 mg, starting 5 days before treatment and maintained for 6 months (until the first follow-up). After 6 months, clopidogrel was normally stopped, and aspirin, 75 mg, was continued for an additional 6 months. Aspirin was continued for a longer period in case of the following: 1) the presence of a patient's vascular risk factors; 2) in-stent stenosis of $>50\%$; or 3) ischemic events related to the stent.

The VerifyNow P2Y12 assay (Accumetrics) was used to test the platelet inhibition (platelet reactivity unit). In case of platelet inhibition of $<30\%$, patients were treated with an additional dose of clopidogrel, 150 mg, or were switched to prasugrel, 10–20 mg. Aspirin VerifyNow platelet reactivity was not tested. Intravenous heparinization was performed for all patients (activated clotting time maintained above 250 seconds).

Description of the Procedure

All patients were treated under general anesthesia via a transfemoral approach. A triaxial access was adopted in all patients. A 6F-long femoral sheath introducer was used. The size of the implanted flow diverter was chosen via biplane 3D rotational angiography of the parent artery and target aneurysm. Preimplantation virtual device simulation was routinely performed with Sim&Size software (Sim&Cure), and the size of the flow diverter was chosen on the basis of the simulation.[15,20]

The stent was unsheathed under roadmap guidance through a Phenom (Medtronic) 0.027-inch microcatheter navigated beyond the aneurysm neck. The correct deployment and vessel wall apposition were visualized with VasoCT (Philips Healthcare), with a diluted iodinated contrast medium.

Clinical and Radiologic Assessment

Clinical evaluation was performed in the periprocedural period (24–48 hours) and during long-term follow-up (6, 12, and 24 months after treatment). The safety of the treatment was evaluated on the basis of the presence of new symptoms or new neurologic deficits related to the procedure. Treatment-related complications were further classified as transient (no impact on the neurologic status) or permanent (associated with an irreversible worsening of the neurologic condition).

Aneurysm occlusion was evaluated with MRA at 6 months and with DSA at 12 and 24 months. Angiographic occlusion was assessed according to the O'Kelly-Marotta grading scale (OKM)[21] (occlusion grade: A = total, B = subtotal, C = entry remnant, D = no filling; degree of aneurysmal stasis: during the 1 = arterial, 2 = capillary, 3 = venous phase).[15,22] Imaging analysis was performed by 2 readers (not directly involved in treatments) with 3 and 5 years' experience in interventional neuroradiology.

Because flow diverters were deployed from the M1 segment to the supraclinoid ICA, we studied the angiographic outcome of the covered A1 artery. Findings about A1 flow modification were reported in our previously published experience.[15] When a collateral circulation from the AcomA complex is present, the anterograde flow from the ipsilateral ICA decreases, allowing the hemodynamic compensation from the contralateral ICA through the AcomA. Accordingly, the status of the covered A1 was evaluated immediately after stent deployment and during angiographic follow-up as the following: 1) patent (unchanged), 2) narrowed (because of partial contralateral flow from the AcomA), and 3) occluded (absence of anterograde flow due to complete flow reversal from the AcomA). In addition, the radiologic and clinical events related to the coverage of the branch were classified as 1) absence of either radiologic or clinical events related to the coverage of the A1

segment; and 2) symptomatic lesions on the territory of the covered A1.

Statistical Analysis

The overall frequency (percentage) and 95% confidence interval were calculated for all results. The Wald method was used to calculate the CI for event rates. Statistical analysis was performed with QuickCalcs software (GraphPad Software). A 2-tailed *t* test was used for continuous data, and the χ^2 test, for categoric variables. Statistical significance was set at $P < .05$.

RESULTS

Baseline Population Characteristics

Twenty consecutive patients (16 women, 4 men; mean age, 53 [SD, 12.6] years; range, 34–79 years) with 20 saccular unruptured ICAbifAs were treated with flow-diverter stents deployed from the ICA to the M1 (Online Supplemental Data). All patients presented with an mRS of 0 before treatment, except 2 subjects with mRS 2 and mRS 3 in relation to a previous SAH. Six patients (30%) were smokers, 4 patients (20%) had hypertension, and 1 (5%) was a smoker with hypertension, whereas 9 (45%) did not present with vascular risk factors (details in the Online Supplemental Data).

Aneurysm and Treatment Characteristics

All 20 ICAbifAs were saccular and unruptured lesions with a mean size of 6.5 (SD, 3.2) mm (range, 4.5–20 mm). All lesions had an unfavorable dome-to-neck ratio (mean/median = 1.6/1.6; range, 0.8–2.8; interquartile range = 0.5) or aspect ratio for coiling (mean/median = 1.5/1.55; range, 0.8–2.5; interquartile range = 0.6). Sixteen aneurysms had an aspect ratio of <1.6, while 15 lesions had a dome-to-neck ratio of <2 (Online Supplemental Data). Nineteen aneurysms were medium-sized (5–9 mm), and 1 was very large (20 mm).

Based on the relationship between the parent artery and the origin of the aneurysm neck, there were 2 types of configurations: 1) Fifteen aneurysms presented with the neck at the midpoint of the ICA terminus; and 2) five aneurysms had the neck deviated to the origin of the A1 segment (ICA terminus to A1). Three patients had an ipsilateral ICA aneurysm (2 posterior communicating artery aneurysms and 1 ophthalmic artery aneurysm) that was covered with the same flow diverter. Four aneurysms (20%) were previously coiled and treated with flow diversion because of recanalization. Among these, 3 (15%) were previously ruptured and 1 had a 20-mm ICAbifA that was treated with flow-diversion–assisted coiling (patient 13).

A single PED was used for all patients.

Angiographic Outcome

The PED was successfully deployed from the M1 to the ICA in all patients.

The mean angiographic follow-up was 13 months (range, 9–24 months). Complete occlusion (OKM D) was achieved among 19 medium-sized (95%) aneurysms (Figs 1 and 2). Incomplete occlusion (OKM B) was found in 1 very large aneurysm (5%). This incompletely occluded aneurysm was stable at the last angiographic follow-up. No cases of aneurysm rupture were reported. There were no cases of in-stent stenosis.

Clinical Outcome and Procedure-Related Complications

There were no transient or permanent events related to the treatment. At the last angiographic follow-up (mean follow-up, 13 months), covered A1 vessels were occluded (complete flow reversal from the contralateral side) among 10 patients (50%) (Fig 1), narrowed among 9 patients (45%) (Fig 2), and patent (unchanged in diameter) in 1 subject (5%). A1 occlusion or narrowing was not associated with clinical adverse events or radiologic asymptomatic lesions at MR imaging. The mean diameter of the covered A1 presenting with occlusion at follow-up was 2.1 (SD, 0.4) mm (range, 1.6–3 mm), while those showing narrowing presented with a mean diameter of 2 (SD, 0.2) mm (range, 1.7–2.6 mm; $P > .05$). Only 1 patient (patient 13) with a 20-mm aneurysm showed patency of the covered A1 segment associated with incomplete occlusion of the aneurysm.

DISCUSSION

Our study showed that flow-diversion treatment for medium-sized ICAbifAs was a feasible and safe alternative endovascular strategy associated with quite a high rate of aneurysm occlusion. Currently, only a few reports with a small number of patients explored flow diversion in the ICA bifurcation region, and the present series could add further data about this strategy.

The concept of this strategy is based on flow redirection and flow remodeling in the ICA terminus region. This mechanism was reported >10 years ago by Kallmes et al,[20] who reported in an animal study that the coverage of elastase-induced aneurysms and adjacent arteries allowed occlusion of the aneurysms without compromising the branch arteries. This report was mainly related to the absence of collateral circulation causing a continued flow in these vessels, permitting ongoing patency. On the other hand, in the literature authors reported, in case of a well represented collateral circulation, the pressure gradient across the stent being normally not enough to maintain the patency of the covered artery, leading to progressive and usually asymptomatic branch occlusion.[21-24]

The ICA terminus region provides unique challenges for endovascular treatment. First, aneurysms of the bifurcation, being the highest point of the circle of Willis, are often wide-neck lesions subjected to constant high hemodynamic stress leading to aneurysm growth, risk of rupture, and recanalization.[25] In addition, aneurysms of this region are close to the medial perforators (penetrating the medial portion of the anterior perforating substance).[26] The flow-remodeling strategy, using a flow diverter deployed from the M1 to the ICA, allowed a hemodynamic redirection, decreasing the anterograde flow into the A1 and the ICA terminus aneurysm. In our series, ICA M1 flow diverters were associated with delayed reversal of the flow in the covered A1 segment that was retrogradely filled through the AcomA. This phenomenon caused a slow flow in the adjacent aneurysm, leading to aneurysm thrombosis, with a contralateral filling of the A1 and the medial lenticulostriate arteries. Accordingly, this mechanism, while resulting in >90% of the complete occlusion of the aneurysm, was associated with no clinical and radiologic events related to impairment of the perforators.

On the basis of our results and treatment strategy, 2 main learning points should be stressed. First, the contralateral supply of the A1 with manual compression of the carotid artery is crucial

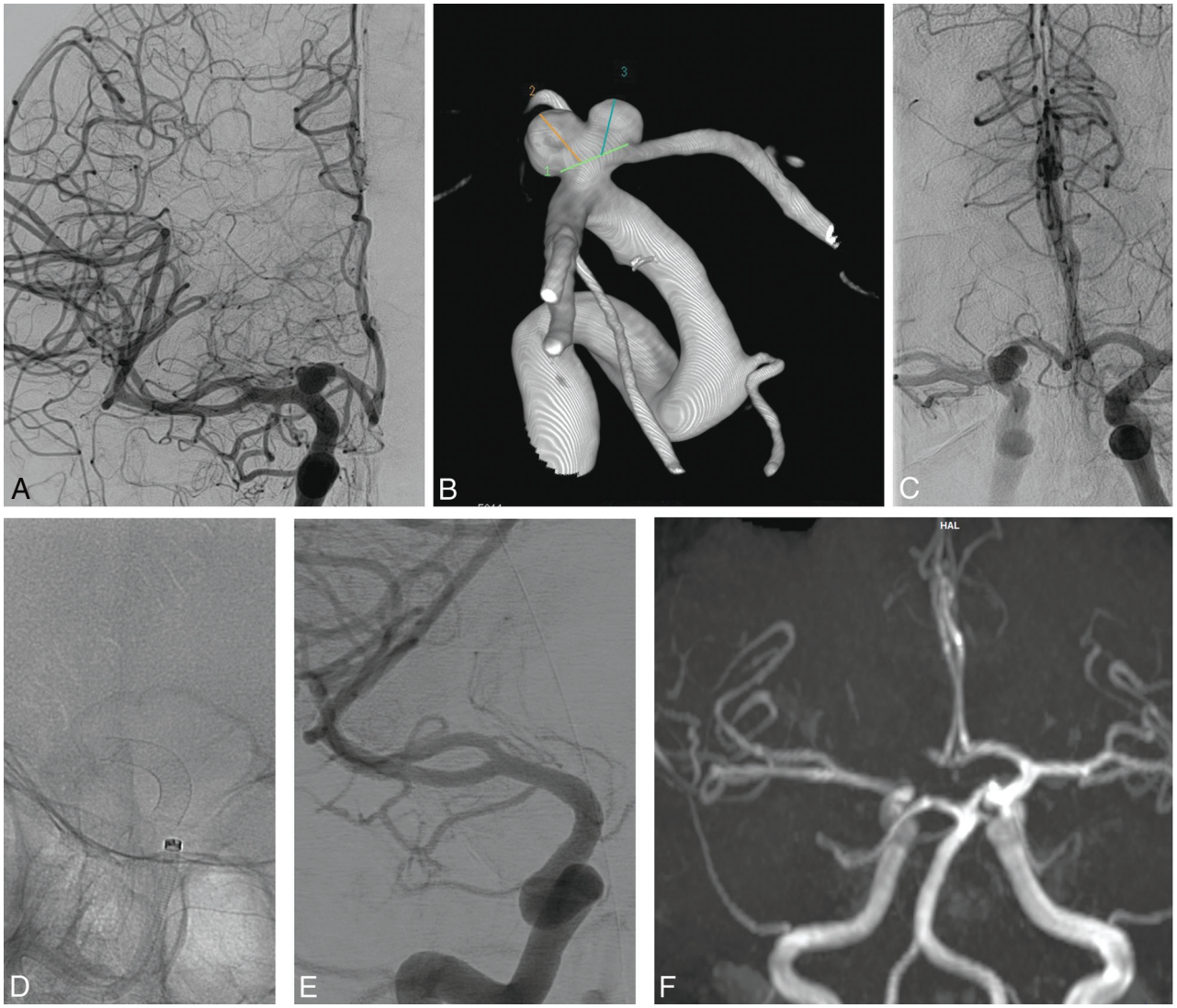

FIG 1. Patient 4. *A*, A right ICA angiogram (anterior-posterior view) shows a wide-neck medium-sized ICA terminus aneurysm. *B*, 3D reconstruction depicts a bilobate irregular shape of the aneurysm with the right A1 segment originating from the neck. *C*, Contralateral ICA angiogram demonstrates the patency of the AcomA with retrograde flow into the left ICA terminus segment. *D*, A 4.5 × 14 mm PED is deployed from the M1 (before the temporal branch) to the supraclinoid ICA, avoiding, as much as possible, the ostium of the ophthalmic artery. *E*, After 12 months, the aneurysm is completely occluded, and the right A1 shows absence of anterograde flow. The lateral lenticulostriate arteries and the temporal branch of the MCA are patent. *F*, The time-of-flight 3D reconstruction sequence shows absence of flow into the aneurysm (OKM D occlusion) and retrograde filling of the right anterior cerebral artery from the contralateral side through the AcomA.

to determine the safety of the coverage and flow remodeling of the ipsilateral A1. Second, accurate sizing of the device is essential and was performed with the use of virtual simulation, choosing the shortest flow diverter to avoid the coverage of the ophthalmic artery (when possible) and to reduce potential ischemic complications related to the coverage of the M1 perforators. Nossek et al[14] reported complete occlusion without neurologic adverse events among 4 ICAbifAs treated with flow redirection from the supraclinoid ICA to the M1. On the other hand, a recent series of flow diversion for 10 ICA terminus aneurysms showed fewer promising results with this technique, reporting 50% adequate occlusion and 2 transient complications.[12] However, 50% of the reported aneurysms were fusiform lesions, and 60% were large or very large lesions. Conversely, our series explored medium-sized saccular aneurysms difficult to treat with coiling due to their morphologic characteristics. Indeed, all lesions had an unfavorable dome-to-neck ratio (mean/median = 1.6/1.6) or aspect ratio for coiling (mean/median = 1.5/1.55), and flow reversal was effective among 19 of 20 lesions. Only 1 patient with a 20-mm aneurysm showed incomplete occlusion.

When we investigated the literature, the rate of long-term complete/near-complete occlusion after coiling of ICAbifAs was approximately 80%, with 6% procedure-related morbidity, a 3% rate of intraprocedural perforation, and a 14% retreatment rate.[4] One of the most important findings of our study was the considerably high rate of stable occlusion. A series of coiling or balloon-assisted coiling of ICA terminus aneurysms reported rates of recanalization between 7% and 40%.[27] This outcome is likely in relation to the direct arterial pulsation and hemodynamic stress due to the T-bifurcation configuration of these lesions.

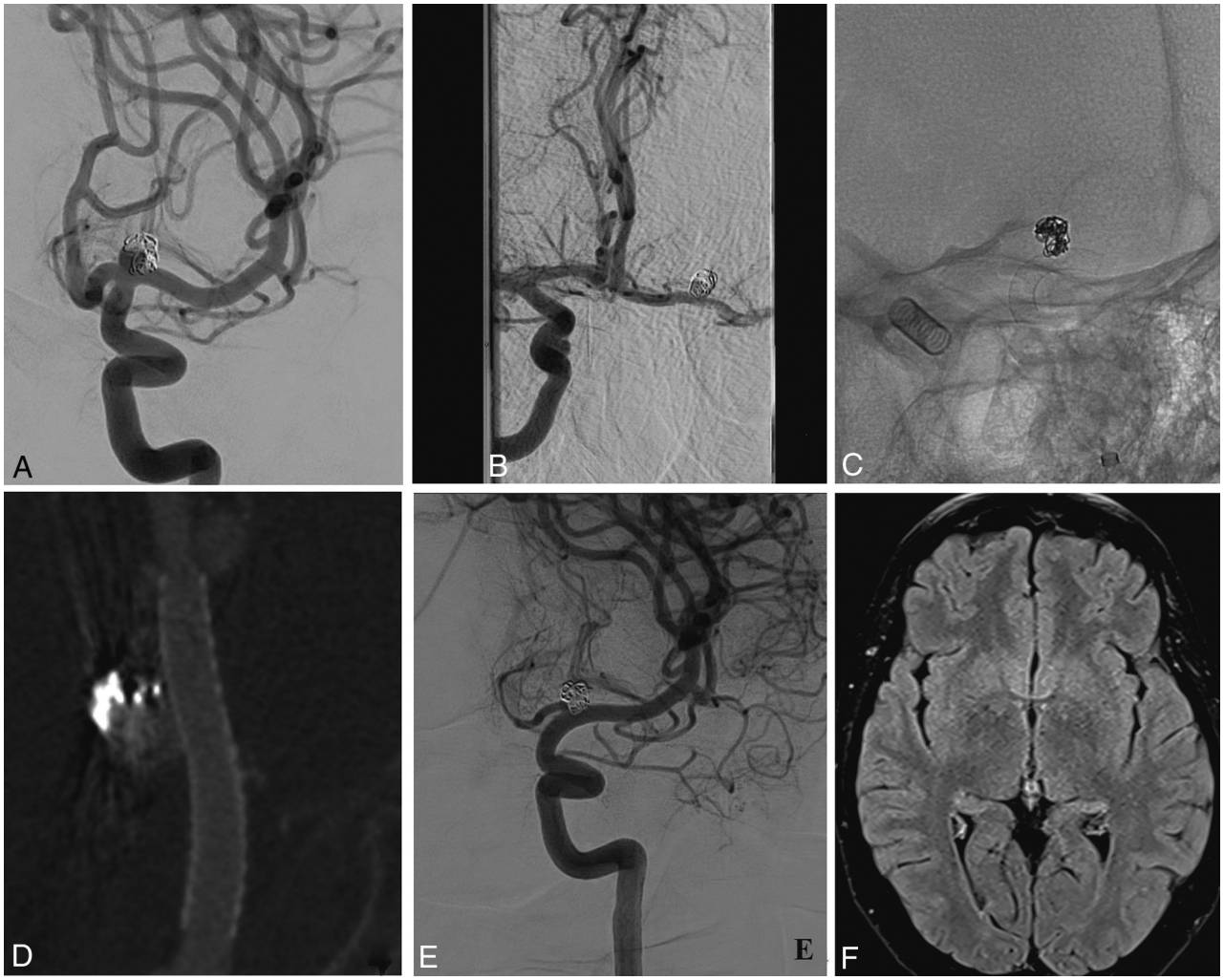

FIG 2. Patient 8. *A*, The left ICA (frontal view) depicts a previously ruptured and recanalized medium-sized ICAbifA treated with coiling during the acute phase. *B*, The presence of contralateral filling from the AcomA. *C*, A PED, 3.5 × 12 mm, is successfully deployed covering the aneurysm and the left A1 segment. The PED was delivered before the origin of the M1 lenticulostriate arteries. *D*, Flat panel angiography confirms good vessel wall apposition of the stent. *E*, A 14-month angiographic follow-up shows complete aneurysm occlusion as well as flow remodeling of the covered A1 with narrowing but without any lesions on the FLAIR sequences (*F*).

It has been shown that large-neck aneurysms (≥4 mm), with a dome-to-neck ratio of <2 and an aspect ratio of <1.6, can predict the need for adjunctive techniques in the endovascular treatment of intracranial aneurysms.[15] In our series, flow diversion was adopted as an alternative strategy for lesions having unfavorable aspect and dome-to-neck ratios. However, other techniques can be used for the treatment of these lesions. Y-stent placement[28] or T-stent placement[7] has been reported to be associated with a high occlusion rate among large-neck bifurcation aneurysms. Recently, Pierot et al,[29] in a series of aneurysms treated with the WEB, described 14 ICAbifAs showing 36% and 29% complete and near-complete occlusion, respectively; the rate of occlusion after WEB treatment for ICA terminus aneurysms was lower compared with other locations, such as the AcomA and MCA.

Finally, all 19 occluded aneurysms were associated with occlusion or narrowing of the covered A1 due to flow reversal through the AcomA. Inversely, the only patient having incomplete aneurysm occlusion showed an unchanged diameter of the A1. A recent series reported outcomes of 42 A1 arteries covered with flow diverters in the presence of a collateral supply[30] and described 31% and 52% asymptomatic occlusion and narrowing of the artery, respectively. This finding emphasizes the concept that flow remodeling for ICAbifA treatment can be effective in case of good collateral circulation from the AcomA, allowing flow reversal in the covered A1 and causing aneurysm thrombosis without neurologic sequalae.

Limitations of the Study

Our study has several limitations. This is a single-center, retrospective series with a relatively small number of patients. The influence of the platelet inhibition rate on the aneurysm occlusion or flow modifications on the covered A1 was not studied. Results cannot be generalized because most of the included aneurysms were medium-sized lesions.

CONCLUSIONS

In our experience, flow remodeling in the ICA terminus region with M1 ICA flow diversion is associated with high rates of

occlusion of medium-sized unruptured ICAbifAs. In the presence of a favorable collateral anatomy through the AcomA complex, flow diversion can be a safe and effective alternative strategy for the treatment of these lesions.

Disclosures: Vincent Costalat—*UNRELATED*: *Consultancy*: Stryker, Medtronic, Balt, Cerenovus, MicroVention; *Grants/Grants Pending*: Stryker, Medtronic, Balt, Cerenovus, MicroVention*; *Payment for Development of Educational Presentations*: Stryker, Medtronic, Balt, Cerenovus, MicroVention. Pierre-Henri Lefevre—*UNRELATED*: *Payment for Development of Educational Presentations*: Medtronic. Alain Bonafe—*UNRELATED*: *Consultancy:* Medtronic, Stryker, MicroVention.* *Money paid to the institution.

REFERENCES

1. Lehecka M, Dashti R, Romani R, et al. **Microneurosurgical management of internal carotid artery bifurcation aneurysms.** *Surg Neurol* 2009;71:649–67 CrossRef Medline
2. Wiebers DO, Whisnant JP, Huston J 3rd, et al. **Unruptured intracranial aneurysms: natural history, clinical outcome, and risks of surgical and endovascular treatment.** *Lancet* 2003;362:103–10 CrossRef Medline
3. Gonzalez-Darder JM, Gonzalez-Lopez P, Botella-Macia L. **Microsurgical treatment of internal carotid bifurcation aneurysms** [in Spanish]. *Neurocirugia (Astur)* 2010;21:205–10 CrossRef Medline
4. Morales-Valero SF, Brinjikji W, Murad MH, et al. **Endovascular treatment of internal carotid artery bifurcation aneurysms: a single-center experience and a systematic review and meta-analysis.** *AJNR Am J Neuroradiol* 2014;35:1948–53 CrossRef Medline
5. Oishi H, Yamamoto M, Nonaka S, et al. **Endovascular therapy of internal carotid artery bifurcation aneurysms.** *J Neurointerv Surg* 2013;5:400–04 CrossRef Medline
6. Fargen KM, Mocco J, Neal D, et al. **A multicenter study of stent-assisted coiling of cerebral aneurysms with a Y configuration.** *Neurosurgery* 2013;73:466–72 CrossRef Medline
7. Aydin K, Stracke CP, Barburoglu M, et al. **Long-term outcomes of wide-necked intracranial bifurcation aneurysms treated with T-stent-assisted coiling.** *J Neurosurg* 2019 Dec 6. [Epub ahead of print] CrossRef Medline
8. Arthur AS, Molyneux A, Coon AL, et al. WEB-IT Study Investigators. **The safety and effectiveness of the Woven EndoBridge (WEB) system for the treatment of wide-necked bifurcation aneurysms: final 12-month results of the pivotal WEB Intrasaccular Therapy (WEB-IT) study.** *J Neurointerv Surg* 2019;11:924–30 CrossRef Medline
9. Pierot L, Gubucz I, Buhk JH, et al. **Safety and efficacy of aneurysm treatment with the WEB: results of the WEBCAST 2 study.** *AJNR Am J Neuroradiol* 2017;38:1151–55 CrossRef Medline
10. Sorenson TJ, Iacobucci M, Murad MH, et al. **The pCONUS bifurcation aneurysm implants for endovascular treatment of adults with intracranial aneurysms: a systematic review and meta-analysis.** *Surg Neurol Int* 2019;10:24 CrossRef Medline
11. Spiotta AM, Chaudry MI, Turner RD, et al. **An update on the Adjunctive Neurovascular Support of Wide-Neck Aneurysm Embolization and Reconstruction Trial: 1-year safety and angiographic results.** *AJNR Am J Neuroradiol* 2018;39:848–51 CrossRef Medline
12. Pujari A, Howard BM, Madaelil TP, et al. **Pipeline Embolization Device treatment of internal carotid artery terminus aneurysms.** *J NeuroIntervent Surg* 2019;11:485–88 CrossRef Medline
13. Nossek E, Chalif DJ, Chakraborty S, et al. **Modifying flow in the ICA bifurcation: Pipeline deployment from the supraclinoid ICA extending into the M1 segment—clinical and anatomic results.** *AJNR Am J Neuroradiol* 2014;35:2125–29 CrossRef Medline
14. Nossek E, Chalif DJ, Levine M, et al. **Modifying flow in the ACA-ACoA complex: endovascular treatment option for wide-neck internal carotid artery bifurcation aneurysms.** *J Neurointerv Surg* 2015;7:351–56 CrossRef Medline
15. Brinjikji W, Cloft HJ, Kallmes DF. **Difficult aneurysms for endovascular treatment: overwide or undertall?** *AJNR Am J Neuroradiol* 2009;30:1513–17 CrossRef Medline
16. Rangel-Castilla L, Munich SA, Jaleel N, et al. **Patency of anterior circulation branch vessels after Pipeline embolization: longer-term results from 82 aneurysm cases.** *J Neurosurg* 2017;126:1064–69 CrossRef Medline
17. Rouchaud A, Leclerc O, Benayoun Y, et al. **Visual outcomes with flow-diverter stents covering the ophthalmic artery for treatment of internal carotid artery aneurysms.** *AJNR Am J Neuroradiol* 2015;36:330–36 CrossRef Medline
18. Touze R, Touitou V, Shotar E, et al. **Long-term visual outcome in patients treated by flow diversion for carotid-ophthalmic aneurysms.** *J Neurointerv Surg* 2018;10:1067–73 CrossRef Medline
19. O'Kelly CJ, Krings T, Fiorella D, et al. **A novel grading scale for the angiographic assessment of intracranial aneurysms treated using flow diverting stents.** *Interv Neuroradiol* 2010;16:133–37 CrossRef Medline
20. Kallmes DF, Ding YH, Dai D, et al. **A new endoluminal, flow-disrupting device for treatment of saccular aneurysms.** *Stroke* 2007;38:2346–52 CrossRef Medline
21. Puffer RC, Kallmes DF, Cloft HJ, et al. **Patency of the ophthalmic artery after flow diversion treatment of paraclinoid aneurysms.** *J Neurosurg* 2012;116:892–96 CrossRef Medline
22. Gascou G, Lobotesis K, Brunel H, et al. **Extra-aneurysmal flow modification following Pipeline embolization device implantation: focus on regional branches, perforators, and the parent vessel.** *AJNR Am J Neuroradiol* 2015;36:725–31 CrossRef Medline
23. Cagnazzo F, Cappucci M, Dargazanli C, et al. **Flow-diversion effect of LEO stents: aneurysm occlusion and flow remodeling of covered side branches and perforators.** *AJNR Am J Neuroradiol* 2018;39:2057–63 CrossRef Medline
24. Cagnazzo F, Lefevre PH, Mantilla D, et al. **Patency of the supraclinoid internal carotid artery branches after flow diversion treatment: a meta-analysis.** *J Neuroradiol* 2019;46:9–14 CrossRef Medline
25. La Pira B, Brinjikji W, Burrows AM, et al. **Unruptured internal carotid artery bifurcation aneurysms: general features and overall results after modern treatment.** *Acta Neurochir (Wien)* 2016;158:2053–59 CrossRef Medline
26. Grand W. **Microsurgical anatomy of the proximal middle cerebral artery and the internal carotid artery bifurcation.** *Neurosurgery* 1980;7:215–18 CrossRef Medline
27. Ban SP, Hwang G, Kim CH, et al. **Risk factor analysis of recanalization and retreatment for patients with endovascular treatment of internal carotid artery bifurcation aneurysms.** *Neuroradiology* 2018;60:535–44 CrossRef Medline
28. Cagnazzo F, Limbucci N, Nappini S, et al. **Y-stent-assisted coiling of wide-neck bifurcation intracranial aneurysms: a meta-analysis.** *AJNR Am J Neuroradiol* 2019;40:122–28 CrossRef Medline
29. Pierot L, Moret J, Barreau X, et al. **Aneurysm treatment with Woven EndoBridge in the cumulative population of three prospective, multicenter series: 2-year follow-up.** *Neurosurgery* 2020;87:E78–79 CrossRef Medline
30. Cagnazzo F, Ahmed R, Lefevre PH, et al. **Flow modification on the internal carotid artery bifurcation region and A1 segment after M1-internal carotid artery flow diverter deployment.** *J Neurointerv Surg* 2020;12:1226–30 CrossRef Medline