Since January 2020 Elsevier has created a COVID-19 resource centre with free information in English and Mandarin on the novel coronavirus COVID-19. The COVID-19 resource centre is hosted on Elsevier Connect, the company's public news and information website.

Elsevier hereby grants permission to make all its COVID-19-related research that is available on the COVID-19 resource centre - including this research content - immediately available in PubMed Central and other publicly funded repositories, such as the WHO COVID database with rights for unrestricted research re-use and analyses in any form or by any means with acknowledgement of the original source. These permissions are granted for free by Elsevier for as long as the COVID-19 resource centre remains active.

Journal of Pediatric Surgery Case Reports 71 (2021) 101913

Contents lists available at ScienceDirect

Journal of Pediatric Surgery Case Reports

journal homepage: www.elsevier.com/locate/epsc

COVID-19-associated multisystem inflammatory syndrome in children (MIS-C) presenting as appendicitis with shock

Jamie E. Anderson [a,*], Julie A. Campbell [b], Lindsey Durowoju [c], Sarah L.M. Greenberg [a], Samuel E. Rice-Townsend [a], Kenneth W. Gow [a], Jeffrey Avansino [a]

[a] Division of General and Thoracic Pediatric Surgery, USA
[b] Division of Rheumatology, USA
[c] Division of Laboratory Medicine and Pathology, Seattle Children's Hospital, PO Box 5371, Seattle, WA, 98145-5005, USA

ARTICLE INFO

Keywords:
COVID-19
Coronavirus
Multisystem inflammatory syndrome in children (MIS-C)
Appendicitis
SARS-CoV-2
Acute abdomen

ABSTRACT

Multisystem inflammatory syndrome in children (MIS-C) is an identified complication of the COVID-19 infection. A common presentation of both COVID-19 and MIS-C is acute abdominal pain, sometimes mimicking appendicitis. We report two cases of patients initially diagnosed with appendicitis who either presented with or developed signs of shock and were found to have MIS-C. An 8-year-old girl who tested positive for severe acute respiratory syndrome coronavirus 2 (SARS-CoV-2) reverse transcriptase-polymerase chain reaction (RT-PCR) presented with fever, abdominal pain, and shock with ultrasound findings consistent with acute appendicitis. After being treated for MIS-C, she underwent appendectomy and improved. Final pathology was consistent with acute appendicitis. A 9-year-old girl who tested negative for COVID RT-PCR presented with uncomplicated appendicitis and underwent laparoscopic appendectomy, but developed post-operative fever and shock. Antibody testing was positive and she responded to treatment for MIS-C. Histology showed lymphohistiocytic inflammation within the muscularis propria, mesoappendix and serosa without the typical neutrophil-rich inflammation and mucosal involvement of acute appendicitis. The diagnosis was MIS-C, not appendicitis. Given the new reality of the COVID-19 pandemic, pediatric surgeons must be aware of MIS-C as a possible diagnosis and should understand the diagnostic criteria and current treatment guidelines.

Multisystem inflammatory syndrome in children (MIS-C) is a recently described complication of the COVID-19 infection [1,2]. A common presentation of both COVID-19 and MIS-C is acute abdominal pain, sometimes mimicking appendicitis. We report two cases of patients initially diagnosed with appendicitis who either presented with or developed signs of shock and were found to have MIS-C. Given the reality of the COVID-19 pandemic, pediatric surgeons must be aware of MIS-C as a possible etiology in children presenting with abdominal pain and should understand the diagnostic criteria and current treatment guidelines.

1. Case report

1.1. Case 1

An 8-year-old Hispanic girl presented to the emergency department (ED) with three days of diffuse abdominal pain and multiple episodes of vomiting associated with fever, sore throat, decreased urine output, myalgias, difficulty walking, and constipation. Her past medical history was significant for a dysplastic kidney identified at birth without renal dysfunction. She had no known exposures to COVID-19, but given her symptoms could be consistent with COVID, she was tested and was found to be positive for severe acute respiratory syndrome coronavirus 2 (SARS-CoV-2) reverse transcriptase-polymerase chain reaction (RT-PCR). She was febrile to 38.9° Celsius, tachycardic (heart rate 157 beats per minute) and hypotensive (90/37). Her abdomen was distended with

* Corresponding author.
E-mail addresses: Jamie.anderson@seattlechildrens.org (J.E. Anderson), Julie.a.campbell@seattlechildrens.org (J.A. Campbell), durowoju@uw.edu (L. Durowoju), Sarah.greenberg@seattlechildrens.org (S.L.M. Greenberg), Samuel.rice-townsend@seattlechildrens.org (S.E. Rice-Townsend), Kenneth.gow@seattlechildrens.org (K.W. Gow), Jeffrey.avansino@seattlechildrens.org (J. Avansino).

https://doi.org/10.1016/j.epsc.2021.101913
Received 29 April 2021; Received in revised form 11 May 2021; Accepted 13 May 2021
Available online 19 May 2021
2213-5766/© 2021 The Authors. Published by Elsevier Inc. This is an open access article under the CC BY-NC-ND license (http://creativecommons.org/licenses/by-nc-nd/4.0/).

diffuse mild tenderness and guarding, worse in the right lower quadrant. She was noted to have dry oral mucosal membranes, no other Kawasaki Disease stigmata, and no evidence of arthritis or muscular tenderness. She was given a total of 80 mL/kg of crystalloid fluid boluses with ongoing hypotension and was started on an epinephrine infusion.

Initial laboratory values were remarkable for a leukocytosis to 15.4 K/mm3 with a left shift (79.0% polymorphonuclear count), an elevated C-reactive protein (17.0 mg/dL) and an elevated erythrocyte sedimentation rate (27 mm/hr) (Table 1). She had evidence of coagulopathy (prothrombin time prolonged at 18.5 seconds, elevated D-dimer at 3.1 mcg/mL, and elevated fibrinogen at 507 mg/dL). COVID-19 IgG antibody was also positive. She did not have evidence of lymphopenia or thrombocytopenia (211,000/mm3), and her basic metabolic panel and liver function tests were normal.

Ultrasound of the appendix showed a dilated and non-compressible tip that measured 12.3 mm in diameter associated with hyperemia and fat stranding, but without a fecalith, fluid collection, or mesenteric lymphadenopathy. Minimal simple fluid was identified in the pelvis. The diameter of the appendix at the origin (3.1 mm) and midportion (5.1 mm) were normal. With the presumed diagnosis of appendicitis, she was started on ceftriaxone and metronidazole. Due to ongoing hypotension unresponsive to fluid and requiring epinephrine, she was admitted to the pediatric intensive care unit for further work-up and resuscitation prior to surgical intervention. She remained febrile with temperature up to 39.5° Celsius during the first 12 hours of admission.

On hospital day one, her hypotension improved and epinephrine was stopped, but she remained febrile and tachycardic. Computed tomography (CT) of the abdomen/pelvis with IV contrast was performed to confirm the diagnosis; results were consistent with perforated appendicitis with multiple small rim-enhancing fluid collections in the periappendiceal region and an appendicolith in the right lower quadrant (unclear if endoluminal). There were numerous abnormally enlarged mesenteric lymph nodes. B-natriuretic peptide was elevated at 528 pg/mL. She also developed lymphopenia (495/mm^3) and thrombocytopenia (172,000/mm^3), which were concerning for MIS-C.

Her fever defervesced on hospital day two and her sinus tachycardia improved to 110–140 beats per minute. As part of the workup for MIS-C, echocardiogram (which is typically done urgently for patients who are hypotensive and within 24–48 hours for patients who are not) showed a prominent left anterior descending coronary artery, but normal in size without aneurysms, normal left ventricular size and function and trivial mitral valve insufficiency. Due to concern for MIS-C, she was given intravenous immunoglobulin (IVIG) 2 g/kg.

With ongoing clinical improvement and blood pressure stability off epinephrine, she was determined stable for general anesthesia and underwent laparoscopic appendectomy on hospital day three. Appendectomy was also favored at this point rather than continuation of non-operative management because of the presence of a fecalith. Perforated appendicitis was identified with a small abscess cavity adjacent to the appendix in the pelvis and turbid fluid in the pelvis. Anakinra (an interleukin-1 antagonist, dosed for this patient at 3.4 mg/kg every 8 hours) and enoxaparin (0.5 mg/kg twice daily) were started 12 hours after surgery and aspirin (81 mg) was started on postoperative day two. Anakinra was chosen over glucocorticoid therapy given the concern for infection; the dose was tapered to 100 mg twice daily on post-operative day two and then once daily from post-operative day three to four.

Repeat echocardiogram on post-operative day three demonstrated borderline dilation of the right coronary artery (*z*-score 2.1) without dilation of the left main coronary artery or the left anterior descending artery. No aneurysms were identified. There was normal left and right ventricular size and systolic function.

Pathology was consistent with perforated acute appendicitis. Histologic sections with hematoxylin and eosin (H&E) stain showed a markedly inflamed appendix with mucosal ulceration and transmural neutrophilic inflammation extending through the muscularis propria to the serosal surface (Fig. 1A and B). Immunohistochemistry performed for viral spike protein with a rabbit anti-SARS- CoV-2 antibody immunostain from Sino Biological (Cat#40150-R007) was negative (Fig. 1C and D).

She was clinically ready for discharge on post-operative day five. She was transitioned to oral amoxicillin-clavulanate and discharged home with two days to complete a seven-day post-operative course of antibiotics. Aspirin 81 mg was prescribed at discharge and enoxaparin and anakinra were discontinued. She was scheduled for follow-up with cardiology including a repeat echocardiogram but was lost to follow-up.

Her final diagnosis was acute appendicitis and MIS-C.

1.2. Case 2

A 9-year-old previously healthy African American girl was seen at another emergency department with four days of abdominal pain, vomiting, fever associated with anorexia, neck pain, and intermittent

Table 1
Laboratory values on day of admission and peak during hospitalization.

Lab value (normal range)	Case 1		Case 2	
	On admission	Peak (or trough) during hospitalization (day of hospitalization)	On admission (or day of hospitalization during first time it was tested if not on admission)	Peak (or trough) during hospitalization (day of hospitalization)
White blood cell count (4.5–13.5 K/mm3)	15.4 K/mm3	15.4 K/mm3 (day 0)	8.8 K/mm3	11.2 K/mm3 (day 5)
Polymorphonuclear count % (25–70%)	79.0%	79.0% (day 0)	85.0%	84.5% (day 5)
Lymphocyte count % (20–50%)	10.0%	10.0% (day 0)	10.8%	6.0% (day 2)
Bands count % (0–9%)	7.0%	12.0% (day 3)	2.4%	24% (day 2)
C-reactive protein (≤0.8 mg/dL)	17.0 mg/dL	23.6 mg/dL (day 2)	22.7 mg/dL	33.6 mg/dL (day 4)
Erythrocyte sedimentation rate (0–10 mm/hr)	27 mm/hr	38 mm/hr (day 2)	12 mm/hr (day 2)	12 mm/hr (day 2)
Fibrinogen (230–450 mg/dL)	507 mg/dL	603 mg/dL (day 2)	318 mg/dL (day 2)	427 mg/dL (day 4)
Procalcitonin (0.00–0.49 ng/mL)	Not checked	Not checked	15.37 ng/mL (2)	25.34 ng/mL (day 4)
D-dimer (≤0.5 mcg/mL)	3.1 mcg/mL	10.7 mcg/mL (day 2)	7.9 mcg/mL (day 3)	7.9 mcg/mL (day 3)
Ferritin (10–82 ng/mL)	62 ng/mL	Only checked at admission	1,750 ng/mL (day 2)	1,750 ng/mL (day 2)
Lactate dehydrogenase (370–840 IU/L)	683 IU/L	683 IU/L (day 0)	677 IU/L	711 IU/L (day 6)
B-type natriuretic peptide (0–41 pg/mL)	12 pg/mL	528 pg/mL (day 1)	215 pg/mL (day 3)	1,950 pg/mL (day 5)

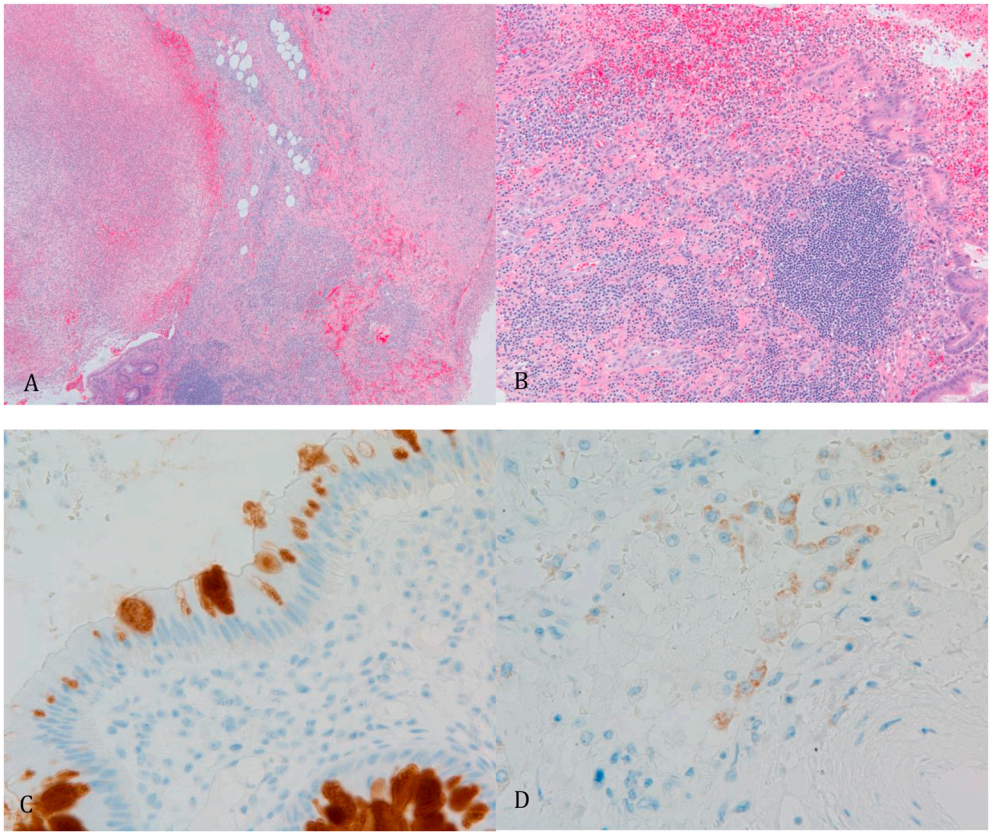

Fig. 1. Pathology findings of perforated acute appendicitis.
A: Transmural neutrophilic inflammation with H&E stain (4x), B: Mucosal ulceration with H&E stain (10x), C: Negative anti-SARS- CoV-2 antibody immunostain shows non-specific staining of goblet cells and mucin (20x), D: Positive control on lung tissue with anti-SARS- CoV-2 antibody immunostain (20x).

headaches. On initial work-up, she did not have a leukocytosis (WBC 8.8 K/mm3), but she did have a left shift (polymorphonuclear count 85.0%) and was lymphopenic (950/mm^3) and thrombocytopenic (146,000/mm^3) (Table 1). Total bilirubin (2.90 mg/dL [normal <2.0 mg/dL]), aspartate aminotransferase (121 U/L [normal 10–45 U/L]), and alanine aminotransferase (95 U/L [normal 10–65 U/L]) were also elevated. C-reactive protein was elevated to 22.7 mg/dL. Right lower quadrant ultrasound identified a dilated, non-compressible appendix to 9mm with free fluid in the pelvis. COVID RT-PCR test was negative. She was started on ceftriaxone and metronidazole and transferred to a tertiary hospital.

On arrival, she was febrile (38.0° Celsius), tachycardic (heart rate 126 beats per minute), with diastolic hypotension (blood pressure 104/53). Her abdomen was distended with diffuse mild tenderness and guarding, but worse in the right lower quadrant. The remainder of her exam was unremarkable. A repeat RT-PCR test was also negative. She underwent a laparoscopic appendectomy. The appendix was inflamed but not ruptured, although there was a moderate amount of serous ascites. She tolerated the procedure well and her initial post-operative course was unremarkable.

On post-operative day two (approximately 36 hours post-operatively), her abdomen became more distended, she had marginal urine output, she was febrile (39.4° Celsius), tachycardic (146 beats per minute) and hypotensive (blood pressure 85/42). She received 60 mL/kg of crystalloid resuscitation with no significant improvement in her hypotension and was started on norepinephrine. Ceftriaxone and metronidazole were restarted (later transitioned to piperacillin-tazobactam). She required oxygen via nasal cannula (2L 21%) for desaturations and tachypnea with respiratory rate in the 40s–50s. She was transferred to the pediatric intensive care unit.

Blood and urine cultures and SARS-CoV-2 IgG antibody test were sent. Repeat RT-PCR qualitative test was negative. Complete blood count showed a leukopenia with WBC 3.0 K/mm3 (lymphocytes low at 6%, bands elevated at 24%). Lactic acid (2.7 mmol/L [normal 0.5–2.2 mmol/L]), C-reactive protein (15.5 mg/dL [normal ≤ 0.8 mg/dL]), procalcitonin (15.37 ng/mL [normal 0.00–0.49 ng/mL]), and ferritin (1,750 ng/mL [normal 10–82 ng/mL]) were elevated. Repeat liver function tests were normal. Radiographs of the chest and abdomen were grossly normal. CT of the chest, abdomen, and pelvis with IV contrast did not show pulmonary emboli, ground glass opacities, or abdominal abscesses, but demonstrated moderate ascites with slight peritoneal lining enhancement, as well as cecal, ascending colon, and terminal ileal wall thickening. She was transitioned from norepinephrine to epinephrine for ongoing hypotension.

On post-operative day three, the SARS-CoV-2 IgG antibody test resulted positive. On further inquiry, her mother had tested positive for COVID-19 four months prior. Repeat chest x-ray showed cardiomegaly. Echocardiogram showed mildly diminished left ventricular systolic function (ejection fraction 48%) with mildly diminished right ventricular systolic function while on epinephrine infusion. She was noted to have bilateral limbic-sparing conjunctivitis, tenderness on her lateral neck bilaterally, thigh tenderness, and mild arthritis in multiple joints. She had no other Kawasaki stigmata.

Due to concern for MIS-C, she was started on IVIG 2 g/kg and intravenous methylprednisolone 30 mg every 12 hours with a subsequent taper. On post-operative day four, blood pressure improved, and vasopressors were discontinued. Enoxaparin 0.5 mg/kg twice daily and aspirin 81 mg were started.

Histopathologic examination of her appendix with H&E stain showed an expanded lamina propria with prominent Peyer's patches with lymphohistiocytic inflammation within the muscularis propria, mesoappendix and serosa (Fig. 2A,B,C). An equivocal focus of perivascular or vascular fibrin deposition with intermixed lymphohistiocytic

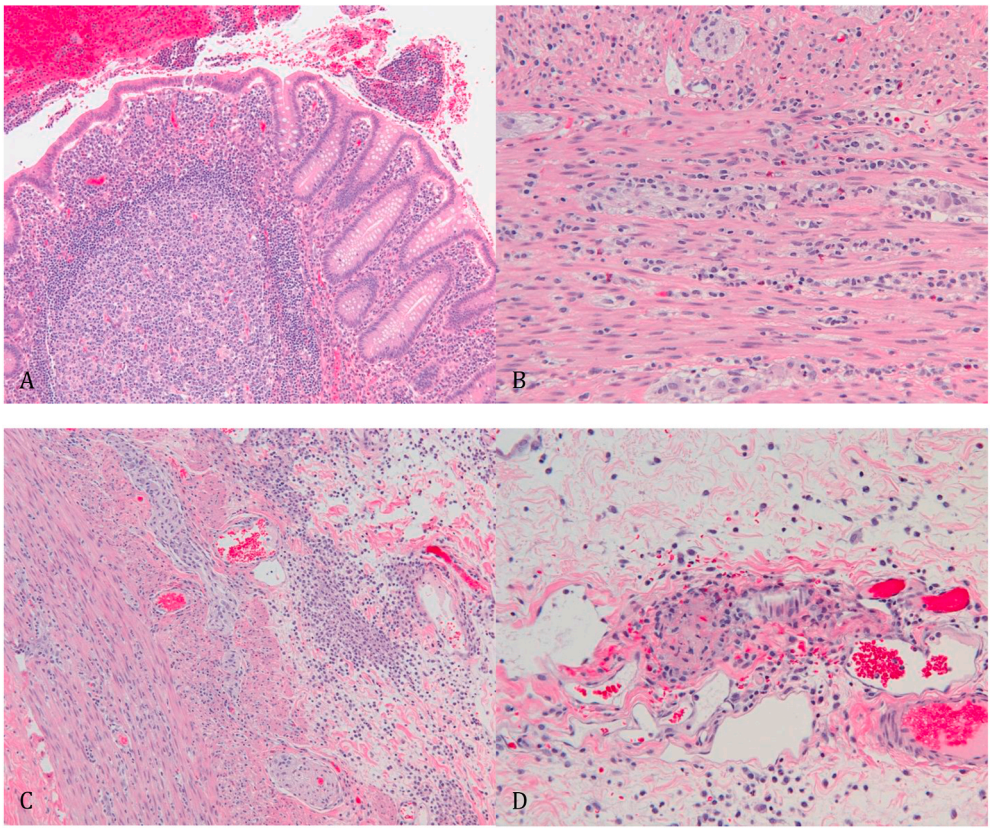

Fig. 2. Hematoxylin and eosin stained appendix.
A: Intact mucosa and prominent Peyer's patches without neutrophilic inflammation (10x), B: Muscularis propria with lymphohistiocytic inflammation (20x), C: Mesoappendix with histiocytic aggregates (10x), D: Possible perivascular or vascular fibrin deposition with intermixed lymphohistiocytic inflammation (20x).

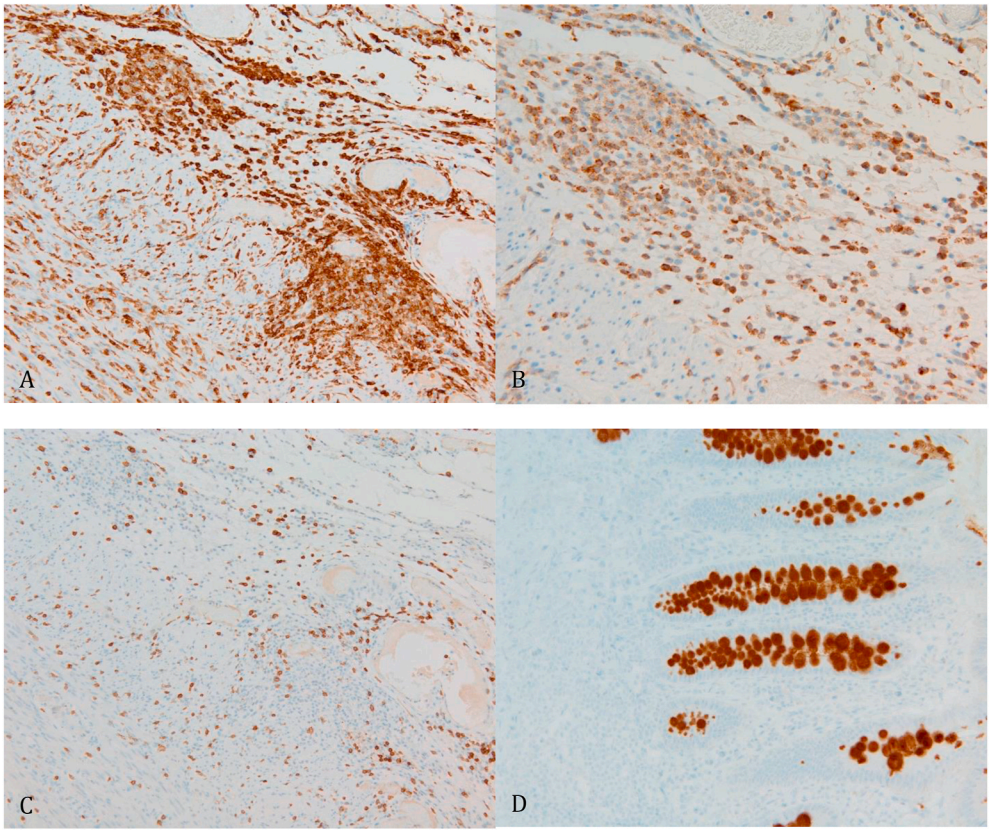

Fig. 3. Immunohistochemical studies.
A: CD163 stain highlights increased histiocytes within the mesoappendix (10x), B: Myeloperoxidase stain demonstrates prominent granular cytoplasmic staining of histiocytes (10x), C: CD3 stain shows T lymphocytes within the muscularis propria and mesoappendix (10x), D: Negative anti-SARS- CoV2 with non-specific staining of goblet cells and mucin (20x).

inflammation was identified within the mesoappendix (Fig. 2D). The typical neutrophil-rich inflammation and mucosal involvement of acute appendicitis were not identified. Immunohistochemistry was performed to further characterize the lymphohistiocytic inflammation. CD163 positive histiocytes were present in aggregates within the mesoappendix and muscularis propria (Fig. 3A) and noted to have prominent cytoplasmic myeloperoxidase (MPO) granules (Fig. 3B). The lymphocytes within the muscularis propria and mesoappendix demonstrated CD3 positivity, confirming T-cell lineage (Fig. 3C). Immunohistochemistry performed to determine the presence of the virus was negative for viral spike protein with a rabbit anti-SARS- CoV-2 antibody immunostain from Sino Biological (Cat#40150-R007) (Fig. 3D).

Antibiotics were stopped after pathology results were finalized. Peritoneal cultures and blood cultures drawn throughout her hospitalization were all negative. Repeat echocardiogram on post-operative day five showed a normal left and right ventricular size and systolic function with trivial mitral valve insufficiency and mild tricuspid valve insufficiency, without evidence of aneurysm. By post-operative day 8, after her inflammatory markers improved and she was tolerating a diet, she was discharged home with aspirin and oral prednisone; enoxaparin was discontinued at discharge.

Her final diagnosis was MIS-C, not appendicitis.

2. Discussion

2.1. Multisystem inflammatory syndrome in children

First identified in April 2020, multisystem inflammatory syndrome in children (MIS-C) is now a well-documented complication from COVID-19 and is thought to be related to post-infection immune dysregulation and inflammation [3,4]. MIS-C is defined in an person less than age 21 with clinical criteria (24-h subjective fever or objective fever $\geq 38.0^{\circ}$ Celsius; AND severe illness necessitating hospitalization; AND two or more organ systems affected), laboratory evidence of inflammation (one or more of the following: elevated CRP, ESR, fibrinogen, procalcitonin, D-dimer, ferritin, LDH, or IL-6; elevated neutrophils or reduced lymphocytes; low albumin), laboratory or epidemiologic evidence of SARS-CoV-2 infection (positive SARS-CoV-2 testing by RT-PCR, serology, or antigen; OR COVID-19 exposure within 4 weeks prior to symptom onset), and no alternative diagnosis [1].

In patients with MIS-C, the majority report gastrointestinal signs and symptoms, many of which overlap with signs and symptoms of acute appendicitis [5,6]. The Centers for Disease Control and Prevention (CDC) recently published a national cross-sectional analysis on 1,733 patients under age 21 with MIS-C from March 2020 to January 2021 [3]. Abdominal pain (66.5%), vomiting (64.3%), and diarrhea (53.7%) were the most common gastrointestinal symptoms. Compared to patients with severe acute COVID-19, patients with MIS-C also seem to present with higher rates of gastrointestinal symptoms [57.5% vs. 90.2%] [7]. In contrast to appendicitis, patients with MIS-C often report mucocutaneous symptoms that overlap with Kawasaki Disease (KD), an inflammatory disease of childhood of unknown etiology. Rash and conjunctival hyperemia were common (55.6% and 53.6% of patients, respectively) [3]. Symptoms varied slightly by age; patients age 5–14 more commonly presented with abdominal pain and vomiting, whereas rash was most common among patients under age 5 (68.1%), and teenagers (age 15–20) had higher rates of cough, shortness of breath, chest pain or tightness. Other typical features of KD (cervical lymphadenopathy, oral mucosal changes, and hand and feet edema) were not reported in this study but have been reported elsewhere [6]. The median duration of fever was 5 days (interquartile range 4–7 days).

Less than half of patient had cardiac dysfunction (31.0%), myocarditis (17.3%), coronary artery dilatation or aneurysm (16.5%), or pericardial effusion (23.4%) [3]. Half (50.8%) of patients had hypotension, one-third of patients had shock (36.8%), and over half (58.2%) of patients required an ICU admission. Older children had a higher rate of requiring ICU admission, with 66.1% of children aged 10–20 requiring ICU stay compared to 52.9% of children aged 0–9. The overall mortality rate was 1.4%. Only 24.7% had a preceding COVID-19-like illness, 51.4% tested positive for COVID-19 by PCR, and 82.6% received COVID IgG serology and tested positive.

Incidence of MIS-C also varied by demographics. It was more commonly identified in patients who were Hispanic (37.4%) or non-Hispanic Black (33.9%) compared to white (20.2%) and Asian (1.3%) patients [3]. MIS-C was less common among children age 15–17 (1.5 cases per 100,000 children) and age 18–20 (0.4 cases per 100,000 children) compared to children age 14 and younger (2.1–2.9 cases per 100,000 children).

2.2. COVID-19 and appendicitis

There are several documented cases of appendicitis in patients co-infected with COVID-19 [8] and patients with COVID-19 who were misdiagnosed with appendicitis. Given that acute appendicitis is one of the most common indications for emergent operations among children [9], it is expected that some children will have concomitant appendicitis and COVID-19. However, concomitant appendicitis and MIS-C (or cases of MIS-C misdiagnosed as appendicitis) may pose a greater clinical challenge, as these patients can demonstrate severe illness, even shock, often unexpectedly and out of proportion to their findings of appendicitis (i.e. appendicitis without perforation or with a small perforation). Appendicitis is most common among children age 10–14 years [9], the age group with similarly high rates of abdominal pain in MIS-C [3].

There are several published cases of MIS-C misdiagnosed as appendicitis [10–13] and several cases of concomitant MIS-C associated with acute appendicitis [14]. In a case series in South Africa, three children initially diagnosed with appendicitis who underwent appendectomies (with confirmatory pathology) were then treated for MIS-C after they developed shock requiring inotropic support. SARS-CoV-2 RT-PCR were positive in all three patients [14]. In New York, a nine-year-old girl was admitted for acute appendicitis but underwent small bowel resection of her distal ileum for inflammation [13]. Post-operatively, she became acutely ill requiring intensive care and was diagnosed with MIS-C. Post-operative CT of her abdomen also showed mild thickening of the cecum and right colon, similar to our patient in case 2. Histologic examination of the resection specimen demonstrated transmural chronic inflammation, extensive venous microthrombi, and markedly inflamed mesentery, similar histologic findings described for the patient in case 2.

The two cases we report provide additional insight into situations in which concomitant infections with appendicitis and COVID-19 may result in MIS-C, or possibly (as may have been the situation in case 2) situations in which MIS-C may be misdiagnosed as acute appendicitis. Both patients had clear radiologic evidence and clinical histories consistent with acute appendicitis. It is possible that the patient in case 1 had acute appendicitis, which may have triggered MIS-C in a clinically predisposed patient, whereas the patient in case 2 had significant lymphohistiocytic inflammation within the muscularis propria without histopathologic evidence of acute appendicitis, suggestive of MIS-C as the primary diagnosis. While the pathogenesis is not entirely known, histologic similarities among the few published cases suggests a possible recognizable histopathologic entity. Additionally, the lack of viral spike protein with a rabbit anti-SARS- CoV-2 antibody immunostain in case 2 supports an indirect systemic inflammatory process, rather than direct viral induced cellular damage.

2.3. Treatment of MIS-C

Treatment for MIS-C is evolving. The American College of Rheumatology recommends high dose IVIG as first line treatment with the addition of glucocorticoids as adjunctive therapy in patients with severe features or refractory disease [15]. Glucocorticoid therapy is then

continued for approximately 3 weeks due to risk of rebound inflammation. Anakinra, a recombinant interleukin-1 antagonist often used to treat macrophage activation syndrome in pediatric and adult patients, is another treatment option in MIS-C refractory to IVIG and glucocorticoids, in disease with features of macrophage activation syndrome or in patients who have contraindications to glucocorticoids, such as infection [15]. Macrophage activation syndrome is a hyperinflammatory state and a form of secondary hemophagocytic lymphohistiocytosis. It is hypothesized to be caused by excess activation and proliferation of macrophages and T lymphocytes, leading to high fevers, lymphadenopathy, hepatosplenomegaly and organ dysfunction, and elevated inflammatory markers, most notably hyperferritinemia [16]. Evidence for the best treatment for MIS-C is still evolving. A recent report suggests that patients who receive IVIG and glucocorticoids have a lower risk of treatment failure (measured by continued fevers, continued need for hemodynamic support, acute left ventricular dysfunction, duration of stay in the pediatric intensive care unit, and need for second-line therapy) [17]. Outcomes across larger populations of patients who have received anakinra have not yet been reported.

In addition to treatment for hyperinflammation for MIS-C, anticoagulation is a routine part of management given the risk of thrombosis. Low dose aspirin is recommended in all patients unless there is active bleeding, high bleeding risk or platelet count less than 80,000/μL. The use of enoxaparin is highly recommended in patients with coronary artery aneurysms with a *z*-score greater than or equal to ten, patients with a documented thrombosis, and patients with an ejection fraction less than 35%. In patients who do not meet these criteria, anticoagulation decisions should be based on the patient's individual risk factors [15].

After discharge, cardiac follow up is recommended. Echocardiograms are recommended at a minimum of 7–14 days and 4–6 weeks after diagnosis. More frequent echocardiograms may be indicated if more cardiac abnormalities are noted. Additionally, a cardiac MRI may be indicated if left ventricular dysfunction is noted during the acute illness. A cardiac CT can be performed to better characterize possible coronary artery aneurysms. There are not guidelines for routine follow-up timing with cardiology or other specialties; follow-up recommendations are currently institution-dependent [15].

Our institution is closely monitoring for changing guidelines and has developed a clinical standard work pathway developed by a multispecialty team that serves as a guideline for management of MIS-C in our patients [18]. Patients identified with MIS-C should also be reported to the Centers for Disease Control for ongoing national coordinated research efforts to better understand this complication of COVID-19 [1].

3. Conclusion

Surgeons should have a high index of suspicion for MIS-C in patients with acute appendicitis who become critically ill out of proportion to their surgical findings, especially in cases of high and prolonged fever and hypotension unresponsive to fluid. An understanding of current treatment guidelines and a multidisciplinary approach is critical to acute management and prevention of long-term sequelae.

Patient consent

Consent to publish the case report was not obtained. The report does not contain any personal information that could lead to the identification of the patient.

Funding

No funding or grant support.

Authorship

All authors attest that they meet the current ICMJE criteria for authorship.

Declaration of competing interest

The authors declare that they have no known competing financial interests or personal relationships that could have appeared to influence the work reported in this paper.

References

[1] Centers for Disease Control and Prevention. Multisystem Inflammatory Syndrome (MIS-C): Healthcare Professionals. Accessed April 3, 2021. https://www.cdc.gov/mis-c/hcp/.
[2] World Health Organization. Scientific Brief: multisystem inflammatory syndrome in children and adolescents temporally related to COVID-19. May 15, https://www.who.int/news-room/commentaries/detail/multisystem-inflammatory-syndrome-in-children-and-adolescents-with-covid-19; 2020.
[3] Belay ED, Abrams J, Oster ME, Giovanni J, Pierce T, Meng L, et al. Trends in geographic and temporary distribution of U.S. children with multisystem inflammatory syndrome during the COVID-19 pandemic. JAMA Ped 2021. https://doi.org/10.1001/jamapediatrics.2021.0630. Published online April 6.
[4] Nakra NA, Blumberg DA, Herrera-Guerra A, Lakshminrushimha S. Multi-system inflammatory syndrome in children (MIS-C) following SARS-CoV-2 infection: review of clinical presentation, hypothetical pathogenesis, and proposed management. Children 2020;7(7):69. https://doi.org/10.3390/children7070069.
[5] Dufort EM, Koumans EH, Chow EJ, Rosenthal EM, Muse A, Rowlands J, et al. Multisystem inflammatory syndrome in children in New York State. N Engl J Med 2020;383(4):347–58.
[6] Feldstein LR, Rose EB, Horwitz SM, Collins JP, Newhams MM, Son MBG, et al. Multisystem inflammatory syndrome in U.S. children and adolescents. N Engl J Med 2020;383(4):334–46. https://doi.org/10.1056/NEJMoa2021680.
[7] Feldstein LR, Tenforde MW, Friedman KG, Newhams M, Rose EB, Dapul H, et al. Characteristics and outcomes of US children and adolescents with multisystem inflammatory syndrome in children (MIS-C) compared with severe acute COVID-19. J Am Med Assoc 2021;325(11):1074–87. https://doi.org/10.1001/jama.2021.2091.
[8] Meyer JS, Robinson G, Moonah S, Levin D, McGahren E, Herring K, et al. Acute appendicitis in four children with SARS-CoV-2 infection. J Peds Surg Case Rep 2021;64:101734. https://doi.org/10.1016/j.epsc.2020.101734.
[9] Anderson JE, Bickler SW, Chang DC, Talamini MA. Examining a common disease with unknown etiology: trends in epidemiology and surgical management of appendicitis in California, 1995-2009. World J Surg 2012;36(12):2787–94. https://doi.org/10.1007/s00268-012-1749-z.
[10] Tullie L, Ford K, Bisharat M, Watson T, Thakkar H, Mullassery D, et al. Gastrointestinal features in children with COVID-19: an observation of varied presentation in eight children. Lancet Child Adolesc Health 2020;4(7):E19–20. https://doi.org/10.1016/S2352-4642(20)30165-6.
[11] Shahbaznejad L, Navaeifar MR, Abbaskhanian Al, Hosseinzadeh F, Rahimzadeh G, Reazai MS. Clinical characteristics of 10 children with a pediatric inflammatory multisystem syndrome associated with COVID-19 in Iran. BMC Pediatr 2020;20:513. https://doi.org/10.1186/s12887-020-02415-z.
[12] Webb K, Abraham DR, Faleye A, McCulloch M, Rabie H, Scott C. On behalf of the Cape Town MISC-Team. Multisystem inflammatory syndrome in children in South Africa. Lancet Child Adolesc Health 2020;4(1):E38. https://doi.org/10.1016/S2352-4642(20)30272-8.
[13] Jackson RJ, Chavarria HD, Hacking SM. A case of multisystem inflammatory syndrome in children mimicking acute appendicitis in a COVID-19 pandemic area. Cureus 2020;12(9):e10722. https://doi.org/10.7759/cureus.10722.
[14] Lishman J, Kohler C, de Vos C, van der Zalm MM, Itana J, Rederm A, et al. Acute appendicitis in multisystem inflammatory syndrome in children with COVID-19. Pediatr Infect Dis J 2020;39(12):e472–3. https://doi.org/10.1097/inf.0000000000002900.
[15] Henderson LA, Canna SW, Friedman KG, Gorelik M, Lapidus SK, Bassiri H, et al. American College of Rheumatology clinical guidance for multisystem inflammatory syndrome in children associated with SARS-CoV-2 and hyperinflammation in pediatric COVID-19: version 2. Arthritis Rheum 2021 Apr;73(4):e13–29. https://doi.org/10.1002/art.41616. Epub 2021 Feb 15. PMID: 33277976.
[16] Ravelli A, Davì S, Minoia F, Martini A, Cron RQ. Macrophage activation syndrome. Hematol Oncol Clin N Am 2015 Oct;29(5):927–41. https://doi.org/10.1016/j.hoc.2015.06.010. Epub 2015 Aug 25. PMID: 26461152.
[17] Ouldali N, Toubiana J, Antona D, et al. Association of intravenous immunoglobulins plus methylprednisolone vs immunoglobulins alone with course of fever in multisystem inflammatory syndrome in children. J Am Med Assoc 2021;325(9):855–64. https://doi.org/10.1001/jama.2021.0694.
[18] Seattle Children's Hospital, Kazmier K, Albert J, de la Morena M, Eckart C, Fenstermacher S, et al. COVID-19 pathway. Available at: https://child.seattlechildrens.org/Documents/CSW/COVID-19_Pathway.pdf; 2020 December.