Since January 2020 Elsevier has created a COVID-19 resource centre with free information in English and Mandarin on the novel coronavirus COVID-19. The COVID-19 resource centre is hosted on Elsevier Connect, the company's public news and information website.

Elsevier hereby grants permission to make all its COVID-19-related research that is available on the COVID-19 resource centre - including this research content - immediately available in PubMed Central and other publicly funded repositories, such as the WHO COVID database with rights for unrestricted research re-use and analyses in any form or by any means with acknowledgement of the original source. These permissions are granted for free by Elsevier for as long as the COVID-19 resource centre remains active.

Clinical Imaging 79 (2021) 104–109

Contents lists available at ScienceDirect

Clinical Imaging

journal homepage: www.elsevier.com/locate/clinimag

Body Imaging

Does COVID-19 cause an increase in spleen dimensions? Possible effects of immune activation, hematopoietic suppression and microthrombosis

Mehmet Tahtabasi [a,*], Tugrul Hosbul [b], Ergin Karaman [a], Yasin Akin [a], Osman Konukoglu [a], Fatih Sahiner [b]

[a] Department of Radiology, University of Health Sciences- Mehmet Akif Inan Education and Research Hospital, Sanliurfa, Turkey
[b] Department of Medical Microbiology, Gulhane Medical Faculty, University of Health Sciences, Ankara, Turkey

ARTICLE INFO

Keywords:
COVID-19
Spleen
Splenomegaly
Severity score
Follow-up computed tomography

ABSTRACT

Purpose: To radiologically examine how the spleen size, which has important functions in hematological and immunological balance, is affected in COVID-19.

Methods: Between July 1 and August 31, 2020, consecutive patients diagnosed with COVID-19 were analyzed. Among these patients, those who underwent chest computed tomography (CT) examination at the time of presentation, patients with follow-up CT due to clinical deterioration were included in the study. The CTs of the patients were evaluated in terms of spleen size and volume.

Results: A total of 160 patients (88 females, 55%) were included in the study. The mean time between the initial and follow-up CT was 7.2 ± 2.8 days. The splenic volume (244.3 ± 136.7 vs. 303.5 ± 156.3 cm^3) and splenic index (421.2 ± 235.5 vs. 523.2 ± 269.4 cm^3) values were significantly higher in the follow-up CT compared to the initial CT ($p < 0.001$). The increase in the splenic volume and splenic index values was 59.2 ± 52.4 cm^3 and 101.9 ± 90.3 cm^3 ($p < 0.001$), respectively. The COVID-19 severity score was significantly higher in the follow-up CT compared to the initial CT (3.7 ± 4.2 vs. 12.5 ± 5.7, respectively; $p < 0.001$). The spleen width measured separately on the initial and follow-up CTs showed a highest positive correlation ($r = 0.982$, $p < 0.001$).

Conclusion: Our study indicates that spleen size increases slightly-moderately in the first stages of the infection, and this increase is correlated with the COVID-19 severity score calculated on the chest CT data, and in this respect, it is similar to infections presenting with cytokine storm.

1. Introduction

Severe acute respiratory syndrome-related coronavirus-2 (SARS-CoV2), called 2019-nCoV when first discovered, was first identified in people with symptoms of pneumonia living in Wuhan, China.[1] The SARS-CoV-2 pandemic can be described as the most important globally epidemic of the last century, with the number of confirmed cases approaching 75 million and deaths exceeding 1.6 million in a year.[2] This novel coronavirus causes severe respiratory disease in humans, similar to two other recent zoonotic respiratory coronaviruses: SARS-CoV and Middle East respiratory syndrome-related coronavirus (MERS-CoV).[3,4] In SARS-CoV-2 infections, in addition to local pathological changes associated with cellular damage occurring in viral replication regions, some cases also present with secondary changes associated with the excessive immune response (*cytokine storm*), which has been directly related to mortality and morbidity.[5–7] Hyperinflammation, hemophagocytosis, thrombocytopenia, lymphopenia, and relative-higher monocyte-neutrophil levels are common findings in SARS-CoV-2 infections.[8,9] A third pathological change is microthrombus-related end organ (kidneys, heart, spleen and central nervous system) damage mainly caused by impairment of coagulation mechanisms and immune response.[7,10,11] Coronavirus disease 2019 (COVID-19) infections have been shown to be associated with a coagulopathy characterized by an increase in procoagulant factors, such as fibrinogen and a strong increase in D-dimers associated with higher mortality.[12] Bilateral pneumonia is a characteristic finding of severe COVID-19 disease, but other organ systems, such as the cardiovascular system, kidneys, liver and the central nervous system are affected in at least half of the fatal cases of COVID-19.[7]

The presence of viral proteins (e.g., nucleocapsid protein) has been demonstrated in the spleen, but it is not one of the target organs for direct viral replication due to the absence of entry receptors.[13,14] The

* Corresponding author.
E-mail address: mehmet.tahtabasi@sbu.edu.tr (M. Tahtabasi).

https://doi.org/10.1016/j.clinimag.2021.04.035
Received 1 February 2021; Received in revised form 24 March 2021; Accepted 18 April 2021
Available online 28 April 2021
0899-7071/© 2021 Elsevier Inc. All rights reserved.

spleen, which has functions both in the immune system and in the coagulation system, undergoes functional changes by the suppression or stimulation of lymphoid tissues, and at the same time, as an end organ, it is indirectly affected by general systemic changes, such as microthrombus, in SARS-CoV-2 infections.[13,15] A better understanding of infection pathology is important for regulating therapies (corticosteroids, anticoagulants, IL-1 and IL-6 blockers) that aim to prevent secondary and tertiary pathological changes, and thus reduce mortality and morbidity rates[7,8] and support specific antiviral treatments, including remdesivir, favipiravir, passive immunization, and recombinant monoclonal antibodies.[16] The aim of this study was to radiologically examine how the spleen size, which has important functions in hematological and immunological balance, is affected in SARS-CoV-2 infections.

2. Material and methods

This retrospective study was approved by the Clinical Research Ethics Committee of Harran University (date: 23.11.2020, session: 20). Informed consent was waived given the retrospective nature and characteristics of the study.

2.1. Study population

Between July 1 and August 31, 2020, consecutive patients diagnosed with COVID-19 by reverse transcriptase-polymerase chain reaction (RT-PCR) test were investigated. Among these patients, those who underwent chest computed tomography (CT) examination at the time of presentation, patients with follow-up CT due to clinical deterioration were included in the study. The exclusion criteria were regression of lesions on the follow-up CT, the spleen not completely entering the examination area, history of splenectomy, presence of traumatic or non-traumatic splenic lesions, and CT motion or imaging artifacts. In addition, patients younger than 18 years were excluded from the study since their spleen would not yet been fully developed. As a result, a total of 160 patients were evaluated. A flow chart diagram is shown in Fig. 1.

2.2. Clinical classification

All patients were clinically classified as common, severe, and critical, and the indication for follow-up CT was clinical deterioration and increased severity. The patients were divided into three categories according to their clinical severity: 1) common disease (symptomatic

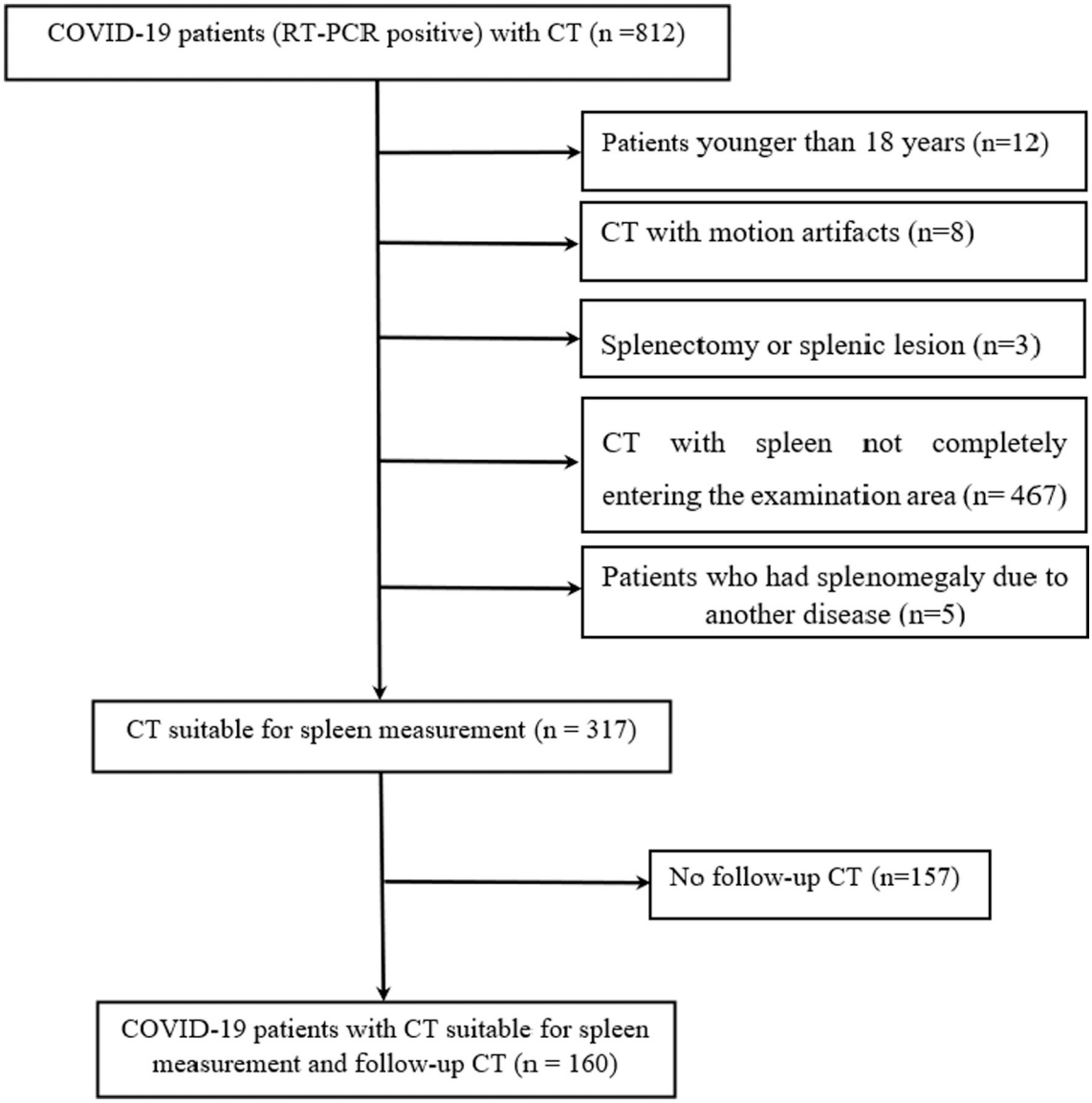

Fig. 1. Flow chart diagram of the study design. CT, Computed tomography; RT-PCR, Reverse transcription-polymerase chain reaction.

patients with pneumonia signs on chest CT, who did not require oxygen support); 2) severe disease [signs of respiratory infection and respiratory distress, and having an increased respiratory rate (≥30 breaths/min), decreased oxygen saturation in room air (SpO2 ≤ 93%), and/or partial pressure of oxygen (PaO2)/fraction of inspired oxygen (FiO2) ≤ 300 mmHg]; and 3) critical disease [respiratory failure requiring mechanical ventilation, septic shock, and other organ failure requiring intensive care unit (ICU) monitoring and treatment].[17]

2.3. CT protocol

Chest CT was performed in all patients with a 16-detector multi-slice CT device (Siemens Healthineers; Erlangen, Germany). The CT room and scanner were sanitized using standard cleaning procedures and approved disinfectants after each procedure. End-inspirium CT images were obtained during a single breath-hold without the use of any intravenous contrast material. The main scanning parameters were as follow: tube voltage, 120 kV; tube current-time product, 50–350 mAs; pitch, 1.25; matrix, 512 × 512; slice thickness, 10 mm; and reconstructed slice thickness, 0.625–1.250 mm.

2.4. CT evaluation

First, the suitability and quality of CT images for spleen measurement were evaluated by a radiologist (M.T.) with eight years of experience in thoracoabdominal imaging. Patients whose CT images were not suitable for the study were excluded. Then, all measurements of the spleen and lung were assessed by two independent radiologists with eight (M.T.) and nine years (E.K.) of experience in thoracoabdominal imaging simultaneously and the mean of two separate measurements of the identical parameter was classified as the final value. All significant discrepancies in measurements between radiologists were analyzed and evaluated one more time in the presence of a third radiologist with ten years (Y.A.) of experience in thoracoabdominal imaging. The observers, unaware of the dates of initial and follow-up CTs, first measured spleen size and then evaluated the COVID-19 pneumonia severity CT score in the lung window settings (with a window center of −500 HU and a window width of 1500 HU).

2.4.1. Evaluation of CT severity score in patients with COVID-19 pneumonia

The COVID-19 severity CT score, a semiquantitative method described in previous studies, was used to measure the severity of lesions on the initial and follow-up CTs.[18,19] First, the scope of the lesions in each lobe was estimated, and a score of 0 (none), 1 (affecting less than 5% of the lobe), 2 (affecting 5–25% of the lobe), 3 (affecting 26–49% of the lobe), 4 (affecting 50–75% of the lobe), or 5 (affecting more than 75% of the lobe) was assigned. Second, the CT score was obtained by adding up the scores of the five lobes. For each patient, the CT score was in the range of 0 to 25.

2.4.2. Evaluation of spleen measurements in patients with COVID-19 pneumonia

The width, thickness and craniocaudal length (CCL) of the spleen dimensions were measured in the initial and follow-up CTs of each patient. Using these values, splenic index (width x thickness x CCL) and splenic volume (30 + 0.58 × width × thickness × CCL) were calculated.[20] Width was measured as the greatest anteroposterior dimension at the hilum. Thickness was measured at the level of the splenic hilum between the inner and outer borders of the spleen. Two or three measurements were averaged when the thickness of the anterior and posterior portions of the spleen considerably differed. Maximum CCL was assessed based on the number of consecutive CT sections through the spleen (Fig. 2).[21,22] The time interval between the initial and follow-up CTs of each patient was recorded, and spleen sizes were compared between the two scans.

2.5. Statistical analyses

Statistical analyses were performed using SPSS version 25.0 (IBM Corp., Armonk, NY, USA). Variables were divided into two as categorical or continuous. Categorical variables were expressed as numbers and percentages. Continuous variables were expressed as mean ± standard deviation or median with interquartile range. Spleen size measurements in the initial and follow-up CTs of the same patients were compared using the paired-samples *t*-test. Pearson's correlation was used to examine the relationship between continuous variables. Independent-samples t-test or Mann-Whitney *U* test was used to compare continuous variables between groups. When the *p* value was less than 0.05, the result was considered statistically significant at a 95% confidence interval.

3. Results

A total of 160 patients with a positive RT-PCR test and radiological findings compatible with COVID-19 in the lungs were included in the study, [55% (n = 88) female and 45% (n = 72) male], and the mean age was 56.8 ± 15.5 years. The mean age of women was 58.2 ± 17.9 years, and that of men was 46.3 ± 8.3 years.

The mean time between the initial and follow-up CTs of all patients was 7.2 ± 2.8 days (median; 5 and IQR; 3–11 days). The splenic volume (244.3 ± 136.7 vs. 303.5 ± 156.3 cm^3) and splenic index (421.2 ± 235.5 vs. 523.2 ± 269.4 cm^3) values were statistically significantly higher in the follow-up CTs of all patients ($p < 0.001$). The increase in the splenic

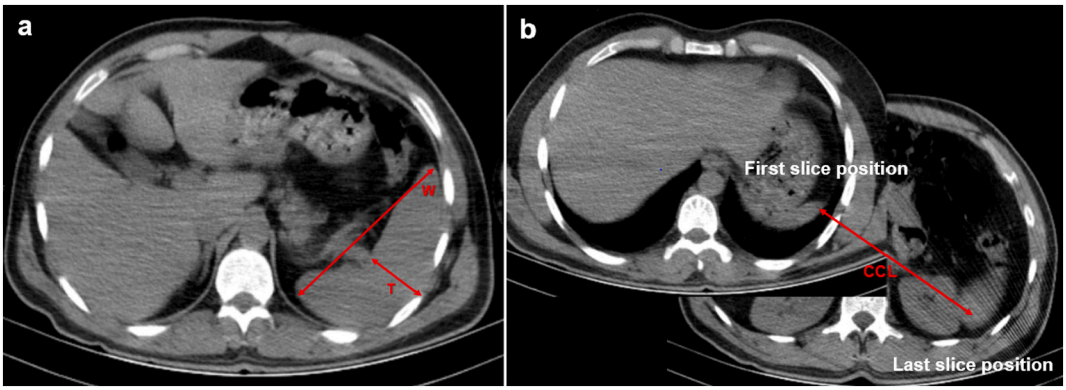

Fig. 2. Axial unenhanced CT image (a) showing the measurement of the greatest anteroposterior width at the level of the hilum and the measurement of the thickness between the inner and outer border of the spleen at the level of the hilum. CT images (b) showing that assessment of the maximum craniocaudal length based on the number of consecutive CT sections passing through the spleen.

volume and index values, respectively was 59.2 ± 52.4 cm^3 and 101.9 ± 90.3 cm^3 ($p < 0.001$), respectively. The width, thickness and CCL of the spleen in the initial and follow-up CTs are shown in Table 1. The COVID-19 CT severity score was significantly higher in the follow-up CT compared to the initial CT (3.7 ± 4.2 vs. 12.5 ± 5.7, respectively; $p < 0.001$). Table 1 also presents the correlation coefficients between the spleen sizes measured in the initial and follow-up CTs. Accordingly, the highest rate of positive correlation was seen in spleen width ($r = 0.982$, $p < 0.001$), followed by splenic volume and index ($r = 0.945$, $p < 0.001$), CCL ($r = 0.898$, $p < 0.001$) and thickness ($r = 0.883$, $p < 0.001$). In addition, there was a positive correlation between the splenic volume calculated in both the initial and follow-up CTs and measured spleen sizes. Among the investigated parameters, splenic thickness showed the best correlation with splenic volume in both the initial and follow-up CTs (Pearson's correlation coefficient $r = 0.909$ and $r = 0.888$, respectively; $p < 0.001$) (Table 2, Fig. 3). When the initial and follow-up hemograms of the patients were evaluated, the white blood cell (6.91 ± 1.37 vs. 8.12 ± 3.7 10^3 cells/μL) and platelet (196.2 ± 80.1 vs. 244.1 ± 85.6 10^3 cells/μL) counts were significantly higher than the baseline ($p < 0.001$). However, the lymphocyte counts were significantly lower in the follow-up examinations compared to the initial examination (1.46 ± 0.6 and 1.63 ± 0.7 10^3 cells/μL, respectively; $p = 0.031$) (Table 3).

As shown in Table 4, the rates of mechanical ventilation, ICU admission and mortality were 23.1% (n = 37), 33.8% (n = 54), and 21.2% (n = 34), respectively. Between all three groups, there was no significant difference in the amount of splenic volume increase on follow-up CTs. At least one comorbidity was present in 47.5% of the patients (n = 135), with the most common being hypertension.

4. Discussion

In the current study, the results revealed that COVID-19 patients with progressive lung involvement had a significant increase in spleen size in early stage. It also showed that the increase in spleen size measured on CT correlated with the COVID-19 pneumonia severity score. To our knowledge, this is the first study evaluating the change in spleen size between the initial and follow-up CTs of the same patients. Moderate or severe increase in spleen size is a clinical pathological finding that can be commonly seen in various etiologies, including congestion states, excessive antigenic stimulation, excessive destruction of blood cells and neoplastic infiltration, and viral infections presenting with cytokine storm.[23–26] Another condition that causes the enlargement of the spleen is a compensatory response secondary to hematological suppression (extramedullary hematopoiesis) in the bone marrow.[27,28] In a case report, a 17-year-old male patient was reported to develop hemophagocytic lymphohistiocytosis secondary to COVID-19 infection, accompanied by and lymphadenopathy and splenomegaly.[8] It is noteworthy that after admission to the hospital, the number of platelets rapidly increased in a short period of one week, and this can be considered as an indicator of a compensatory response. In our study, while the number of platelets increased in the patient group within a week, the number of lymphocytes decreased further (Table 3). We observed that while the COVID-19 CT severity score increased, the number of lymphocytes responsible for the immune response specific to viral infections decreased, and despite this decrease, non-specific immune response cells increased. Many studies have reported that SARS-CoV-2 infection can cause immune damage, and the reduction of lymphocytes is very common in severe or elderly COVID-19 patients. As the number of specific immune response cells decreases, the increasing number of non-specific cells may trigger a condition associated with immune damage indicated by a higher COVID-19 CT severity score in the lungs.[9,29]

Thrombotic microangiopathy, disseminated thrombosis and intravascular coagulation are well-defined conditions in COVID-19 patients.[30] Necrosis and immunosuppression caused by microthrombi in COVID-19 infections have also been reported to cause a decrease in spleen size in autopsy cases.[31] In the histopathological examinations of autopsy specimens in two studies, one with six and the other with ten cases, decreased spleen cell composition, white pulp atrophy, neutrophil and plasma cell infiltration, decrease in or absence of lymph follicles, increased ratio of red pulp to white pulp, decreased T and B cells due to necrosis and apoptosis, and corpuscular atrophy were reported in postmortem examinations of patients with COVID-19 infections.[13,15] In addition, the microscopic examination of the vessels revealed splenic infarction due to arterial thrombosis, CD20 + B cells surrounding the splenic artery, and fibrotic tissue proliferation in the sinuses. Both studies included cases that resulted in death due to COVID-19 infection. One of these studies included seven men and three women aged 39 to 87 years, with a mean age of 68.3 years, and of these 10 patients, four had a history of cancer and a further four had an underlying disease.[15] Similarly, a reduction in spleen size and weight loss was detected in an autopsy study conducted during the 2003 SARS-CoV outbreak.[32] Splenomegaly is also reported in articles presenting the autopsy results of COVID-19-related deaths. In a case series in which autopsy cases were presented, splenomegaly (350 g and 505 g) was found in two patients and splenic atrophy (63 g) was found in one patient.[33] In another study in which four autopsy cases were presented, the presence of splenomegaly was detected in one case, and histologically red pulp hemorrhage was reported together with hemophagocytic histiocytes in the same case.[34] In conclusion, while autopsy results generally indicate splenic atrophy, they can also show the presence of splenomegaly in some cases and reveal changes in spleen size depending on the course of infection.[33,35]

Table 1
Comparison of spleen sizes and COVID-19 CT severity scores between the initial and follow-up CT scans of the same patients

	Initial CT	Follow-up CT	Amount of increase	Correlation coefficient (r)	P value
Width (mm)	96.6 ± 16.7	100.3 ± 16.6	3.7 ± 3.2	0.982	<0.001[a]
Thickness (mm)	40.9 ± 8.7	44.7 ± 10.7	3.8 ± 5.1	0.883	<0.001[a]
Craniocaudal length (mm)	96.9 ± 19.5	107.9 ± 19.5	9.7 ± 9.1	0.898	<0.001[a]
Splenic volume (cm^3)	244.3 ± 136.7	303.5 ± 156.3	59.2 ± 52.4	0.945	<0.001[a]
Splenic index (cm^3)	421.2 ± 235.5	523.2 ± 269.4	101.9 ± 90.3	0.945	<0.001[a]
COVID-19 CT severity score	3.7 ± 4.2	12.5 ± 5.7	8.8 ± 4.6	0.597	<0.001[a]

Data are expressed as mean ± standard deviation. Significance was determined with the paired-sample *t*-test.
[a] Statistically significant. CT, computed tomography.

Table 2
Correlation analysis between calculated splenic volume and spleen measurements

	Splenic volume in initial CT		Splenic volume in follow-up CT	
	Correlation coefficient (r)	P value	Correlation coefficient (r)	P value
Spleen width	0.789	<0.001	0.791	<0.001
Spleen thickness	0.909	<0.001	0.888	<0.001
Spleen craniocaudal length	0.828	<0.001	0.777	<0.001
COVID-19 CT severity score	0.339	<0.001	0.397	<0.001

CT, computed tomography.

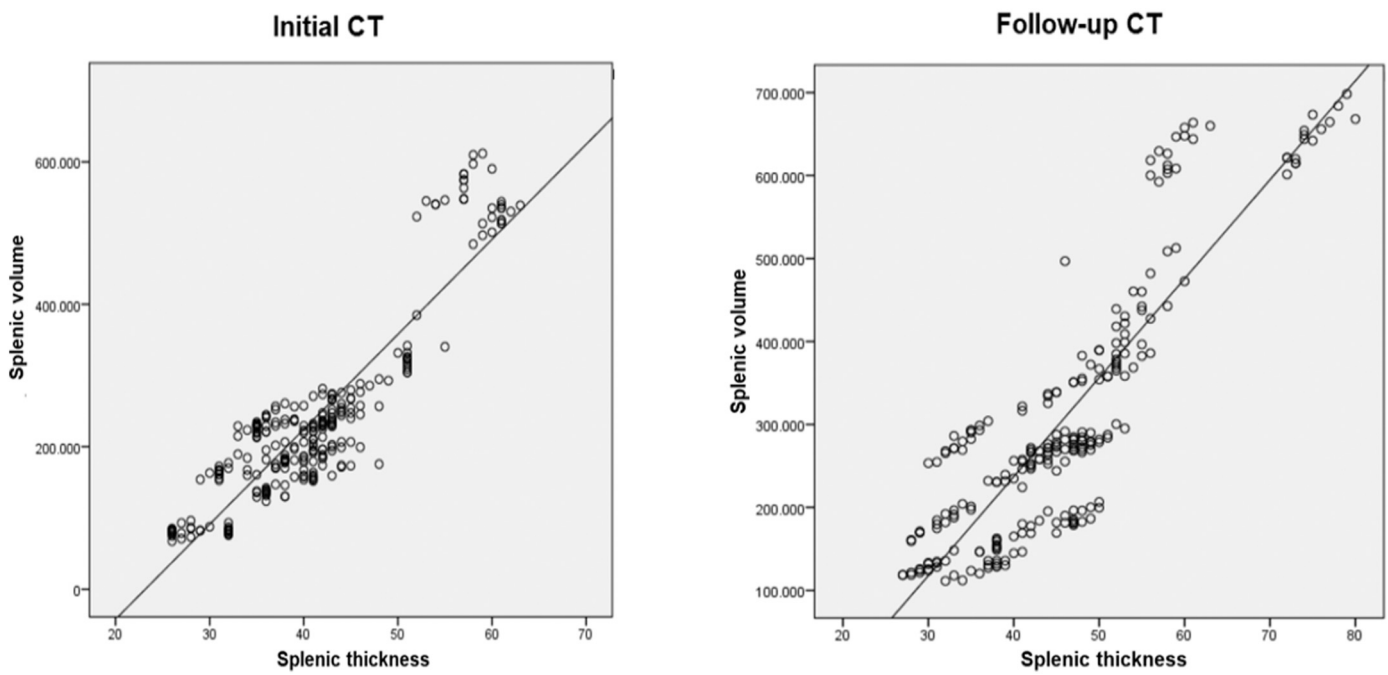

Fig. 3. Scatter plot showing a high positive correlation of splenic volume and splenic thickness in the initial and follow-up computed tomography (CT) scans. Splenic volume and thickness appear to have increased moderately in the follow-up CT.

Table 3
Comparison of parameters in initial and follow-up hemograms of the same patients

	Initial hemogram	Follow-up hemogram	P value
WBC (10^3 cells/μL)	6.91 ± 1.37	8.12 ± 3.7	<0.001[a]
Platelet count (10^3 cells/μL)	196.2 ± 80.1	244.1 ± 85.6	<0.001[a]
Lymphocyte (10^3 cells/μL)	1.63 ± 0.7	1.46 ± 0.6	0.031[a]

Data are expressed as mean ± standard deviation. Significance was determined with the paired-samples t-test.
WBC, white blood cell count.
[a] Statistically significant.

Table 4
The effect of clinical outcomes and presence of comorbidity on spleen size

Variables		All patients n = 160 (%)	Amount of increase in splenic volume (cm^3)	P value
Mortality	Presence	34 (21.2)	52.3 ± 31.1	0.672
	Absence	126 (78.8)	60.7 ± 53.8	
Intensive care unit admission	Presence	54 (33.8)	50.5 ± 34.5	0.551
	Absence	106 (66.2)	61.3 ± 55.8	
Mechanic ventilation	Presence	37 (23.1)	54.5 ± 33.6	0.829
	Absence	123 (76.9)	59.9 ± 54.6	
Comorbidity	Presence	76 (47.5)	45.7 ± 29.2	0.312
	Absence	84 (52.5)	65.8 ± 59.7	
Hypertension	Presence	52 (32.5)	45.9 ± 32.7	0.106
	Absence	108 (67.5)	63.9 ± 57.2	
Diabetes mellitus	Presence	49 (30.6)	45.8 ± 35.1	0.124
	Absence	111 (69.4)	62.7 ± 55.4	
Cardiac disease	Presence	47 (29.3)	43.3 ± 32.4	0.072
	Absence	113 (70.7)	64.9 ± 55.1	
Chronic lung disease	Presence	28 (17.5)	52.3 ± 31.8	0.762
	Absence	132 (82.5)	59.4 ± 54.2	
Chronic kidney failure	Presence	9 (5.6)	49.7 ± 32.6	0.703
	Absence	151 (94.4)	57.8 ± 51.3	

Autopsy results may be insufficient to explain the situation in individuals that have recovered from COVID-19 infection. Some studies have reported cases of splenomegaly associated with increased inflammation.[8,36] Since the spleen is not examined in most cases, we consider that splenomegaly reports in the literature are incomplete. This is confirmed by the statement, "incidental moderate splenomegaly compressing the left kidney" included in a case report.[37] Despite the absence of advanced splenomegaly in our study, a significant increase in spleen size and volume was detected after an average of 7.2 ± 2.8 days following the first CT in the 160 followed-up patients, and this increase was found to be correlated with the COVID-19 CT severity scores. In a study evaluating the CT results of 120 laboratory-confirmed COVID-19 patients, 22 patients had mild splenomegaly.[38] Of the patients included in that study, 96 were inward patients, 11 were receiving intensive care, and 13 died, and the splenomegaly rates of these three groups were 19.8% (19/96), 27.3% (3/11), and 0% (0/13), respectively. The data presented in that study can be interpreted as that spleen size increases in cases where immune response and fight against the virus continue, while in those that result in mortality, the spleen is atrophied with necrotic lesions. In order to better understand the changes during the course of infection, we compared spleen size, volume and degree of changes between the initial and follow-up CTs of infected patients, and also investigated the correlation of the virus with pathological changes (COVID-19 CT severity score) in the lungs, which is the primary replication site. For this purpose, we used both conventional measurement techniques in defining spleen size and volume and a new approach described for calculating three-dimensional volume with CT measurements.[23] Furthermore, our results reveal that the best correlation with splenic volume is splenic width. This allows the use of splenic width rather than volume for patients where the spleen does not completely enter the examination area. Therefore, even if the volume is not calculated, even the measurement of the splenic width may be important in evaluating the spleen size. The results we obtained with both measurement methods showed that during the course of COVID-19 infections, spleen size increased within an average of 7.2 ± 2.8 days compared to the initial CT values obtained at the first presentation of the patients, and this increase was correlated with the COVID-19 CT severity score defined according to the lung CT data. However, there was no significant relationship between spleen size and clinical status and presence of

comorbidity in our study group (Table 4).

A minor limitation of this study can be considered as splenic measurements being performed on non-contrast CTs. In addition, the determination of size changes in the spleen was based on splenic volume and index, which closely reflect splenic volume but are directly based on linear measurements, rather than contouring software that allows direct volume morphometry. This may be a limitation, especially in cases where the spleen shows an abnormal shape.

5. Conclusion

In the literature, spleen size in COVID-19 infection is generally reported as part of autopsy results or case reports without any comparison. Our study differs in that it is the first to investigate changes in the spleen during the course of the infection. The current study indicates that spleen size increases slightly-moderately in the first stages of the infection, and this increase is correlated with the COVID-19 pneumonia severity score calculated on the lung CT data and in this respect, it is similar to infections with cytokine storm.

Funding

This research did not receive any specific grant from funding agencies in the public, commercial, or not-for-profit sectors.

CRediT authorship contribution statement

All authors made substantial contributions to conception and design, acquisition of data, or analysis and interpretation of data; took part in drafting the article or revising it critically for important intellectual content; gave final approval of the version to be published; and agree to be accountable for all aspects of the work.

Declaration of competing interest

All authors have participated and approved the manuscript. None of the authors have any financial conflicts or other disclosures.

References

[1] Huang C, Wang Y, Li X, et al. Clinical features of patients infected with 2019 novel coronavirus in Wuhan, China. Lancet 2020;395:497–506. https://doi.org/10.1016/S0140-6736(20)30183-5.
2. WHO. WHO Coronavirus Disease (COVID-19) Dashboard n.d.
[3] Perlman S. Another decade, another coronavirus. N Engl J Med 2020;382:760–2. https://doi.org/10.1056/NEJMe2001126.
[4] Şahiner F, Hoşbul T. Genomic and biologic characteristics of SARS-CoV-2 and other coronaviruses. J Mol Virol Immunol 2020;1:18–29. https://doi.org/10.46683/jmvi.2020.2.
[5] Ackermann M, Mentzer SJJD. Pulmonary vascular pathology in Covid-19. N Engl J Med 2020;383:886–9. https://doi.org/10.1056/NEJMc2022068.
[6] Hui KPY, Cheung M-C, Perera RAPM, et al. Tropism, replication competence, and innate immune responses of the coronavirus SARS-CoV-2 in human respiratory tract and conjunctiva: an analysis in ex-vivo and in-vitro cultures. Lancet Respir Med 2020;8:687–95. https://doi.org/10.1016/S2213-2600(20)30193-4.
[7] Gencer S, Lacy M, Atzler D, van der Vorst EPC, Döring Y, Weber C. Immunoinflammatory, thrombohaemostatic, and cardiovascular mechanisms in COVID-19. Thromb Haemost 2020. https://doi.org/10.1055/s-0040-1718735.
[8] Haigh K, Syrimi ZJ, Irvine S, et al. Hyperinflammation with COVID-19: the key to patient deterioration? Clin Infect Pract 2020;7–8:100033. https://doi.org/10.1016/j.clinpr.2020.100033.
[9] Peng J, Qi D, Yuan G, et al. Diagnostic value of peripheral hematologic markers for coronavirus disease 2019 (COVID-19): a multicenter, cross-sectional study. J Clin Lab Anal 2020;34. https://doi.org/10.1002/jcla.23475.
[10] Cure E, Cure MC. COVID-19 may predispose to thrombosis by affecting both vascular endothelium and platelets. Clin Appl Thromb 2020;26. https://doi.org/10.1177/1076029620933945. 107602962093394.
11. de Almeida Lima AN, Santos Leite Pessoa M, Franco Costa Lima C, Picasso de Araújo Coimbra P, Bezerra Holanda JL. Images in Vascular Medicine: Acute peripheral artery occlusion and ischemic stroke in a patient with COVID-19. Vasc Med (United Kingdom) 2020;25:482–3. doi:https://doi.org/10.1177/1358863X20945020.
[12] Debuc B, Smadja DM. Is COVID-19 a new hematologic disease? Stem Cell Rev Rep 2020. https://doi.org/10.1007/s12015-020-09987-4.
[13] Feng Z, Diao B, Wang R, et al. The novel severe acute respiratory syndrome coronavirus 2 (SARS-CoV-2) directly decimates human spleens and lymph nodes 2020;2:1–18. https://doi.org/10.1101/2020.03.27.20045427.
[14] Li M-Y, Li L, Zhang Y, Wang X-S. Expression of the SARS-CoV-2 cell receptor gene ACE2 in a wide variety of human tissues. Infect Dis Poverty 2020;9:45. https://doi.org/10.1186/s40249-020-00662-x.
[15] Xu X, Chang XN, Pan HX, et al. Pathological changes of the spleen in ten patients with coronavirus disease 2019(COVID-19) by postmortem needle autopsy. Zhonghua Bing Li Xue Za Zhi 2020;49:576–82.
[16] Şahiner F, Gümral R. The use of convalescent plasma and hyperimmunoglobulin in SARS-CoV-2 infections. J Mol Virol Immunol 2020;1:30–42. https://doi.org/10.46683/jmvi.2020.3.
[17] Liu W, Tao Z-W, Wang L, et al. Analysis of factors associated with disease outcomes in hospitalized patients with 2019 novel coronavirus disease. Chin Med J (Engl) 2020;133:1032–8. https://doi.org/10.1097/CM9.0000000000000775.
[18] Zhou Z, Guo D, Li C, et al. Coronavirus disease 2019: initial chest CT findings. Eur Radiol 2020;30:4398–406. https://doi.org/10.1007/s00330-020-06816-7.
[19] Ooi GC, Khong PL, Müller NL, et al. Severe acute respiratory syndrome: temporal lung changes at thin-section CT in 30 patients. Radiology 2004;230:836–44. https://doi.org/10.1148/radiol.2303030853.
[20] Prassopoulos P, Daskalogiannaki M, Raissaki M, Hatjidakis A, Gourtsoyiannis N. Determination of normal splenic volume on computed tomography in relation to age, gender and body habitus. Eur Radiol 1997;7:246–8. https://doi.org/10.1007/s003300050145.
[21] Gayer G, Ben Ely A, Maymon R, Hertz M. Enlargement of the spleen as an incidental finding on CT in post-partum females with fever. Br J Radiol 2012;85:753–7. https://doi.org/10.1259/bjr/92126864.
[22] Gunes SO, Akturk Y. Determination of splenomegaly by coronal oblique length on CT. Jpn J Radiol 2018;36:142–50. https://doi.org/10.1007/s11604-017-0704-1.
[23] Kucybała I, Ciuk S, Tęczar J. Spleen enlargement assessment using computed tomography: which coefficient correlates the strongest with the real volume of the spleen? Abdom Radiol 2018;43:2455–61. https://doi.org/10.1007/s00261-018-1500-9.
[24] Gao Y-M, Xu G, Wang B, et al. J Intern Med 2020. https://doi.org/10.1111/joim.13144. joim.13144.
[25] Chapman J, Bansal P, Goyal AAA. Splenomegaly. Treasure Isl. (FL): StatPearls Publ; 2020. n.d.
[26] Yang Y, Gao F. Clinical characteristics of primary and reactivated Epstein-Barr virus infection in children. J Med Virol 2020;92:3709–16. https://doi.org/10.1002/jmv.26202.
[27] Robertson JH, Burnside P, Salmon DC. Marrow hypoplasia with splenomegaly in adolescence. J Clin Pathol 1980;33:730–4. https://doi.org/10.1136/jcp.33.8.730.
[28] Short C, Lim HK, Tan J, O'Neill HC. Targeting the spleen as an alternative site for hematopoiesis. BioEssays 2019;41:1800234. https://doi.org/10.1002/bies.201800234.
[29] Chen N, Zhou M, Dong X, et al. Epidemiological and clinical characteristics of 99 cases of 2019 novel coronavirus pneumonia in Wuhan, China: a descriptive study. Lancet 2020;395:507–13. https://doi.org/10.1016/S0140-6736(20)30211-7.
[30] Merrill JT, Erkan D, Winakur J, James JA. Emerging evidence of a COVID-19 thrombotic syndrome has treatment implications. Nat Rev Rheumatol 2020;16:581–9. https://doi.org/10.1038/s41584-020-0474-5.
[31] Tabary M, Khanmohammadi S, Araghi F, Dadkhahfar S, Tavangar SM. Pathologic features of COVID-19: a concise review. Pathol Res Pract 2020;216:153097. https://doi.org/10.1016/j.prp.2020.153097.
[32] Ding Y, Wang H, Shen H, et al. The clinical pathology of severe acute respiratory syndrome (SARS): a report from China. J Pathol 2003;200:282–9. https://doi.org/10.1002/path.1440.
[33] Bradley BT, Maioli H, Johnston R, et al. Histopathology and ultrastructural findings of fatal COVID-19 infections in Washington state: a case series. Lancet 2020;396:320–32. https://doi.org/10.1016/S0140-6736(20)31305-2.
[34] Prilutskiy A, Kritselis M, Shevtsov A, et al. SARS-CoV-2 infection–associated hemophagocytic lymphohistiocytosis an autopsy series with clinical and laboratory correlation. Am J Clin Pathol 2020;154:466–74. https://doi.org/10.1093/AJCP/AQAA124.
[35] Tombolini A, Scendoni R. SARS-CoV-2-related deaths in routine forensic autopsy practice: histopathological patterns. Int J Leg Med 2020;134:2205–8. https://doi.org/10.1007/s00414-020-02354-5.
[36] Blumfield E, Levin TL, Kurian J, Lee EY, Liszewski MC. Imaging findings in multisystem inflammatory syndrome in children (MIS-C) associated with coronavirus disease (COVID-19). Am J Roentgenol 2020:1–11. https://doi.org/10.2214/AJR.20.24032.
[37] Khader M, Al Bishawi A, Kambal A, Abdelmajid A. SARS-CoV-2 infection presenting as colitis with chest and abdomen CT findings. Radiol Case Rep 2020;15:2427–32. https://doi.org/10.1016/j.radcr.2020.09.035.
[38] Tabatabaei SMH, Talari H, Moghaddas F, Rajebi H. CT features and Short-term prognosis of COVID-19 pneumonia: a single-center study from Kashan. Iran Radiol Cardiothorac Imaging 2020;2:e200130. https://doi.org/10.1148/ryct.2020200130.