Since January 2020 Elsevier has created a COVID-19 resource centre with free information in English and Mandarin on the novel coronavirus COVID-19. The COVID-19 resource centre is hosted on Elsevier Connect, the company's public news and information website.

Elsevier hereby grants permission to make all its COVID-19-related research that is available on the COVID-19 resource centre - including this research content - immediately available in PubMed Central and other publicly funded repositories, such as the WHO COVID database with rights for unrestricted research re-use and analyses in any form or by any means with acknowledgement of the original source. These permissions are granted for free by Elsevier for as long as the COVID-19 resource centre remains active.

Neurochirurgie xxx (xxxx) xxx–xxx

Disponible en ligne sur
ScienceDirect
www.sciencedirect.com

Elsevier Masson France
EM|consulte
www.em-consulte.com

Short clinical case

Acute presentation of third ventricular cavernous malformation following COVID-19 infection in a pregnant woman: A case report

H. Saberi*, R.R. Tanha, N. Derakhshanrad, M.J. Soltaninejad

Department of neurosurgery, Imam Khomeini hospital, Tehran University of medical sciences, Keshavarz boulevard, Tehran, Iran

ARTICLE INFO

Article history:
Received 20 December 2020
Received in revised form 3 March 2021
Accepted 6 March 2021
Available online xxx

Keywords:
Cavernous malformation
Hydrocephalus
Hemorrhage
Pregnancy
COVID-19

ABSTRACT

Background. – Cerebral cavernous malformation (CCM) in third ventricular area may become symptomatic relatively rarely, secondary to hemorrhage and growth or rupture into the ventricle, causing obstructive hydrocephalus, during third trimester of pregnancy.

Case description. – A 34^{+4} weeks pregnant (G4P1A2) lady was admitted to one of our satellite hospitals with one-week history of severe headache, blurred vision, nausea, vomiting, and right-sided facial numbness. At presentation, she had sudden decreased level of consciousness with Glasgow Coma Scale (GCS) equal to 4, and bilateral fixed pupils. A brain computed tomography (CT) showed enlargement of both lateral ventricles with 2.5 cm sized round hemorrhagic lesion at the right posterior thalamic region. After medical stabilization and placement of an external ventricular drain (EVD), the patient was referred for neurosurgical intervention. Magnetic resonance imaging (MRI) revealed a cavernous hemangioma adjacent to the right posterior wall of the third ventricle. After cesarean section and anterior interhemispheric trans-callosal approach, the mass was removed totally. However, on third postoperative day, she experienced mild hypoxia and dyspnea with fever. Chest CT-scan of the patient showed bilateral consolidation. Thereafter, COVID-19 was confirmed subsequently with positive nasopharyngeal swab testing for RT-PCR. The patient was treated as COVID-19 infection and symptoms improved on day 10 of the treatment and completely recovered.

Conclusions. – COVID-19 may promote ICH from CCM leading to obstructive hydrocephalous in our patient.

© 2021 Elsevier Masson SAS. All rights reserved.

1. Introduction

Cavernous malformations (CM) around the third ventricle may become symptomatic secondary to hemorrhage and growth or rupture into the ventricle, causing hydrocephalus [1].

To date, rare cases of obstructive hydrocephalus due to cerebral cavernous malformations (CCM) have been reported in pregnancy. Here, we present a case of young pregnant woman with acute obstructive hydrocephalus associated with confirmed coronavirus disease 2019 (COVID-19) infection.

2. Case description

A 29-year-old 34^{+4} weeks pregnant (G4P1A2), right-handed female without significant past medical history such as hypertension, diabetes, heart disease, and malignancy, was admitted to a satellite referring hospital in our region with one-week history of severe headache, blurred vision, nausea, vomiting, and right-sided facial numbness. At presentation, she had sudden decreased level of consciousness with Glasgow Coma Scale (GCS) equal to 4 and bilateral fixed pupils due to acute hydrocephalus treated with external ventricular drain (EVD) elsewhere.

The EVD had been placed urgently with resolution of hydrocephalus and improvement of level of consciousness (GCS = 14). She had no history of central nervous system (CNS) infection or trauma.

At her admission in our centre, fundoscopic examination revealed bilateral papilledema. A brain computed tomography (CT) showed enlargement of both lateral ventricles with 2.5 cm sized round hemorrhagic lesion at the right thalamomesencephalic region.

On examination, the patient was drowsy and neurological examination showed left-sided moderate hemiparesis (3/5) and hemisensory loss, and sensory deficit on the right side of the face. Preoperative blood pressure (BP) was 120/70 mm Hg, heart rate (HR) was 88 bpm, respiratory rate (RR) was 18, oxygen saturation was 96% and axial body temperature = 37 °C without any history of

* Corresponding author.
E-mail address: hgsaberi@yahoo.com (H. Saberi).

https://doi.org/10.1016/j.neuchi.2021.03.010
0028-3770/© 2021 Elsevier Masson SAS. All rights reserved.

Please cite this article as: Saberi H, et al, Acute presentation of third ventricular cavernous malformation following COVID-19 infection in a pregnant woman: A case report, Neurochirurgie, https://doi.org/10.1016/j.neuchi.2021.03.010

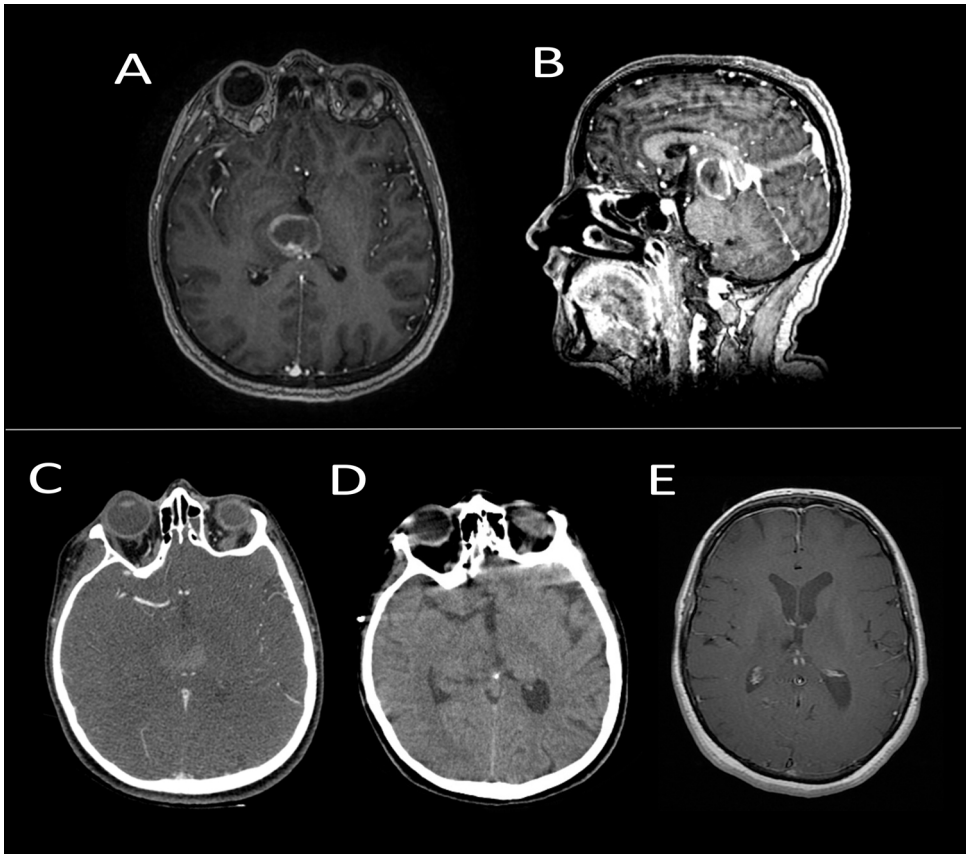

Fig. 1. No obvious edema was found in adjacent thalamic parenchyma and only minimal peripheral rim enhancement around mass was found on contrast enhanced in axial (A) and sagittal (B) T1-weighted images. CT angiograms revealed no vascular abnormalities (C). Postoperative contrast enhanced brain CT scan (D) and MRI showing no residual lesion (E).

drug reaction and fever. On laboratory tests, there were leukocytosis with white blood cells (WBCs) counts equal 15,600 per mm^3, lymphopenia with 6.6% lymphocyte and mild elevation of the C-reactive protein (CRP), equal to 7 mg/L. Regarding the COVID-19 pandemic, to rule out corona infection, RT-PCR test of nasal swab was requested.

Three-Tesla cerebral magnetic resonance imaging (MRI) revealed a single lesion measuring 2.5 cm × 2.0 cm × 1.5 cm at the right posterior thalamic region and adjacent to the right side of third ventricle wall with endophytic growth into the 3rd ventricle, causing obstructive hydrocephalus.

Cerebral CT angiogram revealed no vascular abnormalities (Fig. 1A–C). The patient was finally diagnosed with intracranial space-occupying lesion and cavernous hemangioma.

The patient provided written informed consent for pregnancy termination and neurological surgery at the 36th week of gestation, because of previous history of cesarean section in the second pregnancy. Interdisciplinary approach by the neurosurgeons, obstetricians and anesthetist is pivotal for delicate care of the patient and the baby.

In this patient because of the COVID-19 pandemic, for decreasing aerosolisation as protocols [2], general anesthesia with rapid sequence induction was performed. Delivery was uneventful and the infant girl weighing 2400 g was born healthy.

After setting up the stereotactic neuronavigation system, through a planned horseshoe-shaped incision and craniotomy in the right frontal parasagittal region, performed by placing burr holes on both sides of the superior sagittal sinus. Durotomy was done, and the dural flaps were reflected medially up towards the superior sagittal sinus. Anterior interhemispheric trans-callosal approach was performed for removing the deep lesion. The lateral ventricle was entered after callosotomy, and the septum pellucidum was opened to prevent it from obstructing the surgical field. The mass was removed totally without significant bleeding after localising with neuronavigation. Operative findings showed that the mass with xanthochromic and lobular surface was located in the lateral wall of third ventricle. A new EVD was placed in view of the risk of postoperative hydrocephalus through the same burhole. Surgery was uneventful, and there was no intraventricular hemorrhage (IVH) or intracerebral hemorrhage (ICH) in the immediate postoperative brain CT-scan. Patient, intubated, was transferred to ICU and 14 hours later, extubated fully awake.

Follow-up brain CT-scans showed decreased ventricular size, and on the tenth post-surgical day, the EVD was removed.

Histopathological examination was compatible with small fragments of vascular tissue characteristics of cavernous hemangioma without intervening brain tissue with lymphocytic infiltration (Fig. 2).

After 48 hours, the patient recovered completely in a stepwise manner, except for trace weakness of the left extremities (4/5), as well as trace decreased position sensation on the entire left side of the body.

However, on postoperative day 3, she experienced mild hypoxia, tachycardia, and dyspnea with fever. Blood pressure was 114/70 mm Hg, HR was 112 bpm, RR was 18, oxygen saturation was 94% and axial body temperature = 38.5 °C. Other symptoms included drowsiness or impaired consciousness, delusions following fever, and delirium. A complete infective screening test (urine, blood, CSF and sputum culture) was carried out without any positive result. Cardiac echocardiogram showed good left ventricular

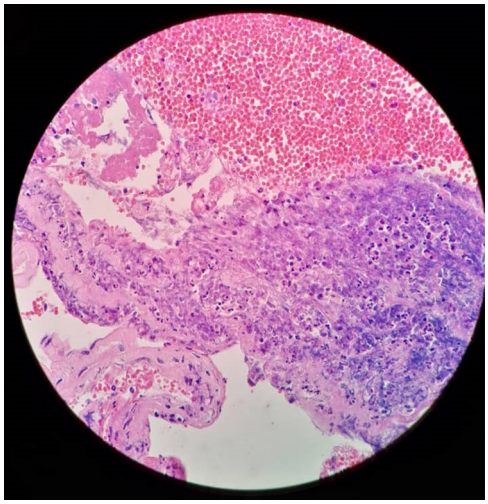

Fig. 2. Histopathological examination was compatible with small fragments of vascular tissue characteristics of cavernous hemangioma without intervening brain tissue with lymphocytic infiltration.

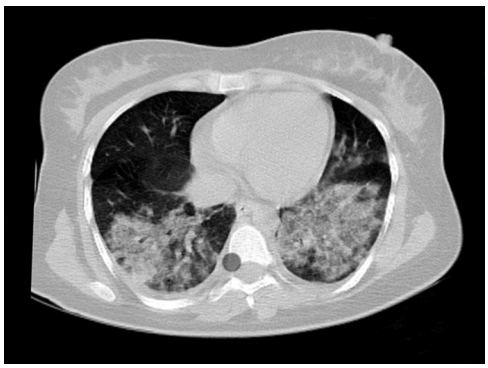

Fig. 3. Chest CT-scan of the patient showed bilateral patchy consolidation with air-bronchogram in the lower lobes, multiple bilateral patchy ground-glass opacities, and bilateral pleural effusion in favour of COVID-19 infection.

function with ejection fraction about 70%. Laboratory workup was unremarkable, except for lymphopenia (WBCs = 8100 per mm^3 with 4.7% lymphocyte), moderate elevation of the CRP (55 mg/L), high serum lactate level = 48 mg/dL, and lumbar CSF analysis revealed WBCs = 5 cells/μL, lactate dehydrogenase = 15.6, protein = 49.9 mg/dL, glucose = 56 mg/dL. Chest CT-scan of the patient showed bilateral patchy consolidation with air-bronchogram in the lower lobes, multiple bilateral patchy ground-glass opacities, and bilateral pleural effusion (Fig. 3). Thereafter, COVID-19 was confirmed subsequently with positive testing for real-time polymerase chain reaction (RT-PCR) from a nasopharyngeal swab and the patient was admitted to the pulmonary ICU for COVID-19 patients.

The patient was treated as COVID-19 pneumonia by atazanavir capsules 300 mg/po/daily, azithromycin 500 mg tablets/po/daily, and supportive care, including oxygen therapy with a high-concentration mask with reservoir bag (10L/min), and respiratory physiotherapy. The symptoms improved on day 10 of the treatment. She remained in good health after completing her treatment course until she was discharged three weeks after the admission. Just post-operative brain CT scan and six month follow-up brain MRI showed gross total resection of the CCM (Fig. 1D, E respectively) and complete clinical recovery was observed.

3. Discussion

Overall, estimates of the hemorrhage risk of CM is 0.7% to 6% per year, according to variety of risk factors, such as prior CM bleeding, family history of CM, causative CM gene [3], and infratentorial location [4], whereas age, sex, size, multiplicity, and associated developmental venous anomalies are not risk factors for CM bleeding [5]. Therefore, we recommend that all pregnant women with a diagnosis of a CCM should be referred to a neurosurgeon and evaluated on aforementioned risk of hemorrhage.

Given that our patient had none of these risk factors for hemorrhage of CCM and also had asymptomatic cavernoma in three previous pregnancies, we hypothesise that COVID-19 may involve cranial hemorrhage in this patient through thrombangitis phenomenon [6], as multiparous women have less problematic delivery.

COVID-19 is an infectious disease caused by severe acute respiratory syndrome coronavirus 2 (SARS-CoV-2). Apart from respiratory complications, acute cerebrovascular disease (CVD) has been observed in some patients with COVID-19. Li et al. showed that in 4.6% of patients with COVID-19 infection developed acute ischemic stroke and 0.5% of them had intracerebral hemorrhage. Also, COVID-19 with new onset of CVD were more likely to have cardiovascular risk factors, including hypertension, diabetes and medical history of CVD [7]. In our patient, the thrombangitic pathophysiology for COVID-19 may have precipitated hemorrhage from a paraventricular asymptomatic CCM.

In addition, patients with atypical presentations of COVID-19 may be unaware of their illness especially during the incubation period. Some patients diagnosed with COVID-19 have exhibited only neurological symptoms as the initial symptoms, such as headache, languidness, unstable walking, malaise, cerebral infarction, cerebral hemorrhage and other neurological signs. In a recent study, 36.4% of patients with COVID-19 had neurological manifestations: CNS (24.8%), peripheral nervous system (PNS) (8.9%), and skeletal muscle injury (10.7%). In patients with CNS manifestations, the most common reported symptoms were dizziness, headache, impaired consciousness, and acute cerebrovascular diseases. In patients with PNS symptoms, the most common reported symptoms was taste impairment associated with smell impairment [8]. More severe neurological complications of COVID-19 have also been recently reported, including acute hemorrhagic necrotising encephalopathy [9], ischemic stroke from large-vessel occlusion, acute transverse myelitis, Guillain-Barré syndrome [10], meningitis [11], reversible cranial nerve injuries (Miller-Fisher syndrome) [12], polyneuropathy, and cerebral vasculitis/endotheliitis [6]. The endotheliopathy due to direct endothelial infection with SARS-COV-2 and the indirect damage caused by lymphocytic infiltration play the predominant role in the development of COVID-19-associated coagulopathy as found in our pathologic specimen [13].

Currently, there have been many cases of patients with COVID-19 complicated by cerebral hemorrhages such as our case [14]. Hence, the physiological relationship between COVID-19 and the incidence of cerebral hemorrhage is related to thrombangitis pathology [6,13]. De novo obstructive (non-communicating) hydrocephalus developing during pregnancy is a rarely reported event. Etiology is diverse as infectious (bacterial, viral), CNS malformations, head traumas, tumours, and hemorrhage [15]. Based on these several lines of evidence, we hypothesise that COVID-19 may have precipitated ICH from CCM, followed by obstructive hydrocephalus in our patient.

4. Conclusions

COVID-19 may have precipitated ICH from CCM, followed by obstructive hydrocephalous, in our patient.

Human and animal rights

The authors declare that the work described has not involved experimentation on humans or animals.

Informed consent and patient details

The authors declare that this report does not contain any personal information that could lead to the identification of the patient(s) and/or volunteers.

Disclosure of interest

The authors declare that they have no competing interest.

Funding

This research did not receive any specific grant from funding agencies in the public, commercial, or not-for-profit sectors.

Author contributions

All authors attest that they meet the current International Committee of Medical Journal Editors (ICMJE) criteria for Authorship.

Acknowledgments

The authors would like to express their appreciation and thanks to Sedigheh Hantoushzadeh, M.D. (Professor of obstetrics and gynecology); Fahimeh Ghotbizadeh Vahdani, M.D. (Associate professor of obstetrics and gynecology), Arash Seifi, M.D. (Assistant professor of infectious disease), Fatemeh Nili Ahmadabadi, M.D., (Associate professor of pathology), and Zahid Huassin Khan, M.D., Professor of neuroanesthesiology.

References

[1] Woodall MN, et al. Cavernous malformations in and around the third ventricle: indications, approaches, and outcomes. Oper Neurosurg 2020;18(6):736–46.
[2] Cook T, et al. Consensus guidelines for managing the airway in patients with COVID-19: guidelines from the Difficult Airway Society, the Association of Anaesthetists the Intensive Care Society, the Faculty of Intensive Care Medicine and the Royal College of Anaesthetists. Anaesthesia 2020;75(6):785–99.
[3] Witiw CD, et al. Cerebral cavernous malformations and pregnancy: hemorrhage risk and influence on obstetrical management. Neurosurgery 2012;71(3):626–31.
[4] Gomez-Paz S, et al. Symptomatic hemorrhage from cerebral cavernous malformations: evidence from a cohort study. World Neurosurg 2020;135:e477–87.
[5] Gross BA, Du R. Hemorrhage from cerebral cavernous malformations: a systematic pooled analysis. J Neurosurg 2017;126(4):1079–87.
[6] Hanafi R, et al. COVID-19 neurologic complication with CNS vasculitis-like pattern. Am J Neuroradiol 2020;41(8):1384–7.
[7] Li Y, et al. Acute cerebrovascular disease following COVID-19: a single centre, retrospective, observational study. Stroke Vasc Neurol 2020;5(3):279–84.
[8] Mao L, et al. Neurological manifestations of hospitalised patients with COVID-19 in Wuhan, China: a retrospective case series study. JAMA Neurol 2020;77(6):683–90.
[9] Poyiadji N, et al. COVID-19–associated acute hemorrhagic necrotising encephalopathy: CT and MRI features. Radiology 2020;296(2):E119–20.
[10] Zhao H, et al. Guillain-Barré syndrome associated with SARS-CoV-2 infection: causality or coincidence? Lancet Neurol 2020;19(5):383–4.
[11] Moriguchi T, et al. A first case of meningitis/encephalitis associated with SARS-Coronavirus-2. Int J Infect Dis 2020;94:55–8.
[12] Gutiérrez-Ortiz C, et al. Miller-Fisher syndrome and polyneuritis cranialis in COVID-19. Neurology 2020;95(5):e601–5.
[13] Iba T, Connors JM, Levy JH. The coagulopathy, endotheliopathy, and vasculitis of COVID-19. Inflamm Res 2020;69(12):1181–9.
[14] Wang H-Y, et al. Potential neurological symptoms of COVID-19. Ther Adv Neurol Dis 2020;13:1–2.
[15] Ekşi MŞ, et al. Management of obstructive hydrocephalus in pregnant patient. Asian J Neurosurg 2018;13(1):123–7.