Received: 26 February 2019 | Accepted: 12 May 2019
DOI: 10.1111/iwj.13149

ORIGINAL ARTICLE

IWJ WILEY

End stage scurvy in the developed world: A diagnostic conundrum but not to be mistaken for pyoderma gangrenosum

Stephanie T. Le[1] | Jenny Z. Wang[1,2] | Claire C. Alexanian[1,3] | Stephanie Y. Johng[3] | Forum B. Patel[1] | Elizabeth A. Wang[1] | Chelsea Ma[1] | Reason Wilken[1] | Michelle Y. Cheng[1] | Emanual Maverakis[1]

[1]Department of Dermatology, University of California, Davis, Sacramento, California
[2]Albert Einstein College of Medicine, Bronx, New York
[3]Georgetown University School of Medicine, Washington, District of Columbia

Correspondence
Emanual Maverakis, MD, Department of Dermatology, University of California, Davis, 3301 C Street, Ste 1300, Sacramento, CA 95816.
Email: emaverakis@ucdavis.edu

Abstract
Scurvy is a clinical syndrome, resulting from ascorbic acid deficiency. Prevalence of the condition is now extremely low in the Western population and its diagnosis can be challenging without a high index of suspicion. When cases do present, they are often misdiagnosed initially. Therefore, a thorough history, physical exam, and laboratory evaluation are key to showing this now rare but extremely well-known disease. We report a case of scurvy manifesting as persistent non-healing lower-extremity ulcerations, initially mistaken for pyoderma gangrenosum. The patient responded to appropriate replacement therapy, but ulcers were slow to heal. As was the case in our patient, symptom reversal may require additional nutritional replacement. We encourage physicians to consider nutritional deficiencies in their differential diagnoses and highlight the incidence of malnutrition in the proper clinical setting to avoid diagnostic delay.

KEYWORDS
ascorbic acid, pyoderma gangrenosum, scurvy, ulcers, wound healing

1 | INTRODUCTION

Scurvy was once considered a disease specific to sailors but has become virtually non-existent in the Western world, with the last documented large-scale outbreak in Afghanistan in 2002.[1] Today, occurrence of vitamin C (ascorbic acid) deficiency, or scurvy, is relatively rare because of the availability of fruits, vegetables, and vitamin-supplemented foods.

We describe an intriguing case of a patient who presented to the dermatology clinic with non-healing ulcers on her bilateral lower extremities, critically low haematocrit, and a variety of non-specific complaints. Her ulcerations had previously been attributed to pyoderma gangrenosum (PG), as PG is generally considered to be a diagnosis of exclusion[2] and her work-up had been entirely negative thus far.

2 | CASE PRESENTATION

A 65-year-old female presented with chronic non-healing bilateral lower-extremity ulcers. The ulcers initially presented 3 years prior and, during this time, continued to grow in size until they became circumferential around her ankles and calves. Vascular and infectious work-ups were unremarkable. Upon presentation to a regional dermatology society, it was concluded that her diagnosis was most consistent with PG, as histopathology showed a neutrophilic infiltrate with no evidence of vasculitis. Following this consensus, the patient was started on tumor necrosis factor inhibitor therapy with infliximab and, when unresponsive, was referred to a specialty immunodermatology clinic for further evaluation.

© 2019 Medicalhelplines.com Inc and John Wiley & Sons Ltd

At the time of her initial presentation, her ulcers were malodorous and covered in feline hair. She had a large 14 × 4 cm ulcer on the right lower extremity (Figure 1A), extending to the lateral and posterior calves, a 2 × 2 cm ulcer over the right medial malleolus, and a 14 × 6 cm ulcer over the left lower extremity (Figure 1B), again, wrapping over the lateral and posterior calf. All ulcers consisted of underlying bright red beefy granulation tissue with thick, adherent, dusky-grey, and necrotic tissue with minimal erythema surrounding the borders. She did not present with any lower extremity oedema. Her left ankle was visibly contracted into an inverted position, preventing normal ambulation and gait. Her general appearance was that of a cachectic, emaciated, and wheelchair-dependent female with frail extremities and poor dentation.

Upon further questioning, she admitted to taking narcotics for pain, which she obtained illicitly. Her diet was limited to fast food hamburgers comprised of meat with ketchup and buns. She noted no fruit intake except for an occasional fruit cocktail. This particular history prompted routine lab work to be obtained to evaluate for malnutrition and delayed wound healing. She was found to have undetectable levels of ascorbic acid (normal 23-114 μmol/L), low-normal levels of niacin (0.81; normal 0.50-8.45 mcg/mL), low-normal pre-albumin (19; normal 16-40 mg/dL), and severely low iron (total iron 11; normal 42-135 μg/dL) and vitamin D levels (14.0; normal 30.0-100.0 ng/mL). She was diagnosed with hypothyroidism (thyroid stimulating hormone 18.77; normal 0.35-3.30 μIU/mL) and severe anaemia (haemoglobin 8.5, MCV 73.1, iron 11, ferritin 4). Her vitamin B12 and zinc levels were within normal limits. After the patient was found to have undetectable ascorbic acid, she was re-examined for signs of scurvy. Upon closer inspection of her lower extremities, bright red pinpoint macules, thin corkscrew hairs (Figure 2A), and perifollicular haemorrhages (Figure 2B) were noted.

Over the course of the next 3 years, she was encouraged to improve her diet with more fruits, vegetables, and protein, with an emphasis on foods high in vitamin C, and was started on iron and thyroid hormone supplementation. She was also seen two to three times a week for in-office wound care, which consisted of gentle debridement, silver sulfadiazine to excessive granulation tissue, gentian violet, xeroform, timolol

Key Messages

- although scurvy is a well-known classic medical diagnosis, it remains difficult to identify clinically, possibly owing to it being considered a historic disease not present in developed countries
- maintain a high index of suspicion for nutritional disorders, such as scurvy, in patients who present with ulcerations of unclear aetiologies or experience an unusual response to standard therapy
- early symptoms of scurvy include petechiae, loss of appetite, fatigue, ecchymosis, perifollicular haemorrhages, and corkscrew hairs. Treatments of scurvy should address the deficiency through vitamin C supplementation or reversal of the underlying conditions that contribute to vitamin C deficiency

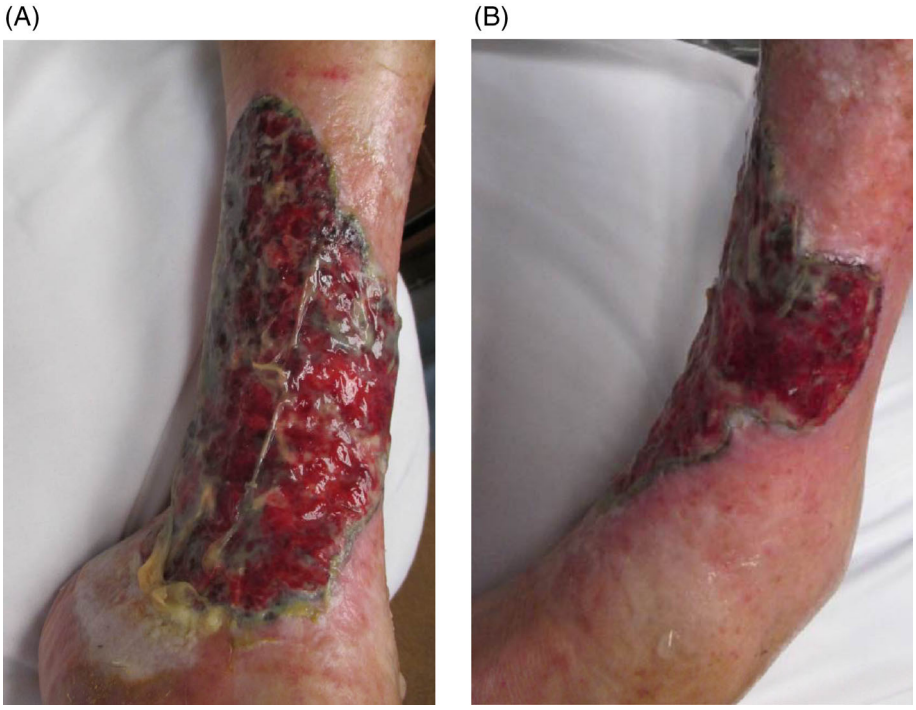

FIGURE 1 A, At initial presentation, the patient's left medial malleolus was encompassed with a beefy red ulceration measuring 14 × 6 cm. B, A 2 × 2 cm smaller ulcer over the right medial malleolus

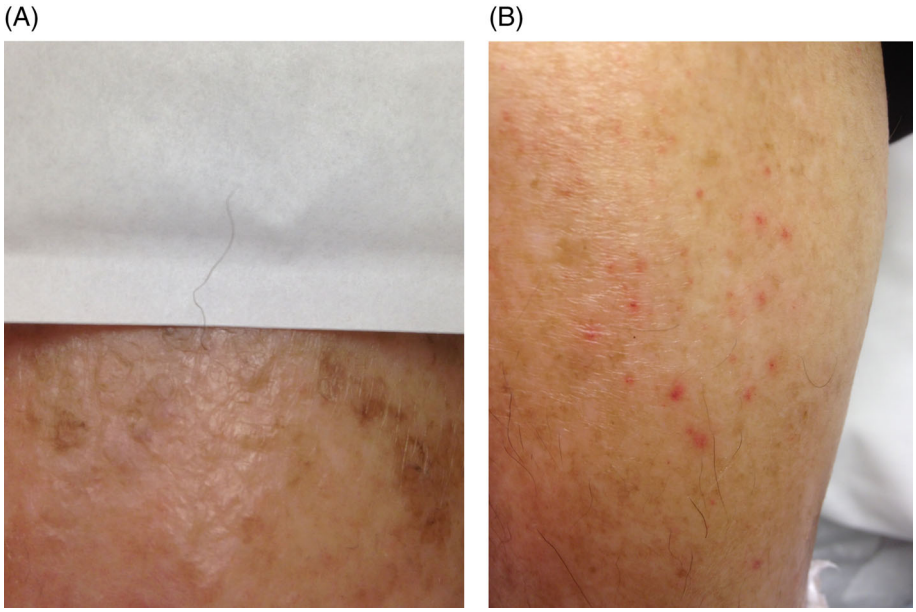

FIGURE 2 A, Hallmark features of scurvy: corkscrew hairs. B, Perifollicular haemorrhage

drops, and regular 3-layer compressive dressing changes, with an emphasis on keeping the ulcers clean. After failing oral iron replacement therapy, she received several infusions of IV iron to replete her iron levels.

Two years after her initial presentation, her ascorbic acid level increased to 38, total iron increased to 52 (although ferritin remained low at 7), and thyroid stimulating hormone improved to 9.36. She admitted to intermittent compliance with her thyroid replacement therapy. The most recent laboratory values to date are from 2017, which included an improved ascorbic acid level of 54 and ferritin of 10. Her care was complicated by socioeconomic difficulties, including lack of transportation and difficulty with home health care. Clinically, her symptoms of scurvy eventually resolved, and her ulcers completely healed (Figure 3).

3 | DISCUSSION

Scurvy is a clinical syndrome resulting from a deficiency of ascorbic acid, an essential cofactor and bionutrient required for the synthesis of collagen.[1,3] Although rare in the United States, scurvy can occur in severely malnourished individuals and in settings such as drug abuse, alcoholism, eating

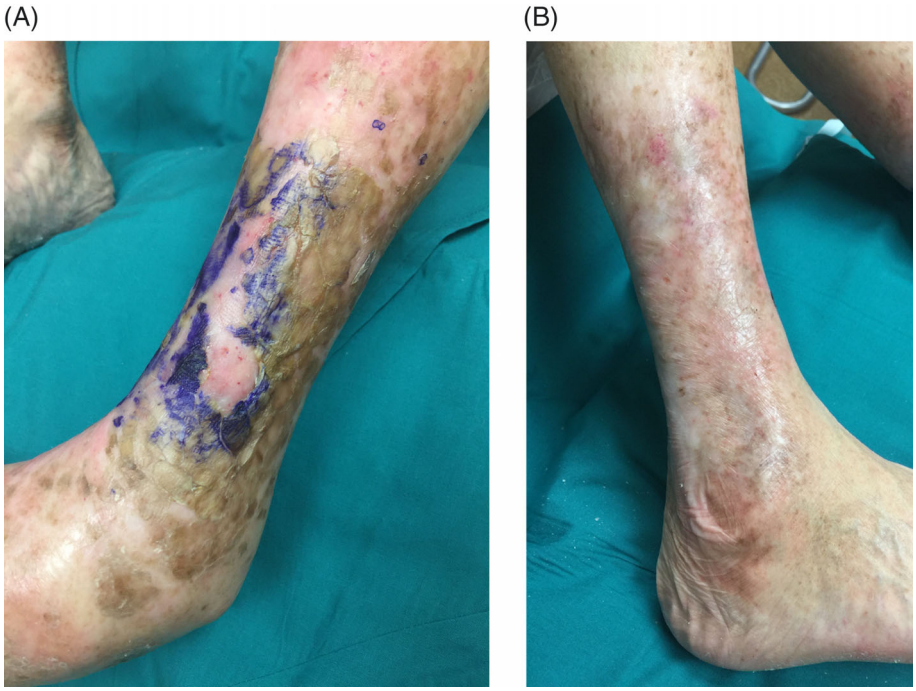

FIGURE 3 A, After vitamin supplementation and diligent wound care, the patient's left medial malleolus ulcer. B, Right lower extremity ulcer markedly improved

disorders, and homelessness.[4-6] It has also previously been reported as a complication in malnutritional states, including oncology patients and those who require total parenteral nutrition or enteral feeds.[6] Another population that is quickly becoming largely at risk includes the elderly, with reports indicating that as many as 85% of institutionalised elderly being undernourished.[1] Affected patients considered to be "well-nourished" have also been reported, with authors attributing the resurgence of this condition to the influx of large chain fast food restaurants and a shortage of healthier alternatives, such as fresh produce.

The pathophysiology of scurvy results from impaired collagen formation, which results in disruption of connective tissues, blood vessels, wound healing, and bone formation and remodelling.[1,3,7] With insufficient intake, ascorbic acid stores can become depleted within the first 3 months and symptoms can present as quickly as the first month. Clinical manifestations often do not present until body stores of ascorbic acid drop below 350 mg or until the serum level reaches 0.2 mg/dL.[5,8] The patient presented herein had undetectable serum levels.

Several findings encompass the clinical presentation of scurvy. Early symptoms include petechiae, loss of appetite, fatigue, ecchymosis, perifollicular haemorrhages, and corkscrew hairs.[9] With disease progression, patients may report myalgia, bone pain, and mood changes, including depression.[10] Additional clinical symptoms are gum disease, lower extremity oedema, severe anaemia, non-healing wounds, haemarthrosis, jaundice, and ultimately death.[5-7,9] The lower extremities and buttocks are commonly involved with cutaneous manifestations, including follicular hyperkeratosis and perifollicular haemorrhage. Late findings can include neuropathy, syncope, leukopenia, and intracerebral haemorrhage.[6] Our current patient was critically ill at presentation.

Clinicians can be easily misguided when presented with findings of lower-extremity ulcerations in the absence of clear causality. Common aetiologies include vascular insufficiency, haematologic disorders, autoimmune processes, and infection.[5,6,11] In cases refractory to standard ulcer care, clinicians should consider nutritional deficiencies in their differential, as symptoms can be difficult to distinguish from other aetiologies.[11] In our particular case, the patient presented with severe ulcerative findings exacerbated by poor wound healing secondary to vitamin C deficiency. Additionally, the vitamin C deficiency likely contributed to her severe anaemia. In such scenarios, vitamin replacement therapy alone is likely insufficient to heal wounds. This patient required iron and thyroid replacement therapy, as well as aggressive wound care to allow her ulcers to heal.

Unlike the ulcers associated with scurvy, PG ulcers are quickly progressive, begin in the deep dermis, and avoid the sites of prior ulceration.[12,13] Indeed PG remains a challenging diagnosis and the initial absence of clear diagnostic criteria may be one reason why 39% of patients who initially received a diagnosis of PG are ultimately found to have an alternative diagnosis.[14] To help remedy these issues, diagnostic guidelines for PG have recently been developed and should be implemented in challenging cases, such as the one described herein.[2,15,16] The potentially detrimental side effects of initiating non-essential immunosuppressive therapy, which is the mainstay treatment for PG,[17,18] may also have been avoided.

In contrast to PG, the diagnosis of scurvy can be successfully made by conducting a thorough history and physical examination, with special attention paid to hallmarks of malnutrition and pathognomonic signs of scurvy, such as perifollicular haemorrhages arising to corkscrew hairs.[4,5] In our case, the patient's classic features of scurvy were unrecognised by numerous dermatologists, likely because the ulcers were so impressive that fine clinical findings were overlooked. Although the ascorbic acid level was undetectable in our patient, a serum vitamin C value of <10 μmol/L is enough to be suggestive of scurvy. While the histopathology associated with scurvy is often broad and non-specific, histology can exclude other diagnoses, such as vasculitis.[1] Subtle clinical findings, such as corkscrew hairs, follicular hyperkeratosis, and perifollicular haemorrhage, can solidify the diagnosis if identified on exam.[5,8]

Treatments include addressing the deficiency through vitamin C supplementation or reversal of the underlying conditions that contribute to vitamin C deficiency, such as alcoholism. Dosing varies widely, but adult patients are typically treated with 100 to 300 mg vitamin C daily orally for 1 month or 300 to 1000 mg daily intravenously, intramuscularly, or subcutaneously until body stores are replenished.[19] Symptoms such as fatigue, myalgias, and arthralgias can improve within 1 week, while gingival bleeding and perifollicular haemorrhage may require at least 2 weeks.[5] Complete resolution of symptoms can occur after 3 months of supplementation, but may require more time in severe cases.[5]

Our case emphasises the importance of maintaining a high index of suspicion for nutritional disorders, such as scurvy, in patients who present with cutaneous ulcerations of unknown aetiology or unusual response to standard therapy. This is especially important for our increasingly aging patient population, who are among the greatest at risk of developing nutritional deficiencies.

4 | CONCLUSION

In conclusion, patients who are at increased risk of nutritional deficiency may present with ulcerations mimicking PG. Thus, scurvy should be considered as one of the

differential diagnoses for ulceration in these cases, especially in individuals with known history of drug abuse, alcoholism, eating disorders, homelessness, or the institutionalised elderly.

CONFLICT OF INTERESTS

The authors have no conflicts of interest to declare.

ORCID

Claire C. Alexanian https://orcid.org/0000-0002-0158-7718

REFERENCES

1. Velandia B, Centor RM, McConnell V, Shah M. Scurvy is still present in developed countries. *J Gen Intern Med*. 2008;23:1281-1284.
2. Maverakis E, Ma C, Shinkai K, et al. Diagnostic criteria of ulcerative pyoderma gangrenosum: a Delphi consensus of international experts. *JAMA Dermatol*. 2018;154:461-466.
3. Pimentel L. Scurvy: historical review and current diagnostic approach. *Am J Emerg Med*. 2003;21:328-332.
4. Abou Ziki M, Podell D, Schiliro D. The value of the history and physical examination—sailing through medicine with modern tools: a teachable moment. *JAMA Intern Med*. 2015;175:1901-1902.
5. Mintsoulis D, Milman N, Fahim S. A case of scurvy-uncommon disease presenting as panniculitis, purpura, and oligoarthritis. *J Cutan Med Surg*. 2016;20:592-595.
6. Francescone MA, Levitt J. Scurvy masquerading as leukocytoclastic vasculitis: a case report and review of the literature. *Cutis*. 2005;76:261-266.
7. Wijkmans RA, Talsma K. Modern scurvy. *J Surg Case Rep*. 2016;2016:1-3.
8. Mertens MT, Gertner E. Rheumatic manifestations of scurvy: a report of three recent cases in a major urban center and a review. *Semin Arthritis Rheum*. 2011;41:286-290.
9. Agarwal A, Shaharyar A, Kumar A, Bhat MS, Mishra M. Scurvy in pediatric age group—a disease often forgotten? *J Clin Orthop Trauma*. 2015;6:101-107.
10. Leger D. Scurvy: reemergence of nutritional deficiencies. *Can Fam Physician*. 2008;54:1403-1406.
11. Edge JC, Callen J. Scurvy masquerading as cellulitis. *J am Acad Dermatol*. 2004;50:P43.
12. Wang EA, Maverakis E. The rapidly evolving lesions of ulcerative pyoderma gangrenosum: a timeline. *Int J Dermatol*. 2018;57:983-984.
13. Wang EA, Steel A, Luxardi G, et al. Classic ulcerative pyoderma gangrenosum is a T cell-mediated disease targeting follicular adnexal structures: a hypothesis based on molecular and Clinicopathologic studies. *Front Immunol*. 2017;8:1980.
14. Weenig RH, Davis MDP, Dahl PR, Su WPD. Skin ulcers misdiagnosed as pyoderma gangrenosum. *N Engl J Med*. 2002;347:1412-1418.
15. Maverakis E, Le ST, Callen J, et al. New validated diagnostic criteria for pyoderma gangrenosum. *J am Acad Dermatol*. 2019;80(4):e87-e88.
16. Su WP, Davis MD, Weenig RH, Powell FC, Perry HO. Pyoderma gangrenosum: clinicopathologic correlation and proposed diagnostic criteria. *Int J Dermatol*. 2004;43:790-800.
17. Sharon V, Burrall B, Patel F, et al. Multimodal therapy of idiopathic pyoderma gangrenosum. *Dermatol Online J*. 2014;20:6.
18. Patel F, Fitzmaurice S, Duong C, et al. Effective strategies for the management of pyoderma gangrenosum: a comprehensive review. *Acta Derm Venereol*. 2015;95:525-531.
19. Hirschmann JV, Raugi GJ. Adult scurvy. *J am Acad Dermatol*. 1999;41:895-906. quiz 7-10.

How to cite this article: Le ST, Wang JZ, Alexanian CC, et al. End stage scurvy in the developed world: A diagnostic conundrum but not to be mistaken for pyoderma gangrenosum. *Int Wound J*. 2019;16:1024–1028. https://doi.org/10.1111/iwj.13149