Since January 2020 Elsevier has created a COVID-19 resource centre with free information in English and Mandarin on the novel coronavirus COVID-19. The COVID-19 resource centre is hosted on Elsevier Connect, the company's public news and information website.

Elsevier hereby grants permission to make all its COVID-19-related research that is available on the COVID-19 resource centre - including this research content - immediately available in PubMed Central and other publicly funded repositories, such as the WHO COVID database with rights for unrestricted research re-use and analyses in any form or by any means with acknowledgement of the original source. These permissions are granted for free by Elsevier for as long as the COVID-19 resource centre remains active.

International Journal of Pediatric Otorhinolaryngology 144 (2021) 110667

Contents lists available at ScienceDirect

International Journal of Pediatric Otorhinolaryngology

journal homepage: www.elsevier.com/locate/ijporl

Case Report

Multisystem inflammatory syndrome in children (MIS-C) and retropharyngeal edema: A case series

Ariel Daube [a,*], Scott Rickert [b], Rebecca Pellett Madan [c], Philip Kahn [d], Joanne Rispoli [e], Heda Dapul [a]

[a] Division of Pediatric Critical Care, New York University Grossman School of Medicine, 424 East 34th Street, New York, NY, 10016, United States
[b] Department of Otolaryngology-Head and Neck Surgery, New York University Grossman School of Medicine, 424 East 34th Street, New York, NY, 10016, United States
[c] Division of Pediatric Infectious Diseases, New York University Grossman School of Medicine, 424 East 34th Street, New York, NY, 10016, United States
[d] Division of Pediatric Rheumatology, New York University Grossman School of Medicine, 424 East 34th Street, New York, NY, 10016, United States
[e] Department of Radiology, New York University Grossman School of Medicine, 424 East 34th Street, New York, NY, 10016, United States

ARTICLE INFO

Keywords:
MIS-C
COVID-19
SARS-CoV-2
Retropharyngeal edema

ABSTRACT

Multisystem inflammatory syndrome in children (MIS-C) is thought to follow SARS-CoV-2 infection and presents with fever and multisystem dysfunction. We report three children with suspected MIS-C found to have retropharyngeal edema without evidence of a bacterial etiology. We raise the possibility that an association between MIS-C and retropharyngeal edema exists.

1. Introduction

Multisystem inflammatory syndrome in children (MIS-C), a newly described phenomenon in the pediatric literature, is suspected to occur following infection with SARS-CoV-2 [1]. The Center for Disease Control (CDC) criteria for MIS-C include the presence of fever, multisystem organ involvement not explained by a plausible alternate diagnosis, and evidence of or suspicion for current or prior SARS-CoV-2 infection [2,3].

During the peak of MIS-C in our region (May 2020 in New York City) [4],we cared for three patients with suspected MIS-C who were also found to have retropharyngeal edema on neck imaging. We present these three patients to raise the possibility that retropharyngeal edema is associated with MIS-C.

This case series was considered by the IRB as exempt, as the patients reported herein were seen in the context of the standard of care, and no generalizable conclusions are made from their presentation. History, physical findings and hospital course were extracted from provider notes in the chart. Laboratory, imaging and vital sign data were systematically reviewed for each patient from admission to discharge and were selected for inclusion based on relevancy.

1.1. Case 1

A 12-year-old boy with a recent history of mild blunt trauma to the neck presented to the pediatric emergency department (ED) with four days of fever followed by acute onset of rapidly progressive, painful right neck swelling, trismus and voice change. He had also reported loss of taste and smell just prior to onset of fever. At least one household contact was suspected of having COVID-19 approximately one month prior to this patient's presentation.

Physical examination revealed bilateral, non-purulent conjunctival injection; dry, cracked lips; erythematous, macular rash over the chest and abdomen; right-sided neck tenderness with swelling; and enlarged right submandibular lymph nodes, and overlying erythema. The triage temperature was 39.5 °C, heart rate 157, blood pressure 119/82, respiratory rate 26, and oxygen saturation 98% on room air.

Initial laboratory testing revealed positive nasopharyngeal PCR for SARS-CoV-2 (Cepheid Xpert™ Xpress real time PCR, run under FDA emergency use authorization [EUA]) and elevated inflammatory and cardiac biomarkers (Table 1). Of note, SARS-CoV-2 plasma IgG antibody (Abbott chemiluminescent microparticle assay, used under FDA EUA) was found to be positive on hospital day 6 (on approximately day 10 of

Abbreviations: MIS-C, Multisystem Inflammatory Syndrome in Children; SARS-CoV-2, Severe Acute Respiratory Syndrome Coronavirus 2; ED, Emergency Department.

* Corresponding author. 424 East 34th Street, New York, NY, 10016, United States.
E-mail addresses: ariel.daube@nyulangone.org (A. Daube), scott.rickert@nyulangone.org (S. Rickert), rebecca.pellettmadan@nyulangone.org (R.P. Madan), philip.kahn@nyulangone.org (P. Kahn), joanne.rispoli@nyulangone.org (J. Rispoli), hedamarie.dapul@nyulangone.org (H. Dapul).

https://doi.org/10.1016/j.ijporl.2021.110667
Received 10 December 2020; Received in revised form 9 February 2021; Accepted 28 February 2021
Available online 4 March 2021
0165-5876/© 2021 Elsevier B.V. All rights reserved.

Table 1
Selected laboratory data from the three patients in this series with associated reference ranges in parentheses.

	Case 1	Case 2	Case 3
SARS-Co-V-2 PCR nasal swab	positive	negative	positive
SARS-Co-V-2 serum IgG	positive	positive	positive
White blood cell count, Highest x10^3/mcL	32.5 (3.8–9.8)	15.7 (6.0–10.5)	24.1 (4.2–9.4)
Absolute Neutrophil Count, Highest x10^3/mcL	31.9 (1.5–7)	9.88 (2.5–6.0)	19.2 (1.8–7.5)
Absolute Lymphocyte count, Lowest x10^3/mcL	0.0 (1.0–3.3)	0.03 (1.3–3.5)	1.1 (1.2–3.3)
C-reactive protein, Highest mg/L	421 (<5)	182 (0–3)	306 (<5)
Erythrocyte sedimentation rate, Highest mm/hr	120 (<10)	120 (<10)	120 (<20)
Procalcitonin, Highest ng/dL	61.6 (<0.05)	21.8 (0.02–0.1)	5.7 (<0.05)
D-dimer, Highest ng/mL DDU	1741 (<230)	6332 (<230)	2035 (<230)
Fibrinogen, Highest ng/mL	843 (150–450)	–	786 (150–450)
Lactate dehydrogenase, Highest	355 (125–220)	324 (110–225)	415 (125–220)
Interleukin-6, Highest pg/mL	176 (<=5)	–	–
Sodium, Lowest mmol/L	130 (136–145)	130 (137–147)	135 (136–145)
Creatinine, Highest mg/dL	1.2 (0.7–1.3)	0.8 (0.1–1.4)	2.04 (0.6–1.1)
AST, Highest U/L	55 (5–34)	40 (11–39)	120 (5–34)
ALT, Highest U/L	36 (<50)	25 (11–35)	72 (0–37)
Albumin, Lowest g/dL	2.3 (3.5–5.2)	2.6 (3.7–5.1)	2.5 (3.5–5.2)
Triglycerides, Highest mg/dL	132 (0–149)	281 (<150)	–
Ferritin, Highest ng/mL	763 (22–248)	534 (22–322)	2849 (5–204)
Troponin I, Highest ng/mL	0.11 (<0.04)	0.49 (<0.06)	0.43 (<0.04)
B-type Natriuretic peptide, Highest pg/mL	1904 (<100)	>5000 (1–125)	63 (<100)
Anti-streptolysin O titer IU/mL	–	220 (0–199)	–
Serum Anti-Dnase B	–	negative	–
Rapid Group A Strep Antigen	–	negative	negative
Pharyngeal group A Strep PCR	–	negative	negative
Blood culture(s)	no growth	no growth	no growth
Throat Culture	–	–	no growth
Retropharyngeal culture	rare Streptococcus parasanguinis	–	–

illness). Repeat nasopharyngeal PCR testing for SARS-CoV-2 was non-detectable on hospital day 13. Pain precluded the patient from opening his mouth to undergo posterior oropharyngeal culture or rapid antigen testing for group A *Streptococcus*.

The admission chest x-ray (CXR) revealed bilateral perihilar opacities consistent with a viral process. CT of the neck with IV contrast was remarkable for a retropharyngeal fluid collection extending from the level of C2-C5 without peripheral enhancement, suggestive of retropharyngeal edema. CT also revealed markedly enlarged right cervical chain lymph nodes and adjacent subcutaneous soft tissue edema suggestive of cellulitis (Fig. 1a).

The patient was admitted to the hospital and started on intravenous vancomycin and ampicillin-sulbactam. On hospital day 2, he underwent surgical neck exploration. Significant retropharyngeal edema was seen but without a discrete collection amenable to drainage. Culture of the edematous tissue later grew *Streptococcus parasanguinis*.

The patient was extubated post-operatively; however, he was reintubated later on hospital day 2 for hypoxemic respiratory failure. A post-intubation CXR revealed bilateral pleural effusions, which resolved with diuresis. During the course of invasive mechanical ventilation, the blood pressure was supported with a low-dose epinephrine drip. The patient was successfully extubated on hospital day 7.

Blood cultures obtained on hospital days 1, 3, 6, 7 and 9 remained negative, and tracheal aspirate culture did not yield bacteria. A nasopharyngeal swab to assess for methicillin-susceptible and methicillin-resistant *Staphylococcus aureus* (*S. aureus*) colonization was also negative.

Due to concern for an atypical Kawasaki-like syndrome, intravenous immune globulin 2 g/kg was given on hospital day 3, and the interleukin (IL)-1 receptor antagonist anakinra 6.7 mg/kg/day was started on hospital day 6. Given that acute COVID-19 infection could not be ruled out, the patient was treated with a five-day course of remdesivir over hospital days 6–10. The patient's clinical status and inflammatory markers slowly improved; he was discharged home on hospital day 26.

1.2. Case 2

A 4-year-old boy presented to the pediatric ED with three days of fever, sore throat, abdominal pain, decreased appetite, conjunctivitis, rash and vomiting. He was evaluated in an ambulatory urgent care center on the second day of illness and was found to have negative group A *Streptococcus* antigen testing from the posterior oropharynx. In the ED, he was noted to have swollen and erythematous tonsils bilaterally without exudate, a full-body maculopapular rash, and multiple ring-shaped erythematous lesions over his lower extremities. Admission vital signs were a temperature of 98.1, pulse 118, blood pressure 98/46, respiratory rate 20, and oxygen saturation 99% on room air.

SARS-CoV-2 nasopharyngeal swab PCR was non-detectable (Cepheid Xpert™ Xpress real time PCR), and SARS-CoV-2 IgG antibody from plasma was positive (Abbott chemiluminescent microparticle assay). Admission laboratory evaluation was also significant for elevated cardiac biomarkers and elevated inflammatory markers (Table 1). He was admitted to the hospital with fluid-responsive shock in the setting of suspected MIS-C. He initially received empiric ceftriaxone pending blood cultures.

On hospital day 2, he developed stridor and was intubated for airway protection. Neck CT with IV contrast showed inflammation of the pharyngeal mucosa and retropharyngeal fluid without enhancement suggestive of retropharyngeal edema measuring up to 6 mm (Fig. 1b). The antibiotic regimen was changed to intravenous linezolid and ampicillin-sulbactam. Blood cultures sent on hospital days 1, 6 and 7 remained negative. A skin biopsy of an erythematous annular lesion on his lower leg showed a non-specific sparse lymphocytic infiltrate with rare neutrophils consistent with a possible viral exanthem or early urticaria. Echocardiograms on hospital days 6 and 8 showed mild left ventricular dilation but normal systolic function and coronary arteries. A repeat echocardiogram on hospital day 10 was normal without evidence of left ventricular dilation. The patient received intravenous immunoglobulins 2 g/kg, and was started on aspirin 3.6 mg/kg/day, methylprednisolone 30mg/kg/day for three days, followed by a prednisolone taper. The patient steadily improved, was extubated on day 9,

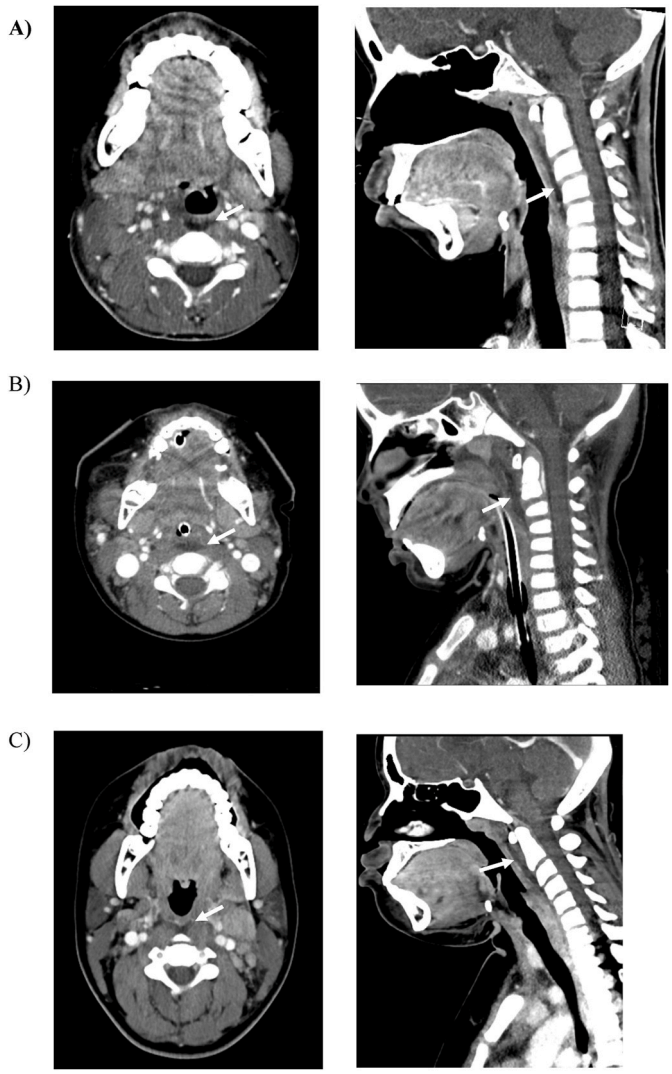

Fig. 1. Contrast-enhanced axial and saggital CT neck images depicting the retropharyngeal edema (white arrow) for the patients in **A.** Case 1, **B.** Case 2, and **C.** Case 3.

and was discharged to home on hospital day 16 on amoxicillin-clavulanate, prednisolone and aspirin.

1.3. Case 3

A 13-year-old obese female presented to the pediatric ED with a five-day history of fever, sore throat, neck pain, vomiting, and diarrhea. Amoxicillin was prescribed by her pediatrician after a telemedicine visit on day 2 of illness but provided no relief. Multiple household contacts were confirmed to have COVID-19 approximately 6 weeks prior to this patient's presentation. Physical examination revealed multiple tender, swollen, left anterior cervical lymph nodes, cracked lips, and posterior oropharyngeal erythema. The temperature was 39.6 °C, heart rate 130, blood pressure 135/64, respiratory rate 20, and oxygen saturation 100% on room air.

Neck CT with IV contrast indicated retropharyngeal fluid collection measuring 0.7 x 2.9 × 7.8cm and extending from the nasopharynx to the level of C4 with associated inflammation of the pharyngeal soft tissues (Fig. 1c). Bilateral enlarged cervical lymph nodes were also noted. SARS-Co-V 2 PCR (Cepheid Xpert™ Xpress real time PCR) from nasopharyngeal swab was positive, as was SARS-CoV-2 plasma IgG antibody (Abbott chemiluminescent microparticle assay). Additional admission laboratory evaluation (Table 1) showed elevated inflammatory markers, negative throat culture for beta-hemolytic streptococci, negative blood cultures, and negative nasopharyngeal PCR swab for both methicillin-susceptible and methicillin-resistant *S. aureus* colonization. Echocardiogram at the time of admission showed a mildly dilated left main coronary artery (Z-score 2.32) and evidence of mild carditis. The patient also developed transient acute kidney injury with a peak creatinine of 2.04 on hospital day 3.

The patient received IVIG 2g/kg and methylprednisolone 60 mg daily for possible MIS-C. As the etiology of the retropharyngeal fluid collection was unclear, she was initially started on pipercillin-tazobactam and vancomycin, which was transitioned to linezolid in the setting of her acute kidney injury. She did not receive remdesivir, as she did not have significant lung disease and improved quickly on steroids and antibiotics. She was discharged home on hospital day 8 on prednisone, aspirin and amoxicillin-clavulanate. An outpatient echo performed roughly two months later revealed resolution of the coronary artery dilation.

2. Discussion

The three patients presented in this case series were found to have retropharyngeal edema in the setting of presumed MIS-C. Retropharyngeal edema is thought to be due to altered lymphatics and can be identified as a finding in several clinical scenarios including inflammatory conditions such as calcific tendonitis and jugular vein thrombosis, or secondary to adjacent neck infections [5]. The imaging findings on the patients presented here were relatively similar, showing retropharyngeal fluid without peripheral enhancement characteristic of a purulent bacterial infection or abscess.

While no clear evidence of bacterial infection was identified in any of the patients, all three received broad spectrum antibiotics with anaerobic coverage empirically, and both Case 2 and 3 received antibiotics prior to hospital admission. Only Case 1 underwent surgical intervention; although surgery was performed after administration of antibiotics, no discrete abscess was found for drainage, and the clinical relevance was unclear for the *Streptococcus parasanguinis* obtained from soft tissue culture.

Although retropharyngeal abscesses are more typically associated with oropharyngeal bacteria such as group A *Streptococcus* and *S. aureus*, several aspects of these cases and local epidemiology at the time of presentation raised concern for MIS-C. These cases underscore the challenges of distinguishing MIS-C from other overlapping syndromes following periods of extensive COVID-19 community transmission. Case 1 in particular also highlights the difficulty of distinguishing MIS-C from acute COVID-19 illness, as this patient had clinical features of MIS-C but also had lung disease with loss of taste and smell.

It has been suggested that MIS-C shares features with Kawasaki Disease [1,4,6–8], and retropharyngeal edema has been described in the latter [9–12]. Compared with the CT findings described in Kawasaki patients [13], the three cases presented here are similar in appearance and presented with findings of retropharyngeal low density without peripheral enhancement. That said, the apparent similarity between MIS-C and Kawasaki may stem from having two inflammatory conditions with relatively broad definitions, and comparison between the two is controversial [14].

3. Conclusion

Despite the limitations of this case series, these cases do suggest a possible association between MIS-C and retropharyngeal edema. Confirmation of this association in additional studies could influence antibiotic and surgical management of retropharyngeal edema found in patients with MIS-C. Inversely, knowledge of such an association might alert clinicians to the possibility of MIS-C when retropharyngeal edema is discovered. Further mechanistic and epidemiologic studies are needed

to evaluate this question.

Funding

This research did not receive any specific grant from funding agencies in the public, commercial, or not-for-profit sectors. The authors have no conflicts of interest to disclose.

This case series has been accepted as an abstract in the Society of Critical Care Medicine 2021 Annual Congress.

References

[1] N.A. Nakra, D.A. Blumberg, A. Herrera-Guerra, S. Lakshminrusimha, Multi-system inflammatory syndrome in children (MIS-C) following SARS-CoV-2 infection: review of clinical presentation, hypothetical pathogenesis, and proposed management, Children 7 (7) (2020).

[2] Centers for Disease Control and Prevention, Emergency preparedness and response: multisystem inflammatory syndrome in children (MIS-C) associated with coronavirus disease 2019 (COVID-19), Health Advisory (2020). https://emergency.cdc.gov/han/2020/han00432.asp.

[3] S. Godfred-Cato, B. Bryant, J. Leung, et al., COVID-19-Associated multisystem inflammatory syndrome in children - United States, march-july 2020, MMWR Morb. Mortal. Wkly. Rep. 69 (32) (2020) 1074–1080.

[4] E.M. Dufort, E.H. Koumans, E.J. Chow, et al., Multisystem inflammatory syndrome in children in New York state, N. Engl. J. Med. (2020).

[5] J.K. Hoang, B.F. Branstetter, J.D. Eastwood, et al., Multiplanar CT and MRI of collections in the retropharyngeal space: is it an abscess? AJR Am. J. Roentgenol. 196 (4) (2011) W426–W432.

[6] R. Ebina-Shibuya, H. Namkoong, Y. Shibuya, N. Horita, Multisystem inflammatory syndrome in children (MIS-C) with COVID-19: insights from simultaneous familial Kawasaki disease cases, Int. J. Infect. Dis. 97 (2020) 371–373.

[7] L.R. Feldstein, E.B. Rose, S.M. Horwitz, et al., Multisystem inflammatory syndrome in U.S. Children and adolescents, N. Engl. J. Med. (2020).

[8] M. Riollano-Cruz, E. Akkoyun, E. Briceno-Brito, et al., Multisystem inflammatory syndrome in children (MIS-C) related to COVID-19: a New York City experience, J. Med. Virol. (2020).

[9] D.C.Y. Au, N. Chung Fong, Y. Wah Kwan, Kawasaki disease with retropharyngeal edema: case series from a single center experience, Chin Med J (Engl). 132 (14) (2019) 1753–1754.

[10] K. Inagaki, C. Blackshear, C.V. Hobbs, Deep neck space involvement of Kawasaki disease in the US: a population-based study, J. Pediatr. 215 (2019) 118–122.

[11] O. Nomura, N. Hashimoto, A. Ishiguro, et al., Comparison of patients with Kawasaki disease with retropharyngeal edema and patients with retropharyngeal abscess, Eur. J. Pediatr. 173 (3) (2014) 381–386.

[12] L. Puhakka, R. Saat, T. Klockars, L. Kajosaari, E. Salo, T. Nieminen, Retropharyngeal involvement in Kawasaki disease–a report of four patients with retropharyngeal edema verified by magnetic resonance imaging, Int. J. Pediatr. Otorhinolaryngol. 78 (10) (2014) 1774–1778.

[13] K. Roh, S.W. Lee, J. Yoo, CT analysis of retropharyngeal abnormality in Kawasaki disease, Korean J. Radiol. 12 (6) (2011) 700–707.

[14] A.H. Rowley, Understanding SARS-CoV-2-related multisystem inflammatory syndrome in children, Nat. Rev. Immunol. 20 (8) (2020) 453–454.