Case Report Rapport de cas

Iridociliary adenoma in a greater sulfur-crested cockatoo *(Cacatua galerita galerita)*

Sara Gardhouse, Chantale L. Pinard, Trinita Barboza, Britta Knight, Omar A. Zaheer, Leonardo Susta, Hugues Beaufrère

Abstract — A 34-year-old female greater sulfur-crested cockatoo *(Cacatua galerita galerita)* was referred for suspected left globe rupture. Ophthalmic examination revealed effacement of the anterior chamber and cornea by a large mass. The left eye was enucleated due to suspicion of globe rupture, secondary to a neoplastic process or chronic trauma. Histopathological examination revealed complete effacement of the internal ocular structures by a neoplasm morphologically consistent with an iridociliary adenoma. The diagnosis was confirmed by Periodic acid-Schiff histochemistry and immunohistochemistry for S100, Melan-A/PNL2, and vimentin antigens. The cockatoo recovered well from surgery, with appropriate healing of the enucleation site, and no evidence of recurrence at 1-year follow-up.

Key clinical message:
To the authors' knowledge, this is the first report of iridociliary adenoma in a greater sulfur-crested cockatoo, and the third report of such a neoplasm in a psittacine species with a description of the use of immunohistochemistry to confirm a diagnosis of a rare tumor in a bird species.

Résumé — Adénome iridociliaire chez un cacatoès à crête de soufre *(Cacatua galerita galerita)*. Une femelle cacatoès à crête de soufre *(Cacatua galerita galerita)* âgée de 34 ans a été référée pour suspicion de rupture du globe oculaire gauche. L'examen ophtalmique a révélé un effacement de la chambre antérieure et de la cornée par une masse importante. L'œil gauche fut énucléé en raison d'une suspicion de rupture du globe oculaire, secondaire à un processus néoplasique ou à un traumatisme chronique. L'examen histopathologique a révélé un effacement complet des structures oculaires internes par un néoplasme morphologiquement compatible avec un adénome iridociliaire. Le diagnostic a été confirmé par histochimie avec coloration PAS (Periodic acid-Schiff) et immunohistochimie pour les antigènes S100, Melan-A/PNL2 et vimentine. Le cacatoès s'est bien rétabli de la chirurgie, avec une guérison appropriée du site d'énucléation, et aucun signe de récidive à 1 an de suivi.

Message clinique clé :
À la connaissance des auteurs, il s'agit du premier rapport d'adénome iridociliaire chez un grand cacatoès à crête de soufre et du troisième rapport d'un tel néoplasme chez une espèce psittacidé avec une description de l'utilisation de l'immunohistochimie pour confirmer le diagnostic d'une tumeur rare chez une espèce d'oiseau.

(Traduit par Dr Serge Messier)

Can Vet J 2021;62:226–232

Ophthalmic lesions are commonly diagnosed in avian species; however, there is a paucity of reports of ocular neoplasia (1–3). Marek's disease of chickens is the most common cause of intraocular neoplasia in birds, resulting in herpesvirus-induced ocular lymphomas (4). In contrast, primary intraocular tumors in dogs and cats have been extensively studied and have distinct immunohistochemical features reported (5), whereas only 2 reported cases of such avian tumors were retrieved from the literature, with limited confirmation of immunohistochemistry findings (1,6). These epithelial tumors arise from the iris and ciliary bodies, and malignancy (i.e., adenomas and adenocarcinomas) must be determined based on tumor behavior, including local invasion and recurrence or distant metastases (5).

The objective of this article was to report an iridociliary adenoma in a greater sulfur-crested cockatoo, without concurrent evidence of systemic involvement. To the best of the

Health Sciences Centre (Gardhouse, Zaheer), Department of Clinical Sciences (Pinard, Barboza, Beaufrère), Department of Pathobiology (Knight, Susta), Ontario Veterinary College, University of Guelph, Guelph, Ontario N1G 2W1.

Address all correspondence to Dr. Sara Gardhouse; e-mail: sgardhous@vet.k-state.edu

Dr. Gardhouse's current address is Assistant Professor, Exotic Pet, Wildlife, and Zoological Medicine, Department of Clinical Sciences, College of Veterinary Medicine, Kansas State University, Manhattan, Kansas, USA.

Use of this article is limited to a single copy for personal study. Anyone interested in obtaining reprints should contact the CVMA office (hbroughton@cvma-acmv.org) for additional copies or permission to use this material elsewhere.

Figure 1. Photograph of the left eye of a 34-year-old female greater sulfur-crested cockatoo *(Cacatua galerita galerita)* demonstrating outstretched eyelids separated by blood-tinged, brown-black tissue, fresh blood on the eyelids, and absence of normal ocular structures.

authors' knowledge, this report expands the body of literature on a rare tumor type in psittacines and provides an extensive description of the immunohistochemical staining properties used for confirmation.

Case description

A 34-year-old female greater sulfur-crested cockatoo *(Cacatua galerita galerita)* was presented on referral to the Ontario Veterinary College, Health Sciences Centre, for an examination of the left eye. Ten years before presentation, a cloudy white spot was noted in the left eye, but no veterinary care was pursued. Four years later, the left eye became swollen and hemorrhage was noted; at that time, a ruptured globe was diagnosed by the referring veterinarian. The owner elected to have treatment with occasional antibiotic drops (Tobrex, Tobramycin Ophthalmic Solution 0.3%; Novartis Pharmaceuticals Canada, Dorval, Quebec). Ten years following the initial signs, increased discomfort and scratching associated with the left eye were noted. Three weeks before presentation, scratching, recurrent hemorrhage of increasing frequency, and changes in the appearance of the globe were noted. An Elizabethan collar was not tolerated by the bird and referral was pursued.

A physical and ophthalmic examination on presentation to the referral center reported the bird as bright, alert, and responsive, but with a thin body condition (score 1.5/5) and significant feather destructive behavior. Aside from the ocular abnormalities, no other significant abnormalities were detected on examination.

On neuro-ophthalmic examination, the dazzle reflex, palpebral reflex, and direct pupillary light reflex were positive in the right eye, and there was a questionable menace response. The left eye could not be evaluated for reflexes due to effacement of the anterior chamber and cornea by a large mass. The right eye had blood-stained upper eyelids, a faint capsular paracentral cataract, nuclear sclerosis, and a normal fundus. The left eye had outstretched eyelids, fresh blood on the eyelids, and blood-tinged, brown-black tissue protruding from the orbit between the eyelids. No normal ocular structures could be identified

Figure 2. Computed tomography image of the left eye of 34-year-old greater sulfur-crested cockatoo *(Cacatua galerita galerita)* demonstrating proliferative tissues at the lateral aspect of the left globe (arrows), and mineralization of the left globe (arrowheads), with suspected rupture.

(Figure 1). A Schirmer tear test, fluorescein stain uptake, and intraocular pressure were not performed on the right eye, due to the temperament of the patient. Based on the appearance of the left eye, differential diagnoses of an ocular tumor with secondary globe rupture or a chronically ruptured globe secondary to ocular trauma were suspected.

Following examination, a complete blood cell count and biochemistry profile revealed a mild regenerative anemia [hematocrit 34%; reference interval for *Cacatua* spp.: 39.7 +/− 9, (6)] but no other abnormalities. A whole body computed tomography (CT) scan was performed under general anesthesia and abnormalities were limited to the left eye. The study revealed proliferative soft tissues in the lateral aspect of the globe, a mineralized globe, as well as a suspicion of globe rupture (Figure 2). Differential diagnoses for the proliferative soft tissues included neoplasia, especially melanocytic tumors due to the dark brown appearance of the mass, and iridociliary epithelial tumors, abscessation, chronically inflamed tissue, or granulation tissue secondary to chronic ocular trauma. Differential diagnoses for the mineralization of the globe of the left eye included dystrophic mineralization, a cataract, collapsed scleral ossicles, or inspissated purulent debris.

The left eye was enucleated. The bird was sedated with midazolam (Midazolam injection USP; Pfizer Canada, Kirkland, Quebec), 0.4 mg/kg body weight (BW), IM, and butorphanol (Torbugesic; Zoetis, Kalamazoo, Michigan, USA), 0.4 mg/kg BW, IM, followed by mask induction with isoflurane (IsoFlo; Abbott Laboratories, North Chicago, Illinois, USA). A 3.0 uncuffed endotracheal tube was used for intubation and the bird was placed

on a butorphanol constant rate infusion of 1 mg/kg BW per hour, and intravenous fluids (Plasma-lyte A; Baxter Healthcare, Deerfield, Illinois, USA) were given at a rate 10 mL/kg BW per hour.

The bird was placed in dorsal recumbency with the head and neck in right lateral recumbency. Feathers in the left periocular area were manually plucked and the area was prepared with a 1:50 dilution of betadine solution. An Ocudrape (Storz Ophthalmics, St. Louis, Missouri, USA) was placed overlying the surgical site. An operating microscope (Moller-Hi R Operating Microscope; Moller-Wedel A Haag-Streit Company, Rosengarten, Wedel, Germany) was used to magnify the surgical site. A medial and lateral canthotomy was performed using tenotomy scissors to expose the globe. A large pigmented vascularized mass was visualized occupying the left orbit. No remnants of the cornea were observed. Starting at the lateral canthotomy site, a 360° subconjunctival dissection was performed to undermine the conjunctiva from the eyelids using colibri forceps and tenotomy scissors; the latter were used in a sharp and blunt dissection fashion to sever attachments of the globe to the orbit. Cotton swabs were also used in a blunt fashion to tear away attachments. On the ventral aspect of the sclera, a large vascular supply was observed and 3 small titanium hemoclips (Hemoclip Traditional Ligating Clips; Teleflex, Morrisville, North Carolina, USA) were placed on this pedicle before transection. The lateral and ventral attachments to the sclera were not clearly visualized and transection to remove the globe from the orbit, along with the third eyelid, and Harderian gland, lead to hemorrhage which was controlled with manual pressure, electrocautery, suction, and placement of absorbable gelatin sponge (Gelfoam; Pfizer Canada). Upon examination of the removed grossly distorted left eye, the conjunctiva appeared attached to the sclera and large blood vessels were observed. The dorsal lacrimal gland was incorporated on the exterior of the mass as well as the third eyelid. A 2-mm margin of the ventral and dorsal eyelid was removed using tenotomy scissors.

The surgical site was sutured closed using 9-0 PDS (Polydioxanone; Ethicon, Somerville, New Jersey, USA). The subcutaneous tissue was closed in a simple continuous pattern and the skin was closed in a Ford interlocking pattern using the same suture material. Due to the volume of blood loss (~8 to 10 mL), a 10 mL/kg BW, IV bolus of Plasmalyte-A Injection (PLA; Baxter, Mississauga, Ontario) was administered, followed by two 5 mL/kg BW boluses of 6% hydroxyethyl starch in 0.9% sodium chloride (Voluven; Fresenius Kabi Canada, Richmond Hill, Ontario) to counteract suspected hypovolemia. A 0.1 mg/kg BW dose of ephedrine (Ephedrine sulfate inj; Sandoz, Princeton, New Jersey, USA) was also administered intravenously to counteract hypotension. The bird had an uneventful recovery from anesthesia and surgery. The globe was fixed intact in 10% neutral-buffered formalin and submitted for histological examination.

Immediate postoperative care included meloxicam (meloxicam injection; Putney, Portland, Maine, USA), 1 mg/kg BW, IM, butorphanol (Zoetis), 2 mg/kg BW, IM, with transition to tramadol (compounded product, Ontario Veterinary College, Guelph, Ontario), 10 mg/kg BW, PO, q12h, for overnight administration. While in hospital, the bird also received PLA (Baxter), 25 mL/kg BW, SC, q12h, enrofloxacin (compounded product, Ontario Veterinary College), 15 mg/kg BW, PO, q12h, and gavage feeding based on body weight and caloric need (Tropican Hand-Feeding Formula; Rolf C. Hagen, Baie d'Urfé, Quebec). Twelve hours after surgery, the packed cell volume (PCV) and total protein (TP) were 15% and 30 g/L, respectively. The bird remained bright, alert, and responsive, and it was decided to monitor the PCV instead of proceeding with a blood transfusion, since the source of ongoing hemorrhage had resolved.

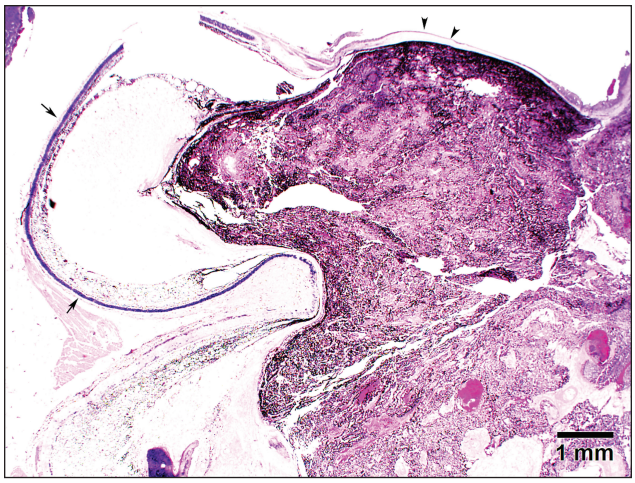

Figure 3. Sub-gross histologic image of the enucleated left eye from a 34-year-old greater sulfur-crested cockatoo *(Cacatua galerita galerita)* demonstrating complete effacement and replacement of the internal ocular structures by an expansile and poorly delimitated neoplasm extruding from the globe, without evidence of infiltration of sclera or cornea, or invasion of extraocular tissue. The cornea is demarcated by the arrowheads, and the arrows demarcate the lateral aspect of the eye (scleral cartilage).

The bird was discharged 24 h after surgery for further monitoring and hand feeding at home to reduce stress associated with hospitalization. The bird was discharged with enrofloxacin (compounded at Ontario Veterinary College), 15 mg/kg BW, PO, q12h for 30 d, meloxicam (Metacam; Boehringer Ingelheim Vetmedica, St. Joseph, Missouri, USA), 1 mg/kg BW, PO, q12h for 7 d, and tramadol (compounded at Ontario Veterinary College), 10 mg/kg BW, PO, q12h for 7 d.

Grossly, the enucleated eye appeared as a dark brown to black, soft, spheroid piece of tissue, with no internal ocular structures discernible on cross section. Histologically, the internal ocular structures were effaced and replaced by an expansile, non-infiltrative, and poorly delineated neoplasm that appeared confined within the globe, without evidence of infiltration of sclera or cornea, or invasion of extraocular tissue (Figure 3). The neoplasm was composed of variably pigmented cuboidal to polygonal cells arranged into single or double rows against the basal lamina, and forming papillary fronds, nests, and packets supported by small amounts of stroma (Figure 4A). Segments of basal lamina throughout were multifocally thick and prominent. Neoplastic cells had distinct cell borders, and

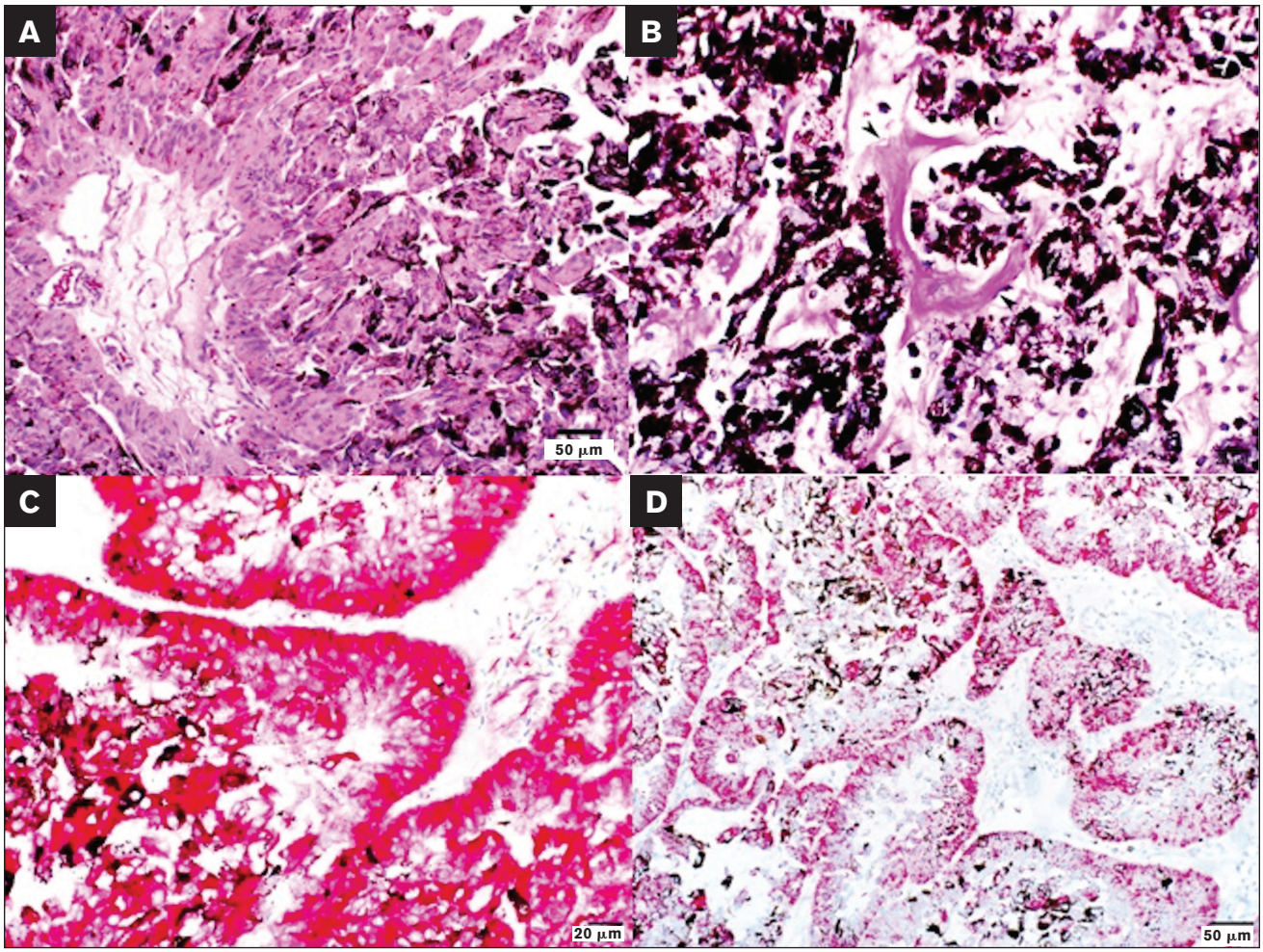

Figure 4. A – Microphotographs showing high magnification details of an intraocular mass from the enucleated left eye of a 34-year-old greater sulfur-crested cockatoo *(Cacatua galerita galerita).* The mass is composed of cuboidal to polygonal epithelial cells, arranged 1 to 2 rows deep, which are laid out to form papillary fronds supported by fine stroma. Cells have moderate amounts of intensely eosinophilic cytoplasm that contains finely granular dark brown to black pigment. Hematoxylin and eosin (H&E) staining; original magnification 20×. B – Nests and pockets of neoplastic cells are delimited by thick segments of basal lamina that stain intensely purple with PAS histochemical staining. Period acid-Shiff (PAS) staining; original magnification 40×. C – The neoplastic epithelium shows intense, diffuse, finely granular cytoplasmic signal (red). Immunochemistry for vimentin antigen, hematoxylin counterstain; original magnification 40×. D – The neoplastic epithelium shows multifocal, punctate cytoplasmic signal (red). Immunohistochemistry for melanA/PNL2, hematoxylin counterstain; original magnification 20×.

a moderate amount of eosinophilic cytoplasm, often containing finely granular, dark brown to black pigment (interpreted as melanin), and a single oval to elongated nucleus with finely stippled chromatin and a single nucleolus. There was 3-fold anisocytosis and anisokaryosis, with 3 mitotic figures per 10 high power (400×) fields.

Throughout the neoplasm, there were multifocal profiles of unraveled, hyalinized membranes (suspect Descemet's membrane or lens capsule), and multifocal lakes of eosinophilic proteinaceous fluid, fibrin, and hemorrhage. On the posterior aspect of the globe, between the mass and the sclera, there were multiple xanthogranulomas composed of epithelioid macrophages, often vacuolated, and giant cells admixed with abundant acicular cholesterol clefts. These areas were admixed with fibrosis and numerous melanophages. The corneal epithelium was diffusely ulcerated and in areas replaced by fibrin enmeshed with cellular debris and heterophils. The underlying corneal stroma was expanded by granulation tissue at various stages of maturation.

Main differential diagnoses included iridociliary tumor and uveal melanoma, as well as uveal melanocytoma or metastatic melanoma. A metastatic carcinoma of unknown origin was considered unlikely, due to the pigmentation of the mass, and lack of extraocular involvement. Periodic acid-Schiff (PAS) histochemical stain and immunohistochemical staining for vimentin (mouse monoclonal antibody; Dako, Agilent, Santa Clara, California, USA at 1:1200 dilution), melan-A (mouse monoclonal antibody; Novocastra, Newcastle upon Tyne, UK at 1:25 dilution) and PNL2 (mouse monoclonal antibody; Santa Cruz Biotechnology, Dallas, Texas, USA at 1:50 dilution), S100 (rabbit polyclonal antibody; Dako at 1:2000 dilution) antigens were undertaken to better identify the tumor (Figures 4B–D) (5).

Most neoplastic cells had intense, diffuse cytoplasmic immunoreactivity for vimentin, and approximately 20 to 40% had intense, punctate cytoplasmic immunoreactivity for melan-A/PNL2. No S100 expression was observed. Approximately

Figure 5. Photograph of the healing enucleation site of a 34-year-old female greater sulfur-crested cockatoo *(Cacatua galerita galerita)* 5 d after surgery.

10 to 20% of the neoplastic cells had thick profiles of basement membrane that reacted with PAS stain. Cross reactivity of the used commercial antibodies was verified using archived formalin-fixed, paraffin-embedded tissues from a congeneric bird submitted for postmortem examination to the Animal Health Laboratory, University of Guelph. The final histologic diagnosis was consistent with an iridociliary adenoma (benign iridociliary epithelial tumor) with phthisis bulbi, corneal rupture, and multifocal xanthogranulomas.

The bird was presented 5 d after discharge for a re-check of the surgical site and for determination of PCV and TP. The PCV was 30% and TP was 42 g/L. Given the marked improvement, no further intervention was deemed necessary. The surgical site was healing well with no discharge, erythema, or swelling (Figure 5). Antibiotics were continued for a total of 1 mo after surgery. Fourteen months after the initial presentation, the bird was maintaining a healthy body weight, with normal appetite and behavior.

Discussion

The gross and histopathologic changes and immunohistochemical reactivity in this bird were consistent with an iridociliary adenoma that completely effaced the intraocular structures. Although the tumor was heavily pigmented on histopathologic examination, a diagnosis of melanocytic neoplasia was considered less likely, due to the presence of a well-defined epithelial arrangement of cells with formation of papillary fronds. Further differentiation of an iridociliary epithelial tumor from a melanoma or melanocytoma was accomplished with a PAS stain that demonstrated a robust basement membrane, present in iridociliary epithelial tumors (7,8). In this case, several immunohistochemical stains were also used to rule out a possible melanocytic neoplasm (5). Expression of vimentin and S100 were consistent with the literature, as iridociliary tumors are reported to be most commonly reactive for vimentin and inconsistently reactive for S100 (5). In 1 canine study, only 10/20 iridociliary tumors expressed S100 (5). Moderate reactivity of this tumor with the melanoma cocktail was an unexpected finding, as both PNL-2 and melan-A are markers considered specific to melanocytes (9); however, melan-A reactivity has been described in the pigmented and non-pigmented iridociliary epithelium of dogs and humans (10). In this case, it was suspected that the PNL-2/melan-A reactivity was derived from the iridociliary epithelium, not melanocytes.

Iridociliary adenomas arise from the epithelium of the iris and ciliary body (5). They can be solid or papillary, invasive to noninvasive, and have varying degrees of pigmentation (5). These tumors occupy the posterior chamber and often displace the lens (7). In dogs, primary epithelial tumors of the iris and ciliary body possess 3 features: localized noninvasive growth into the posterior chamber, pigmented epithelium within the tumor, and thick, smooth basement membranes supporting the cells (5). If the tumor lacks ≥ 1 of these features, it must be distinguished from a metastatic carcinoma (5).

In dogs and cats, iridociliary adenocarcinoma is differentiated from adenoma based on histological features such as scleral invasion and cellular anaplasia (5). Adenomas are usually limited to the ciliary body, but adenocarcinomas invade into the sclera (5,11). Both tumors are reported to be slow growing with a low incidence of metastasis in dogs, with rare cases of distant metastasis (5,11). In the case of this cockatoo, although there was no gross evidence of scleral invasion, the tumor had effaced all intraocular structures, suspected to be a result of the chronicity of the tumor. There was no evidence of periocular tissue invasion or vascular metastases. Overall, the rupture of the tumor through the globe was likely a result of the long-standing nature of the adenoma, rather than the invasiveness of an adenocarcinoma. It has been reported that iridociliary tumors demonstrate variability in pigment content and mitotic figures, and the best measure of degree of malignancy is the degree of scleral invasiveness (12).

Overall, the prevalence of ocular neoplasia in birds appears to be low, reported at 5.2% in 1 retrospective study of ocular lesions (1,13). Reports of orbital, intraocular, and eyelid neoplasia in birds include benign and malignant, primary and metastatic tumors (1,2,14–17). Birds with ophthalmic tumors are typically presented with ocular clinical signs, such as exophthalmos (15,18), poor body condition (18), weakness, and dehydration, or no clinical signs (1). Avian ocular anatomy differs from that of mammals (15). Avian species have large eyes compared to head and brain size, and poor development of extraocular muscles, resulting in a globe that nearly completely fills the orbit (15,16). The presence of exophthalmos in the face of an intraorbital mass is common due to this anatomy (15,16).

With respect to avian intraocular tumors, there are 2 previous reports of iridociliary adenomas in psittacine species (1,19). The first report occurred in a male yellow-crested cockatoo *(Cacatua sulphurea)* of unknown age (1). The histologic findings reported in that case were similar to the histologic results in the current case, although an extensive description of diagnosis including immunohistochemistry and treatment was not provided (1). No evidence of metastasis was reported, similar to the present case (1). The second reported case occurred in a 19-year-old female Congo African grey parrot *(Psittacus erithacus)* that was presented with a suspected intraocular mass with no evidence

of metastasis or recurrence following enucleation (19). In that case, immunohistochemistry was only reported for vimentin and neuron-specific enolase (NSE), in contrast to the present case, in which tests for vimentin, melan-A/PNL2, and S100 were performed, in addition to PAS stain (19). Vimentin staining in the African grey parrot showed approximately 70% of neoplastic cells with strong staining compared to almost all neoplastic cells staining strongly positive in the cockatoo in this report (19). Although NSE immunohistochemistry was not performed in the current case, it has potential to lend further evidence to the diagnosis of iridociliary adenomas due to positive staining for optic nerve astrocytes (5,19).

Diagnosis of ocular tumors involves a systemic workup including blood analysis and imaging to diagnose the neoplasia, and evaluate for presence of metastasis (20). In humans, ocular ultrasound has been demonstrated to be a safe and rapid diagnostic procedure for screening ocular and extraocular lesions; however, it does not provide a complete picture of the patient (21,22). In this patient's case, a whole-body CT scan was elected over an ocular ultrasound, due to concerns for metastasis, and to serve as a screening tool for underlying disease before anesthesia and surgery due to the thin body condition. Definitive diagnosis and treatment of intraocular tumors involve either biopsy or enucleation and histopathology of the mass (20).

Previous reports of treatment of intraocular tumors include enucleation or exenteration, with varying results depending on the underlying disease. There are several concerns associated with ocular surgery in birds, including hemorrhage from the vascular plexus located in the ventrolateral region of the orbit (16), bradycardia due to traction on the extraocular muscles or compression of the globe (oculocardiac reflex) (23), blindness in the contralateral eye due to traction on the optic nerves and chiasm (24), or pressure trauma to the brain associated with excessive traction (25). The cause of hemorrhage in the present case was attributed to the highly vascularized mass and not disruption of the vascular plexus. Eviscerations are not as invasive as enucleations or exenterations and carry less risk (26). The decision to proceed with an enucleation in this case was made due to concerns for neoplasia and due to the altered anatomy (ruptured cornea and unrecognizable anterior chamber). Enucleation in birds is more challenging due to the unique ocular anatomy that creates a rigid globe tightly encased in the orbit, the presence of scleral ossicles and a posterior scleral cartilage that also increase the rigidity of the globe (26,27). Additionally, the posterior wall of the orbit is fragile and can be damaged during surgery and the interorbital septum is thin and may result in damage to the contralateral eye (28,29).

Evidence of metastasis at the time of enucleation was not reported in retrospective studies of iridociliary epithelial tumors in dogs, cats, and rabbits; however, some of these tumors had aggressive scleral invasion, a marker for malignancy (5,7). There was a lack of metastasis in our case and the previously reported case in an African grey parrot (19), despite the suspected prolonged growth pattern. Furthermore, in our case, the mass did not show scleral invasion. The literature supports that the metastasis of iridociliary adenocarcinomas is also rare, with only 3 confirmed cases of metastasis in the veterinary literature (11,30–32).

Despite the rarity of this tumor, it is important to recognize it as an important differential diagnosis in birds that are presented with intraocular disease. The behavior, location, histology, and immunohistochemical properties appeared to be similar to the findings in dogs. This tumor has a unique immunohistochemical staining pattern. To the best of our knowledge, this is the second detailed description of immunohistochemistry to aid in diagnosis of a rare tumor in a psittacine eye. CVJ

References

1. Rodriguez-Ramos Fernandez J, Dubielzig RR. Ocular and eyelid neoplasia in birds: 15 cases (1982–2011). Vet Ophthalmol 2015;18:113–118.
2. Hvenegaard AP, Safatle AMV, Guimarães MB, Ferreira AJP, Barros PSM. Retrospective study of ocular disorders in Amazon parrots. Pesqui Veterinária Bras 2009;29:979–984.
3. Turrel JM, McMillan MC, Paul-Murphy J. Diagnosis and treatment of tumors of companion birds II. AAV Today 2010;1:159.
4. Dukes TW, Pettit JR. Avian ocular neoplasia: A description of spontaneously occurring cases. Can J Comp Med 1983;47:33–36.
5. Dubielzig R, Steinberg H, Garvin H, Deehr A, Fischer B. Iridociliary epithelial tumors in 100 dogs and 17 cats: A morphological study. Vet Ophthalmol 2003;1:223–231.
6. Hawkins MG, Sanchez-Migallon Guzman D, Beaufrère H, Lennox AM, Carpenter JW. Birds. In: Carpenter JW, Marion CJ, eds. Exotic Animal Formulary. 5th ed. St. Louis, Missouri: Elsevier, 2018:167–375.
7. Swisher SD, Klein H, Lennox AM, Reavill DR, Teixeira LBC, Shaw GC. Four cases of iridociliary tumors in domestic rabbits *(Oryctolagus cuniculus).* Vet Ophthalmol 2018;21:646–651.
8. Dubielzig RR, Ketring K, McLellan GJ, Albert DM. The principles and practice of ocular pathology. In: Veterinary Ocular Pathology. St. Louis, Missouri: Elsevier, 2010:1–8.
9. Busam KJ, Kucukgöl D, Sato E, Frosina D, Teruya-Feldstein J, Jungbluth AA. Immunohistochemical analysis of novel monoclonal antibody PNL2 and comparison with other melanocyte differentiation markers. Am J Surg Pathol 2005;29:400–406.
10. Labelle P, Reilly CM, Naydan DK, Labelle AL. Immunohistochemical characteristics of normal canine eyes. Vet Pathol 2012;49:860–869.
11. Peiffer RL. Ciliary body epithelial tumours in the dog and cat: A report of thirteen cases. J Small Anim Pract 1983;24:347–370.
12. Beckwith-Cohen B, Dubielzig RR, Bentley E. Outcome of iridociliary epithelial tumour biopsies in dogs: A retrospective study. Vet Rec 2015; 176:147.
13. Gibson DJ, Nemeth NM, Beaufrère H, Varga C, Eagalle T, Susta L. Captive psittacine birds in Ontario, Canada: A 19-year retrospective study of the causes of morbidity and mortality. J Comp Pathol 2019; 171:38–52.
14. Kern TJ, Paul-Murphy J, Murphy CJ, et al. Disorders of the third eyelid in birds: 17 cases. J Avian Med Surgery 1996;10:12–18.
15. Woodhouse SJ, Rose M, Desjardins DR, Agnew DW. Diagnosis of retrobulbar round cell neoplasia in a Macaroni penguin *(Eudyptes chrysolophus)* through use of computed tomography. J Avian Med Surg 2015; 29:40–45.
16. Kern J. Disorders of the special senses. In: Altman R, Clubb S, Dorrestein G, Quesenberry K, eds. Avian Medicine and Surgery. Philadelphia, Pennsylvania: WB Saunders, 1989:563–589.
17. Cazzini P, Watson VE, Schnellbacher R, Sakamoto K, Divers SJ, Murdock JH. Retrobulbar adenocarcinoma in an Amazon parrot *(Amazona autumnalis).* J Vet Diagn Investig 2013;25:273–276.
18. Koma M, Fordham M, Rosenthal K, Durham A, Duda L. Intraocular osteosarcoma in an umbrella cockatoo *(Cacatua alba).* Vet Ophthalmol 2010;13:103–108.
19. Thielen LE, Sledge DG, Hess L. Ocular iridociliary adenoma in a Congo African grey parrot *(Psittacus erithacus).* J Avian Med Surg 2019;3:278.
20. Robat CS, Ammersbach M, Mans C. Avian oncology: Diseases, diagnostics and therapeutics. Vet Clin North Am Exot Anim Pract 2016;20:57–86.
21. Suman S, Babita, Singh GN. Comparing ultrasound and CT for diagnosis of ocular disorders. Int J Contemp Med Res 2016;3:2784–2786.
22. Jacobsen BH, Ricks C, Harrie RP. Ocular ultrasound *versus* MRI in the detection of extrascleral extension in a patient with choroidal melanoma. BMC Ophthalmol 2018;18:320.

23. Pipo R, Broadstone R, Murphy C. Lethal oculocardiac reflex in a cockatiel. Vet Comp Ophthalmol 1996;6:27–29.
24. Altman R. Soft tissue surgical procedures. In: Altmann R, ed. Avian Medicine and Surgery. Philadelphia, Pennsylvania: Saunders, 1997:704–732.
25. Bennett RA, Harrison GJ. Soft tissue surgery. In: Ritchie BW, Harrison GJ, Harrison LR, eds. Avian Medicine: Principles and Applications. Lake Worth, Florida: Wingers Publishing, 1994:1096–1136.
26. Murray M, Pizzirani S, Tseng F. A technique for evisceration as an alternative to enucleation in birds of prey: 19 cases. J Avian Med Surg 2013; 27:120–127.
27. Murphy C, Brooks D, Kern T. Enucleation in birds of prey. J Am Vet Med Assoc 1983;183:1234–1237.
28. Coles B. Surgery. In: Coles B, ed. Essentials of Avian Medicine and Surgery. 3rd ed. Oxford, UK: Blackwell Publishing, 2007:142–182.
29. Murphy C. Raptor ophthalmology. Comp Small Anim 1987;9:241–260.
30. Belhorn R. Ciliary body adenocarcinoma in the dog. J Am Vet Med Assoc 1971;159:1124–1128.
31. Glickstein JM, Allen HL. Malignant ciliary body adenocarcinoma in a dog. J Am Vet Med Assoc 1974;165:455–456.
32. Zarfoss M, Dubielzig R. Metastatic iridociliary adenocarcinoma in a Labrador retriever. Vet Pathol 2007;44:672–676.