Photodynamic Therapy as a New Treatment for Chronic Rhinosinusitis - A Systematic Review

Review

Anika Kaura[1], Rishi Shukla[2], Abigail Lamyman[2], Robert Almeyda[3], Mark Draper[4], Pablo Martinez-Devesa[2], Ali Qureishi[2]

[1]Ear Institute, University College London, London, UK
[2]Department of ENT Surgery, John Radcliffe Hospital, Headley Way, Headington, Oxford, UK
[3]Department of ENT Surgery, Royal Berkshire Hospital, Craven Road, Reading, UK
[4]Department of ENT Surgery, Milton Keynes University Hospital, Standing Way, Milton Keynes, UK

Abstract

This review examines the latest evidence for photodynamic therapy (PDT) in treating chronic rhinosinusitis. MedLine, EMBASE and TRIP Database searches were conducted using the terms: "photodynamic" or "phototherapy" or "photo" and "sinusitis" or "rhinosinusitis," date range January 2000 to May 2020. A total of 192 records were initially identified, after duplicates and exclusions, 9 full papers and 3 abstracts were included. All study types including in-vitro, animal and human studies were evaluated. Whilst there is in-vitro evidence for the efficacy of PDT's bactericidal effect on drug resistant bacteria and biofilm viability, there are few clinical studies. PDT is a promising area of research, but larger, focused studies looking at the safety, delivery, efficacy, and patient selection are required before it can be considered a viable treatment for CRS.

Keywords: Phototherapy, photodynamic therapy, paranasal sinus diseases, sinusitis, alternative therapies

Introduction

Chronic rhinosinusitis has a significant impact on patient quality of life and productivity, affecting 5-12% of the general population (1). It is classified as chronic when the core symptoms persist beyond 12 weeks; is difficult to treat or is recalcitrant when symptoms persist despite appropriate medical and surgical treatment. Recent work has focused on defining CRS as either primary or secondary based on the type of the inflammatory disease or endotype. The overall aim is to allow for tailored treatment regimens focusing either on a primarily infective or an inflammatory (type 2) cause. The previous classification of CRS with nasal polyps (CRSwNP) and without nasal polyps (CRSsNP) is no longer favored, as polyps can present in both types of CRS. The classification for primary and secondary CRS is summarized in Figure 1 which has been adapted from Grayson et al. (2). The pathophysiology of CRS is complex; we must consider the various possible predisposing and causative factors.

Allergy and Asthma

Allergy and asthma in the context of CRS have been extensively studied. The presence of inhalant allergy has been found to be significantly higher in both CRS patients with and without polyps (3). The prevalence of allergy appears to vary with phenotype; central compartment atopic disease and allergic fungal rhinosinusitis have stronger associations than CRS with and without polyp groups. There is a strong association between asthma and CRS, especially in those with both CRS and allergic rhinitis (4). A United Kingdom study showed the prevalence of asthma to be 44.9% in CRSwNP, 21.2% in CRSsNP, compared to the 9.95% in controls (3).

Environmental Irritants

It is hypothesized that the pollutants can affect ciliary function including mucociliary clearance (5), predisposing to repeated infection and inflammation. It has been demonstrated that air pollutants are correlated with CRS symptom severity, with CRSsNP being the most affected cohort (6). Studies have shown that occupational exposure to dust from metals, textiles and paper are associated with CRS (6-8).

Fungi

Like bacteria, fungi can form biofilms and secrete toxins, but their role in CRS pathogenesis is yet to be fully elucidated. The role of fungi, like Aspergillus, in subtypes where fungal balls occur and in allergic fungal rhinosinusitis is clearer (9). Ex-vivo studies have shown that *Aspergillus niger* stimulation resulted in increased pro-inflammatory cytokines like IL-6 (10). Shin et al. (11) demonstrated that CRS patients showed exaggerated humoral

ORCID iDs of the authors:
A.K. 0000-0003-3563-5164;
R.S. 0000-0003-2111-3787;
A.L. 0000-0002-4923-4591;
R.A. 0000-0002-1087-7098;
M.D. 0000-0001-5273-8718;
P.M.D. 0000-0002-5665-8173;
A.Q. 0000-0001-8654-6888.

Cite this article as: *Kaura A, Shukla R, Lamyman A, Almeyda R, Draper M, Martinez-Devesa P, et al. Photodynamic Therapy as a New Treatment for Chronic Rhinosinusitis - A Systematic Review. Turk Arch Otorhinolaryngol 2020; 58(4): 254-67.*

Corresponding Author:
Anika Kaura; anika.kaura.19@ucl.ac.uk

Received Date: 16.02.2020
Accepted Date: 19.10.2020

Content of this journal is licensed under a Creative Commons Attribution 4.0 International License. Available online at www.turkarchotolaryngol.net

DOI: 10.5152/tao.2020.5218

and cellular responses to common airborne fungi, particularly Alternaria, and that this could explain the chronicity of inflammation seen in CRS.

Virus

It is hypothesized that viral infection could initiate or exacerbate CRS; coronavirus was the most commonly found virus in patients with CRS (12). In a study from Iran with 76 CRS patients undergoing endoscopic sinus surgery, 33% were found to have at least one of rhinovirus and respiratory syncytial virus (13). Ex-vivo studies have demonstrated that rhinovirus infection can be associated with exacerbation of CRS, including increased susceptibility to secondary microbial infection and impairment of mucociliary clearance (14, 15).

Bacteria and Biofilms

Part of the pathophysiology of CRS is thought to be secondary to bacteria like *Staphylococcus aureus*, where colonization results in the disruption of the normal mucosal barrier and the promotion of immune dysregulation, further amplified by antibiotic drug resistance and biofilm formation (16, 17). In addition, the overgrowth of "bad" bacteria displaces those bacteria that are considered part of a healthy microbiome, resulting in microbial dysbiosis (16).

Patients with CRS have been found to lack normal sinus mucociliary defense mechanisms and to be colonized by multi-drug resistant bacteria that form biofilms within sinus cavities and continue to cause chronic inflammation (18-20). Methicillin-resistant *S. aureus* (MRSA) and multidrug resistant *Pseudomonas aeruginosa* are found in the clinical isolates of CRS patients and are a cause of antibiotic treatment failures (18, 20). Traditional treatment with steroids, oral antibiotics, nasal douches, and sinus surgery are less effective in this population. For these patients and those with other types of CRS, alternative therapies must be evaluated, as supported by the recommendations from EPOS 2020 (21).

A relatively new area of interest involves the use of light therapies. Light therapies include laser, near infra-red illumination, ultraviolet (UV) light therapy and photodynamic therapy (PDT). To date, PDT has been most effective in the treatment of cancer. It is often used to treat actinic keratosis and basal cell carcinoma. It has also been shown to be effective in early stage squamous cell carcinoma of the oropharynx, nasopharynx and larynx, although a clinical role for PDT in this context is yet to be defined (22). In animal studies, PDT has proven effective in treating chronic wound infections by suppressing bacterial growth (23).

Main Points

- Photodynamic therapy involves applying a photoactive agent to a surface and then irradiating this area with light. It has been shown to have anti-inflammatory, anti-bacterial and anti-neoplastic effects.
- Photodynamic therapy aims to reduce the bacterial load causing chronic infection and immune dysregulation in chronic rhinosinusitis
- Photodynamic therapy has been shown to be highly effective *in-vitro* and *in-vivo* against bacteria implicated in chronic rhinosinusitis
- The clinical studies to date have shown promising results through improvements in both objective and subjective outcome measures, with no unacceptable adverse effects
- Randomised control trials are required to fully assess the short and long term efficacy of this treatment modality

PDT uses a photosensitizing agent solution to prime the surface area covered by biofilm, then light at a specific wavelength is administered to activate this solution. This triggers the formation of reactive oxygen species (ROS) which have anti-bacterial, anti-inflammatory and anti-neoplastic downstream activity (24). The ROS damage cell walls, allow translocation of further activated solution and damage inner organelles, resulting in apoptosis (25). This cell death mechanism is an entirely different pathway to that of antimicrobials and might offer an alternative option for combatting multi-drug resistant organisms (26, 27). Commonly used photosensitizers include ultra-methylene blue (selectively binds to microbial cell walls and biofilms) and aminolevulinic acid variants. In addition, in-vitro studies have shown that unlike antibiotics, bacteria do not develop resistance to repeated photodynamic therapy treatments (28). There is also much evidence that PDT can disrupt biofilm by further reducing bacteria viability and increase sensitivity to antibiotics (29).

There are numerous studies to support the bactericidal effect of photodynamic therapy on drug resistant and biofilm forming bacteria (30-37). Whilst this technique may have a role in treating CRS, the research in this area is only just evolving and there is a need to evaluate its potential in treating CRS. This review will focus on the studies that are relevant to PDT and the treatment of CRS.

At present, approved devices include the Sinuwave photodisinfection system licensed in Canada, and a study using this device in human studies has been conducted by Desrosiers et al. (38). Rhinolight is a device that emits UV and visible light and is predominantly being used in the treatment of allergic rhinitis in centers across Hungary and Germany (without the application of a photoactive agent). Its evidence base centers on allergic rhinitis and the ex-vivo study discussed here uses this device in conjunction with a photoactive agent (39, 40). The other studies that have been evaluated in this review use light emitting devices in lab-based settings, not commercially produced or licensed for use in humans.

This review article examines the current evidence base for use of photodynamic therapy in the treatment of chronic rhinosinusitis.

Materials and Methods

MedLine, EMBASE and TRIP database searches were conducted in May 2020 using the following terms: "photodynamic" or "phototherapy" or "photo" and "sinusitis" or "rhinosinusitis", date range January 2000 to May 2020.

Inclusion criteria:
- Original scientific contributions
- Studies that employ photodynamic therapy (agent that acts as a photosensitizer and irradiation with light which could be in the form of a laser, LED, etc.)
- Use bacterial isolates from the human sinus or CRS patients for in-vitro studies
- Must investigate the use of PDT in the context of CRS or bacteria that cause CRS

Exclusion criteria:
- Studies that use light therapy alone without a photosensitizer
- Studies that use planktonic or other research strains of bacteria (they may be referenced to provide supporting evidence but are not included in the main table of papers)
- Insufficient information/conference abstracts (Three conference abstracts, all by Desrosiers et al. (38, 41, 42), have been included as they provide preliminary information on the results in human studies)
- Reviews, books etc. that refer to other studies
- Studies that are not directly looking at CRS, but investigate other conditions like allergic rhinitis or acute rhinosinusitis

AK and RS independently assessed the title and abstracts of the identified articles to determine relevance. Any disagreement was resolved by discussion with senior authors. Database searching identified 192 records that met the search terms (Figure 2). After duplicates were removed, 161 abstracts were screened, of which 106 were then excluded. Fifty-five full text articles were assessed for eligibility against the inclusion and exclusion criteria. After 43 articles were excluded, nine full papers and three abstracts were selected to be included in the review. Some of the full text articles that were excluded (n=43) have been referred to in the paper where they support the evidence of the included articles, for example mechanisms of delivery of PDT.

Regarding in-vitro studies, the papers included here are all relevant to investigating the effect of photodynamic therapy on biofilm forming bacteria, although not all use strains of bacteria from CRS patients or from the sinus cavity. The studies that use other isolates have not been included in the main table of results. According to the American Society of Microbiology (2010), a new approach has to prove an efficacy of 3 $\log_{10}$ reduction of colony forming units (CFU) before being able to use the term "antibacterial" (43).

Results

The studies included six in-vitro, one ex-vivo, one animal case report, three human case series and one randomized control trial (RCT), these are summarized in Table 1.

Pre-Clinical Studies (Laboratory)

In-vitro Studies

Preliminary studies by Zhao et al. (44) demonstrated antimicrobial properties of 5-aminolevulinic acid (ALA) mediated PDT on biofilm forming strains of *S.aureus* and *S.epidermidis*. The application of PDT appreciably reduced bacterial growth of *S.aureus* and *S.epidermidis* isolated from CRS patients. This was measured as a significant reduction in bacterial growth (measured as log reduction in colony forming units) when compared with control groups of the same planktonic strains of bacteria. In the biofilm *S.aureus* experiment, the mean log colony forming units (lgCFU) was 8.68±0.05 (control group), 6.90±0.96 (experiment group) ($t=3.68$, $p<0.05$); and in biofilm *S.epidermidis* experiment the data was 8.67±0.05 (control group), 7.29±0.61 (experiment group, $t=5.07$, $p<0.01$). They present clear methodology for how biofilm was cultured and how conditions were controlled, including how the optimal photosensitizer concentration and light intensity were found. The CRS patients included here had received medical therapy prior to endoscopic sinus surgery (ESS), secretions from the middle meatus were sampled in order to obtain *S.aureus* and *S.epidermidis* strains for this in-vitro experiment. No further details regarding the type and length of medical treatment received by this cohort of CRS patients were included in the manuscript.

This study is supported by research undertaken by Biel et al. (45) using drug resistant strains of *P. aeruginosa* and MRSA. They demonstrated that PDT reduced the CRS polymicrobial biofilm by >99.9% after a single treatment. For the 300μg/mL concentration of the photoactive agent methylene blue (MB) there was a 6.5 log reduction of antibiotic-resistant multi-species bacterial biofilms after a single PDT treatment. When they used a higher MB concentration and lower light parameters, they achieved greater than seven logs of bacteria kill using two PDT light treatments. They showed clear methodology for each of the experimental groups and used an objective automated tool for counting colonies; however, the authors do not offer limitations or a critical appraisal of the study.

More recently, this group created an anatomically correct maxillary sinus model in order to conduct the same experiment using MB and 670 nm non-thermal activating light (46). Again, they showed a 99.9% reduction in biofilm for both *P. aeruginosa* and MRSA strains after one treatment as measured by log reduction in CFU. The model was created from human CT scans, and dimensions were taken as the average of 10 random male and female maxillary sinuses. The mixed species biofilm inoculum was pipetted into sterile silicone models and then allowed to shake for 24 hours. It is not clear how these results using silicone models and artificially grown biofilm can be extrapolated to how biofilm forms on human ciliated respiratory mucosa of the maxillary sinus, and the authors have recognized this as a limitation. The have shown methodological rigor by using 11 different treatment combinations to assess the effects of different concentrations of ethylenediaminetetraacetic acid (EDTA), EtOH and methylene blue. They were able to show that low concentration of EDTA added to MB results in improved PDT efficacy of killing biofilm forming bacteria.

A further study by Zhang et al. (47) in 2017 investigated the effect of ALA mediated PDT on *S.aureus* biofilm, and the effect

Table 1. Summary of Studies of Photodynamic Therapy and Chronic Rhinosinusitis

Title	Author Date Country	Cohort	Level of evidence/ Study type	Outcomes	Key Results	Study Limitations/Risk of Bias
In-vitro study of photodynamic therapy of antibiotic-resistant staphylococcus from patients with chronic rhinosinusitis	Zhao et al. (44) 2016 China	45 patients treated medically for CRS requiring FESS, mucus taken from middle meatus. 13 S.aureus and 16 *S.epidermidis* strains were identified. 5-aminolevulinic acid mediated PDT was applied to these strains as well as Planktonic strains.	Level 5 In-vitro	Mean IgCFU for experiment and control groups of planktonic and patient *S.aureus* and *S. epidermidis* strains.	In the biofilm *S.aureus* experiment, the mean lgCFU was 8.68±0.05 (control group), 6.90±0.96 (experiment group) (t=3.68, P<0.05); and in biofilm *S.epidermidis* experiment the data was 8.67±0.05 (control group), 7.29±0.61 (experiment group, t=5.07, P<0.01).	In-vitro study, only 2 major biofilm forming strains of bacteria used. Single outcome measure (IgCFU), clinical applicability requires evaluation.
Antimicrobial photodynamic therapy treatment of chronic recurrent sinusitis biofilms	Biel et al. (45) 2011 USA	Antibiotic resistant planktonic bacteria and fungi, and polymicrobial biofilms of *Pseudomonas aeruginosa* and MRSA were grown on silastic sheets and treated with a methylene blue photosensitizer and 670nm non-thermal activating light. Cultures of the planktonic microorganisms and biofilms were obtained before and after light treatment to determine efficacy of planktonic bacteria and biofilm reduction.	Level 5 In-vitro	Kill rate as measured by log CFU reduction in bacteria.	The CRS planktonic microorganism and biofilm study demonstrated that aPDT reduced the CRS polymicrobial biofilm by >99.9% after a single treatment. For the 300 µg/mL MB concentration there was 6.5 log reduction of antibiotic-resistant multi-species bacterial biofilms after a single PDT treatment. Using a higher MB concentration (500 µg/mL) and lower light parameters achieved greater than 7 logs of bacteria kill using two PDT light treatments.	Multi-organism biofilm was treated with PDT rather than single organism biofilm.
5-aminolevulinic acid-mediated photodynamic therapy and its strain-dependent combined effect with antibiotics on Staphylococcus aureus biofilm	Zhang et al. (47) 2017 China	Study investigating the effect of 5-aminolevulinic acid with light emitting diode 633nm (ALA mediated PDT) on S.aureus. Biofilm forming MRSA and MSSA strains were isolated from CRS patients undergoing endoscopic sinus surgery. MRSA and MSSA were treated with ALA-PDT, compared with ALA-PDT combined with antibiotics (vancomycin, netilmicin or cefaclor). Control groups included no treatment, ALA alone, and light irradiation alone.	Level 5 In-vitro	Kill rate as measured by log CFU reduction in bacteria.	ALA-PDT was found to significantly inactivate *S.aureus* biofilm across all 15 strains, mean 5.75log10CFU/ml reduction in viable count; the effects were similar in the MSSA and MRSA groups. When ALA-PDT was combined with antibiotics (vancomycin, netilmicin or cefaclor) the bactericidal effect increased for at least 9 out of the 15 strains. They hypothesize that PDT breaks the sessile structure of biofilm leading to recovery of antibiotic sensitivity, although it is not clear why this happens in a strain dependent way.	The addition of antibiotics seems to have an additive effect to the PDT. Experimental groups were small, the conclusion that the effect in MRSA and MSSA strains is not significantly different may not be repeatable. The authors cannot explain why the additive effect of antibiotics is seen in some strains and not in others.

Table 1. Summary of Studies of Photodynamic Therapy and Chronic Rhinosinusitis (Continue)

Title	Author Date Country	Cohort	Level of evidence/ Study type	Outcomes	Key Results	Study Limitations/Risk of Bias
Development and characterization of erythrosine nanoparticles with potential for treating sinusitis using photodynamic therapy	Garapati et al. (48) 2015 USA	Study of erythrosine mediated PDT in *S. aureus* cells using nanoparticle delivery system. In one arm of the experiment, cells were incubated with free erythrosine drug, and the other arm with erythrosine nanoparticles. The control arm was *S. aureus* only plus irradiation. Cells in all arms were irradiated at 6 time points with an LED (530nm).	Level 5 In-vitro	Kill rate as measured by log CFU reduction in bacteria.	The uptake of erythrosine in *S.aureus* cells from nanoparticles and pure drug was approximately 14.83±0.15 and 0.60±0.19 g per mg of protein, respectively. This indicates the ability of bacteria cells to internalize erythrosine nanoparticles is better than the free drug. Photodynamic inactivation of erythrosine nanoparticles after 8, 16 and 24 h, was significantly higher compared to pure erythrosine. This could be attributed to the sustained released of erythrosine from nanoparticles.	This nanoparticle mediated method of PDT could potentially mean that reactive agent is only inserted into a sinus cavity once, and then the irradiation can be repeated at several time points to achieve maximum bactericidal effect. Further in-vivo studies are required to test the efficacy and safety of this method.
The effect of antimicrobial photodynamic therapy on human ciliated respiratory mucosa	Biel et al. (52) 2012 USA	Study of aPDT treatment of EpiAirway™ (in-vitro airway tissue model that originates from normal, human-derived tracheal/ bronchial epithelial cells) was performed. Treatment groups included a non-treatment control, laser light alone, photosensitizer alone, and therapeutic photosensitizer and light combination (aPDT).	Level 5 In-vitro	Histomorphological evaluation of the EpiAirway specimens.	The EpiAirway™ histologic study demonstrated no histologic alteration of the respiratory cilia or mucosal epithelium in any of the treatment groups.	Unclear how accurately in-vitro airway tissue model reflects normal sinus ciliated respiratory epithelium.
Photodynamic therapy of antibiotic-resistant biofilms in a maxillary sinus model	Biel et al. (46) 2013 USA	Antibiotic resistant polymicrobial biofilms of P. aeruginosa and MRSA were grown in an anatomically correct novel maxillary sinus model and treated with a methylene blue/EDTA photosensitizer and 670nm non-thermal activating light. Cultures of the biofilms were obtained before and after light treatment to determine efficacy of biofilm reduction.	Level 5 In-vitro	Kill rate was calculated as surviving CFU/ ml in experimental conditions versus control (no light and no photosensitizer) and expressed as a log10 reduction from control for each individual organism.	PDT reduced the CRS polymicrobial biofilm by >99.99% after a single treatment. The best treatment results in biofilm reduction were achieved with PDT using the photosensitizer 1.25mM EDTA + 5% EtOH + 0.03%MB in the presence of 670nm light resulting in a 5 log10 (99.99%) reduction in *P. aeruginosa* biofilm and a 3.1 log10 (99.9%) reduction in MRSA biofilm after a single treatment. Low concentrations of EDTA added to MB results in improved PDT efficacy of multispecies biofilm bacterial kill.	In-vitro study using anatomically correct model based on CT scans. As the model is not lined by respiratory epithelium it is unclear as to what degree this reflects human physiology.

Table 1. Summary of Studies of Photodynamic Therapy and Chronic Rhinosinusitis (Continue)

Title	Author Date Country	Cohort	Level of evidence/ Study type	Outcomes	Key Results	Study Limitations/Risk of Bias
Ultraviolet light and photodynamic therapy induce apoptosis in nasal polyps	Nemeth et al. (40) 2012 Hungary	Ex-vivo study nasal polyp (NP) tissue was surgically collected from 21 consecutive patients with CRS associated with NP. The removed polyps were cut into pieces and tissue samples were irradiated in-vitro by different doses of combined ultraviolet and visible light (UV/VIS: 280-650nm) and by selective ultraviolet and visible light (sUV/VIS: 295-650nm). PDT was performed by pre-sensitizing tissue samples with 5-delta-aminolevulinic acid (DALA) then irradiated with visible light (VIS: 395-650nm). Tunel assay was applied to detect apoptosis of epithelial and inflammatory cells in irradiated and control nasal polyp tissue samples.	Level 5 Ex-vivo	Apoptosis rate of cells.	UV/VIS light significantly increased epithelial cell and subepithelial leukocyte apoptosis compared to control groups. PDT treatment showed the highest surface epithelial cell apoptosis rate as well as subepithelial leukocyte apoptosis rate compared to all other groups.	This study applies treatment to tissue in a non-physiologic environment and provides results only relating to the CRSwNP cohort.
Temporary regression of locally invasive polypoid rhinosinusitis in a dog after photodynamic therapy	Osaki et al. (51) 2012 Japan	Antivascular photodynamic therapy (PDT) using benzoporphyrin derivative monoacid ring A was applied in one dog with CRS and polyps, 8 months after initial presentation and after failed steroid treatment.	Level 5 Animal case report	CT findings, symptom recurrence.	Short term improvements in symptoms and scan findings up to 11 months post treatment.	In this single case report the subject needed multiple PDT therapies. The improvements appeared to be short lived. Frontal trepanations were used- a method not used by the other studies. Not evident how applicable the results are to human CRS treatment.

Table 1. Summary of Studies of Photodynamic Therapy and Chronic Rhinosinusitis (Continue)

Title	Author Date Country	Cohort	Level of evidence/ Study type	Outcomes	Key Results	Study Limitations/Risk of Bias
Phototherapy for chronic rhinosinusitis	Krespi et al. (53) 2011 USA	A prospective randomized study with 23 symptomatic post-surgical CRS patients with positive cultures was conducted. Two groups (GR1 and GR2) were treated with NILI. GR1 was treated with a 940nm laser, while GR2 was treated with a topical photoactive agent, indocyanine-green, followed with 810nm laser. Saccharin test was performed 1 week following treatment.	Level 4 Case series	Nasal endoscopic scoring (NES), SNOT-20 scores and cultures-positivity / log reduction.	Significant improvement in SNOT scores in both groups. Of the 8 cultures in group 2, post treatment 2 were clear of bacteria and 2 showed significant log reduction. In group 2 there was a 50% reduction in mean NES score. Saccharin transit test for group 2 post treatment was normal in all cases. Two of the 23 patients experienced pain during treatment which subsided after reverting from continuous to pulsed mode.	Small group of test patients. Patients had varying degrees of pre-treatment surgery. NES scoring and saccharin tests were only performed in group 2. Saccharin transit test results suggest no adverse effect on ciliary movement. Little information provided regarding patient characteristics of the two groups, randomization, blinding and follow-up protocol. It appears the experiment was run in the first group which influenced how the second group experiments were conducted.
Sinuwave photo-disinfection for the treatment of refractory chronic rhinosinusitis: a case series	Desrosiers et al. (38) 2013 Canada	Twenty-nine sinuses (13 frontal, 6 ethmoid, 10 maxillary) in nine patients with recalcitrant CRS persisting following technically successful FESS have been treated with the Sinuwave™ photo-disinfection system.	Level 4 Case series		Short term follow-up has shown no delayed complications and somewhat surprisingly, resolution of disease in several patients.	Conference abstract- full results not published yet.
Evaluation of the safety of antimicrobial photodynamic therapy (aPDT) for refractory chronic rhinosinusitis	Desrosiers et al. (42) 2016 Canada	Of the 44 trial patients, 31 were randomized to receive aPDT and a total of 43 treatments were delivered to 154 sinuses (52 frontal, 48 maxillary, 54 ethmoid).	Level 4 Case series-safety study	Pre and post treatment endoscopic visualization, CT imaging, ophthalmologic evaluation, olfactory testing.	aPDT of the paranasal sinuses can be safely performed in post endoscopic sinus surgery sinus cavities. No instances of ocular dysfunction or visual loss occurred. There was no trauma at the level of the surrounding sinus mucosa, and in several patients, there was resolution of disease.	Conference abstract- full results not published yet.

Table 1. Summary of Studies of Photodynamic Therapy and Chronic Rhinosinusitis (Continue)

Title	Author Date Country	Cohort	Level of evidence/ Study type	Outcomes	Key Results	Study Limitations/Risk of Bias
Antimicrobial photodynamic therapy for chronic rhinosinusitis	Desrosiers et al. (41) 2016 Canada	Prospective, randomized controlled trial of 47 patients at 2 clinical centers with a 2:1 randomization model. Twenty-three patients with chronic rhinosinusitis without nasal polyps (CRSsNP) and 24 with chronic rhinosinusitis with nasal polyposis (CRSwNP) unresponsive to medical and surgical therapy were randomized to treatment: a single treatment with aPDT or 2 treatments with aPDT separated by a 4-week interval, or control: endoscopic irrigation with saline.	Level 1 RCT	SNOT-22, endoscopic mucosal score, UPSIT smell test, conventional bacteriology, and Lund-Mackay endoscopic scores.	aPDT treatment improved symptoms and disease specific quality of life, with the greatest effect occurring in the CRSwNP group receiving 2 treatments (endoscopic sinus score improvement 47% at 6 months, p=0.007). aPDT treatments were well tolerated, with the most frequent adverse event being a temporary mild pressure in the treated sinus.	Conference abstract- full results not published yet. The only RCT evaluating both CRSwNP and CRSsNP cohorts. Study uses a variety of objective and subjective outcomes. The follow up time is only 6 months and has a moderate sample size.

IgCFU: log number of colony forming units; CRS: chronic rhinosinusitis; RCT: randomized controlled trial; FESS: functional endoscopic sinus surgery; PDT: photodynamic therapy; EDTA: ethylenediaminetetraacetic acid; CT: computerized tomography; NILI: near infrared laser illumination.

when combined with antibiotics. Ten methicillin sensitive *S.aureus* (MSSA) and 5 MRSA biofilm forming strains were isolated from CRS (with and without polyps) patients undergoing endoscopic surgery. The authors do not detail the clinical history or the previous treatments of these patients who were sampled.

ALA-PDT was found to significantly inactivate *S.aureus* biofilm across all 15 strains, mean 5.75$\log_{10}$CFU/mL reduction in viable count; the effects were similar in the MSSA and MRSA groups. Through the live/dead staining they were able to show that in the ALA-PDT group, the dead cells were predominantly distributed in the upper layer of the biofilm, this could be due to lower concentration of photosensitizer in the inner lay or inability of light to penetrate these regions. When ALA-PDT was combined with antibiotics (vancomycin, netilmicin or cefaclor) the bactericidal effect increased for at least 9 out of the 15 strains. They hypothesize that PDT can break the sessile structure of biofilm resulting in increased antibiotic sensitivity, the authors cannot explain why the added effect with antibiotics is seen in some strains and not others. Regarding the similar effect of ALA-PDT in MSSA and MRS biofilms, the authors recognize that small experimental groups were used and therefore these results may not be generalizable, and further studies are required.

Garapati et al. (48) investigated the role of erythrosine nanoparticles in PDT. They offer detailed and thorough methodology regarding the development of their erythrosine-loaded PLGA (biodegradable polymer) nanoparticle delivery system. They demonstrated that by using nanoparticles to deliver erythrosine inside MRSA cells (from human sinus), there was significantly better uptake of erythrosine than using the free drug (14.83 micrograms per mg of protein compared with 0.6). After 1 hour of incubation, the uptake of erythrosine was ~25 times higher in the presence of erythrosine nanoparticles compared to the free drug. MRSA cells with free erythrosine drug (group 1) and those with erythrosine nanoparticles (group 2) were irradiated at 6 time points with an LED (530 nm). The control groups were MRSA alone, and MRSA plus LED irradiation. There was no effect on MRSA viability in the control groups. At 0.5- and 2-hour time points, groups 1 and 2 produced similar rates of MRSA inactivation. At 8, 16 and 24 hours, photodynamic inactivation of MRSA was significantly higher for group 2. At 16 hours in group 1 there was 5-fold reduction in mean log10CFU/mL compared with complete loss of viability in group 2. They found erythrosine nanoparticles (and irradiation) were highly effective in killing MRSA cells and this could be attributed to the sustained release of erythrosine from nanoparticles. The paper deduces that the nanoparticle system of delivering photoactive reagent into the cells will have more effective bactericidal activity compared with neat reagent. They propose that erythrosine nanoparticles could be delivered into a sinus cavity by using a powder insufflation technique, and that potentially a patient could undergo repeat light therapy without the need for further delivery of the erythrosine, as it is being released continuously from the nanoparticles. They acknowledge that whilst they have shown success in the in-vitro setting, in-vivo studies are required to evaluate the safety and efficacy of the erythrosine nanoparticle delivery system.

Other *In-vitro* Studies (Supporting Evidence)

A more recent study by Parasuraman et al. (49), supports the hypothesis that PDT is more effective when the photosensitizer is delivered into bacterial cells using nanoparticles. They used toluidine

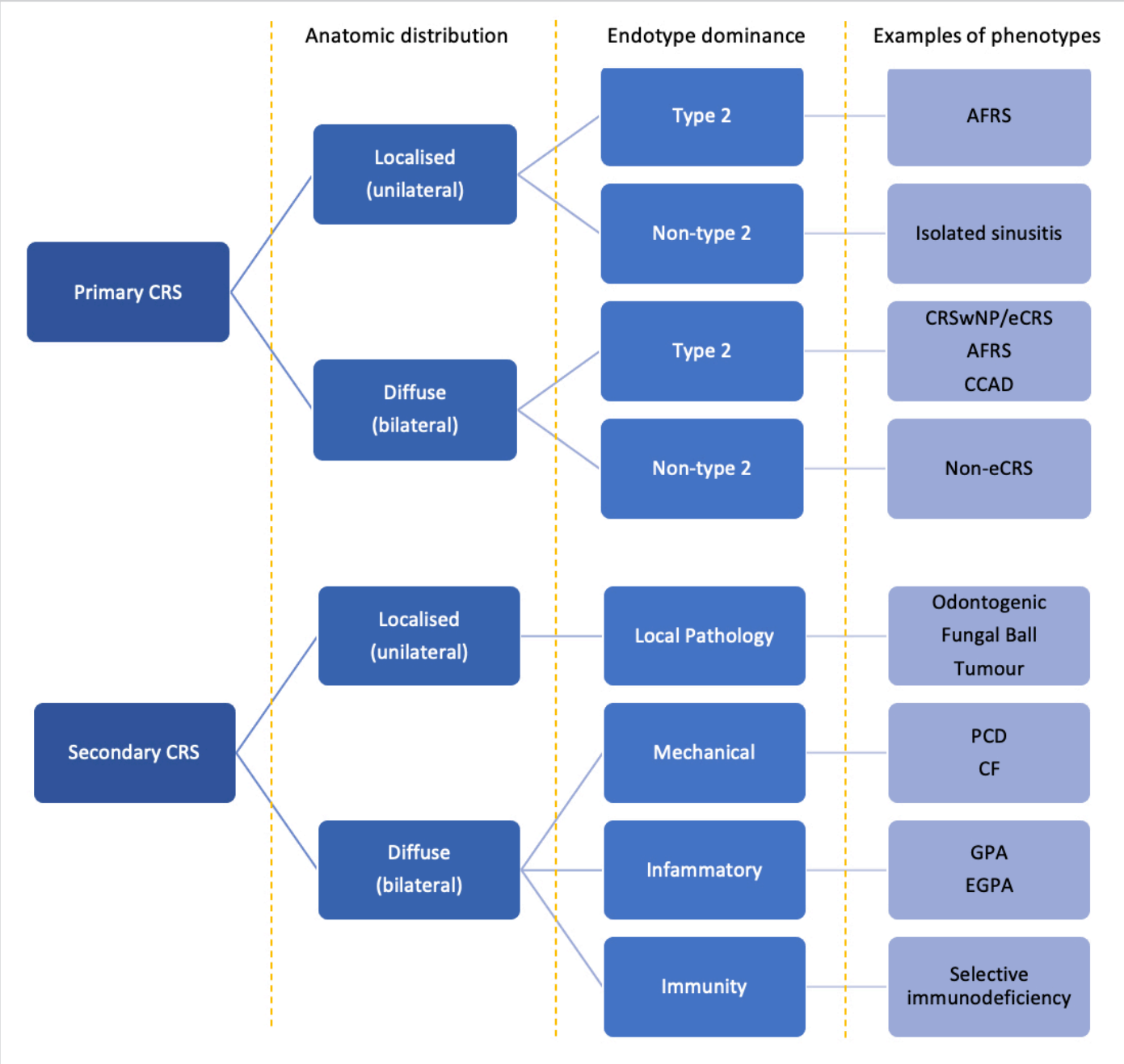

Figure 1. Classification of Primary and Secondary Chronic Rhinosinusitis (adapted from Grayson et al. [2])

blue (TB) encapsulated in mesoporous silica nanoparticles and a red diode laser (670 nm), on *P.aeruginosa* and *S.aureus* (not isolated from the sinus). The study demonstrated significant benefit of using TB in nanoparticles compared with TB alone in terms of reactive oxygen species production, cell inactivation, cell viability and importantly biofilm formation. This is a comprehensive and well-designed study that looked at many outcomes to determine efficacy; these included detection of reactive oxygen species, cell viability, extracellular polymeric substances quantification, protein leakage, lipid peroxidation, biofilm inhibition and anti-biofilm efficiency (live and dead cells) using confocal laser scanning microscopy.

Gandara et al. (50) investigated the effect of toluidine blue (TB) and photodynamic inactivation using 635 nm laser, and the additive effects of using near-infrared treatment (980 nm laser) and proteinase K treatment. Applying TB as the photosensitizer to *S.aureus* biofilm (research strain), and then applying consecutive treatment with 980nm and 635nm lasers produced the largest reduction in biofilm viability (4.5-log viable count decrease), which was significantly more than the effect of TB alone or TB with only one of the lasers. This group proposed that enzymatic digestion of biofilm components using proteinase K could enhance the effect of PDT. When biofilm was treated with proteinase K before TB-PDT there was increased reduction in bacteria CFU counts compared with TB-PDT alone (4.3 vs. 5.46 logs CFU/mL, respectively). This study highlights the additive effect of multiple laser treatment and enzyme treatment in further reducing biofilm viability in an in-vitro setting. The authors

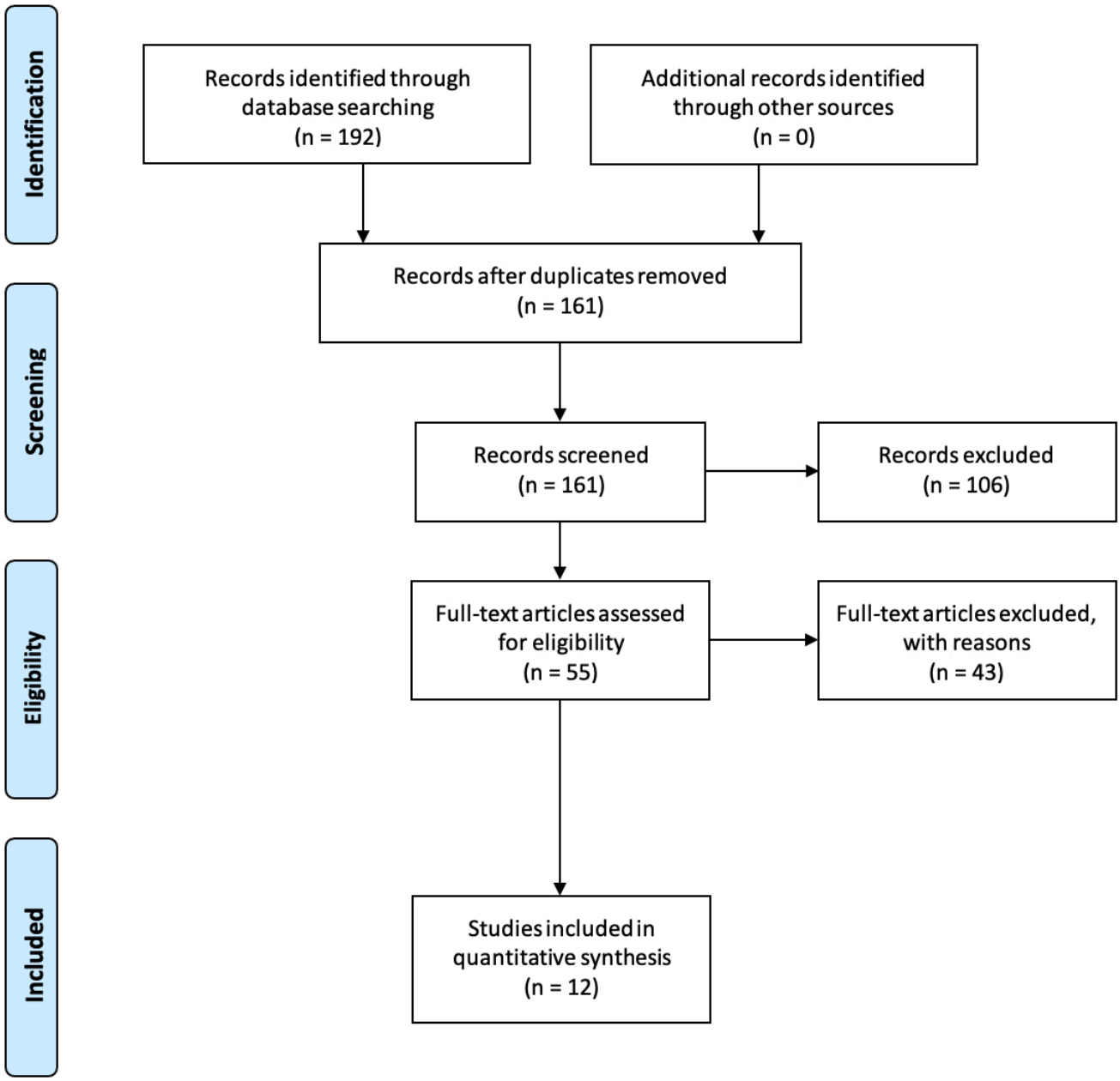

Figure 2. PRISMA Flow Diagram for Systematic Review

recognize that the therapeutic window for near infrared diode lasers is narrow to avoid thermal damage to the host tissue, and this must be further investigated with regards application on human respiratory mucosa that is both safe and with high bactericidal efficacy. They highlight that in-vitro studies investigating the effects of PDT use wide ranging concentrations of photosensitizer and selected wavelengths of light and there it is difficult to compare efficiencies between various studies to obtain mechanistic conclusions.

Ex-vivo Study

Nemeth et al. (40) in 2012 performed an ex-vivo study on polyps taken from 21 consecutive CRS patients undergoing ESS. Patients were excluded if they used certain medication in the four weeks prior, including corticosteroids and leukotrienes. However, no details regarding the clinical history or prior medical or surgical treatment are described. Combinations of ultraviolet and visible light or photodynamic therapy using 5-delat-aminolevulenic acid were applied to the tissue samples using the Rhinolight device. The phototherapy group showed the highest rate of apoptosis of surface epithelial cells (80%) and subepithelial inflammatory cells (70%).

A major limitation of this study is that it is ex-vivo, where harvested polyps are experimented on, it is therefore not clear whether these results reflect in any way what occurs in-vivo in CRS patients with polyps and what the safety profile of the photosensitizing agent or the light irradiation would be. The au-

thors show that for control samples there were smaller numbers of apoptotic surface epithelial cells and subepithelial leukocytes and describe that the numbers seen in the treatment groups were significantly higher than that of the control groups. The authors do not comment on the fact that the polyp tissue being ex-vivo could certainly affect cell viability and susceptibility to light and PDT treatments, potentially skewing the results reported here compared with what would happen in-vivo.

Animal Case Report

A Japanese group have trialed the use of PDT in a dog with CRS and nasal polyps. Osaki et al. (51) describe the case of a dog with disease affecting the nasal cavity and frontal sinuses, which had failed steroid therapy. In this case, antivascular photodynamic therapy (PDT) using benzoporphyrin derivative monoacid ring A (BPD-MA) was administered intranasally via intravenous catheters fitted with cylindrical diffusers, and fibers with microlens inserted through small trephinations of the skin. After 15 minutes of instilling the photosensitizing agent, 690 nm laser light emitted by diode laser was applied via the fibers. After the first treatment there was resolution of symptoms and improvement of computerized tomography (CT) scan findings, however three months later symptoms recurred, and the dog was given a further course of treatment. The subject received four treatments over the space of 11 months. Whilst this case report showed improvement in clinical signs and symptoms after each PDT treatment using BPD-MA, these were clearly short lived. In terms of side-effects, post procedural facial swelling was reported after each treatment, lasting a few days each time and did not require any treatment. This study describes a new technique whereby PDT can be used to treat frontal sinus disease through percutaneous trephinations; although clinically it will be more pragmatic to deliver PDT endonasally via a frontal sinusotomy procedure. This mechanism for treatment would require careful evaluation in human subjects and it is yet unclear if any of the results or analysis would be applicable to the management of CRS in humans.

Safety Studies

The safety of photodynamic therapy has been evaluated by Biel et al. (52) on an in-vitro tissue airway model. They tested PDT using methylene blue and Sinuwave technology on EpiAirway™; this histologic study demonstrated no histologic alteration of the respiratory cilia or mucosal epithelium in any of the treatment groups. It is not evident how representative EpiAirway is of in-vivo respiratory epithelium, so it remains unclear how much these results can be extrapolated.

Desrosiers et al. (41) evaluated the safety of using PDT in human subjects. A conference abstract only gives a summary of the results (full study has not been published). Forty-three PDT treatments were delivered to 154 sinuses. Outcomes included pre and post treatment endoscopic visualization, CT imaging, ophthalmologic evaluation, and olfactory testing using the University of Pennsylvania Smell Identification Test (UPSIT). There were no episodes of ocular dysfunction or mucosal damage. The most frequently reported side effect was transient mild pressure over the treated sinus.

Clinical Studies

In a study by Krespi et al. (53), 23 patients were randomized to receiving laser (940 nm) alone (group 1) or laser (810 nm) and topical photosensitizing agent indocyanine-green (group 2). Post treatment saccharin transit tests for both groups were normal, suggesting no adverse effect on ciliary movement. In the PDT group, Sino-Nasal Outcome Test-20 (SNOT-20) scores dropped by 41% (p=0.0003) and nasal endoscopic scores (NES, based on severity of inflammation, ostial patency and crusting) halved (p=0.0005). In group 1, two of 13 patients were culture negative post treatment, and in group 2, two of 10 patients were culture negative. For the patients where cultures remained positive, there was no detail regarding the log reduction in bacterial growth, and the authors recognized that not measuring bacterial growth qualitatively was a limitation.

There were no serious adverse effects, some experienced minor discomfort during laser illumination, and two patients felt pain associated with heat that subsided when changing from a continuous to a pulsed method of light therapy.

The RoB2 Cochrane tool was used to assess risk of bias in this clinical study. A major limitation was they did not include a control arm. Patients with persistent CRS symptoms, with and without polyps, with at least one prior ESS surgery were recruited; the overall sample size was small. The paper does not offer further details regarding the clinical or surgical history of these patients, and therefore it is unclear whether the two groups were similarly matched in this regard. Patients were assigned to each group by consecutive recruitment randomly to one arm until the group was complete (n=13), then to the other arm. The severity of patient symptoms and endoscopic findings, along with response to treatment guided the number of treatments administered for each patient; it is not clear whether this followed a protocol or was at the discretion of the clinician. The mean follow-up time was 2.8 months, with a range of 2-6 months; it is not evident whether there was a standard follow up protocol; certainly, variable time after treatment could affect the reported outcomes and potentially the magnitude of change in either the SNOT-20 or NES scores.

It appears that experiments were performed consecutively for the two groups, rather than in parallel, so the results of the first study (group 1) appear to have influenced conducting the second study (group 2) experiments. Nasal endoscopic scoring was carried out in group 2 to "record the encouraging endoscopic results demonstrated in group 1." In addition, saccharin transit tests were only carried out in group 2. It is not clear whether the nasal endoscopic scoring was carried out by the same clinician each time, or whether scores were independently checked, and could be considered subjective depending on the clinician's experience; and if different clinicians carried out NES then inter-observer variability needs to be accounted for.

The study appears to have a design where experiments have been carried out consecutively and the first group 1 experiments have influenced how experiments and tests were carried out in the second group. The experiments should have been carried out in parallel using the same protocol. It is also unclear whether patients, clinicians or those carrying out the study were blinded to the type of treatment received.

Whilst there is a lot of missing information regarding the randomization process, the approach in blinding, how the similarity of the characteristics in the two groups were ensured, and how missing data was dealt with, we can conclude that there are considerable concerns regarding risk of bias, and this should be taken into account when interpreting the results and conclusions.

Canada has approved the use of Sinuwave technology for delivering photodynamic therapy in chronic rhinosinusitis. Desrosiers et al. (38) have pioneered the research in this field and after a small case series in 2013, this group conducted the first randomized control trial in 2016 (42). The results have only been published in conference abstract form and the full study results are yet to be published. Each treatment consisted of application of the photosensitizing agent to a previously operated sinus cavity and then illumination with a custom fiber-optic light diffusing balloon catheter. They recruited 23 CRS patients without polyps and 24 CRS patients with polyps to this study. Patients were randomized to PDT or to endoscopic irrigation with saline. Pre and post treatment measures included Sino-Nasal Outcome Test-22, endoscopic mucosal score, UPSIT smell test, conventional bacteriology, and Lund-Mackay endoscopic scores. The study showed PDT treatment improved symptoms and disease specific quality of life, the greatest improvement was in the CRS with polyps group receiving two treatments (endoscopic sinus score improvement of 47% at 6 months, p=0.007).

Discussion/Clinical and Research Consequences

Photodynamic therapy is a new technology that has been used in anti-cancer treatment and might have a role in the treatment of CRS. Studies suggest efficacy in both in-vitro and in-vivo settings, with safety studies so far demonstrating no unacceptable adverse effects.

Clinical studies have shown an improvement in objective and subjective outcome measures in patients with CRS. These studies have only used small sample sizes with follow up times of maximum six months and therefore do not demonstrate the potential long-term benefits or side-effects of PDT.

The studies discussed here use a variety of photosensitizing agents and light emitting devices (Sinuwave and Rhinolight) at different wavelengths. Further studies evaluating combinations of photosensitizing agents at different concentrations, along with each light emitting device at different wavelengths needs to be trialed in human subjects to understand the optimum setting for the eradication of antibiotic resistant biofilm forming bacteria. In addition, most of the clinical studies to date have compared groups of patients receiving different light therapies with no control arm. Studies with control arms receiving no therapy or other traditional medical therapy should be conducted.

The future of PDT will rely on further studies which accurately evaluate the long-term efficacy and sustainability of this intervention using both objective and subjective measures. The ideal study would be a large RCT with appropriately selected CRS patients (with primary and secondary CRS) followed up for more than one year. Evaluation methods should include quantitative measures of bacterial growth, CT scan findings, nasal endoscopic scoring, ciliary activity, olfactory assessment, and subjective measures including the SNOT-22 questionnaire.

Limitations

This review is limited by the lack of existing research, and the quality of included studies, especially clinical trials. Whilst photodynamic therapy is already being used successfully in other domains of medicine and there is in-vitro evidence for the efficacy of PDT, there is little evidence yet to fully support PDT as a viable treatment in CRS patients.

The in-vitro and ex-vivo studies evaluated here have used relatively small experimental groups and different photosensitizers and wavelengths of light. Therefore, it is difficult to compare the in-vitro studies to one another. It is yet unclear how the results of in-vitro studies that have used laboratory-grown biofilm from CRS isolates and/or silicone maxillary models can be extrapolated to the treatment of CRS in humans. Therefore in-vivo studies based on the in-vitro methods used are required to fully assess efficacy, durability, and safety. The clinical studies that have been conducted so far either have insufficient information regarding methodology or considerable risk of bias.

Conclusion

Research in CRS to date have shown that the factors in CRS pathophysiology include the sino-nasal microbiome, host immunity and mucosal barrier. Photodynamic therapy aims to reduce the bacterial load causing chronic infection and immune dysregulation. Preliminary data suggests that PDT is likely to be safe and has proven effective in-vitro. Further clinical research is required to evaluate the safety and efficacy of photodynamic therapy compared with traditional treatment, and how a healthier nasal microbiome can be restored.

The ultimate goal for research into PDT should be to demonstrate an ability to significantly improve the burden of CRS disease and identify the patients or the endotypes of the disease that are most likely to respond. For the treatment to reach clinical practice it will need to be proven as safe, effective, practical, and reproducible. Whilst this may take several years there is enough pre-clinical and early data for cautious optimism in this novel treatment modality.

Peer-review: Externally peer-reviewed.

Author Contributions: Concept - A.Q.; Design - A.K., A.Q.; Supervision - A.Q.; Data Collection and/or Processing - A.K., R.S.; Analysis and/or Interpretation - A.K., A.Q., R.S.; Literature Search - A.K., R.S.; Writing - A.K., A.Q.; Critical Review - A.L., R.A., M.D., P.M.D.

Conflict of Interest: The authors have no conflicts of interest to declare.

Financial Disclosure: The authors declared that this study has received no financial support.

References

1. Dietz de Loos D, Lourijsen ES, Wildeman MAM, Freling NJM, Wolvers MDJ, Reitsma S, et al. Prevalence of chronic rhinosinusitis in the general population based on sinus radiology and symptomatology. J Allergy Clin Immunol. 2019; 143: 1207-14. [Crossref]
2. Grayson JW, Hopkins C, Mori E, Senior B, Harvey RJ. Contemporary Classification of Chronic Rhinosinusitis Beyond Polyps vs No Polyps: A Review. JAMA Otolaryngol Head Neck Surg. 2020. [Crossref]
3. Philpott CM, Erskine S, Hopkins C, Kumar N, Anari S, Kara N, et al. Prevalence of asthma, aspirin sensitivity and allergy in chronic rhinosinusitis: data from the UK National Chronic Rhinosinusitis Epidemiology Study. Respir Res 2018; 19: 129. [Crossref]
4. Jarvis D, Newson R, Lotvall J, Hastan D, Tomassen P, Keil T, et al. Asthma in adults and its association with chronic rhinosinusitis: the GA2LEN survey in Europe. Allergy 2012; 67: 91-8. [Crossref]
5. Gudis D, Zhao KQ, Cohen NA. Acquired cilia dysfunction in chronic rhinosinusitis. Am J Rhinol Allergy 2012; 26: 1-6. [Crossref]
6. Mady LJ, Schwarzbach HL, Moore JA, Boudreau RM, Tripathy S, Kinnee E, et al. Air pollutants may be environmental risk factors in chronic rhinosinusitis disease progression. Int Forum Allergy Rhinol 2018; 8: 377-84. [Crossref]
7. Gao WX, Ou CQ, Fang SB, Sun YQ, Zhang H, Cheng L, et al. Occupational and environmental risk factors for chronic rhinosinusitis in China: a multicentre cross-sectional study. Respir Res 2016; 17: 54. [Crossref]
8. Veloso-Teles R, Cerejeira R, Roque-Farinha R, von Buchwald C. Higher prevalence of nasal polyposis among textile workers: an endoscopic based and controlled study. Rhinology 2018; 56: 99-105. [Crossref]
9. Ponikau JU, Sherris DA, Kern EB, Homburger HA, Frigas E, Gaffey TA, et al. The diagnosis and incidence of allergic fungal sinusitis. Mayo Clin Proc 1999; 74: 877-84. [Crossref]
10. Sproson EL, Thomas KM, Lau LC, Harries PG, Howarth PH, Salib RJ. Common airborne fungi induce species-specific effects on upper airway inflammatory and remodelling responses. Rhinology 2016; 54: 51-5. [Crossref]
11. Shin SH, Ponikau JU, Sherris DA, Congdon D, Frigas E, Homburger HA, et al. Chronic rhinosinusitis: an enhanced immune response to ubiquitous airborne fungi. J Allergy Clin Immunol 2004; 114: 1369-75. [Crossref]
12. Rowan NR, Lee S, Sahu N, Kanaan A, Cox S, Phillips CD, et al. The role of viruses in the clinical presentation of chronic rhinosinusitis. Am J Rhinol Allergy 2015; 29: e197-200. [Crossref]
13. Abshirini H, Makvandi M, Seyyed Ashrafi M, Hamidifard M, Saki N. Prevalence of rhinovirus and respiratory syncytial virus among patients with chronic rhinosinusitis. Jundishapur J Microbiol 2015; 8: e20068. [Crossref]
14. Meng J, Zhou P, Liu Y, Liu F, Yi X, Liu S, et al. The development of nasal polyp disease involves early nasal mucosal inflammation and remodelling. PLoS One 2013; 8: e82373. [Crossref]
15. Hoggard M, Wagner Mackenzie B, Jain R, Taylor MW, Biswas K, Douglas RG. Chronic rhinosinusitis and the evolving understanding of microbial ecology in chronic inflammatory mucosal disease. Clin Microbiol Rev 2017; 30: 321-48. [Crossref]
16. Vickery TW, Ramakrishnan VR, Suh JD. The role of staphylococcus aureus in patients with chronic sinusitis and nasal polyposis. Current allergy and asthma reports 2019; 19: 21. [Crossref]
17. Singh P, Mehta R, Agarwal S, Mishra P. Bacterial biofilm on the sinus mucosa of healthy subjects and patients with chronic rhinosinusitis (with or without nasal polyposis). J Laryngol Otol 2015; 129: 46-9. [Crossref]
18. Marple BF, Stankiewicz JA, Baroody FM, Chow JM, Conley DB, Corey JP, et al. Diagnosis and management of chronic rhinosinusitis in adults. Postgrad Med 2009; 121: 121-39. [Crossref]
19. Harvey RJ, Lund VJ. Biofilms and chronic rhinosinusitis: systematic review of evidence, current concepts and directions for research. Rhinology 2007; 45: 3-13.
20. Desrosiers MY, Kilty SJ. Treatment alternatives for chronic rhinosinusitis persisting after ESS: what to do when antibiotics, steroids and surgery fail. Rhinology 2008; 46: 3-14.
21. Fokkens WJ, Lund VJ, Hopkins C, Hellings PW, Kern R, Reitsma S, et al. European Position Paper on Rhinosinusitis and Nasal Polyps 2020. Rhinology 2020; 58: 1-464. [Crossref]
22. Agostinis P, Berg K, Cengel KA, Foster TH, Girotti AW, Gollnick SO, et al. Photodynamic therapy of cancer: an update. CA Cancer J Clin 2011; 61: 250-81. [Crossref]
23. Fila G, Kasimova K, Arenas Y, Nakonieczna J, Grinholc M, Bielawski KP, et al. murine model imitating chronic wound infections for evaluation of antimicrobial photodynamic therapy efficacy. Front Microbiol 2016; 7: 1258. [Crossref]
24. Castano AP, Mroz P, Hamblin MR. Photodynamic therapy and anti-tumour immunity. Nat Rev Cancer 2006; 6: 535-45. [Crossref]
25. Vatansever F, de Melo WC, Avci P, Vecchio D, Sadasivam M, Gupta A, et al. Antimicrobial strategies centered around reactive oxygen species--bactericidal antibiotics, photodynamic therapy, and beyond. FEMS Microbiol Rev 2013; 37: 955-89. [Crossref]
26. Grinholc M, Szramka B, Kurlenda J, Graczyk A, Bielawski KP. Bactericidal effect of photodynamic inactivation against methicillin-resistant and methicillin-susceptible Staphylococcus aureus is strain-dependent. J Photochem Photobiol B 2008; 90: 57-63. [Crossref]
27. Maisch T. Resistance in antimicrobial photodynamic inactivation of bacteria. Photochem Photobiol Sci 2015; 14: 1518-26. [Crossref]
28. Pedigo LA, Gibbs AJ, Scott RJ, Street CN, editors. Absence of bacterial resistance following repeat exposure to photodynamic therapy. Photodynamic Therapy: Back to the Future; 2009: International Society for Optics and Photonics. [Crossref]
29. de Melo WCMA, Avci P, de Oliveira MN, Gupta A, Vecchio D, Sadasivam M, et al. Photodynamic inactivation of biofilm: taking a lightly colored approach to stubborn infection. Expert Rev Anti Infect Ther 2013; 11: 669-93. [Crossref]
30. Demidova T, Hamblin M. Photodynamic therapy targeted to pathogens. Int J Immunopathol Pharmacol 2004; 17: 245-54. [Crossref]
31. Sung N, Back S, Jung J, Kim K-H, Kim J-K, Lee JH, et al. Inactivation of multidrug resistant (MDR)-and extensively drug resistant (XDR)-Mycobacterium tuberculosis by photodynamic therapy. Photodiagnosis Photodyn Ther 2013; 10: 694-702. [Crossref]
32. Liu Y, Qin R, Zaat SA, Breukink E, Heger M. Antibacterial photodynamic therapy: overview of a promising approach to fight antibiotic-resistant bacterial infections. J Clin Transl Res 2015; 1: 140.
33. Fu X-j, Fang Y, Yao M. Antimicrobial photodynamic therapy for methicillin-resistant Staphylococcus aureus infection. BioMed 2013; 2013. [Crossref]
34. Hamblin MR. Antimicrobial photodynamic inactivation: a bright new technique to kill resistant microbes. Curr Opin Microbiol 2016; 33: 67-73. [Crossref]

35. Soukos NS, Goodson JM. Photodynamic therapy in the control of oral biofilms. Periodontology 2011; 55: 143-66. [Crossref]
36. Garcez AS, Núnez SC, Azambuja Jr N, Fregnani ER, Rodriguez HM, Hamblin MR, et al. Effects of photodynamic therapy on gram-positive and gram-negative bacterial biofilms by bioluminescence imaging and scanning electron microscopic analysis. Photomed Laser Surg. 2013; 31: 519-25. [Crossref]
37. Hu X, Huang Y-Y, Wang Y, Wang X, Hamblin MR. Antimicrobial photodynamic therapy to control clinically relevant biofilm infections. Front Microbiol 2018; 9: 1299. [Crossref]
38. Desrosiers M, Felasi M, Endam L, Knapik M, editors. Sinuwave photodisinfection for the treatment of refractory chronic rhinosinusitis: a case series. Poster presented at: American Rhinologic Society at American Academy of Otolaryngology 59th Annual Meeting, Vancouver BC; 2013.
39. Brehmer D. Endonasal phototherapy with Rhinolight for the treatment of allergic rhinitis. Expert Rev Med Devices 2010; 7: 21-6. [Crossref]
40. Nemeth IB, Zsiros O, Koreck A, Bella Z, Kiricsi A, Ignacz F, et al. Ultraviolet light and photodynamic therapy induce apoptosis in nasal polyps. J Photochem Photobiol B 2012; 117: 179-84. [Crossref]
41. Desrosiers M, Endam ML, Lasso A, Kilty S, editors. Evaluation of the safety of antimicrobial photodynamic therapy (aPDT) for refractory chronic rhinosinusitis. New Jersey: Wiley-Blackwell.
42. Desrosiers M, Endam L, Lasso A, Andersen R, Loebel N, Cross C. Antimicrobial photodynamic therapy for chronic rhinosinusitis. Otolaryngol Head Neck Surg 2016; 155: 145-6.
43. Cieplik F, Tabenski L, Buchalla W, Maisch T. Antimicrobial photodynamic therapy for inactivation of biofilms formed by oral key pathogens. Front Microbiol 2014; 5: 405. [Crossref]
44. Zhao K, Yang C, Ding G, Liu C, Ma Y, Chen X, et al. [In-vitro study of photodynamic therapy of antibiotic-resistant staphylococcus from patients with chronic rhinosinusitis]. Zhonghua Er Bi Yan Hou Tou Jing Wai Ke Za Zhi. 2016; 51: 164-8.
45. Biel MA, Sievert C, Usacheva M, Teichert M, Balcom J. Antimicrobial photodynamic therapy treatment of chronic recurrent sinusitis biofilms. Int Forum Allergy Rhinol 2011; 1: 329-34. [Crossref]
46. Biel MA, Pedigo L, Gibbs A, Loebel N. Photodynamic therapy of antibiotic-resistant biofilms in a maxillary sinus model. Int Forum Allergy Rhinol 2013; 3: 468-73. [Crossref]
47. Zhang QZ, Zhao KQ, Wu Y, Li XH, Yang C, Guo LM, et al. 5-aminolevulinic acid-mediated photodynamic therapy and its strain-dependent combined effect with antibiotics on Staphylococcus aureus biofilm. PLoS One 2017; 12: e0174627. [Crossref]
48. Garapati C, Clarke B, Zadora S, Burney C, Cameron BD, Fournier R, et al. Development and characterization of erythrosine nanoparticles with potential for treating sinusitis using photodynamic therapy. Photodiagnosis Photodyn Ther 2015; 12: 9-18. [Crossref]
49. Parasuraman P, Antony AP, B SLS, Sharan A, Siddhardha B, Kasinathan K, et al. Antimicrobial photodynamic activity of toluidine blue encapsulated in mesoporous silica nanoparticles against Pseudomonas aeruginosa and Staphylococcus aureus. Biofouling 2019; 35: 89-103. [Crossref]
50. Gandara L, Mamone L, Bohm GC, Buzzola F, Casas A. Enhancement of photodynamic inactivation of Staphylococcus aureus biofilms by disruptive strategies. Lasers Med Sci 2017; 32: 1757-67. [Crossref]
51. Osaki T, Takagi S, Hoshino Y, Aoki Y, Sunden Y, Ochiai K, et al. Temporary regression of locally invasive polypoid rhinosinusitis in a dog after photodynamic therapy. Aust Vet J 2012; 90: 442-7. [Crossref]
52. Biel MA, Jones JW, Pedigo L, Gibbs A, Loebel N. The effect of antimicrobial photodynamic therapy on human ciliated respiratory mucosa. Laryngoscope 2012; 122: 2628-31. [Crossref]
53. Krespi YP, Kizhner V. Phototherapy for chronic rhinosinusitis. Lasers Surg Med 2011; 43: 187-91. [Crossref]