The Oncologist®

Immuno-Oncology

The Safety and Efficacy of Checkpoint Inhibitors in Transplant Recipients: A Case Series and Systematic Review of Literature

Vivek Kumar,[a] Atul B. Shinagare,[b] Helmut G. Rennke,[c] Sandeep Ghai,[d] Jochen H. Lorch,[a] Patrick A. Ott,[a] Osama E. Rahma[a]

[a]Department of Medical Oncology, Dana Farber Cancer Institute and Brigham and Women's Hospital, Boston, Massachusetts, USA; Departments of [b]Radiology and [c]Pathology, Brigham and Women's Hospital, Boston, Massachusetts, USA; [d]Transplant Nephrology, Boston Medical Center, Boston, Massachusetts, USA

Disclosures of potential conflicts of interest may be found at the end of this article.

Key Words. Immune checkpoint inhibitors • Renal transplant • Liver transplant • Heart transplant • Transplant rejection

Abstract

Limited data exist on safety and efficacy of immune checkpoint inhibitors (ICIs) among organ transplant recipients. The objective of this study was to report a case series of two patients with renal transplant who received treatment with an ICI and to conduct a pooled analysis of published cases to describe the safety and efficacy of ICIs in organ transplant patients. A systematic search in the Google Scholar and PubMed databases was carried out to include all the published cases of organ transplant patients who received treatment with ICIs including programmed cell death protein 1 (PD-1), programmed death-ligand 1, or cytotoxic lymphocyte antigen-4 inhibitors since their inscription to January 31, 2019. In the present series of two cases with renal allografts who received pembrolizumab, one patient with squamous cell carcinoma of the skin experienced complete response (CR), whereas another patient with melanoma had a mixed response. Both patients experienced allograft rejection, but graft was salvaged. The pooled analysis of 64 patients published in literature showed that overall allograft rejection rate is 41% in organ transplant recipients following ICI therapy. The graft rejection rate was 44% (17/39) for renal, 39% (7/19) for liver, and 20% (1/5) for cardiac allografts. The highest risk was seen among patients who were treated with PD-1 inhibitors, 20/42 (48%)—13/24 (54%) on nivolumab and 7/18 (39%) on pembrolizumab. The risk was lowest with ipilimumab, 23% (3/13). The overall response rate (CR + partial response [PR]) was 20% with ipilimumab, 26% with nivolumab, and 53% with pembrolizumab, whereas disease control rate (CR + PR + stable disease) was 35% with ipilimumab, 37% with nivolumab, and 53% with pembrolizumab. None of the variables including age, gender, type of cancer, type of allograft, type of immunosuppression, time since transplantation to initiation of ICI, and prior history of rejection were significantly associated with the transplant rejection on univariate analysis. The efficacy of ICI among patients with organ transplant appears promising, warranting testing in prospective clinical trials. The risk of rejection and allograft loss is considerable; therefore, the risk and alternative form of therapies should be thoroughly discussed with the transplant patients prior to initiating ICI therapy. ***The Oncologist*** 2020;25:505–514

Implications for Practice: Transplant recipients are at higher risk of developing cancers. Although immune checkpoint inhibitors have been shown to improve the outcome in more than one cancer type, transplant recipients were excluded from these trials. Most of the data on the safety and efficacy of immune checkpoint inhibitors in transplant patients are based upon case series and case reports. The pooled data from these reports suggest that anti-programmed death-ligand 1 inhibitors have reasonable safety and efficacy among organ transplant patients, which warrants testing in clinical trials.

Introduction

Immune checkpoint inhibitors (ICIs) have drastically changed the landscape of cancer therapy [1–4], and the spectrum of their indications is set to increase [5]. However, the safety and efficacy of ICIs in patients with cancer who received organ transplants is largely unknown.

The two clinically most relevant immune checkpoints are the inhibitory receptors cytotoxic T-lymphocyte-associated antigen-4 (CTLA-4), which modulates T-cell activation during the antigen priming phase, and the programmed death 1/programmed cell death protein 1 (PD-1/PD-L1) axis, which

Correspondence: Osama E. Rahma, M.D., Dana Farber Cancer Institute, 450 Brookline Ave., Boston 02215, Massachusetts, USA. Telephone: 617-632-3000; e-mail: osamae_rahma@dfci.harvard.edu Received August 27, 2019; accepted for publication December 9, 2019; published Online First on February 11, 2020. http://dx.doi.org/10.1634/theoncologist.2019-0659

No part of this article may be reproduced, stored, or transmitted in any form or for any means without the prior permission in writing from the copyright holder. For information on purchasing reprints contact Commercialreprints@wiley.com. For permission information contact permissions@wiley.com.

 © AlphaMed Press 2020

functions during the effector phase of tumor-specific T-cell response [6, 7]. By blocking these inhibitory receptors, ICIs stimulate the host immune response marked by restoration of antigen priming, proliferation, migration, and effector functions of T cells. Although this can initiate or restore host immunity against the tumor cells, its consequences could be catastrophic for patients with organ transplants. Because immune checkpoints are also involved in the immune tolerance required for allograft survival, ICIs can lead to allograft rejection as shown in several animal studies [8, 9]. Conversely, organ transplant patients receive immunosuppressive therapy, which may counteract the effect of ICIs.

As compared with the general population, the risk of developing cancer is higher in organ transplanted patients, with cancer being the second most common cause of death. For example, the risk for developing non-Hodgkin lymphoma is 7.5 times greater compared with the general population, whereas for lung, kidney, and liver cancer, the risk is increased by 2, 4.7, and 11.6 times, respectively [10]. The increased risk has been attributed to chronic immunosuppression (IS) and infection with oncogenic viruses [10, 11].

Patients with organ transplants are routinely excluded from ICIs clinical trials, resulting in a lack of data on their safety and efficacy in this patient population. Nevertheless, ICIs have been used off label among patients with cancer with organ transplant, leading to an emerging literature based on case reports and small case series [12–50]. Herein, we report on two renal transplant patients from our own experience (one with metastatic squamous cell carcinoma [SCC] and another with melanoma). We also carried out a systematic search of the available literature to identify the factors that could predict the risk of allograft rejection.

Case Reports

Case 1

Case 1 was a 66-year-old patient with a past medical history of live donor renal transplant (in October 2003) for end-stage renal disease (ESRD) secondary to polycystic kidney disease, hypertension, and multiple recurrent facial cutaneous SCC, status post left orbital exenteration followed by rectus sheath flap reconstruction and several courses of radiation therapy (in 2010, 2013, and 2016; Fig. 1). His post-transplant course was unremarkable. For IS, he initially received mycophenolate mofetil (MMF) 1,000 mg b.i.d., tacrolimus 4 mg b.i.d., and prednisone 20 mg daily. The IS regimen was changed from calcineurin inhibitor (CNI; tacrolimus) to mammalian target of rapamycin (mTOR) inhibitors (sirolimus) following a skin cancer diagnosis as mTOR inhibitors have been shown to be associated with risk of cutaneous malignancies among renal transplant patients [11]. His IS regimen was further modified multiple times owing to the recurrent cancers, but he continued to develop recurrent SCCs over his scalp and facial region. These lesions were resected surgically with flap repair. In the year 2017, the sirolimus was switched over to tacrolimus because of the concerns for sirolimus affecting the wound healing. In January 2018, a surveillance positron emission tomography (PET)/computed tomography (CT) showed nodal and distant recurrence of SCC as evident by fluorodeoxyglucose avid lesions in the local lymph node and liver despite absence of new skin disease (Fig. 2A, 2B). Given the extent of recurrent disease, treatment with ICIs was reviewed, including detailed discussion of the risks and benefits about the use of ICIs in the setting of organ transplant. Subsequently, he was started on pembrolizumab 200 mg every 3 weeks in February 2018. The IS regimen was changed from tacrolimus 1 mg b.i.d. and MMF 750 mg in the morning and 500 mg in the evening to MMF 500 b.i.d. and sirolimus 2 mg daily. The patient tolerated pembrolizumab well, without clinically significant adverse events. Restaging magnetic resonance imaging (MRI and CT scan) performed 2 months after the initiation of pembrolizumab showed a complete response (CR; Fig. 2C). However, there were multifocal infiltrates and ground glass opacities concerning for pneumonitis. Treatment with pembrolizumab was continued given the absence of clinical symptoms. Repeat CT imaging 3 months later in June 2018 (5 months after starting pembrolizumab) showed continued CR. After 8 months of treatment with pembrolizumab, in September 2018, a rise in creatinine to 2.5 mg/dL (from a baseline of 1.7–1.9 mg/dL) was noted on routine laboratory studies. Computed tomography of the abdomen and pelvis demonstrated new mild enlargement and fullness of the right pelvicalyceal system of the transplanted right kidney. No new metastatic lesions were seen. Urinalysis was unremarkable. A biopsy of the renal allograft was performed, demonstrating acute cell-mediated rejection of Banff grade IIA. The patient was treated with methylprednisolone pulse (250 mg daily × three doses) and intravenous immunoglobulin (IVIG; 2 g/kg), leading to improvement of serum creatinine to 2. He was then continued on prednisone taper and sirolimus (2 mg daily). Given the graft rejection in the setting of complete tumor response, pembrolizumab was discontinued. Two months later, in November 2018, he was again readmitted because of an elevated serum creatinine (to 2.8 mg/dL) on routine follow-up. Another biopsy of the kidney graft was performed in December 2018, which was again consistent with acute cell-mediated rejection. He was re-treated with IVIG (2 g/kg) and methylprednisolone (500 mg × 3 days) and was later discharged on sirolimus, prednisone taper, and MMF with stable renal function.

Case 2

Case 2 was a 78-year-old man with past medical history of allogenic renal transplant in 2006 for ESRD due to Alport syndrome, diabetes mellitus, atrial fibrillation, and hypertension who was initially maintained on tacrolimus (1 mg [a.m.] and 2 mg [p.m.]), mycophenolate (1000 mg b.i.d. and later titrated down to 500 mg b.i.d.) and prednisone 5 mg. He was diagnosed with stage T2bN0M0 cutaneous melanoma arising from the nasal skin, BRAF/NRAS/c-KIT wild type, and underwent a wide local excision in 2015. His IS regimen was changed to sirolimus 1 mg daily, MMF 750 mg b.i.d., and prednisone 5 mg daily. In June 2017, he was diagnosed with nodal recurrence and underwent a left neck dissection followed by adjuvant radiation to the left neck and was subsequently monitored closely with cross-sectional imaging. In July 2018, disease progression in the left neck and metastases to bones were noted on PET/CT (Fig. 3A, 3B). After extensive discussion with the patient, he was started on pembrolizumab 200 mg every 3 weeks. Prednisone was stopped while sirolimus and MMF were continued on the same doses. His other

© AlphaMed Press 2020

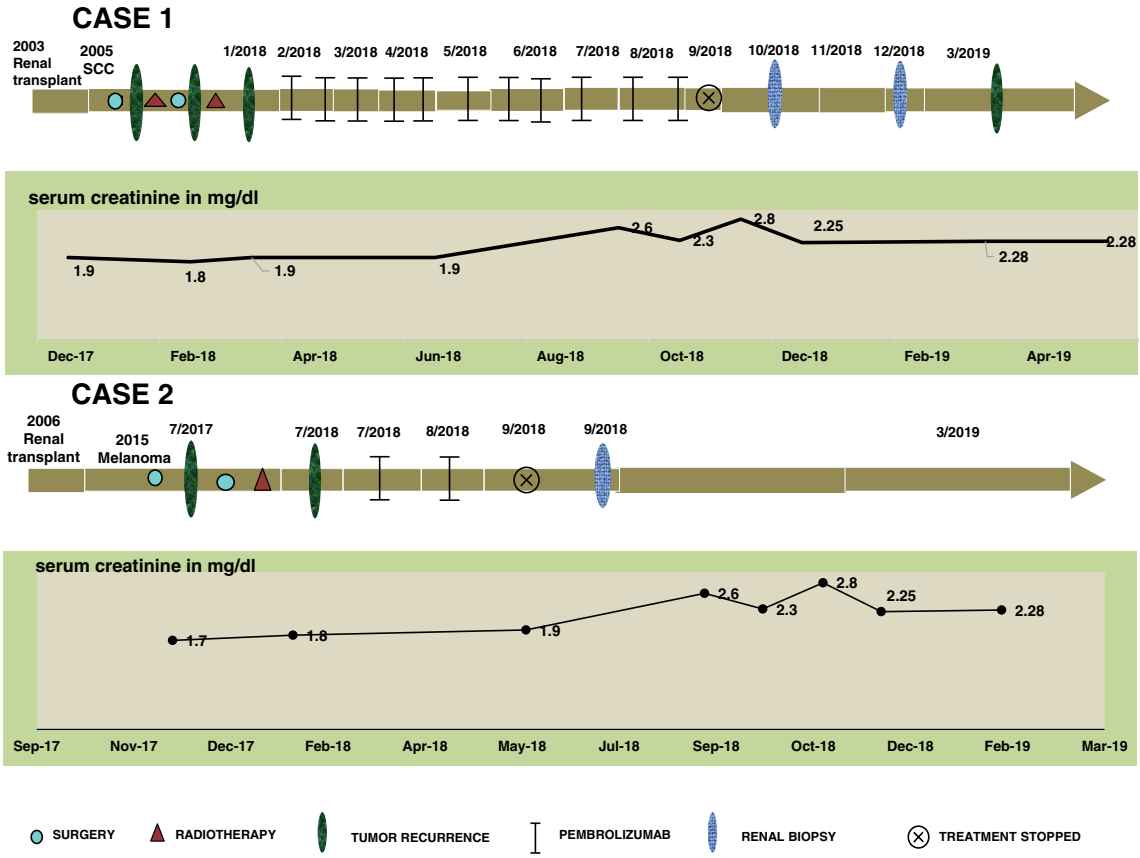

Figure 1. Timeline illustration of clinical courses of two cases.

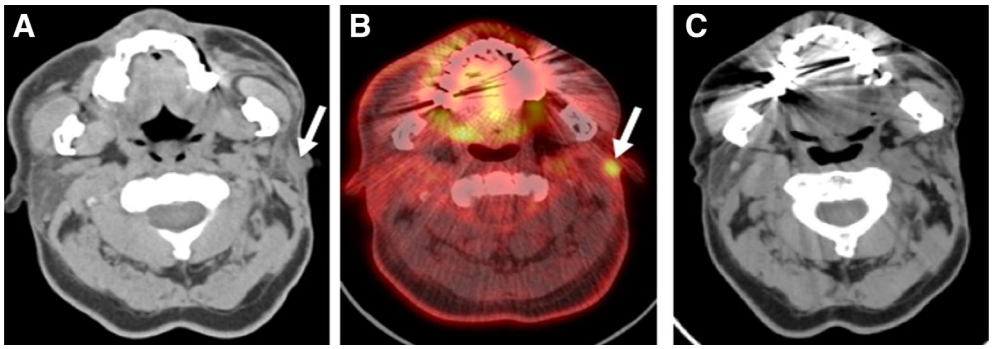

Figure 2. Radiological course of lesion in the first case. Axial unenhanced computed tomography (CT) image at baseline **(A)** shows a left cervical superficial soft tissue nodule that was fluorodeoxyglucose-avid on subsequent positron emission tomography/CT **(B)**. This nodule resolved on follow-up CT **(C)**.

medications included apixaban, insulin, furosemide, and losartan. His kidney function was monitored weekly. After the first dose, he developed diarrhea and his creatinine showed mild elevation from 1.24 mg/dL to 1.39 mg/dL. The diarrhea resolved after supportive treatment before the second cycle. After the second dose, a gradual increase in creatinine levels was noticed. After 5 weeks since initiation of pembrolizumab, he was hospitalized because of a rise in creatinine to 2.85 mg/dL. His urine output was normal, and he did not have any signs or symptoms of acute renal failure. Workup revealed normal urinalysis and fractional excretion of sodium of 1. A renal ultrasound was normal with normal resistive indices. The patient underwent renal biopsy, which demonstrated active cell-mediated rejection of Banff grade IA. He was treated with pulse methylprednisolone 500 mg for 3 days followed by a prednisone taper starting from 50 mg daily. The MMF dose was increased to 1 g twice a day, and sirolimus was increased to 2 mg daily. Treatment with pembrolizumab was discontinued permanently. On follow-up after 2 weeks, serum creatinine was again found to be increased to 2.85 mg/dL. The patient received another course of pulse methylprednisolone. Serum creatinine eventually plateaued at 2.5 mg/dL and ultimately decreased to baseline of 1.4 mg/dL. Repeat staging scans performed 3 months after initiation of pembrolizumab showed a mixed response (Fig. 4A, 4B).

 © AlphaMed Press 2020

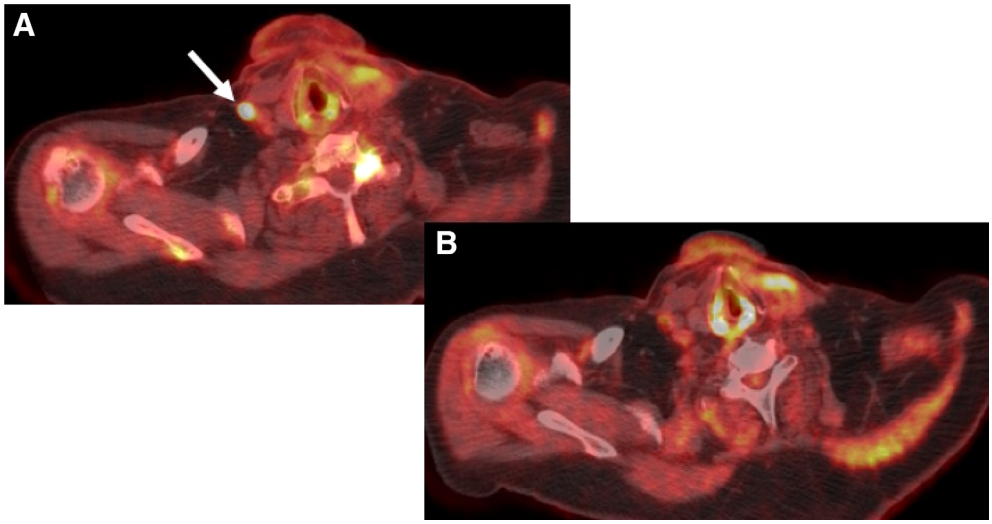

Figure 3. Radiological course of lesion in the second case in axial view. Axial fused positron emission tomography/computed tomography image at baseline **(A)** shows a fluorodeoxyglucose-avid focus in the right neck (arrow), which has resolved on follow-up **(B)**.

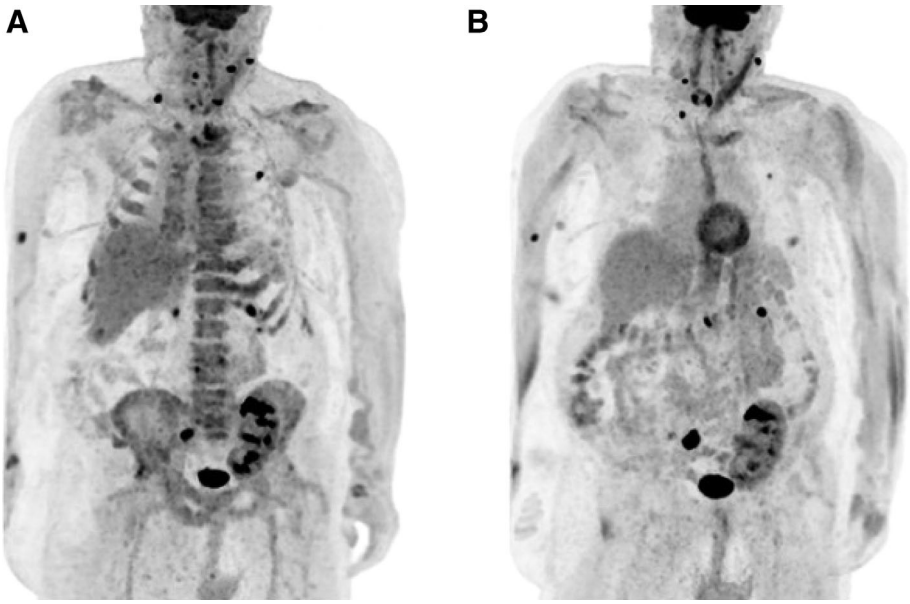

Figure 4. Radiological course of lesion in the second case in coronal view. Coronal maximum-intensity projection image from baseline **(A)** and follow-up **(B)** positron emission tomography/computed tomography show an overall decrease in multiple fluorodeoxyglucose-avid lesions.

Methods

A systematic search in Google Scholar and PubMed databases was carried out using the following key words: immunotherapy, immune checkpoint inhibitors, checkpoint inhibitors, PD-1, PD-L1, CTLA-4, anti-PD-1 therapy, anti-PD-L1 therapy, anti-CTLA-4 therapy, nivolumab, pembrolizumab, ipilimumab, avelumab, durvalumab, atezolizumab, allograft rejection, organ transplant rejection, transplant rejection, and solid organ transplant rejection. We included all published cases of organ transplant patients who received ICI treatment. The chi-square and *t* tests were used to calculate the *p* values to analyze the difference between categorical and continuous variables, respectively. All *p* values were two sided and $p < .05$ was considered statistically significant. For estimation of disease control rates (DCRs) and overall response rates (ORRs), the best responses to ICI that were reported in the case reports or case series were used.

Results

As of January 2019, 64 cases (including the present 2 cases) from 36 case series and case reports were found eligible for the present analysis (Table 1) [13–50, 55]. The median age was 63.8 years (range 14–85) and 75% were males. Most patients had renal allograft (n = 39, 61%), followed by liver (n = 19, 30%) and heart transplant (n = 5, 8%). One patient had a corneal transplant.

Forty-two of the 64 patients (66%) received monotherapy with a PD-1 inhibitor. Twenty patients were initially treated

© AlphaMed Press 2020

with ipilimumab; seven of these were switched to a PD-1 inhibitor after progression on ipilimumab. One patient was treated with combined ipilimumab and nivolumab [35], whereas another one was treated with a PD-L1 inhibitor, avelumab (Table 1). The median time from transplant to treatment with an ICI was 8 years (0.75–32). The patients received a median of 4 cycles (1–4) of ipilimumab or 3 cycles (1–25) of PD-1 inhibitors.

Antitumor Responses by ICI Regimen

The antitumor response to ICI therapy was reported for 56 (88%) patients. The ORR (CR + partial response [PR]) was 36% (20/56) with a DCR (CR + PR + stable disease [SD]) of 45% (25/56), although 55% of patients (n = 31) did not respond to ICIs. Overall, 7 out of 20 patients on ipilimumab responded to therapy, resulting in an ORR of 20% (4/20) and a DCR of 35% (7/20) for ipilimumab. Among seven patients who received an anti-PD-1 inhibitor as second-line ICI (received after ipilimumab failure), two experienced PR, resulting in an ORR and DCR of 29% (2/7). Nivolumab was used as the first-line ICI in 24 patients, whereas 1 patient received nivolumab in combination with ipilimumab. Response was evaluable in 19 patients who received nivolumab as the first-line ICI (either not reported or nonevaluable in 5 patients). The ORR was 26% (5/19) and DCR was 37% (7/19). The single patient who received combination of ipilimumab and nivolumab experienced a CR. After combining patients who received nivolumab as the first- or second-line ICI, ORR was 27% (6/22) and DCR was 36% (8/22). Of 18 patients who received pembrolizumab as first-line ICI, response was not evaluable in 2 patients and was not reported for 1 other case. CR was reported in 5 and PR was reported in 3 patients out of 15 evaluable patients. Therefore, ORR and DCR were similar and were 53% (8/15) among patients who received pembrolizumab as the first-line ICI. The ORR and DCR among patients who received pembrolizumab as first- or second-line ICI were 47% (9/19). Of 56 patients, CR was observed in 6, 3 with melanoma and 3 with SCC.

Antitumor Responses by Immunosuppressive Regimen

At the time of initiation of ICIs, all but one patient (with corneal transplant) were on some type of IS. Of the remaining 63 patients, 29 (46%) received IS with a single agent including prednisone (n = 12, 19%), tacrolimus (n = 10, 16%), sirolimus (n = 4, 6%), or cyclosporine (n = 3, 5%). The response to ICI was reported in 24 of 29 (83%) patients who received a single-agent IS and 31 of 34 patients (91%) who received combination IS. The ORR in patients who received a single-agent IS was 46% (11/24) as compared with an ORR of 29% (9/31) among patients who received combined IS (p = .2). The DCR was 54% (13/24) for patients who received single-agent IS as compared with 35% (11/31) among patients who received combined IS (p = .24). Prednisone alone or in combination was used in 32 (51%) patients. Antitumor responses to ICI were reported in 29 of the 32 (91%) patients who received prednisone and 26 of the 31 patients (84 %) who did not receive prednisone at the time of ICI initiation. The ORR among the patients who received prednisone either as a single agent or in combination versus no prednisone was 41% (12/29) and 27% (7/26), respectively, whereas corresponding DCRs were 48% (14/29) and 38% (10/26), respectively (p = .5 for ORR and p = .3 for DCR).

Incidence of Allograft Rejection

Twenty-six (including corneal transplant) of 64 patients (41%) experienced graft rejection after a median of 2 (range 1–11) doses of a PD-1 inhibitor or a median of 1 (1–2) dose of ipilimumab. There were no differences in the demographic and clinical characteristics of the patients who experienced an episode of allograft rejection as compared with those who did not (Tables 1, 2). Seventeen of 39 (44%) patients with renal allograft experienced graft rejection, whereas 7/19 (39%) with liver allograft and 1/5 (20%) patients with cardiac transplants had rejection of their graft. The highest risk of allograft rejection was seen with PD-1 inhibitors, in which 20/42 (48%) patients experienced graft rejection (13/24 [54%] on nivolumab and 7/18 [39%] on pembrolizumab), followed by patients who received sequential ICIs, 3/7 (43%; Table 2). The risk of rejection was lowest with ipilimumab, in which only 3 of 13 (23%) suffered rejection. The only patient who received combined ipilimumab and nivolumab did not experience rejection of their allograft. Eight (13%) of 64 patients had a history of previous graft rejection. Five of these eight (62.5%) patients had prior allograft rejection following treatment with an ICI. The allograft could be salvaged in 8 of 26 (29%) patients who experienced graft rejection; the remainder of the patients had permanent graft failure (Table 2). The single patient with cornea transplant suffered permanent graft failure after receiving nivolumab. Of the 25 patients who experienced any response to therapy or had stable disease (CR, PR, or SD), 9 (36%) experienced rejection. On the other hand, among 31 patients who did not experience any response to therapy, 11 (35%) experienced rejection. Among 29 patients who received IS with a single agent, 14 (48%) suffered rejection, whereas among 34 patients who received combination IS regimen, only 11 (32%) experienced rejection. Nine of 12 (75%) patients who received only prednisone for IS suffered allograft rejection. In comparison, of 10 patients who received only tacrolimus, 1 (10%) experienced allograft rejection.

None of the variables including age, gender, type of cancer, type of allograft, type of IS, time since transplantation to initiation of ICI, and prior history of rejection were significantly correlated with the transplant rejection on univariate analysis (Table 1).

Discussion

The present two cases add to the existing literature on the experience of ICIs in the solid organ transplant patients. Both patients had renal allografts and both were on combination of IS and received pembrolizumab. Our first case is one of the relatively few patients reported in the literature who had a CR following treatment with pembrolizumab concomitant with IS of tacrolimus and MMF. Whereas our first patient experienced organ rejection after 11 doses of pembrolizumab, the second patient suffered rejection after only 2 doses of pembrolizumab. Both patients underwent kidney biopsy at the time of worsening kidney function, confirming graft rejection, and although both patients witnessed a secondary elevation in their creatinine, only the first patient underwent another kidney biopsy,

 © AlphaMed Press 2020

Table 1. Characteristics of patients with organ transplant who received treatment with an ICI

Characteristics	Total, *n* = 64 (100%)	No rejection, *n* = 38 (59%)	Rejection, *n* = 26 (41%)	*p* value
Gender				
Female	16	10 (63)	6 (37)	.74
Male	48	28 (58)	20 (42)	
Median age (range), years	63.8 (14–85)	65.5 (35–77)	63 (14–85)	.48
Time to immunotherapy since transplant, median (range), years	8 (0.75–32)	8 (0.75–32)	6 (0.75–27.6)	.74
Solid organs				
Kidneys	39	21 (54)	18 (46)	.34
Liver	19	13 (68)	6 (32)	
Heart	5	4 (80)	1 (20)	
Cornea	1	0 (0)	1 (100)	
Type of immunotherapy				
CTLA-4 inhibitor	13	10 (77)	3 (23)	.45
PD-1/PD-L1 inhibitors	43	23 (53)	20 (47)	
Sequential ICIs	8	5 (62.5)	3 (37.5)	
Number of doses, median (range)				
CTLA-4 inhibitors	4 (1–4)	4 (4–4)	1 (1–2)	.88
PD-1 inhibitors	3 (1–25)	4 (1–25)	2 (1–11)	.5
Prior history of significant rejection				
Yes	8	3 (37.5)	5 (62.5)	.36
No	33	19 (57)	14 (43)	
Response to therapy				
Yes	25	16 (62.5)	9 (37.5)	.8
CTLA-4 inhibitors	7	6 (86)	1 (14)	
PD-1/PD-L1 inhibitors	15	9 (60)	6 (40)	
Both	3	1 (33)	2 (66)	
No	31	20 (64.5)	11 (35.5)	
CTLA-4 inhibitors	6	4 (67)	2 (33)	
PD-1/PD-L1 inhibitors	20	12 (60)	8 (40)	
Both	5	4 (80)	1 (20)	
Type of cancer				
Malignant melanoma	37	24 (65)	13(35)	0.23
HCC	10	7 (70)	3 (30)	
Lungs	7	4 (57)	3 (43)	
Others	10	7 (70)	3 (30)	
Type of immunosuppression				
Single agent	29	15 (52)	14 (48)	0.2
Prednisone alone	12	3 (25)	9 (75)	
Tacrolimus alone	10	9 (90)	1 (10)	
Cyclosporine	3	1 (33)	2 (67)	
Sirolimus	4	2 (50)	2 (50)	
Combination	34	23 (68)	11 (32)	
2 drugs combination	28	18 (64)	10 (36)	
3 drugs combination	6	5 (83)	1 (17)	
Tacrolimus alone or in combination	23	15 (65)	8 (35)	
Prednisone alone or in combination	32	20 (62.5)	12 (37.5)	

Abbreviations: CTLA-4, cytotoxic T-lymphocyte-associated antigen-4; HCC, hepatocellular carcinoma; ICIs, immune checkpoint inhibitors; PD-1, programmed death 1; PD-L1, programmed cell death protein 1.

© AlphaMed Press 2020

Table 2. Differences in the profile (for rejection) of immune checkpoint inhibitors among patients with organ transplant

Characteristics	Ipilimumab, 23% (*n* = 13)	Nivolumab, 54.2% (*n* = 24)	Pembrolizumab, 44% (*n* = 18)	Sequential/combination, 37.5% (*n* = 8)
Rate of rejection				
Liver	12.5 (8)	33 (9)	25 (5)	50 (6)
Kidney	50 (4)	67 (12)	55 (12)	0 (1)
Heart	0 (1)	50 (2)	0 (1)	0 (1)
Cornea	0 (0)	100 (1)	0 (0)	0 (0)
Tumor type				
Melanoma	30 (13)	75 (4)	38 (13)	28.5 (7)
NSCLC	0 (0)	57 (7)	0 (0)	0 (0)
HCC	0 (0)	37.5 (8)	0 (2)	0 (0)
Others	0 (0)	60 (5)	100 (3)	100 (1)
Median doses to rejection, median (range)	1 (1–2)	1.5 (1–9)	2 (1–11)	1 (1–7)
Time since transplant to immunotherapy, median (range), years	16 (1.5–26)	5 (0.75–19)	14 (1–27.6)	14 (4–15)
Age, median (range), years	44 (40–67)	59 (14–74)	63.2 (57–85)	68 (48–72)
Type of immunosuppression				
Single agent	37.5 (8)	60 (10)	43 (7)	50 (4)
Prednisone	60 (5)	100 (3)	50 (2)	100 (2)
Tacrolimus	0 (2)	20 (5)	0 (2)	0 (1)
Cyclosporine	0 (0)	0 (0)	67 (3)	0 (0)
Sirolimus	0 (1)	100 (2)	0 (0)	0 (1)
Combination	0 (5)	56 (13)	44 (11)	25 (4)
2 drugs combination	0 (3)	42 (12)	50 (9)	50 (2)
3 drugs combination	0 (2)	100 (1)	0 (2)	0 (2)
Tacrolimus alone or in combination	0 (2)	56 (11)	17 (6)	33 (3)
Prednisone alone or in combination	30 (10)	56 (9)	33 (8)	40 (5)

Data are presented as % of rejection (total patients received) unless otherwise indicated.
Abbreviations: HCC, hepatocellular carcinoma; NSCLC, non-small cell lung cancer.

which again showed pembrolizumab induced allograft cellular rejection. Fortunately, the allograft could be salvaged in both the patients.

Our pooled analysis reaffirms previous observations of high rates (∼40%) of allograft rejection in patients with cancer who were treated with an ICI leading to organ failure in 71% of the patients who experienced rejection. This should be discussed with patients clearly before the initiation of treatment, and these patients should be monitored closely for signs of rejection.

Our pooled analysis reaffirms previous observations of high rates (∼40%) of allograft rejection in patients with cancer who were treated with an ICI leading to organ failure in 71% of the patients who experienced rejection. This should be discussed with patients clearly before the initiation of treatment, and these patients should be monitored closely for signs of rejection.

Both CTLA-4 and PD-1/PD-L1 play a key role in immunotolerance required for allograft survival [8, 9]. In a mouse model, the injection of anti-CTLA-4 immunoglobulin in the perioperative period led to acute rejection of liver allograft but did not have any effect on graft survival when it was injected after the establishment of peripheral tolerance [8]. On the contrary, the early infusion of anti PD-1 antibodies prevented induction of peripheral tolerance, and infusion at a later stage led to complete loss of allograft [51]. Although this has not been proved in humans, these findings are consistent with the observation of a higher risk of graft rejection with anti PD-1 antibodies, which has also been found in prior reports [13].

Despite the fact that none of the variables we analyzed were associated with allograft rejection (this could be due to small sample size), several findings from the present analysis are notable. The choice of IS was associated with graft rejection. Four classes of drugs are available for the maintenance of IS after renal transplant, including corticosteroids; antimetabolites (azathioprine and MMF/mycophenolate sodium), which inhibit DNA synthesis, thereby preventing cell replication; CNIs

 © AlphaMed Press 2020

(cyclosporine and tacrolimus) that halt the progression of T cells from the G0 to G1 phase; and mTOR inhibitors (sirolimus and everolimus), which inhibit progression of late activation to synthesis phase of cell cycle. As these agents act at different steps in the cell cycle, they are frequently combined to achieve optimal IS [52]. In most of the patients in our analysis, the IS regimen was further altered at the time of initiation of treatment with an ICI. Many patients received only low-dose prednisone when they were initiated on an ICI. The majority of these patients had graft rejection, consistent with previous reports [19]. Therefore, IS with low-dose prednisone alone seems to be insufficient in transplant patients who require treatment with an ICI. Patients who received tacrolimus-based regimens or combinations of IS agents had lower rates of allograft rejection. Although there is a concern about compromising the efficacy of ICI against the cancer with IS, it is noteworthy that many patients, including the two cases we report here, who received combination immunosuppression at the time of ICI initiation responded to immunotherapy. Importantly, patients with cardiac or liver allografts were mostly maintained on tacrolimus either as standalone or as a combination IS because of the lack of an alternative treatment in cases of allograft failures. These patients also experienced response to ICIs.

The majority of patients received only high-dose steroids without any other agent for treatment of acute graft rejection. The treatment of acute rejection in kidney transplant patients is based upon the severity on Banff grading [12]. Although high-dose steroids alone may be adequate for Banff grade I, grade II and III require additional IS with antithymocyte globulin or alemtuzumab [53]. The most common form of rejection was cellular; however, a mixed (cellular and humoral) form of rejection was also reported in some cases [14, 21], which warrants a different class of IS treatment against the humoral rejection including IVIG and plasmapheresis [53].

The other factor that was observed to be associated with allograft rejection based on the current analysis is prior history of significant allograft rejection with at least 2/3 of those patients suffering allograft rejection after treatment with ICIs. Therefore, patients with previous allograft rejection may require more robust IS with tacrolimus-based regimens or combination regimen and should be followed closely.

PDL-1 expression on the allograft lymphocytes has been suggested as a marker of rejection after treatment with ICIs [19, 21]. The small number of liver transplant patients (n = 3) without expression of PD-L1 on allograft lymphocytes did not experience graft rejection, whereas all four patients with PD-L1 expression on allograft lymphocytes suffered rejection [19]. Although this approach may have value, it needs to be validated in larger studies. Moreover, PD-L1 expression was analyzed only after treatment with ICI, which could have been driven by immune activation, and more information is needed on pre-ICI PD-L1 expression.

Although the majority of graft rejections happened after 1–2 doses of ICIs, we did not find any association between number of doses of ICIs or time from transplant to commencement of ICI treatment and rate of rejection. This could be due to small number of patients, but it is also possible that the loss of immunotolerance secondary to ICI is dose and time independent. Therefore, providers should remain vigilant throughout the ICI treatment for early detection and treatment of graft rejection. The treatment in our first case was continued for much longer after achieving CR. This was done after weighing the risk of transplant rejection over recurrence of a life-threatening malignancy. However, in light of present analysis, another approach could be to stop ICs in patients who achieve a response and rechallenge up on progression of disease.

Although the majority of graft rejections happened after 1–2 doses of ICIs, we did not find any association between number of doses of ICIs or time from transplant to commencement of ICI treatment and rate of rejection. This could be due to small number of patients, but it is also possible that the loss of immunotolerance secondary to ICI is dose and time independent.

The observations from this analysis should be interpreted in light of the following limitations: the small sample size, limiting meaningful multivariate statistical analysis; the data were obtained from published individual case reports and therefore are heterogeneous and raise the possibility of selection bias; and the retrospective nature of the analysis did not allow for the testing of predictive immune biomarkers.

Accordingly, prospective studies using ICIs in organ transplanted patients with cancer are needed. The only prospective study reported to date is a small phase I clinical trial [54] testing the safety of nivolumab in four renal transplant recipients with multiple myeloma, head and neck SCC, renal cell carcinoma, and bladder cancer. The patients were required to have a serum creatinine of <180 μmol/L and absence of human leukocyte antigen donor-specific antibodies (DSAs). Patients received one, two, three, and nine doses of nivolumab, respectively. None of the patients had a graft rejection, and only one patient (who received nine doses) experienced a partial response. Although the study was small, the safety profile of nivolumab among selected patients of renal transplant without DSA appears to be encouraging and warrants testing on a larger-scale trial. Another phase I trial [56] is open and accruing patients with renal transplant diagnosed with unresectable or metastatic cutaneous melanoma or Merkle cell carcinoma to receive prednisone, tacrolimus, and nivolumab with the addition of ipilimumab up on progression of disease. The primary endpoint of the study is response rate at 16 weeks among patients without allograft loss [NCT03816332].

Further studies should focus on identifying an optimal IS regimen, which could be given effectively with ICIs without blunting their therapeutic effects. The role of prior history of allograft transplant, presence of DSA, and PD-L1 expression on allograft lymphocytes in addition to novel biomarkers in predicting rejection should be explored further. Long-term data on recurrent malignancies among patients who could maintain residual organ function following immunosuppression for rejection should be collected and reported. Transplant registries and Medicare-linked Surveillance, Epidemiology, and End Results database could be useful sources of data for such analyses.

© AlphaMed Press 2020

Conclusion

The efficacy of ICI among patients with organ transplant appears promising, which warrants testing in prospective clinical trials. However, the risk of rejection and allograft loss is considerable; therefore, the risk and alternative form of therapies should be thoroughly discussed with the transplant patients prior to initiating ICI therapy. Although none of the clinical factors could predict the risk of rejection, the role of concomitant immunosuppression and a prior history of transplant rejection warrants further testing. Importantly, the loss of allograft is idiosyncratic, and therefore, a high index of suspicion is required throughout the course of ICI.

Author Contributions

Conception/design: Vivek Kumar, Patrick A. Ott, Osama E. Rahma
Provision of study material or patients: Vivek Kumar, Atul B. Shinagare, Helmut G. Rennke, Sandeep Ghai, Jochen H. Lorch, Patrick A. Ott
Collection and/or assembly of data: Vivek Kumar, Atul B. Shinagare, Helmut G. Rennke, Sandeep Ghai, Jochen H. Lorch, Patrick A. Ott
Data analysis and interpretation: Vivek Kumar, Osama E. Rahma
Manuscript writing: Vivek Kumar, Atul B. Shinagare, Helmut G. Rennke, Sandeep Ghai, Jochen H. Lorch, Patrick A. Ott, Osama E. Rahma
Final approval of manuscript: Vivek Kumar, Atul B. Shinagare, Helmut G. Rennke, Sandeep Ghai, Jochen H. Lorch, Patrick A. Ott, Osama E. Rahma

Disclosures

Atul B. Shinagare: Arog Pharmaceuticals, Virtualscopics (C/A); **Jochen H. Lorch:** Novartis, Bayer, Takeda, Bristol-Myers Squibb (RF [to institution]), Genentech, Bayer (SAB); **Patrick A. Ott:** Bristol-Myers Squibb, Merck, Neon Therapeutics, Celldex, ArmoBiosciences, AstraZeneca/MedImmune, Novartis, Pfizer, CytomX, Xencor, Genentech (RF); Merck, Bristol-Myers Squibb, Genentech, Novartis, Pfizer, Neon Therapeutics, Celldex, CytomX, Array (C/A). The other authors indicated no financial relationships.

(C/A) Consulting/advisory relationship; (RF) Research funding; (E) Employment; (ET) Expert testimony; (H) Honoraria received; (OI) Ownership interests; (IP) Intellectual property rights/inventor/patent holder; (SAB) Scientific advisory board

References

1. Ipilimumab [package insert]. Princeton, NJ: Bristol-Myers Squibb Company; 2018.
2. Durvalumab [package insert]. Wilmington, DE: AstraZeneca Pharmaceuticals; 2018.
3. Pembrolizumab [package insert]. Whitehouse Station, NJ: Merck & Co., Inc.; 2018.
4. Atezolizumab [package insert]. South San Francisco, CA: Genentech, Inc.; 2018.
5. Kumar V, Chaudhary N, Garg M et al. Current diagnosis and management of immune related adverse events (irAEs) induced by immune checkpoint inhibitor therapy. Front Pharmacol 2017;8:49.
6. Topalian SL, Drake CG, Pardoll DM. Immune checkpoint blockade: A common denominator approach to cancer therapy. Cancer Cell 2015;27:450–461.
7. Brahmer JR, Tykodi SS, Chow LQ et al. Safety and activity of anti–PD-L1 antibody in patients with advanced cancer. N Engl J Med 2012;366:2455–2465.
8. Judge TA, Wu Z, Zheng XG et al. The role of CD80, CD86, and CTLA4 in alloimmune responses and the induction of long-term allograft survival. J Immunol 1999;162:1947–1951.
9. Li W, Zheng XX, Kuhr CS et al. CTLA4 engagement is required for induction of murine liver transplant spontaneous tolerance. Am J Transplant 2005;5:978–986.
10. Engels EA, Pfeiffer RM, Fraumeni JF et al. Spectrum of cancer risk among US solid organ transplant recipients. JAMA 2011;306:1891–1901.
11. Chapman JR, Webster AC, Wong G. Cancer in the transplant recipient. Cold Spring Harb Perspect Med 2013;3:a015677.
12. Demetris AJ, Batts KP, Dhillon AP et al. Banff schema for grading liver allograft rejection: An international consensus document. Hepatology 1997;25:658–663.
13. Aguirre LE, Guzman ME, Lopes G et al. Immune checkpoint inhibitors and the risk of allograft rejection: A comprehensive analysis on an emerging issue. ***The Oncologist*** 2019;24:394–401.
14. Alhamad T, Venkatachalam K, Linette GP et al. Checkpoint inhibitors in kidney transplant recipients and the potential risk of rejection. Am J Transplant 2016;16:1332–1333.
15. Barnett R, Barta VS, Jhaveri KD. Preserved renal-allograft function and the PD-1 pathway inhibitor nivolumab. N Engl J Med 2017;376:191–192.
16. Biondani P, De Martin E, Samuel D. Safety of an anti-PD-1 immune checkpoint inhibitor in a liver transplant recipient. Ann Oncol 2018;29:286–287.
17. Boils CL, Aljadir DN, Cantafio AW. Use of the PD-1 pathway inhibitor nivolumab in a renal transplant patient with malignancy. Am J Transplant 2016;16:2496–2497.
18. De Toni EN, Gerbes AL. Tapering of immunosuppression and sustained treatment with nivolumab in a liver transplant recipient. Gastroenterology 2017;152:1631–1633.
19. DeLeon TT, Salomao MA, Aqel BA et al. Pilot evaluation of PD-1 inhibition in metastatic cancer patients with a history of liver transplantation: The Mayo Clinic experience. J Gastrointest Oncol 2018;9:1054–1062.
20. Dueland S, Guren T, Boberg K et al. Acute liver graft rejection after ipilimumab therapy. Ann Oncol 2017;28:2619–2620.
21. Friend BD, Venick RS, McDiarmid SV et al. Fatal orthotopic liver transplant organ rejection induced by a checkpoint inhibitor in two patients with refractory, metastatic hepatocellular carcinoma. Pediatr Blood Cancer 2017;64:e26682.
22. Garant A, Guilbault C, Ekmekjian T et al. Concomitant use of corticosteroids and immune checkpoint inhibitors in patients with hematologic or solid neoplasms: A systematic review. Crit Rev Oncol Hematol 2017;120:86–92.
23. Gastman BR, Ernstoff MS. Tolerability of immune checkpoint inhibition cancer therapy in a cardiac transplant patient. Ann Oncol 2016;27:2304–2305.
24. Goldman JW, Abdalla B, Mendenhall MA et al. PD 1 checkpoint inhibition in solid organ transplants: 2 sides of a coin–case report. BMC Nephrol 2018;19:210.
25. Grant MJ, DeVito N, Salama AKS. Checkpoint inhibitor use in two heart transplant patients with metastatic melanoma and review of high-risk populations. Melanoma Manag 2018;5:MMT10.
26. Herz S, Hofer T, Papapanagiotou M et al. Checkpoint inhibitors in chronic kidney failure and an organ transplant recipient. Eur J Cancer 2016;67:66–72.
27. Jose A, Yiannoullou P, Bhutani S et al. Renal allograft failure after ipilimumab therapy for metastatic melanoma: A case report and review of the literature. Transplant Proc 2016;48:3137–3141.
28. Kittai AS, Oldham H, Cetnar J, et al. Immune checkpoint inhibitors in organ transplant patients. J Immunother 2017;40:277–281.
29. Kuo JC, Lilly LB, Hogg D. Immune checkpoint inhibitor therapy in a liver transplant recipient with a rare subtype of melanoma: A case report and literature review. Melanoma Res 2018;28:61–64.
30. Kwatra V, Karanth NV, Priyadarshana K et al. Pembrolizumab for metastatic melanoma in a renal allograft recipient with subsequent graft rejection and treatment response failure: A case report. J Med Case Rep 2017;11:73.
31. Le Fournis S, Gohier P, Urban T et al. Corneal graft rejection in a patient treated with nivolumab for primary lung cancer. Lung Cancer 2016;102:28–29.
32. Lesouhaitier M, Dudreuilh C, Tamain M et al. Checkpoint blockade after kidney transplantation. Eur J Cancer 2018;96:111–114.
33. Lipson EJ, Bagnasco SM, Moore J et al. Tumor regression and allograft rejection after administration of anti–PD-1. N Engl J Med 2016;374:896–898.
34. Lipson EJ, Bodell MA, Kraus ES et al. Successful administration of ipilimumab to two kidney transplantation patients with metastatic melanoma. J Clin Oncol 2014;32:e69–e71.
35. Miller DM, Faulkner-Jones BE, Stone JR et al. Complete pathologic response of metastatic cutaneous squamous cell carcinoma and allograft rejection after treatment with combination immune checkpoint blockade. JAAD Case Rep 2017;3:412–415.
36. Morales RE, Shoushtari AN, Walsh MM et al. Safety and efficacy of ipilimumab to treat advanced melanoma in the setting of liver transplantation. J Immunother Cancer 2015;3:22.

 © AlphaMed Press 2020

37. Morita M, Fujino M, Jiang G et al. PD-1/B7-H1 interaction contribute to the spontaneous acceptance of mouse liver allograft. Am J Transplant 2010;10:40–46.

38. Ong M, Ibrahim AM, Bourassa-Blanchette S et al. Antitumor activity of nivolumab on hemodialysis after renal allograft rejection. J Immunother Cancer 2016;4:64.

39. Owonikoko TK, Kumar M, Yang S et al. Cardiac allograft rejection as a complication of PD-1 checkpoint blockade for cancer immunotherapy: A case report. Cancer Immunol Immunother 2017;66:45–50.

40. Qin R, Salama AK. Report of ipilimumab in a heart transplant patient with metastatic melanoma on tacrolimus. Melanoma Manag 2015;2:311–314.

41. Rai R, Ezeoke O, McQuade J et al. 1148PDImmunotherapy in patients with concurrent solid organ transplant, HIV, and Hepatitis B and C. Ann Oncol 2017;28(suppl 5).

42. Ranganath HA, Panella TJ. Administration of ipilimumab to a liver transplant recipient with unresectable metastatic melanoma. J Immunother 2015;38:211.

43. Sadaat M, Jang S. Complete tumor response to pembrolizumab and allograft preservation in renal allograft recipient on immunosuppressive therapy. J Oncol Pract 2017;14:198–199.

44. Schvartsman G, Perez K, Sood G et al. Immune checkpoint inhibitor therapy in a liver transplant recipient with melanoma. Ann Intern Med 2017;167:361–362.

45. Spain L, Higgins R, Gopalakrishnan K et al. Acute renal allograft rejection after immune checkpoint inhibitor therapy for metastatic melanoma. Ann Oncol 2016;27:1135–1137.

46. Tamain M, Garrouste C, Aguilera D et al. Mixed acute kidney allograft rejection after an antiprogrammed cell death protein 1 antibody treatment for lung epidermoid carcinoma. Transpl Int 2016;29:1247–1248.

47. Tio M, Rai R, Ezeoke OM et al. Anti-PD-1/PD-L1 immunotherapy in patients with solid organ transplant, HIV or hepatitis B/C infection. Eur J Cancer 2018;104:137–144.

48. Varkaris A, Lewis DW, Nugent FW. Preserved liver transplant after PD-1 pathway inhibitor for hepatocellular carcinoma. Am J Gastroenterol 2017;112:1895–1896.

49. Winkler JK, Gutzmer R, Bender C et al. Safe Administration of an anti-PD-1 antibody to kidney-transplant patients: 2 clinical cases and review of the literature. J Immunother 2017;40:341–344.

50. Zehou O, Leibler C, Arnault JP et al. Ipilimumab for the treatment of advanced melanoma in six kidney transplant patients. Am J Transplant 2018;18:3065–3071.

51. Tanaka K, Albin MJ, Yuan X et al. PDL1 is required for peripheral transplantation tolerance and protection from chronic allograft rejection. J Immunol 2007;179:5204–5210.

52. Dalal P, Shah G, Chhabra D et al. Role of tacrolimus combination therapy with mycophenolate mofetil in the prevention of organ rejection in kidney transplant patients. Int J Nephrol Renovasc Dis 2010;3:107–115.

53. Brennan DC, Malone A, Legendre C. Treatment of acute T cell-mediated (cellular) rejection of the renal allograft. Available at https://www.uptodate.com/contents/treatment-of-acute-t-cell-mediated-cellular-rejection-of-the-renal-allograft#references. Accessed March 15, 2019.

54. Carroll R, Zalcberg J, Tang H. 1208P PD-1 blockade in renal transplant patients with poor prognosis cancer and minimizing risk of organ rejection using comprehensive immune monitoring and screening techniques: A safety study. Ann Oncol 2018;29(suppl 8):viii400–viii441.

55. Rammohan A, Reddy MS, Farouk M et al. Pembrolizumab for metastatic hepatocellular carcinoma following live donor liver transplantation: The silver bullet? Hepatology 2018;67:1166–1168.

56. Tacrolimus, nivolumab, and ipilimumab in treating kidney transplant recipients with selected unresectable or metastatic cancers. Available at https://clinicaltrials.gov/ct2/show/NCT03816332. Accessed June 30, 2019.

© AlphaMed Press 2020