Case reports

Pulmonary barotrauma: a case report with illustrative radiology

Sarah Bigeni[1], Mario Saliba[1]

[1] *Hyperbaric Unit, Gozo General Hospital, Malta*

Corresponding author: *Dr Sarah Bigeni, Medical Consultant, Hyperbaric Unit, Gozo General Hospital, Ghajn Qatet Street, Victoria VCT2520, Malta*
sarah.bigeni@gov.mt

Key words
Pulmonary barotrauma; Diving; Pneumothorax; CT scan

Abstract

(Bigeni S, Saliba M. Pulmonary barotrauma: a case report with illustrative radiology. Diving and Hyperbaric Medicine. 2020 March 31;50(1):66–69. doi: 10.28920/dhm50.1.66-69. PMID: 32187620.)
A case of a 24-year-old gentleman who had pulmonary barotrauma (PBT) after diving is reported. He presented with chest pain after the second of two uneventful shallow SCUBA dives. Computerized tomography (CT) scan confirmed the diagnosis and he was treated conservatively. Relevant radiology and a discussion of PBT are presented.

Introduction

Barotrauma refers to the injuries that may occur in gas-containing compartments of the body when there is a pressure change. To understand how barotrauma occurs, certain laws of physics have to be applied. According to Boyle's Law, as the pressure decreases, the volume of a gas space increases and vice versa ($P_1V_1=P_2V_2$). When a diver starts ascending from a dive, the ambient pressure decreases and the volume in gas-filled spaces such as the lungs would increase.[1] Consequently, a golden rule of SCUBA diving is to never breath-hold. As the ambient pressure decreases during ascent, the compressed gas in the lungs expands and this gas needs to be exhaled. The lungs are insensate when over-expanded.[2] Thus, the scuba diver has no warning to prevent lung injury if breath-holding on ascent. Unlike SCUBA diving, pulmonary barotrauma in breath-hold-diving is extremely unlikely since a 'lungful' of gas inhaled at the surface is compressed during descent, and simply re-expands safely to its original volume on ascent.[3]

Case report

The patient provided written consent for his case and radiology to be reported. A 24-year-old male presented to the accident and emergency department in Gozo General Hospital complaining of chest pain. During the day, he had done SCUBA dives and had no symptoms during the first dive which was at 6 metres' sea water (msw) for 20 minutes. His second dive was at 12 msw for twenty minutes. He was a novice diver who smoked 20 cigarettes a day.

About two and a half hours after surfacing from the second dive, he started complaining of chest tightness. He then noticed 'bubbles under the skin' at the left base of his neck associated with discomfort. He came to the emergency department with persisting chest tightness and increasing severity of the neck pain. He denied any other symptoms such as shortness of breath, cough, and haemoptysis. Examination of his cardiovascular, respiratory and neurological systems was normal. Blood pressure was stable at 130/70 mmHg with a regular pulse of 83 beats/min. Hamman's sign (a cracking sound heard over the precordium during systole) was negative. He was afebrile and oxygen saturation on air was 99%.

A chest X-ray showed no pneumothorax, however, there was left subcutaneous emphysema in the left axillary area and pneumomediastinum (Figure 1). Although there were no obvious precipitating events during the dives (such as a rapid panic ascent) the gas was presumed to have arisen from pulmonary barotrauma (PBT) during diving. He was admitted to the male general ward for observation. He was started on intravenous crystalloid fluids and high flow oxygen. After 24 hours, his chest discomfort persisted. All other investigations came back within the normal range (blood results including troponins and D-dimer, and ECG). Thus, further imaging was requested because of the persisting symptoms and to exclude pneumothorax, in which case, he would be unfit to fly home immediately.

A CT scan revealed the presence of a pneumomediastinum, minimal pneumothorax on the right side and subcutaneous emphysema in the neck and chest wall on the left side more than on the right side (Figures 2–7).

He was reviewed by the surgeons and treated conservatively. His subcutaneous emphysema disappeared after two days

Figure 1
Chest X-ray performed in the emergency department showing left axillary subcutaneous emphysema and pneumomediastinum (arrows)

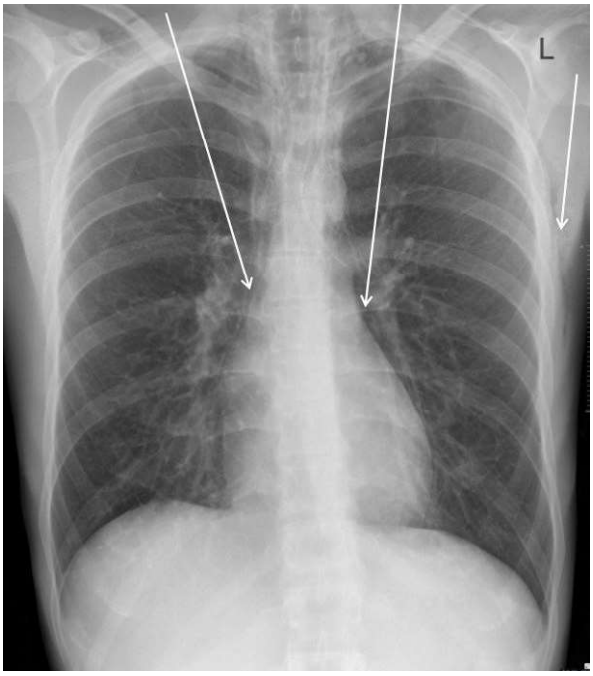

Figure 2
Sagittal section of CT scan showing the effects of pulmonary barotrauma: air leaks shown as a radio-lucent outline in the mediastinum and subcutaneous emphysema (arrows) present in the left axilla and neck

and he was fit for discharge. He was advised not to dive again since PBT is often considered a contraindication for diving. This was not an issue with this novice diver since he still had not acquired a passion for diving. He was supposed to fly back home three days after the event but was strongly advised against it. He flew back home after two weeks with no complications.

Figure 3
Pneumomediastinum and surgical emphysema (arrows) at the level of the great vessels

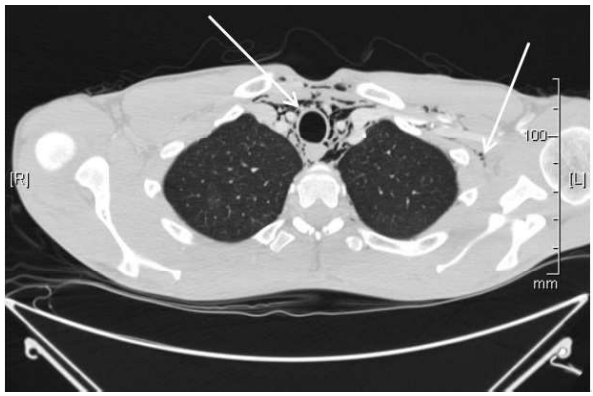

Figure 4
Pneumomediastinum and subcutaneous emphysema (arrows) at the level of the 2nd thoracic vertebral body

Discussion

PBT is damage to the lung parenchyma caused by an increase in pulmonary gas volume during a decrease in ambient pressure. PBT may occur in the following scenarios: involuntary laryngospasm on ascent which can be caused in loss of consciousness or panic; intentional or involuntary breath-holding while ascending (even if it's for a short period e.g., coughing), a sudden increase in the volume of gas supplied by SCUBA equipment, and during a fast ascent.[4] As in this case, PBT is often seen in novice divers; probably because they hold their breath.

Multiple symptoms can occur in patients suffering from PBT. These include discomfort due to minor degrees of pneumomediastinum or pneumothorax, through to life-threatening arterial gas embolism (AGE).[5] It was also noted in a study that recurrent PBT tends to be worse than the first incident and more likely to include AGE.[6]

Figure 5
Pneumomediastinum with subcutaneous emphysema (arrows) at the level of the bifurcation of the right bronchus

Figure 6
Pneumomediastinum (arrow) at the 5th thoracic vertebral body

Figure 7
Small right sided pneumothorax (arrow) at the level of the diaphragm

There may be predisposing factors for PBT. Conditions that increase air trapping in the lungs resulting in a degree of obstruction and parenchymal disease with regional differences in the level of compliance have been implicated in promoting pulmonary barotrauma.[7] Obstruction of the bronchi is frequent in asthma, acute and chronic bronchitis, respiratory tract infections, tuberculosis, tumours of the lung, calcified glands, cysts in the lung, and emphysema. Heavy smoking may obstruct the airways by increasing the formation of mucous plugs. Obstructions may act like a ball valve, allowing air to enter the lungs but restricting its exit.[8] Although certain respiratory conditions are thought to increase risk of PBT, in most cases, no respiratory predisposing factor is found.

Previously, it was recommended that prior to air travel there should be a six week wait after complete resolution of a pneumothorax but this has been abandoned.[9] Current guidelines are based on sparse data but recommend postponing air travel for one to three weeks after full resolution of the pneumothorax.[10]

Conclusions

In this patient, the cause of PBT was probably breath-holding. PBT can occur in someone without predisposing factors, however, smoking affects the lungs and the airways in such a way that it may increase the risk of PBT.

Chest X-ray was useful in diagnosing subcutaneous emphysema but a CT scan provides higher sensitivity in detecting the extent of the PBT.

References

1 Cunha JP. Barotrauma and decompression sickness. Available from: https://www.emedicinehealth.com/barotraumadecompression_sickness/article_em.htm. [cited 2019 July 10].
2 Aircraft operations at altitudes above 25,000 feet mean sea level or mach numbers greater than 75. Advisory Circular 61-107B. US Department of Transportation Federal Aviation Administration. Available from: https://www.faa.gov/documentLibrary/media/Advisory_Circular/AC_61-107B_CHG_1_FAA.pdf. [cited 2019 July 15].
3 Neuman TS. Arterial gas embolism and pulmonary barotrauma. In: Brubakk AO, Neuman TS, editors. Bennett and Elliott's physiology and medicine of diving, 5th ed. Philadephia: Saunders; 2003. p. 557.
4 Siermontowski P, Kozlowski W, Pedrycz A, Krefft K, Kaczerska D. Experimental modelling of pulmonary barotrauma. Undersea Hyperb Med. 2015;42:143–9. PMID: 26094289.
5 Leitch DR, Green RD. Pulmonary barotrauma in divers and the treatment of cerebral arterial gas embolism. Aviat Space Environ Med 1986;57:931–8. PMID: 3778391.
6 Leitch DR, Green RD. Recurrent pulmonary barotrauma. Aviat Space Environ Med. 1986;57:1039–43. PMID: 3790021.
7 Russi EW. Diving and the risk of barotrauma. Thorax. 1998;53(Suppl 2):S20–4. doi: 10.1136/thx.53.2008.s20. PMID: 10193343. PMCID: PMC1765901.
8 Maximum safety of human beings in relation with the sea. Cyprus Federation of Under Water Activities. Available from: http://cfua.org/Pulmonary-Barotrauma.htm. [cited 2019 July 5].

9 Coker R. BTS updates advice on air travel for patients with respiratory disease. Available from: https://www.guidelinesinpractice.co.uk/bts-updates-advice-on-air-travel-for-patients-with-respiratory-disease/300746.article. [cited 2019 July 5].
10 Hu X, Cowl CT, Baqir M, Ryu JH. Air travel and pneumothorax. Chest. 2014;145:688–94. doi: 10.1378/chest.13-2363. PMID: 24687705.

Conflicts of interest and funding: nil

Submitted: 19 July 2019
Accepted after revision: 06 November 2019

Copyright: This article is the copyright of the authors who grant *Diving and Hyperbaric Medicine* a non-exclusive licence to publish the article in electronic and other forms.