CLINICAL MEDICINE

Postvasectomy Scrotal Pain and Hematospermia, a Possible Harbinger for Vasectomy Failure and Recanalization: A Case Report

Tyler Kern, MD[1]; Daniel Artenstein, MD[1]; Charles Shapiro, MD[1]

Perm J 2020;24:19.068

E-pub: 11/08/2019

https://doi.org/10.7812/TPP/19.068

ABSTRACT

Introduction: Vasectomy is the most common and most effective method of achieving permanent male sterility. However, there is a low risk of vasectomy failure. To our knowledge, there is no symptom complex that has been identified and described that is predictive of early recanalization and vasectomy failure.

Case Presentation: A 44-year-old man underwent a routine bilateral vasectomy without complication. Two months after the procedure, the patient experienced an acute onset of scrotal pain and hematospermia. Several semen analyses were performed during the following months, the results of which demonstrated progressively rising numbers of motile sperm and were indicative of vasal recanalization. The patient underwent repeated vasectomy, during which he was found to have right vasal recanalization leading to vasectomy failure.

Discussion: Delayed postvasectomy scrotal pain associated with hematospermia may be a sign of vasal recanalization. We propose that this symptom complex should prompt an investigation for vasal recanalization, during which the patient should be instructed to refrain from intercourse without the use of an additional method of contraception.

INTRODUCTION

Vasectomy is the most common and effective method of achieving permanent male sterility. In 2002, an estimated 526,501 vasectomies were performed in the US.[1] In 2004, nearly 43 million men worldwide underwent vasectomy.[2] Vasectomies are routinely performed in the outpatient setting under local anesthesia. Vasectomies are typically performed by urologists but may also be performed by family medicine physicians or general surgeons. Although there are various vasectomy techniques, it remains a highly effective procedure regardless of the technique performed, with pregnancy rates of 0.10% to 0.15% within the first year after vasectomy.[3] Vasectomy complications are relatively uncommon and include infection, epididymitis, hemorrhage, and sperm granuloma. Each of these complications occurs in less than 5% of cases.[2,4]

A vasectomy does not result in immediate sterility because residual sperm are located throughout the vas deferens and seminal vesicles. Patients are instructed to use an additional method of contraception during intercourse until a postvasectomy semen analysis demonstrates the absence of motile sperm. Men are typically instructed to submit a semen analysis 3 months postoperatively. If sperm are present on the semen analysis, a series of repeated studies will be performed to trend the sperm count.

Physicians should inform patients interested in a vasectomy that although the procedure typically results in permanent sterilization, there is a risk of vasectomy failure. Vasectomy failure may result from failure to divide the vas deferens bilaterally (ie, division of an incorrect structure, incomplete transection of the vas), vasal recanalization, or anatomic variations that are unrecognized at the time of vasectomy (ie, vasal duplication). Failure can be defined by the presence of motile sperm on postvasectomy semen analysis or unexpected postvasectomy pregnancy. Early failure or recanalization of the vas deferens after vasectomy occurs in approximately 0.3% to 0.6% of cases.[5] This failure occurs when a substantial number of spermatozoa or any motile spermatozoa are identified at least 4 months after vasectomy. To our knowledge, there is no symptom complex that has been identified or described that is predictive of early recanalization after vasectomy. We report a case of vasectomy failure in which the patient exhibited possible early signs of vasal recanalization.

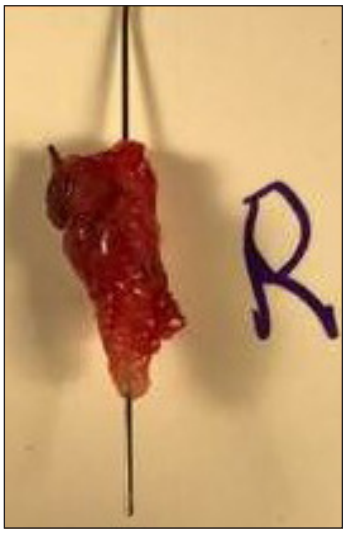

Figure 1. Excised portion of the right vasectomy site with a patent lumen, which is demonstrated by accommodation of a lacrimal duct probe.

CASE PRESENTATION

Presenting Concerns

A 44-year-old man with no remarkable medical history elected to undergo a bilateral vasectomy by a high-volume urologic surgeon, who has performed approximately 5000 vasectomies. The routine clinic procedure was performed in the following manner: Bilateral transverse scrotal incisions, excision of a portion of each vas, mucosal cauterization of all 4 vasal ends, and nylon suture ligation without fascial interposition. The 2 excised specimens were sent for pathologic analysis, and the results revealed completely transected segments of bilateral vas deferens. There were no significant histopathologic abnormalities, and the length of excised vas deferens from the left and right was 0.5 cm and 0.6 cm, respectively.

Author Affiliations

[1] Department of Urology, Kaiser Permanente Los Angeles Medical Center, CA

Corresponding Author

Tyler Kern, MD (tyler.kern@kp.org)

Keywords: hematospermia, post-vasectomy, postvasectomy, post-vasectomy scrotal pain, postvasectomy scrotal pain, vasal recanalization, vasectomy, vasectomy failure

The Permanente Journal • For personal use only. No other uses without permission. Copyright © 2019 The Permanente Press. All rights reserved.

Table 1. Semen analyses performed after initial vasectomy

Time after initial vasectomy, mo	Sperm count (0-3 sperm/HPF)	Total sperm count, million	Spermatozoa motility
2	4-20	Not available	Nonmotile
4	> 20	88	Normal motility
5	Not available	192	Normal motility
6	Not available	60	Normal motility

HPF = high-power field.

Table 2. Semen analyses performed after repeated vasectomy

Time after repeated vasectomy, mo	Sperm count (0-3 sperm/HPF)	Spermatozoa motility
2	0	Not applicable
4	0-3	Nonmotile
6	0-3	Nonmotile
7	0	Not applicable

HPF = high-power field.

Two months after the procedure, the patient presented with a 6-day history of acute, right-sided scrotal pain and hematospermia. The patient reported that the pain was most prominent superior to the right testicle and in the right-sided inguinal region. He denied prior episodes of hematospermia, hematuria, and dysuria. On examination, the patient exhibited tenderness over the right vasectomy site, which on palpation reproduced the pain that he described. Semen analysis findings 13 days after the pain and hematospermia episode revealed 4 to 20 nonmotile sperm per high-power field (Table 1). Two months later, a repeated semen analysis result revealed more than 20 motile sperm per high-power field, indicating vasectomy failure (Table 1).

Results of 2 subsequent semen analyses are also documented in Table 1. Normalization of semen parameters (Table 1) was indicative of vasal recanalization.

Table 3. Timeline of the Case

Relevant Medical History and Interventions
A 44-year-old man with no remarkable medical history elected to undergo a bilateral vasectomy.

Date	Diagnostic testing and interventions
March 10, 2017	Bilateral vasectomy performed
May 6, 2017	Patient began experiencing right scrotal pain and hematospermia
May 12, 2017	Physical examination findings revealed tenderness of the right vasectomy site
May 19, 2017-September 12, 2017	Four semen analyses performed, with progressively rising numbers of motile sperm
November 9, 2017	Repeated bilateral vasectomy performed
January 18, 2018-June 19, 2018	Four semen analyses performed, confirming absence of motile sperm
June 19, 2018	Patient deemed sterile

Therapeutic Intervention and Treatment

The decision was made to pursue a repeated vasectomy because the semen analysis results indicated vasal recanalization and the patient still desired permanent sterilization. A repeated vasectomy was performed in the operating room 8 months after the initial vasectomy (6 months after the pain and hematospermia episode). During the operation, the prior vasal excision sites were identified and carefully excised, along with a portion of proximal and distal vas deferens. Intraoperative inspection of the excised right-sided specimen revealed a patent lumen, through which a 3-0 lacrimal duct probe (Figure 1) was able to be passed. The excised left-sided specimen was probed but was patent for only 2 mm on either side, indicating there was no patent lumen.

Pathologic findings of the repeated vasectomy site specimens revealed bilateral complete cross-section of vas deferens with a sperm granuloma and lymphohistiocytic reaction.

Follow-up and Outcomes

After the repeated bilateral vasectomy, there were no complications. The patient completed several semen analyses, the results of which confirmed that no motile sperm were present (Table 2). Seven months after the repeated vasectomy, the patient was deemed sterile. A timeline of the case appears in Table 3.

DISCUSSION

Our patient experienced vasectomy failure because of early recanalization of the right vas deferens. His vasectomy failure was not because of anatomic variation or a failure to completely transect each vas deferen at the time of the initial vasectomy. This patient's early vasectomy failure was defined by progressively rising numbers of motile sperm present on semen analysis 4 months after vasectomy. Early recanalization is thought to result from epithelial microtubule proliferation through a granuloma at the vasectomy site, resulting in a fistula that facilitates sperm passage.[6] In our case, we surmised that the patient had a sperm granuloma, which led to recanalization. Final pathologic findings of the right vas deferens excised during the repeated vasectomy confirmed the presence of a sperm granuloma.

To our knowledge, the symptom complex of delayed postvasectomy scrotal pain and hematospermia has not been described as a harbinger for recanalization of the vas deferens. Initial scrotal pain is a recognized adverse effect of the procedure, but it is generally self-limited and not thought to be a potential risk factor for recanalization or vasectomy failure. Initial hematospermia, although less common than scrotal pain, is considered self-limited and clinically insignificant during the first 2 months after a vasectomy.[7] In our case, it seems that the patient's episode of acute scrotal pain and hematospermia was indicative of recanalization. Furthermore, it is likely that the fistula tract matured during the months after this episode, as evidenced by the increasing motile sperm counts on semen

The Permanente Journal • For personal use only. No other uses without permission. Copyright © 2019 The Permanente Press. All rights reserved.

analyses. However, because this is the first reported case of vasal recanalization after scrotal pain and hematospermia, it is also possible that these events were coincidental. Future reports of similar cases could strengthen this proposed association.

CONCLUSION

Delayed postvasectomy hematospermia with scrotal pain may be a sign of vasal recanalization. We propose that this symptom complex should prompt an investigation for vasal recanalization, during which the patient should be instructed to refrain from intercourse without the use of an additional method of contraception. ❖

Disclosure Statement

The author(s) have no conflicts of interest to disclose.

Acknowledgments

Kathleen Louden, ELS, of Louden Health Communications performed a primary copy edit.

How to Cite this Article

Kern T, Artenstein D, Shapiro C. Postvasectomy scrotal pain and hematospermia, a possible harbinger for vasectomy failure and recanalization: A case report. Perm J 2020;24:19.068. DOI: https://doi.org/10.7812/TPP/19.068

References

1. Barone MA, Hutchinson PL, Johnson CH, Hsia J, Wheeler J. Vasectomy in the United States, 2002. J Urol 2006 Jul;176(1):232-6. DOI: https://doi.org/10.1016/S0022-5347(06)00507-6.
2. Peterson HB, Curtis KM. Clinical practice. Long-acting methods of contraception. N Engl J Med 2005 Nov 17;353(20):2169-75. DOI: https://doi.org/10.1056/NEJMcp044148.
3. Trussell J. Contraceptive failure in the United States. Contraception 2004 Aug;70(2):89-96. DOI: https://doi.org/10.1016/j.contraception.2004.03.009.
4. Alderman PM. Complications in a series of 1224 vasectomies. J Fam Pract 1991 Dec;33(6):579-84.
5. Schwingl PJ, Guess HA. Safety and effectiveness of vasectomy. Fertil Steril 2000 May;73(5):923-36. DOI: https://doi.org/10.1016/s0015-0282(00)00482-9.
6. Labrecque M, Hays M, Chen-Mok M, Barone MA, Sokal D; American Urological Association. Frequency and patterns of early recanalization after vasectomy. BMC Urol 2006 Sep 19;6:25. DOI: https://doi.org/10.1186/1471-2490-6-25.
7. Sharlip ID, Belker AM, Honig S, et al. Vasectomy: AUA guideline. J Urol 2012 Dec;188(6 Suppl):2482-91. DOI: https://doi.org/10.1016/j.juro.2012.09.080.

The Permanente Journal • For personal use only. No other uses without permission. Copyright © 2019 The Permanente Press. All rights reserved.