doi:10.1093/brain/aww159 BRAIN 2016: 139; 2528–2539 | 2528

BRAIN
A JOURNAL OF NEUROLOGY

Atrophy, hypometabolism and clinical trajectories in patients with amyloid-negative Alzheimer's disease

Gaël Chételat,[1,2,3,4] Rik Ossenkoppele,[5,6,7,*] Victor L. Villemagne,[8,*] Audrey Perrotin,[1,2,3,4,*] Brigitte Landeau,[1,2,3,4] Florence Mézenge,[1,2,3,4] William J. Jagust,[9] Vincent Dore,[8,10] Bruce L. Miller,[7] Stéphanie Egret,[1,2,3,4] William W. Seeley,[7] Wiesje M. van der Flier,[6,11] Renaud La Joie,[1,2,3,4] David Ames,[12,13] Bart N. M. van Berckel,[6] Philip Scheltens,[5] Frederik Barkhof,[6] Christopher C. Rowe,[8] Colin L. Masters,[14] Vincent de La Sayette,[1,2,3,4,15] Femke Bouwman[5,*] and Gil D. Rabinovici[7,9,*]

*These authors contributed equally to this work.

See O'Sullivan and Vann (doi:10.1093/aww166) for a scientific commentary on this article.

About 15% of patients clinically diagnosed with Alzheimer's disease do not show high tracer retention on amyloid positon emission tomography imaging. The present study investigates clinical and demographic features, patterns of brain atrophy and hypometabolism and longitudinal clinical trajectories of these patients. Forty amyloid-negative patients carrying a pre-scan diagnosis of Alzheimer's disease dementia from four centres were included (11/29 females/males; mean age = 67 ± 9). Detailed clinical histories, including the clinical diagnoses before and after the amyloid scan and at follow-up, were collected. Patients were classified according to their pre-scan clinical phenotype as amnestic (memory predominant), non-amnestic (predominant language, visuospatial or frontal symptoms), or non-specific (diffuse cognitive deficits). Demographic, clinical, neuropsychological, magnetic resonance imaging and ^{18}F-fluorodeoxyglucose positon emission tomography data were compared to 27 amyloid-positive typical Alzheimer's disease cases (14/13 females/males; mean age = 71 ± 10) and 29 amyloid-negative controls (15/14 females/males; mean age = 69 ± 12) matched for age, gender and education. There were 21 amnestic, 12 non-amnestic, and seven non-specific amyloid-negative Alzheimer's disease cases. Amyloid-negative subgroups did not differ in age, gender or education. After the amyloid scan, clinicians altered the diagnosis in 68% of amyloid-negative patients including 48% of amnestic versus 94% of non-amnestic and non-specific cases. Amnestic amyloid-negative cases were most often reclassified as frontotemporal dementia, non-amnestic as frontotemporal dementia or corticobasal degeneration, and non-specific as dementia with Lewy bodies or unknown diagnosis. The longer-term clinical follow-up was consistent with the post-scan diagnosis in most cases (90%), including in amnestic amyloid-negative cases whose post-positon emission tomography diagnosis remained Alzheimer's disease. While the non-amnestic and non-specific amyloid-negative cases usually showed patterns of atrophy and hypometabolism suggestive of another degenerative disorder, the amnestic amyloid-negative cases had subtle atrophy and hypometabolism, restricted to the retrosplenial/posterior cingulate cortex. Patients with a negative amyloid positon emission tomography scan following an initial clinical diagnosis of Alzheimer's disease have heterogeneous clinical presentations and neuroimaging profiles; a majority showed a clinical progression that was consistent with a neurodegenerative condition. In contrast, in the subgroup of amnestic amyloid-negative cases, the clinical presentation and follow-up usually remained consistent with Alzheimer's disease. An alternative diagnosis was not made in about half of the amnestic amyloid-negative cases, highlighting the need for a clinical framework and terminology to define these patients, who may have underlying limbic-predominant, non-amyloid-related pathologies.

Received November 5, 2015. Revised April 28, 2016. Accepted May 16, 2016. Advance Access publication June 29, 2016
© The Author (2016). Published by Oxford University Press on behalf of the Guarantors of Brain. All rights reserved.
For Permissions, please email: journals.permissions@oup.com

1 INSERM, U1077, 14074 Caen, France
2 Université de Caen Basse-Normandie UMR-S1077, 14074 Caen, France
3 Ecole Pratique des Hautes Etudes, UMR-S1077, 14074 Caen, France
4 CHU de Caen, U1077, 14000 Caen, France
5 VU University Medical Centre, Neuroscience Campus Amsterdam, Department of Neurology and Alzheimer Centre, 1081 HZ Amsterdam, The Netherlands
6 VU University Medical Centre, Department of Radiology and Nuclear Medicine, 1081 HZ Amsterdam, The Netherlands
7 University of California San Francisco, Memory and Aging Centre, Department of Neurology, San Francisco, CA 94720, USA
8 Department of Nuclear Medicine and Centre for PET, Austin Health, Melbourne, VIC 3084, Australia
9 Helen Wills Neuroscience Institute, University of California, Berkeley, Berkeley CA 94720, USA; Lawrence Berkeley National Laboratory, Berkeley, California, USA
10 Commonwealth Scientific Industrial Research Organization Health and Biosecurity Flagship, Brisbane, QLD 4006, Australia
11 VU University Medical Centre, Department of Epidemiology and Biostatistics, 1081 HZ Amsterdam, The Netherlands
12 Academic Unit for Psychiatry of Old Age, St. Vincent's Health, Department of Psychiatry, The University of Melbourne, Kew, VIC 3101, Australia
13 National Ageing Research Institute, Parkville, VIC 3052, Australia
14 The Florey Institute of Neuroscience and Mental Health, Mental Health, Melbourne, VIC 3010, Australia
15 CHU de Caen, Service de Neurologie, 14000 Caen, France

Correspondence to: Gaël Chételat,
Unité U1077, GIP CYCERON, Bd Henri Becquerel – BP 5229,
14074 Caen Cedex, France
E-mail: chetelat@cyceron.fr

Keywords: amyloid; PET; MRI; Alzheimer's disease; retrosplenial posterior cingulate

Abbreviations: Aβneg-AD = amyloid-negative probable Alzheimer's disease patients; Aβneg-HC = amyloid-negative healthy control subjects; Aβpos-AD = amyloid-positive probable Alzheimer's disease patients

Introduction

Amyloid-β deposition is one of the neuropathological hallmarks of Alzheimer's disease (Hyman *et al.*, 2012). For more than a decade, it has been possible to visualize these lesions *in vivo* with PET radiotracers that bind to fibrillar amyloid-β plaques (Klunk *et al.*, 2004). Most patients with a clinical diagnosis of probable Alzheimer's disease have a positive amyloid-β scan (Aβpos-AD). However, a significant proportion, ~15% (ranging from 2 to 32%) of patients across clinical series, have a negative amyloid-β scan (Aβneg-AD) (Jagust *et al.*, 2010; Rowe *et al.*, 2010; Vandenberghe *et al.*, 2010; Doraiswamy *et al.*, 2012; Ossenkoppele *et al.*, 2013, 2015*a*; Sperling *et al.*, 2014). Very few studies have been conducted on Aβneg-AD cases so that their aetiology remains largely unknown. Some cases of Aβneg-AD might correspond to false negatives due to technical issues or scan misinterpretation, or a lack of sensitivity of amyloid-β ligands in cases with low amyloid-β burden or atypical amyloid-β forms (Cairns *et al.*, 2009; Rosen *et al.*, 2010; Schöll *et al.*, 2012; Johnson *et al.*, 2013). The majority of Aβneg-AD cases probably reflect clinical misdiagnosis, as the accuracy of the clinical diagnosis of probable Alzheimer's disease at expert centres is ~70% when compared to the cause of dementia as determined at autopsy (Beach *et al.*, 2012).

Clinical series have shown that clinicians change their diagnosis after disclosure of PET results from Alzheimer's disease to a non-amyloid-β neurodegenerative or non-degenerative condition in a significant portion of Aβneg-AD cases, especially when prior diagnostic certainty was low (Ossenkoppele *et al.*, 2013; Sánchez-Juan *et al.*, 2014). This is particularly the case for patients who present with an atypical (non-amnestic) clinical phenotype (e.g. behavioural-predominant or language deficits). However, clinicians may not revise their diagnosis when faced with a progressive amnestic disorder suggestive of 'typical' Alzheimer's disease, and identifying the aetiologies of these intriguing cases is particularly challenging. Even in post-mortem studies a significant proportion (~20%) of the cases not meeting the neuropathological threshold for Alzheimer's disease were diagnosed with Alzheimer's disease anyway as no other neuropathological diagnosis could be found (Beach *et al.*, 2012). In-depth description of the atrophy and hypometabolism pattern and longitudinal clinical trajectories of these patients would further our understanding of their possible underlying pathology, which is crucial to improve both the clinical diagnosis of Alzheimer's disease and Alzheimer's disease-like dementia and the understanding of the pathological mechanisms leading to Alzheimer's disease symptoms.

In the present study, we gathered detailed clinical and neuroimaging data on Aβneg-AD cases from different samples to further characterize this population compared to Aβpos-AD and amyloid-β negative healthy controls (Aβneg-HC). Patients were split in subgroups according to their baseline clinical presentation with the two following main objectives: (i) to determine the most plausible alternative diagnosis per subgroup based on all available

information (clinician judgement based on clinical, neuropsychological, CSF, neuroimaging data and follow-up clinical information); and (ii) in the Alzheimer's disease-mimic typical amnestic subgroup, especially those without an alternative diagnosis, to provide a comprehensive description of their neuroimaging (atrophy and hypometabolism) profile as a key to the possible aetiologies.

Materials and methods

Participants

Aβneg-AD cases were identified by database searches in four amyloid-β PET research centres. In two centres recruitment for amyloid-β PET was derived from observational research studies of typical amnestic Alzheimer's disease (Caen, France and Melbourne, Australia), whereas in the other two recruitment centred around clinical populations with more diverse clinical profiles (Amsterdam, The Netherlands and San Francisco, USA). All participants underwent standard dementia screening that included medical history, informant-based history, physical and neurologic examinations, screening laboratory tests, MRI and neuropsychological testing. Pre-PET clinical diagnosis was established by consensus in a multidisciplinary team within each centre. Individuals were eligible for inclusion in this study if they had (i) a pre-PET clinical diagnosis of probable Alzheimer's disease dementia according to international consensus National Institute of Neurological and Communicative Disorders and Stroke, and the Alzheimer's Disease and Related Disorders Association criteria (McKhann *et al.*, 1984) without taking into account imaging data; (ii) an amyloid-β-PET scan that was classified as negative by local readers (V.L.V., C.C.R., W.J.J., V.L.S., G.D.R., B.V.B.); and (iii) a structural MRI scan [used for MRI and fluorodeoxyglucose (FDG)-PET data processing].

All amyloid-β-PET scans [Pittsburgh compound B (PiB) or florbetapir standardized uptake value images; see Supplementary Table 2] from the four centres were re-reviewed by a single reader blinded to all clinical information (G.D.R.). Ambiguous cases (i.e. high degree of uncertainty or discordance across readers) were excluded, as the goal of this study was to characterize the clearly negative (compared to the clearly positive) Alzheimer's disease cases, and not to deal with the issue of intermediate/ambiguous amyloid-β scans. Of the 48 Aβneg-AD cases preselected by the centres (representing 9–21% of all Alzheimer's disease cases with an amyloid-β PET scan in those centres), 40 cases were finally included in the present study (Table 1; five from Caen, six from Melbourne, 18 from Amsterdam and 11 from San Francisco). Among the eight cases that were excluded, six had ambiguous or positive amyloid-β-PET reading on re-review, one had an ambiguous pre-PET diagnosis and one was too severely impaired.

For comparison, Aβpos-AD and Aβneg-HC cases were selected from each centre. The Aβpos-AD cases were eligible if they had a pre-PET clinical diagnosis of probable Alzheimer's disease according to the National Institute of Neurological and Communicative Disorders and Stroke, and the Alzheimer's Disease and Related Disorders Association criteria (McKhann *et al.*, 1984), a structural MRI scan and a positive amyloid-β-PET scan. The Aβneg-HC were cognitively normal volunteers recruited through newspaper advertisements as described elsewhere (Mormino *et al.*, 2009; Villemagne *et al.*, 2011; Ossenkoppele *et al.*, 2012; Mevel *et al.*, 2013). The reader who adjudicated the Aβneg-AD visual reads (G.D.R.) performed a blinded review of all Aβpos-AD and Aβneg-HC cases and all cases with an ambiguous amyloid-β PET scan were excluded. Within-centre matching of cases across all relevant parameters was not feasible due to across-centre differences in the pools of eligible subjects. We prioritized matching the cases for demographics and clinical data over matching for centres. Therefore, the Aβpos-AD and Aβneg-HC cases were selected from the whole pool of eligible data so that the groups were matched to the Aβneg-AD group for age and education (and Mini-Mental State Examination for Alzheimer's disease cases) and the proportions from each centre were equivalent in all groups. In total, 27 Aβpos-AD and 29 Aβneg-HC cases were included in the study. The demographic characteristics of the groups are presented in Table 1. All participants or their surrogates provided informed consent to participate in research, and the local ethics committee in each centre approved for all protocols.

Table 1 Demographic and clinical characteristics of the samples

	Aβneg-AD (n = 40)	Aβpos-AD (n = 27)	Aβneg-HC (n = 29)	Group effect
Age	67.4 ± 9.1	70.6 ± 9.8	69.3 ± 11.7	0.4
Gender (M:F)	29 : 11	13 : 14	14 : 15	0.06
Education	12.6 ± 4.6	13.1 ± 3.3	13.5 ± 4.0	0.7
MMSE	23.2 ± 4.4	23.5 ± 3.3	29.0 ± 1.0*	< 0.001
APOE4[a]	5/35 (14%)	20/26 (77%)**	3/28 (11%)	< 0.001

*Significant difference from both other groups in *post hoc* tests ($P < 0.001$); **significant difference from both other groups in 2 × 2 chi-square ($P < 0.001$).
[a]indicated is number (percentage) of *APOE4* cases / number of cases with *APOE* genotyping.
MMSE = Mini-Mental State Examination.

Data collection

All the data in this study were collected retrospectively via chart and database review. To optimize data collection, A.P. or G.C. performed site visits at each of the centres following a prespecified procedure. Before the visit, each centre prepared a list of cases (Aβneg-AD, Aβpos-AD and Aβneg-HC) with their corresponding demographic, apolipoprotein ε (*APOE*) genotype and neuropsychological data, results of CSF analyses when available, and a file summarizing available neuroimaging data (structural MRI, FDG-PET, amyloid-β-PET). The procedure for the site visit is detailed in the Supplementary material.

All Aβneg-AD patients were then classified according to their clinical phenotype in the last assessment prior to the PET scan. The clinical phenotype was determined by the clinician based on clinical and neuropsychological information. They were classified as (i) 'amnestic' Aβneg-AD if they had predominant episodic memory deficits, with various involvement of other cognitive domains; (ii) 'non-amnestic' Aβneg-AD if their predominant deficit was in another cognitive domain than

memory, i.e. if they had predominant language, visuospatial or frontal symptoms, while memory deficits, if present, were less prominent; or (iii) 'non-specific' Aβneg-AD if they had a diffuse pattern of cognitive impairment (i.e. they did not present with a predominant deficit in one specific area of cognition).

Neuropsychological scores

To quantify and compare subgroup's performances, the same or an equivalent test was selected within each centre for each of the following cognitive functions: verbal episodic memory (immediate and delayed recall), visual episodic memory, executive functions, visuo-spatial function and semantic memory. The tests and scores selected for each centre are presented in the Supplementary Table 1. Each score was z-score transformed based on a control database from each corresponding centre.

Neuroimaging data

The scanner types and acquisition protocols for each site are presented in the Supplementary Table 2. For voxel-wise analyses, MRI and FDG-PET data were processed and analysed using Statistical Parametric Mapping 5 software (Wellcome Trust Centre for Neuroimaging, London, UK). T_1-weighted MRI images were segmented, spatially normalized to the MNI space, modulated to correct for non-linear warping effects using the Voxel-Based Morphometry 5.1 toolbox and smoothed using a 12 mm full-width at half-maximum Gaussian kernel. FDG-PET images were co-registered onto corresponding MRI, normalized using the deformation parameters defined from the VBM procedure performed on the corresponding MRI, scaled using the mean PET value of the cerebellar grey matter and smoothed using a 12 mm full-width at half-maximum Gaussian kernel.

Quality control for raw data and for each step of data processing was performed by experts (details in Supplementary material). Note that PET data were not corrected for atrophy as this would rather exacerbate differences due to the different MRI scanners.

Eighty-one MRI scans (n = 34 Aβneg-AD, 23 Aβpos-AD and 24 Aβneg-HC) and 74 FDG-PET scans (n = 34 Aβneg-AD, 21 Aβpos-AD and 19 Aβneg-HC) were included in the corresponding voxel-wise analyses. The demographic and clinical characteristics of the respective samples are presented in Supplementary Table 3; there was no significant difference in the characteristics of the MRI and FDG subsamples compared to those of the main sample.

CSF

CSF sampling was obtained in a proportion of the Aβneg-AD (18/40) from Amsterdam and San Francisco as previously described [(Duits *et al.*, 2014) for Amsterdam; (Shaw *et al.*, 2009) for San Francisco] and detailed in the Supplementary material.

Statistical analyses

Demographic, clinical and neuropsychological data were compared between groups using ANOVAs and *post hoc* 2 × 2 group comparisons. Chi-square tests were performed for categorical variables (gender and *APOE4*). MRI and FDG-PET images were compared voxel-wise between groups using the full factorial design in Statistical Parametric Mapping 5. Results are displayed at a threshold of uncorrected P ($P_{uncorrected}$) < 0.001) unless specified otherwise. Results described below are presented with all models performed without covariates. This appears as the best option given that the groups were matched to avoid reducing the degrees of freedom and associated statistical power in our analyses. Yet, to ensure that none of our findings were merely reflecting the effects of a covariate, all analyses were repeated including age, gender or centre as a covariate.

Table 2 Demographic and clinical characteristics in Aβneg-AD subgroups

	Amnestic Aβneg-AD (n = 21)	Non-amnestic Aβneg-AD (n = 12)	Non-specific Aβneg-AD (n = 7)	Group effect (P-value)
Age	68.6 ± 10.8	64.8 ± 5.7	68.3 ± 8.2	0.5
Gender (M:F)	14:7	9:3	6:1	0.6
Education	12.1 ± 4.5	12.7 ± 3.6	15.7 ± 9.1	0.5
MMSE	24.6 ± 2.5	21.1 ± 5.9*	22.6 ± 4.8	0.08
APOE4[a]	5/20 (25%)	0/10 (0%)	0/5 (0%)	0.1

Post hoc Fisher LSD difference from amnestic Aβneg-AD P = 0.04.
[a]Number of *APOE4* cases / number of cases with *APOE* genotyping (proportion).
MMSE = Mini Mental State Examination.

Results

Demographic and clinical data

The Aβpos-AD, Aβneg-AD, and Aβneg-HC did not differ in age, gender or education (Table 1). The proportion of *APOE4* carriers was significantly higher in Aβpos-AD compared to both controls and Aβneg-AD but was not different between the controls and Aβneg-AD.

Among Aβneg-AD patients, there were 21 amnestic, 12 non-amnestic, and seven non-specific cases. Aβneg-AD subgroups did not differ in age, gender or education. Amongst the Aβneg-AD, all *APOE4* carriers were in the amnestic subgroup; the group effect on the proportion of *APOE4* carriers was at the trend level when considering the three subgroups and the amnestic Aβneg-AD had more *APOE4* carriers when compared to the other Aβneg-AD cases considered as a single group (P = 0.04). There was also a trend for a group effect on the Mini-Mental State Examination (MMSE) and *post hoc* analyses showed that non-specific Aβneg-AD had slightly lower scores than amnestic Aβneg-AD (Table 2). Comparisons of the neuropsychological scores between these subgroups were consistent with their classification, showing overall more severe episodic memory deficits in Aβpos-AD and amnestic Aβneg-AD, while non-amnestic Aβneg-AD had lower performance on non-memory tasks (see details in Supplementary material and Supplementary Fig. 1).

After amyloid-β PET, the clinicians altered the diagnosis in 25 of 37 (68%; missing information in three cases) Aβneg-AD cases (Fig. 1). Post-amyloid-β PET diagnoses

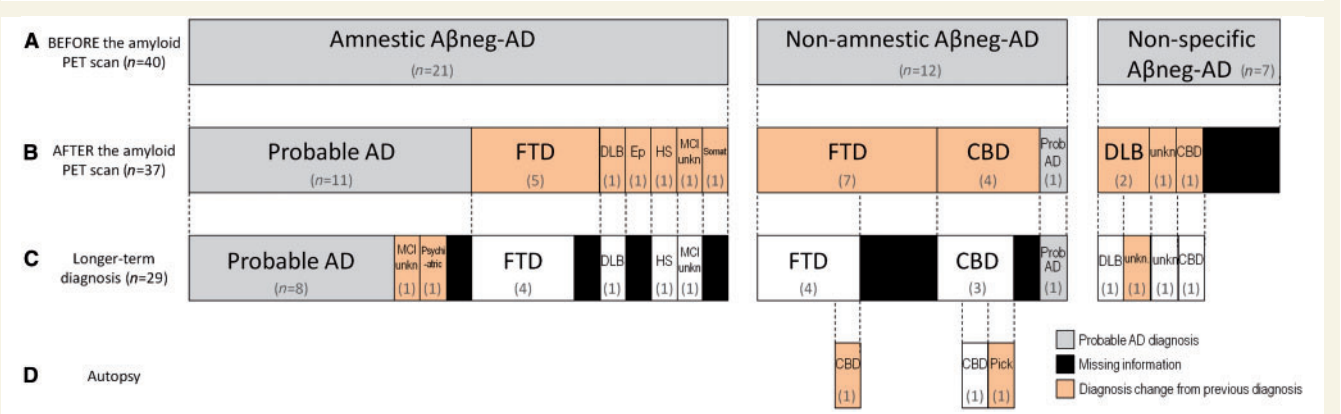

Figure 1 Clinical diagnosis and trajectories of Aβneg-AD. Clinical diagnosis at baseline (in the last assessment prior to the amyloid-β-PET scan) (**A**), once the clinicians knew the results of the PET scan (**B**), and after a longer-term clinical follow-up (**C**, see Table 3 for follow-up duration). The neuropathological diagnosis is also indicated in three patients who died and underwent autopsy (**D**). AD = Alzheimer's disease; CBD = corticobasal degeneration; DLB = dementia with Lewy Body; Ep = Epilepsy-depression; FTD = frontotemporal dementia; HS = hippocampal sclerosis; MCI unkn = mild cognitive impairment with unknown aetiology; Prb = probable; unkn. = unknown disease; Somat = somatoform disorder.

included behavioural and/or language variants of frontotemporal dementia ($n = 12$), corticobasal degeneration ($n = 5$), dementia with Lewy bodies ($n = 3$), epilepsy/depression ($n = 1$), hippocampal sclerosis ($n = 1$), somatoform disorder ($n = 1$) and unknown ($n = 2$, see Fig. 1). The frontotemporal dementia diagnoses included non-fluent variant of primary progressive aphasia ($n = 3$), behavioural variant of frontotemporal dementia ($n = 2$), semantic dementia ($n = 2$), mixed language and behavioural frontotemporal dementia ($n = 2$), unspecified variant ($n = 2$) and atypical frontotemporal dementia ($n = 1$).

When considering Aβneg-AD subgroups (Fig. 1), clinicians did not change their clinical diagnosis in 52% of amnestic Aβneg-AD patients, but nearly always changed the diagnosis in non-amnestic and non-specific cases (94%; significantly different from the percentage in amnestic Aβneg-AD; χ^2 $P = 0.003$). Amnestic Aβneg-AD cases were most often reclassified as frontotemporal dementia, non-amnestic as frontotemporal dementia or corticobasal degeneration, and non-specific as dementia with Lewy bodies.

Clinical follow-up was obtained in a majority of participants (75%, 78% and 90% of the Aβneg-AD, Aβpos-AD and Aβneg-HC cases, respectively). Information on the duration of follow-up, mean number of visits and mean MMSE slope is presented in Table 3. The mean follow-up time did not differ between Aβneg-AD subgroups but was longer in Aβneg-HC and Aβpos-AD. The mean MMSE slope was highly significantly different between groups ($P < 10^{-10}$) with *post hoc* analyses showing that the slope was less steep in Aβneg-HC than in all other groups and steeper in non-amnestic Aβneg-AD than in all other groups. The MMSE slope did not differ between amnestic Aβneg-AD, non-specific Aβneg-AD and Aβpos-AD, although it tended to be less steep in amnestic than in non-amnestic Aβneg-AD ($P = 0.09$).

Among the patients who had longer-term clinical follow-up, the post-PET diagnosis was supported and remained unchanged in most cases (Fig. 1; $n = 26/29$; 90%, missing information in one case). Three non-amnestic Aβneg-AD patients were followed to death and underwent brain autopsy at the UCSF Neurodegenerative Disease Brain Bank following previously published protocols (Ossenkoppele *et al.*, 2015*b*). The post-mortem diagnoses were corticobasal degeneration (two patients) and Pick's disease, pathological variants of frontotemporal lobar degeneration (Mackenzie *et al.*, 2010). The two former cases had no amyloid at all (Thal stage 0, CERAD absent) and the latter case showed sparse diffuse plaques without neuritic plaques (Thal stage 1, CERAD absent).

CSF biomarkers

The results of CSF Alzheimer's disease biomarkers in Aβneg-AD are presented in Table 4. CSF amyloid-β_{42} results in Aβneg-AD patients were usually in the normal range, concordant with the negative amyloid-β PET. However, CSF total tau or phosphorylated-tau (p-tau)_levels were abnormal in more than half the cases. Only one patient had a CSF profile strongly suggestive of underlying Alzheimer's disease, with low amyloid-β_{42} and high tau/p-tau. The results of Aβneg-AD subgroups (Table 4) should be considered with caution because of the small sample sizes.

Neuroimaging

The neuroimaging findings in the total Aβneg-AD group, compared to Aβpos-AD and Aβneg-HC, are described in the Supplementary material and Supplementary Fig. 2. The

Table 3 Information on the follow-up of the participants included in this study per subgroup

	⩾ 1 year*	⩾ 2 year*	⩾ 3 year*	⩾ 4 year*	Mean follow-up time	Mean number of visits	Mean MMSE slope
Amnestic Aβneg-AD	17	13	11	5	2.7 ± 1.4	3.7 ± 1.5	− 1.6 ± 1.4
Non-amnestic Aβneg-AD	8	7	4	0	2.1 ± 1.0	4.0 ± 1.6	− 6.6 ± 3.3*
Non-specific Aβneg-AD	5	3	3	1	3.0 ± 1.6	4.5 ± 2.6	−3.4 ± 2.7
Aβpos-AD	21	19	15	9	3.3 ± 1.3	3.8 ± 1.5	−2.1 ± 2.8
Aβneg-HC	26	25	20	12	3.5 ± 1.1	3.3 ± 1.0	0.0 ± 0.4*
P (ANOVA)					0.03	0.3	10^{-10}

*Numbers indicate the number of participants that have been followed-up at least *x* years. The mean number of visits and the mean follow-up time were calculated from the participants who have been followed-up. The mean MMSE slope was calculated from the regression of the MMSE scores over follow-up years. The *P*-values of the main effect of group from one-factor ANOVAs are indicated in the last line of the table.
MMSE = Mini-Mental State Examination.

Table 4 CSF profile per Aβneg-AD subgroup

	n total	$A\beta_{42}$ normal, tau/p-tau normal	$A\beta_{42}$ low, tau/p-tau normal	$A\beta_{42}$ normal, tau/p-tau high	$A\beta_{42}$ low, tau/p-tau high
All	18	7 (39%)	1 (5.5%)	9 (50%)	1 (5.5%)
Amnestic Aβneg-AD	9	4	–	5	–
Non-amnestic Aβneg-AD	7	2	1	2	1
Non-specific Aβneg-AD	3	1	–	2	–

Values are presented as number of cases (percentage).

neuroimaging findings for the different Aβneg-AD subgroups are shown in Fig. 2 and the corresponding effect sizes are shown in Supplementary Fig. 3.

Compared to Aβneg-HC, significant atrophy ($P_{uncorrected} < 0.001$) in amnestic Aβneg-AD was restricted to the right and left retrosplenial/posterior cingulate cortex [*P* corrected for family-wise errors (P_{FWE}) = 0.05] and orbito-frontal and dorsomedial prefrontal cortex (not surviving at $P_{FWE} < 0.05$). With a more permissive threshold ($P_{uncorrected} < 0.005$), atrophy was also found in the hippocampus (anterior and posterior portions), and posterior cingulate cortex. There was no area of significant hypometabolism in amnestic Aβneg-AD compared to Aβneg-HC; even at a more permissive threshold ($P_{uncorrected} < 0.005$), only very small clusters in the medial prefrontal, hippocampus and posterior cingulate cortex were observed. As expected, both atrophy and hypometabolism were significantly less pronounced in amnestic Aβneg-AD compared to Aβpos-AD in large portion of the posterior associative cortex, (surviving at $P_{FWE} < 0.05$ in several areas).

In non-amnestic Aβneg-AD, asymmetric atrophy was found in left greater than right prefrontal, temporal, temporoparietal and temporo-occipital cortex, temporal pole, insula, posterior cingulate and precuneus, amygdala and parahippocampal gyrus. The hippocampus was mostly preserved (except a small portion in the posterior end of the right hippocampus). Large portions of the prefrontal cortex and small clusters in the left temporal lobe survived multiple comparisons correction ($P_{FWE} < 0.05$). Significant hypometabolism was more restricted and located in bilateral dorsolateral prefrontal cortex (surviving at $P_{FWE} < 0.05$) and left angular gyrus. Compared to Aβpos-AD, non-amnestic Aβneg-AD showed greater atrophy especially in frontal and insular regions and caudate nucleus. No significant difference was found in hypometabolism between non-amnestic Aβneg-AD and Aβpos-AD.

Compared to Aβneg-HC, the non-specific Aβneg-AD showed restricted areas of atrophy in the orbital and dorsomedial frontal cortex (not surviving at $P_{FWE} < 0.05$), and significant and extended hypometabolism predominantly in the temporal neocortex extending to the temporoparietal junction (clusters in right superior temporal and left angular cortex surviving at $P_{FWE} < 0.05$), and the bilateral prefrontal cortex. Compared to Aβpos-AD, atrophy was slightly less pronounced in non-specific Aβneg-AD while hypometabolism was more pronounced in the left insula and bilateral lingual cortex.

Additional analyses in the amnestic Aβneg-AD subgroup

To further understand what distinguished amnestic Aβneg-AD from Aβpos-AD cases, we divided the Aβneg-AD group according to their post-PET diagnosis, i.e. whether or not the diagnosis changed after the clinician knew the results of the amyloid-β-PET scan. The diagnosis did not change in 11 amnestic Aβneg-AD cases (i.e. Aβneg-AD-unchanged) (Fig. 1). Within this subgroup, longer term follow-up was available in all but one patient, and the diagnosis remained probable Alzheimer's disease in 8 of 10 cases. The diagnosis changed in the remaining cases to psychiatric disease

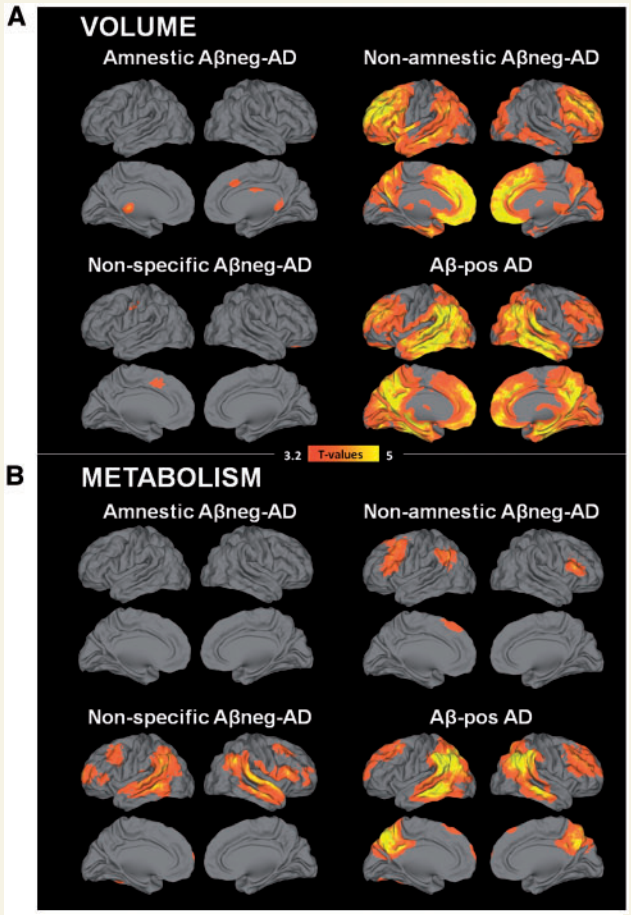

Figure 2 Atrophy and hypometabolism in Aβneg-AD. Profiles of atrophy (**A**) and hypometabolism (**B**) in the three Aβneg-AD subgroups and in the Aβpos-AD compared to the Aβneg-HC. The threshold was set at $P_{uncorrected} < 0.001$, $k > 50$. Effect-sizes are presented in Supplementary Fig. 3. Sample sizes n = 17, 11, 6, 23 and 24 for volume and 16, 12, 6, 21 and 19 for metabolism for amnestic Aβneg-AD, non-amnestic Aβneg-AD, non-specific Aβneg-AD, Aβpos-AD and Aβneg-HC, respectively.

(persecution delirium / melancholy; $n = 1$) and to unspecified mild cognitive impairment ($n = 1$) as the functional impairment was in the grey zone between mild cognitive impairment and dementia and there was no deterioration during the follow-up. The 10 amnestic Aβneg-AD cases with a post-PET change in diagnosis were called amnestic Aβneg-AD-changed. Longer term follow-up was available in 7 of these 10 patients and the clinical diagnosis remained the same as the post-PET diagnosis in all cases. The description of each individual amnestic Aβneg-AD case and their clinical follow-up is detailed in Supplementary Table 4.

The neuroimaging findings of the amnestic Aβneg-AD subgroups are shown in Fig. 3 (at $P_{uncorrected} < 0.005$ and as effect-size maps). The amnestic Aβneg-AD-unchanged showed significant atrophy and hypometabolism compared to Aβneg-HC in the retrosplenial/posterior cingulate cortex encroaching the posterior hippocampus ($P_{uncorrected} = 2.10^{-5}$; $P_{FWE} = 0.1$; $k = 1717$ for atrophy and $P_{uncorrected} = 0.001$; $P_{FWE} = 0.8$; $k = 37$ for hypometabolism). Interestingly, non-thresholded effect-size maps showed that even more subtle effects were essentially restricted to the posterior hippocampus, posterior cingulate and precuneus.

The amnestic Aβneg-AD-changed group had significantly more atrophy compared to Aβneg-HC in the bilateral medial orbitofrontal cortex, dorsomedial frontal cortex (superior frontal gyrus), thalamus, amygdala, and parahippocampal gyrus. There was no area of significant hypometabolism but the corresponding effect size map showed that subthreshold hypometabolism concerned the bilateral middle and superior temporal neocortex and anterior medial temporal lobe.

Individual profiles of atrophy and hypometabolism were also assessed as illustrated in Supplementary Fig. 4. They showed that three different scenarios could be found amongst the amnestic Aβneg-AD. About half of the cases presented with very slight and similar profiles of atrophy and hypometabolism restricted to the posterior hippocampus, retrosplenial/posterior cingulate cortex (representative examples in Supplementary Fig. 4B and C). In these cases, the clinical follow-up did not allow us to identify an alternative diagnosis to probable Alzheimer's disease. About 30% of the cases had a profile of atrophy and hypometabolism consistent with another degenerative disease (representative example in Supplementary Fig. 4E); the clinicians changed the diagnosis based on this information and in all cases the longer-term clinical evolution was consistent with the post-PET diagnosis. Finally, ~20% of the amnestic Aβneg-AD cases had a clinical progression that was not consistent with a neurodegenerative disease in that they were relatively stable or declined very slowly. Interestingly, the profiles of atrophy and hypometabolism were different in these later cases compared to both previous scenarios, in that they had almost no atrophy and no hypometabolism (Supplementary Fig. 4D). It seems relevant to identify these cases as their clinical outcome is different and they likely do not have a neurodegenerative disease.

Discussion

In this multicentre study we assessed the clinical, neuropsychological and neuroimaging features of patients clinically diagnosed with Alzheimer's disease who had a negative amyloid PET scan. We found Aβneg-AD patients to have heterogeneous clinical presentations and outcomes. Fifty-two per cent had a clinical phenotype typical of Alzheimer's disease with memory predominant deficits (amnestic Aβneg-AD), 30% showed an atypical presentation with predominant deficits in a non-memory domain (non-amnestic Aβneg-AD), while the remaining 18% had a non-specific neurobehavioural phenotype (non-specific Aβneg-AD). After disclosure of PET scan results, the diagnosis was changed in two-thirds of all cases, including 48% of amnestic-Aβneg-AD cases versus all but one (94%) of

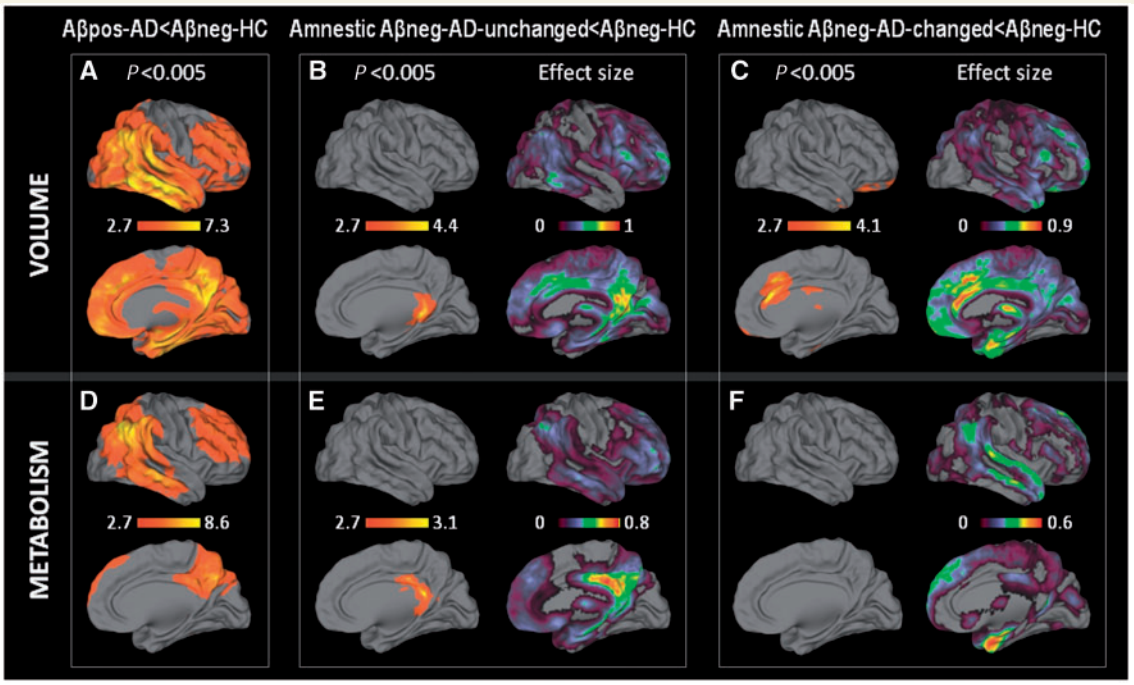

Figure 3 Atrophy and hypometabolism in amnestic Aβneg-AD subgroups. Profiles of atrophy (**A–C**) and hypometabolism (**D–F**) in Aβpos-AD (**A** and **D**), amnestic Aβneg-AD-unchanged (**B** and **E**) and amnestic Aβneg-AD changed (**C** and **F**), compared to Aβneg-HC. The results are displayed as T-value maps thresholded at $P_{uncorrected} < 0.005$, $k > 10$ and as effect-size maps. Sample sizes n = 8, 9, 23 and 24 for volume and 7, 9, 21 and 19 for metabolism for amnestic Aβneg-AD-unchanged, amnestic Aβneg-AD-changed, Aβpos-AD and Aβneg-HC, respectively.

non-amnestic and non-specific cases. The alternative diagnosis was another degenerative condition in a majority of cases, which reflects the overlap in clinical expression between the different degenerative diseases. The diagnosis was maintained over the clinical follow-up in most cases (90%) suggesting that the diagnosis was accurate. However, this might also reflect the fact that the clinician tended not to want to change their diagnosis. Indeed, there was no systematic assessment made of the profile of clinical progression and follow-up clinical data blind to PET scan results, so that there is a risk of theory-dependent observations.

In the national Alzheimer's coordinating centre autopsy database, a mismatch between the clinical and neuropathological diagnoses of Alzheimer's disease was found in 17% of the 526 subjects diagnosed as clinically probable Alzheimer's disease (Beach *et al.*, 2012), and in 25% of patients diagnosed with possible or probable Alzheimer's disease in a follow-up study (Monsell *et al.*, 2015). The proportion of Aβneg-AD cases in the four centres in the present study (9–21%) is comparable to these post-mortem studies, and to the rate of patients with clinically diagnosed Alzheimer's disease with negative amyloid-β PET reported in the literature (Jagust *et al.*, 2010; Vandenberghe *et al.*, 2010; Doraiswamy *et al.*, 2012; Salloway *et al.*, 2014; Ossenkoppele *et al.*, 2015*a*).

The most frequent primary neuropathological diagnoses for the cases not meeting the neuropathological threshold for Alzheimer's disease in Beach *et al.* (2012) were Alzheimer's disease nevertheless (19%), frontotemporal dementia [17%; among which 7/15 had ubiquitin or TAR DNA-binding protein 43 (TDP-43) positive inclusions and 3/15 had tauopathies], tangle-only dementia or argyrophilic grain disease (17%), cerebrovascular disease (11%), dementia with Lewy bodies (10%), hippocampal sclerosis (9%) and corticobasal degeneration (2%). The alternative clinical diagnoses in the present study were mostly similar, with differences likely reflecting the differences in the study design (e.g. referral basis, post-mortem versus clinical diagnoses, availability of both plaque and tangle data at autopsy versus amyloid-β biomarker only in the present study).

A proportion of Aβneg-AD might reflect false negative amyloid-β scans. However, the fact that Aβneg-AD showed different profiles of hypometabolism and atrophy as compared to Aβpos-AD makes this an unlikely explanation in the majority of cases in this study as it rather suggests that Aβneg-AD represents a different entity from Aβpos-AD. Moreover, most Aβneg-AD had a normal CSF level of amyloid-β_{42}, consistent with previous reports (Shimada *et al.*, 2011; Takeuchi *et al.*, 2012) and studies showing high agreement between amyloid PET and CSF amyloid-β results (Palmqvist *et al.*, 2014; Zwan *et al.*, 2014). Only two patients had low CSF amyloid-β_{42}, suggesting that false negative amyloid-β PET may occur infrequently at least in our cohort, although post-mortem confirmation would be needed. A few cases (especially

those with an Alzheimer's disease-typical phenotype and clinical evolution, or low CSF amyloid-β) might yet have low levels (Leinonen *et al.*, 2008; Cairns *et al.*, 2009) or an atypical form (Schöll *et al.*, 2012) of amyloid-β, that would not be detected with amyloid-β PET. As regard to CSF tau and p-tau, the high levels found in about half of the cases indicates that neurodegeneration and/or neurofibrillary tangles are likely present in at least 50% of Aβneg-AD in our study (Blennow *et al.*, 2010).

Aβneg-AD patients were characterized by a low prevalence of APOE4 (14% versus 77% in the Aβpos-AD), consistent with previous reports (Shimada *et al.*, 2011; Takeuchi *et al.*, 2012; Serrano-Pozo *et al.*, 2014) and with the fact that *APOE4* is strongly associated with amyloid-β deposition (Fouquet *et al.*, 2014). In Monsell *et al.* (2015), minimal plaques were found post-mortem in 13% of APOE4 carriers versus 37% of non-carriers in patients with a clinical diagnosis of possible or probable Alzheimer's disease. In a recent clinical trial of anti-amyloid-β immunotherapy, the prevalence of amyloid-β PET-negativity in patients clinically diagnosed with mild-moderate Alzheimer's disease dementia was 6.5% in APOE4 carriers versus 36% in non-carriers (Salloway *et al.*, 2014; Liu *et al.*, 2015). The large difference in the prevalence of APOE4 carriers between the Aβneg- and Aβpos-AD in the present study might reflect the fact that only clearly positive and clearly negative cases were included. It further supports the view that APOE4 is a strong predictor of the presence of amyloid in the brain especially in patients diagnosed with probable Alzheimer's disease (*APOE4* and amyloid-β-positive status were inconsistent in only 18% of patients with Alzheimer's disease). Aβneg-AD patients were also characterized by a high prevalence of females; sex is not usually found to affect amyloid positivity (Jansen *et al.*, 2015) but it is possible that the conditions associated with amyloid-negative Alzheimer's disease mimics are more frequent in females.

Amnestic Aβneg-AD

The largest subgroup of Aβneg-AD patients presented with a progressive amnestic disorder consistent with typical Alzheimer's disease, and performed most similarly to Aβpos-AD on cognitive tests. The clinical follow-up suggests that in most cases this condition is not benign: only 2/17 patients with longer-term clinical follow-up were reclassified as mild cognitive impairment as their cognition remained stable, and one was diagnosed with psychiatric disorder while the others showed clinical progression consistent with ongoing neurodegeneration and dementia. Within this group, patients whose diagnosis changed after the amyloid-β PET scan were most often reclassified as frontotemporal dementia, and their neuroimaging profiles consistently showed predominant fronto-temporal alterations. In the Aβneg-AD-unchanged group, atrophy and hypometabolism were restricted to the hippocampus, retrosplenial/posterior cingulate cortex. These regions are known to be highly connected and involved in episodic memory (Ranganath and Ritchey, 2012), which is consistent with the predominant episodic memory deficits of these patients. These patients seem likely to harbour a variety of limbic-predominant pathologies affecting the medial temporal lobe. One likely cause may be tangle-predominant dementia. Along the line of the recently termed primary age-related tauopathy, patients with a clinical diagnosis of Alzheimer's disease and neurofibrillary tangles but lacking amyloid-β plaques have been described in many cohorts (Crary *et al.*, 2014). Among clinically diagnosed Alzheimer's disease cases with no or sparse neuritic plaques from autopsy [excluding the cases with a non-Alzheimer's disease pathological diagnosis in Serrano-Pozo *et al.* (2014)], 40–45% had substantial neurofibrillary degeneration (Braak stages ⩾ III) (Serrano-Pozo *et al.*, 2014; Monsell *et al.*, 2015). On the other hand, more than half of amyloid-β-negative patients thus had Braak stages 0/I/II of neurofibrillary tangles, which is insufficient to account for their mild-to-moderate dementia. Additional neuropathologies that specifically target the medial temporal lobe and hippocampal circuit include hippocampal sclerosis (with or without TDP-43-positive inclusions; Nag *et al.*, 2015) and argyrophillic grain disease, a primary tauopathy with inclusions that are morphologically and biochemically distinct from neurofibrillary tangles (Grinberg *et al.*, 2013). Cerebrovascular disease and dementia with Lewy bodies can also mimic typical Alzheimer's disease clinically, though are more often associated with a non-amnestic predominant clinical phenotype. Notably, Serrano-Pozo and colleagues (2014) found essentially no difference in the frequency and severity of concurrent vascular and Lewy body pathologies at autopsy in low versus high amyloid brains of patients diagnosed clinically with Alzheimer's disease. Emerging tau-specific PET ligands may shed further light on the underlying pathology in these patients (Villemagne *et al.*, 2015).

It is particularly striking that amnestic Aβneg-AD-unchanged were comparable to Aβpos-AD in their clinical presentation and trajectories, while they had significantly less atrophy and hypometabolism in extended neocortical brain areas. It is possible that of the presence of atrophy/hypometabolism beyond the hippocampo-posterior cingulate cortex area is at least partly due to the presence of amyloid-β that may facilitate the spread of other pathologies (e.g. tau in Alzheimer's disease) and related neurodegeneration from the initially involved site to distant connected brain regions (i.e. temporo-parietal, precuneus and frontal areas in Alzheimer's disease). The presence of amyloid-β might also partly explain the mismatch between atrophy and hypometabolism patterns typically found in Alzheimer's disease (Chételat *et al.*, 2008; La Joie *et al.*, 2012) but not in the Aβneg-AD.

Non-amnestic and non-specific Aβneg-AD

A second group of Aβneg-AD patients was characterized by non-amnestic predominant clinical presentations. These

patients showed relatively greater impairment in non-memory domains compared to Aβpos-AD and amnestic Aβneg-AD. Predominant deficits in language, executive functions/behaviour and visuospatial function characterize ~15% of patients with Alzheimer's disease presenting to academic dementia centres (Snowden *et al.*, 2007) and even more in early-onset Alzheimer's disease (Mendez *et al.*, 2012). While these presentations are now recognized as Alzheimer's disease phenotypes and are included in newly proposed Alzheimer's disease diagnostic criteria (McKhann *et al.*, 2011; Dubois *et al.*, 2014), these patients also show significant clinical overlap with frontotemporal dementia-spectrum disorders (Alladi *et al.*, 2007; Ossenkoppele *et al.*, 2015*b*). In these cases clinicians changed their clinical diagnosis to frontotemporal dementia-spectrum syndromes (such as behavioural variant frontotemporal dementia, non-fluent variant primary progressive aphasia or corticobasal degeneration), and the topography of atrophy and hypometabolism was consistent with the alterations typically found in frontotemporal dementia (Diehl *et al.*, 2004; Rabinovici *et al.*, 2007), corticobasal degeneration (Lee *et al.*, 2011), and primary progressive aphasia (Nestor *et al.*, 2003; Rabinovici *et al.*, 2008; Gorno-Tempini *et al.*, 2011). These diagnoses remained stable over time.

The third (and smallest) subtype of Aβneg-AD presented with non-specific clinical symptoms and cognitive deficits. In these patients, Alzheimer's disease may have represented a 'default' diagnosis for a condition felt to be neurodegenerative in origin, but failing to conform a clearly described cognitive-behavioural syndrome. This group did not show a clear 'signature' in the post-PET diagnoses (including dementia with Lewy bodies, corticobasal degeneration, and unknown dementia), clinical evolution, cognitive testing or MRI/FDG patterns, reflecting its heterogeneity as well as small numbers. In two cases cognition was stable or even improved at follow-up, suggesting that some non-specific patients, despite meeting criteria for dementia at one point, may not have an underlying neurodegenerative disease. This subtype illustrates the utility of amyloid-β PET for 'ruling-out' Alzheimer's disease in patients with non-specific presentations, and potentially identifying treatable non-degenerative aetiologies in a subset.

Limitations

The lack of autopsy data (except in three cases) is a limitation of the present study as post-mortem analysis would be particularly helpful to our understanding of the aetiology of Aβneg-AD cases. Note that 19% of the cases not meeting full neuropathological criteria for Alzheimer's disease in Beach *et al.* (2012) were nevertheless diagnosed with Alzheimer's disease as the primary cause of dementia, illustrating that histopathological analyses do not always provide a clear answer; in some cases, the pathological processes underlying their dementia might not be identified using current techniques.

Missing information in some participants (e.g. *APOE* status, CSF, cognitive scores) is also a limitation, as well as the fact that the main neuroimaging results are presented at a rather liberal threshold (uncorrected for multiple comparisons). We applied a liberal threshold in the interest of fully describing neuroimaging profiles given our limited sample size and power. While most of our findings did survive at $P_{FWE} < 0.05$, findings at more liberal thresholds should be considered with caution. Note also that we could not assess the potential influence of the CSF results on the diagnosis at any stage of the study as the CSF results were obtained in less than half of the cases, before or after the PET scan, and therefore the impact of CSF results on diagnosis could not be systematically assessed.

Another limitation is the lack of standard cognitive tests and the fact that we compared retrospectively data from different centres so that the diagnoses were established by different multidisciplinary teams and sometimes different cognitive tests and different scanners/scanning parameters were used. Similarly, only clinical follow-up was available in the present study. Future prospective, longitudinal studies including an Aβneg-AD sample tested using a standardized neuropsychological battery will be needed to further assess whether subtle difference in the nature, degree or evolution of cognitive (including episodic memory) deficits are present.

Conclusion

This study shows that Aβneg-AD is neither a rare nor a benign condition. The clinical evolution suggests an underlying neurodegenerative disease in most patients, including those with a typical amnestic presentation or the less typical non-amnestic cases. In the latter, who likely reflect misdiagnosis, amyloid-β PET imaging proved to be useful to rule-out Alzheimer's disease, as shown in previous studies on the clinical impact of amyloid PET imaging. The individual profiles of atrophy and hypometabolism help, not only to find an alternative diagnosis in those cases, but also to detect the cases that might not have a neurodegenerative disease and remain relatively stable clinically. In the amnestic Aβneg-AD cases, however, an alternative diagnosis is not readily apparent: they showed atrophy and hypometabolism restricted to the restrosplenial cortex, have no amyloid, but mimic Alzheimer's disease dementia in their clinical presentation as well as in their clinical trajectory. Based on the current neuropathological definition of Alzheimer's disease, these cases should not be called Alzheimer's disease, but there is a need for a clinical framework and terminology for the classification of these patients, who likely represent a mixed population of limbic-predominant Alzheimer's disease-mimics. Further *in vivo* exploration (including tau-PET imaging) and extensive longitudinal assessment with autopsy data are needed to expand on our understanding of these intriguing clinical cases.

Acknowledgements

Authors are grateful to J. Mutlu, C. Tomadesso, R. de Florès, J. Gonneaud, G. Poisnel, S. Egret, C. Lebouleux, A. Manrique, M-C. Onfroy, L. Barré, A. Abbas, A. Quillard, for their help with recruitment, cognitive testing and imaging examinations. We thank J. Vogel, P. Ghosh and B. Cohn-Sheehy for their help with data collection.

Funding

This study was supported by the Fondation Plan Alzheimer, Programme Hospitalier de Recherche Clinique, Agence Nationale de la Recherche, Région Basse Normandie, Institut National de la Santé et de la Recherche Médicale (Caen). This research was also funded by NIA P01-AG1972403 (B.L.M.), and ADRC P50-AG023501 (B.L.M. and G.D.R.), Alzheimer's Association (G.D.R.), State of California DHS 04-33516 (B.L.M.), John Douglas French Alzheimer's Foundation (B.L.M. and G.D.R.), Avid Radiopharmaceticals (G.D.R.), NHMRC project grant 1071430 (V.L.V. and C.C.R.) and Senior Research Fellowship (V.L.V.). In addition, this research was funded by Marie Curie FP7 International Outgoing Fellowship [628812] (R.O.); The donors of [Alzheimer's Disease Research], a program of BrightFocus Foundation (R.O.). Research of the VUmc Alzheimer centre is part of the neurodegeneration research program of the Neuroscience Campus Amsterdam. The VUmc Alzheimer Centre is supported by Stichting Alzheimer Nederland and Stichting VUmc fonds. PET scans were performed within the framework of CTMM, the Centre for Translational Molecular Medicine (www.ctmm.nl), project LeARN (grant 02N-101). This work was also financially supported by the Internationale Stichting Alzheimer Onderzoek (ISAO, grant 05512) and the American Health Assistance Foundation (AHAF, grant A2005-026).

Supplementary material

Supplementary material is available at *Brain* online.

References

Alladi S, Xuereb J, Bak T, Nestor P, Knibb J, Patterson K, et al. Focal cortical presentations of Alzheimer's disease. Brain 2007; 130: 2636–45.

Beach TG, Monsell SE, Phillips LE, Kukull W. Accuracy of the clinical diagnosis of alzheimer disease at national institute on aging Alzheimer Disease Centers, 2005–2010. J Neuropathol Exp Neurol 2012; 71: 266–73.

Blennow K, Hampel H, Weiner M, Zetterberg H. Cerebrospinal fluid and plasma biomarkers in Alzheimer disease. Nat Rev Neurol 2010; 6: 131–44.

Cairns NJ, Ikonomovic MD, Benzinger T, Storandt M, Fagan AM, Shah AR, et al. Absence of Pittsburgh compound B detection of cerebral amyloid beta in a patient with clinical, cognitive, and cerebrospinal fluid markers of Alzheimer disease: a case report. Arch Neurol 2009; 66: 1557–62.

Chételat G, Desgranges B, Landeau B, Mézenge F, Poline JB, de la Sayette V, et al. Direct voxel-based comparison between grey matter hypometabolism and atrophy in Alzheimer's disease. Brain 2008; 131: 60–71.

Crary JF, Trojanowski JQ, Schneider JA, Abisambra JF, Abner EL, Alafuzoff I, et al. Primary age-related tauopathy (PART): a common pathology associated with human aging. Acta Neuropathol 2014; 128: 755–66.

Diehl J, Grimmer T, Drzezga A, Riemenschneider M, Förstl H, Kurz A. Cerebral metabolic patterns at early stages of frontotemporal dementia and semantic dementia. A PET study. Neurobiol Aging 2004; 25: 1051–6.

Doraiswamy PM, Sperling RA, Coleman RE, Johnson KA, Reiman EM, Davis MD, et al. Amyloid-β assessed by florbetapir F 18 PET and 18-month cognitive decline: a multicenter study. Neurology 2012; 79: 1636–44.

Dubois B, Feldman HH, Jacova C, Hampel H, Molinuevo JL, Blennow K, et al. Advancing research diagnostic criteria for Alzheimer's disease: the IWG-2 criteria. Lancet Neurol 2014; 13: 614–29.

Duits FH, Teunissen CE, Bouwman FH, Visser P-J, Mattsson N, Zetterberg H, et al. The cerebrospinal fluid 'Alzheimer profile': easily said, but what does it mean? Alzheimers Dement 2014; 10: 713–723.e2.

Fouquet M, Besson FL, Gonneaud J, La Joie R, Chételat G. Imaging brain effects of APOE4 in cognitively normal individuals across the lifespan. Neuropsychol Rev 2014; 24: 290–9.

Gorno-Tempini ML, Hillis AE, Weintraub S, Kertesz A, Mendez M, Cappa SF, et al. Classification of primary progressive aphasia and its variants. Neurology 2011; 76: 1006–14.

Grinberg LT, Wang X, Wang C, Sohn PD, Theofilas P, Sidhu M, et al. Argyrophilic grain disease differs from other tauopathies by lacking tau acetylation. Acta Neuropathol 2013; 125: 581–93.

Hyman BT, Phelps CH, Beach TG, Bigio EH, Cairns NJ, Carrillo MC, et al. National Institute on Aging–Alzheimer's Association guidelines for the neuropathologic assessment of Alzheimer's disease. Alzheimers Dement 2012; 8: 1–13.

Jagust WJ, Bandy D, Chen K, Foster NL, Landau SM, Mathis CA, et al. The Alzheimer's Disease Neuroimaging Initiative positron emission tomography core. Alzheimers Dement 2010; 6: 221–9.

Jansen WJ, Ossenkoppele R, Knol DL, Tijms BM, Scheltens P, Verhey FRJ, et al. Prevalence of cerebral amyloid pathology in persons without dementia: a meta-analysis. JAMA 2015; 313: 1924–38.

Johnson KA, Minoshima S, Bohnen NI, Donohoe KJ, Foster NL, Herscovitch P, et al. Update on appropriate use criteria for amyloid PET imaging: dementia experts, mild cognitive impairment, and education. Amyloid Imaging Task Force of the Alzheimer's Association and Society for Nuclear Medicine and Molecular Imaging. Alzheimers Dement 2013; 9: e106–9.

Klunk WE, Engler H, Nordberg A, Wang Y, Blomqvist G, Holt DP, et al. Imaging brain amyloid in Alzheimer's disease with Pittsburgh Compound-B. Ann Neurol 2004; 55: 306–19.

La Joie R, Perrotin A, Barré L, Hommet C, Mézenge F, Ibazizene M, et al. Region-specific hierarchy between atrophy, hypometabolism, and β-amyloid (Aβ) load in Alzheimer's disease dementia. J Neurosci 2012; 32: 16265–73.

Lee SE, Rabinovici GD, Mayo MC, Wilson SM, Seeley WW, DeArmond SJ, et al. Clinicopathological correlations in corticobasal degeneration. Ann Neurol 2011; 70: 327–40.

Leinonen V, Alafuzoff I, Aalto S, Suotunen T, Savolainen S, Någren K, et al. Assessment of beta-amyloid in a frontal cortical brain biopsy specimen and by positron emission tomography with carbon 11-labeled Pittsburgh Compound B. Arch Neurol 2008; 65: 1304–9.

Liu E, Schmidt ME, Margolin R, Sperling R, Koeppe R, Mason NS, et al. Amyloid-β 11C-PiB-PET imaging results from 2 randomized bapineuzumab phase 3 AD trials. Neurology 2015; 85: 692–700.

Mackenzie IRA, Neumann M, Bigio EH, Cairns NJ, Alafuzoff I, Kril J, et al. Nomenclature and nosology for neuropathologic subtypes of frontotemporal lobar degeneration: an update. Acta Neuropathol 2010; 119: 1–4.

McKhann G, Drachman D, Folstein M, Katzman R, Price D, Stadlan EM. Clinical diagnosis of Alzheimer's disease: report of the NINCDS-ADRDA Work Group under the auspices of Department of Health and Human Services Task Force on Alzheimer's Disease. Neurology 1984; 34: 939–44.

McKhann GM, Knopman DS, Chertkow H, Hyman BT, Jack CR, Jr, Kawas CH, et al. The diagnosis of dementia due to Alzheimer's disease: recommendations from the National Institute on Aging-Alzheimer's Association workgroups on diagnostic guidelines for Alzheimer's disease. Alzheimers Dement 2011; 7: 263–9.

Mendez MF, Lee AS, Joshi A, Shapira JS. Nonamnestic presentations of early-onset Alzheimer's disease. Am J Alzheimers Dis Other Demen 2012; 27: 413–20.

Mevel K, Landeau B, Fouquet M, La Joie R, Villain N, Mézenge F, et al. Age effect on the default mode network, inner thoughts, and cognitive abilities. Neurobiol Aging 2013; 34: 1292–301.

Monsell SE, Kukull WA, Roher AE, Maarouf CL, Serrano G, Beach TG, et al. Characterizing apolipoprotein E ε4 carriers and noncarriers with the clinical diagnosis of mild to moderate alzheimer dementia and minimal β-amyloid peptide plaques. JAMA Neurol 2015; 72: 1124–31.

Mormino EC, Kluth JT, Madison CM, Rabinovici GD, Baker SL, Miller BL, et al. Episodic memory loss is related to hippocampal-mediated beta-amyloid deposition in elderly subjects. Brain 2009; 132: 1310–23.

Nag S, Yu L, Capuano AW, Wilson RS, Leurgans SE, Bennett DA, et al. Hippocampal sclerosis and TDP-43 pathology in aging and Alzheimer disease. Ann Neurol 2015; 77: 942–52.

Nestor PJ, Caine D, Fryer TD, Clarke J, Hodges JR. The topography of metabolic deficits in posterior cortical atrophy (the visual variant of Alzheimer's disease) with FDG-PET. J Neurol Neurosurg Psychiatry 2003; 74: 1521–9.

Ossenkoppele R, Jansen WJ, Rabinovici GD, Knol DL, van der Flier WM, van Berckel BNM, et al. Prevalence of amyloid PET positivity in dementia syndromes: a meta-analysis. JAMA 2015a; 313: 1939–49.

Ossenkoppele R, Pijnenburg YAL, Perry DC, Cohn-Sheehy BI, Scheltens NME, Vogel JW, et al. The behavioural/dysexecutive variant of Alzheimer's disease: clinical, neuroimaging and pathological features. Brain 2015b; 138: 2732–49.

Ossenkoppele R, Prins ND, Pijnenburg YAL, Lemstra AW, van der Flier WM, Adriaanse SF, et al. Impact of molecular imaging on the diagnostic process in a memory clinic. Alzheimers Dement 2013; 9: 414–21.

Ossenkoppele R, Zwan MD, Tolboom N, van Assema DME, Adriaanse SF, Kloet RW, et al. Amyloid burden and metabolic function in early-onset Alzheimer's disease: parietal lobe involvement. Brain 2012; 135: 2115–25.

Palmqvist S, Zetterberg H, Blennow K, Vestberg S, Andreasson U, Brooks DJ, et al. Accuracy of brain amyloid detection in clinical practice using cerebrospinal fluid β-amyloid 42: a cross-validation study against amyloid positron emission tomography. JAMA Neurol 2014; 71: 1282–9.

Rabinovici GD, Jagust WJ, Furst AJ, Ogar JM, Racine CA, Mormino EC, et al. Abeta amyloid and glucose metabolism in three variants of primary progressive aphasia. Ann Neurol 2008; 64: 388–401.

Rabinovici GD, Seeley WW, Kim EJ, Gorno-Tempini ML, Rascovsky K, Pagliaro TA, et al. Distinct MRI atrophy patterns in autopsy-proven Alzheimer's disease and frontotemporal lobar degeneration. Am J Alzheimers Dis Other Demen 2007; 22: 474–88.

Ranganath C, Ritchey M. Two cortical systems for memory-guided behaviour. Nat Rev Neurosci 2012; 13: 713–26.

Rosen RF, Ciliax BJ, Wingo TS, Gearing M, Dooyema J, Lah JJ, et al. Deficient high-affinity binding of Pittsburgh compound B in a case of Alzheimer's disease. Acta Neuropathol 2010; 119: 221–33.

Rowe CC, Ellis KA, Rimajova M, Bourgeat P, Pike KE, Jones G, et al. Amyloid imaging results from the Australian Imaging, Biomarkers and Lifestyle (AIBL) study of aging. Neurobiol Aging 2010; 31: 1275–83.

Salloway S, Sperling R, Fox NC, Blennow K, Klunk W, Raskind M, et al. Two phase 3 trials of bapineuzumab in mild-to-moderate Alzheimer's disease. N Engl J Med 2014; 370: 322–33.

Sánchez-Juan P, Ghosh PM, Hagen J, Gesierich B, Henry M, Grinberg LT, et al. Practical utility of amyloid and FDG-PET in an academic dementia center. Neurology 2014; 82: 230–8.

Schöll M, Wall A, Thordardottir S, Ferreira D, Bogdanovic N, Långström B, et al. Low PiB PET retention in presence of pathologic CSF biomarkers in Arctic APP mutation carriers. Neurology 2012; 79: 229–36.

Serrano-Pozo A, Qian J, Monsell SE, Blacker D, Gómez-Isla T, Betensky RA, et al. Mild to moderate Alzheimer dementia with insufficient neuropathological changes. Ann Neurol 2014; 75: 597–601.

Shaw LM, Vanderstichele H, Knapik-Czajka M, Clark CM, Aisen PS, Petersen RC, et al. Cerebrospinal fluid biomarker signature in Alzheimer's disease neuroimaging initiative subjects. Ann Neurol 2009; 65: 403–13.

Shimada H, Ataka S, Takeuchi J, Mori H, Wada Y, Watanabe Y, et al. Pittsburgh compound B-negative dementia: a possibility of misdiagnosis of patients with non-alzheimer disease-type dementia as having AD. J Geriatr Psychiatry Neurol 2011; 24: 123–6.

Snowden JS, Stopford CL, Julien CL, Thompson JC, Davidson Y, Gibbons L, et al. Cognitive phenotypes in Alzheimer's disease and genetic risk. Cortex J Devoted Study Nerv Syst Behav 2007; 43: 835–45.

Sperling R, Mormino E, Johnson K. The evolution of preclinical Alzheimer's disease: implications for prevention trials. Neuron 2014; 84: 608–22.

Takeuchi J, Shimada H, Ataka S, Kawabe J, Mori H, Mizuno K, et al. Clinical features of Pittsburgh compound-B-negative dementia. Dement Geriatr Cogn Disord 2012; 34: 112–20.

Vandenberghe R, Van Laere K, Ivanoiu A, Salmon E, Bastin C, Triau E, et al. 18F-flutemetamol amyloid imaging in Alzheimer disease and mild cognitive impairment: a phase 2 trial. Ann Neurol 2010; 68: 319–29.

Vann SD, Aggleton JP, Maguire EA. What does the retrosplenial cortex do? Nat Rev Neurosci 2009; 10: 792–802.

Villemagne VL, Fodero-Tavoletti MT, Masters CL, Rowe CC. Tau imaging: early progress and future directions. Lancet Neurol 2015; 14: 114–24.

Villemagne VL, Pike KE, Chételat G, Ellis KA, Mulligan RS, Bourgeat P, et al. Longitudinal assessment of Aβ and cognition in aging and Alzheimer disease. Ann Neurol 2011; 69: 181–92.

Zwan M, van Harten A, Ossenkoppele R, Bouwman F, Teunissen C, Adriaanse S, et al. Concordance between cerebrospinal fluid biomarkers and [11C]PIB PET in a memory clinic cohort. J Alzheimers Dis 2014; 41: 801–7.