Guiding Antiepileptic Therapy in a Pediatric Patient with Severe Meningoencephalitis and Decompressive Craniectomy with the Use of Amplitude-Integrated Electroencephalography

Karl F. Schettler[1] Beatrice Heineking[1] Silvia Fernandez-Rodriguez[1] Angelika Pilger[1] Nikolaus Alexander Haas[1]

[1] Department of Pediatric Cardiology and Pediatric Intensive Care, Campus Grosshadern of the Ludwig Maximilians University, Munich, Germany

J Pediatr Intensive Care 2017;6:136–141.

Address for correspondence Karl F. Schettler, MHBA, Department of Pediatric Cardiology and Pediatric Intensive Care, Campus Grosshadern of the Ludwig Maximilians University, Marchioninistreet 15, 81377 Munich, Germany (e-mail: Karl.Florian@Schettler.eu).

Abstract

Introduction Amplitude-integrated electroencephalography (aEEG) is one of the most widely used neuromonitoring tools in neonatology today. However, little is known about its clinical indications and potential benefits in pediatric intensive care patients. Based on limited experience, its impact on therapeutic decision-making in this patient population is unclear.

Case Description We report the case of a 16-year-old boy who, after a pansinusitis, developed a severe meningoencephalitis and intracranial empyema with increased intracranial pressure that required drainage and decompressive craniectomy. He subsequently developed status epilepticus despite a combination of various anticonvulsants. Only after the initialization of an aEEG, we were able to adequately diagnose and continuously monitor his seizure activity and titrate the effect of the antiepileptic drugs. During his hospital stay, we were able to clearly monitor and guide our therapy by accurately identifying the termination of status epilepticus and the recurrence of seizures.

Discussion With the help of aEEG, it was easy to identify the nonconvulsive status epilepticus (NCSE) and the ongoing seizure activity in this teenage patient. NCSE is a clinical problem with an effect on the outcome of the patient and is often underdiagnosed. AEEG enabled a rapid detection and management of seizure activity and thereby reduced the overall seizure burden, which was associated with better neurologic outcome.

Keywords
- amplitude-integrated EEG
- antiepileptic therapy
- meningoencephalitis
- neuromonitoring
- nonconvulsive status epilepticus

Introduction

Amplitude-integrated electroencephalography (aEEG) was developed and first used in the 1960s by Maynard et al.[1] It is a simplified method to monitor brain activity by a filtered and time-compressed visualization of the amplitudes from a classic raw EEG in a semilogarithmic display. In the beginning, it was only an one-channel analog method with crosscerebral recording, but now it has developed into a two-channel digital aEEG, which allows side differentiation of the signal from the brain and records the corresponding raw EEG. With its use in the hypothermia studies in neonatology, it has become a standard for

received
April 3, 2016
accepted after revision
July 1, 2016
published online
August 8, 2016

Copyright © 2017 by Georg Thieme Verlag KG, Stuttgart · New York

DOI http://dx.doi.org/10.1055/s-0036-1587328.
ISSN 2146-4618.

This document was downloaded for personal use only. Unauthorized distribution is strictly prohibited.

neuromonitoring in neonates.[2] The main indications for monitoring with an aEEG in neonatology are asphyxia[3] and seizure detection.[4] Numerous other possibilities of use of aEEG have been published in neonatal patients, such as monitoring brain activity after intracranial hemorrhage,[5] posthemorrhagic ventricular dilation,[6] metabolic encephalopathy,[7] and predicting outcome in preterm infants.[8]

Despite the very successful and promising indications in neonatology, aEEG has been rarely used in the pediatric intensive care or adult setting. Mainly brief reports and case reports have been published thus far.[9] Neuromonitoring in the pediatric intensive care unit may be beneficial in cardiac surgery,[10] neurocritical care,[11] severe metabolic conditions,[7] and various forms of epilepsy that are difficult to treat.[12]

We describe a case of a teenage patient with severe neurologic pathology, where we continuously monitored seizure and electrical brain activity. With the help of aEEG, we had a convenient, safe, and easily applied method to better identify and treat nonconvulsive status epilepticus (NCSE) and the ensuing clinical seizure activity.

Case Description

Our patient is a 16-year-old boy with an unremarkable medical history except for a small posterior cleft palate surgically repaired in infancy. He had a prior upper respiratory tract infection with sinusitis, and 1 week before admission, he suffered a head injury while playing sports and subsequently developed a left-sided headache. He presented to an outside hospital with increasing neck pain, vomiting, and fluctuating levels of consciousness. Cranial computed tomography (CT) revealed left-sided hemispheric generalized swelling, midline shift, and diminished sulci. Meningitis doses of cefotaxime were administered to the patient. His initial Glasgow Coma Scale (GCS) was 11. A magnetic resonance imaging was performed the next day that revealed an enlarging subdural empyema over the left hemisphere. Because of signs of increased intracranial pressure, he was transferred by helicopter to our pediatric intensive care unit for further treatment.

After admission to our hospital, removal of the empyema was immediately performed and abscesses in the paranasal sinuses were drained, followed by decompressive craniectomy. He was admitted to our pediatric intensive care unit and extubated. Initially, he was able to move his arms and to speak single words. In the next 2 hours, he developed inadequate fixation with his eyes for periods of up to 2 minutes and short rhythmic movements with his right hand. Focal seizure activity was clinically presumed and levetiracetam was started to treat the seizures. Over the next 12 hours, the patient gradually became less responsive with GCS of 5–8. Cranial CT revealed progressive brain herniation due to increasing cerebral edema (►**Fig. 1**). After deterioration of GCS < 5, the patient was intubated and aEEG was started to assist with neuromonitoring of the patient. Immediately after the aEEG was started, it revealed status epilepticus with a classic "saw-tooth pattern" (►**Fig. 2**, arrow 1). An extra dose of levetiracetam was given and the dosing was increased to 35 mg/kg/day. At this point, no obvious clinical seizures were present, only slight movements of the mouth. The amplitude-integrated EEG revealed no change in the status epilepticus and, therefore, a total dose of 2 mg of lorazepam was given intravenously (►**Fig. 2**, arrow 2). The amplitude-integrated EEG changed from status epilepticus to an identifiable continuous background pattern. However, within the continuous

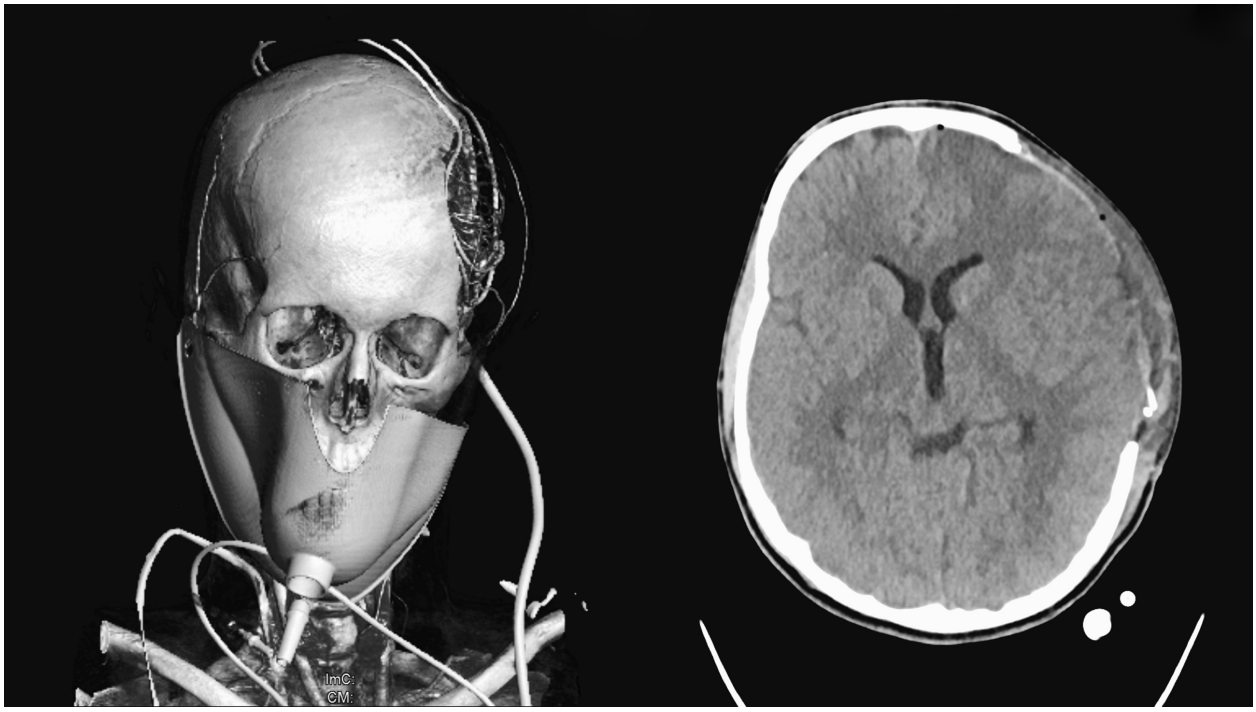

Fig. 1 Cranial computed tomography showing the herniation of the left side of the brain after decompressive craniectomy.

This document was downloaded for personal use only. Unauthorized distribution is strictly prohibited.

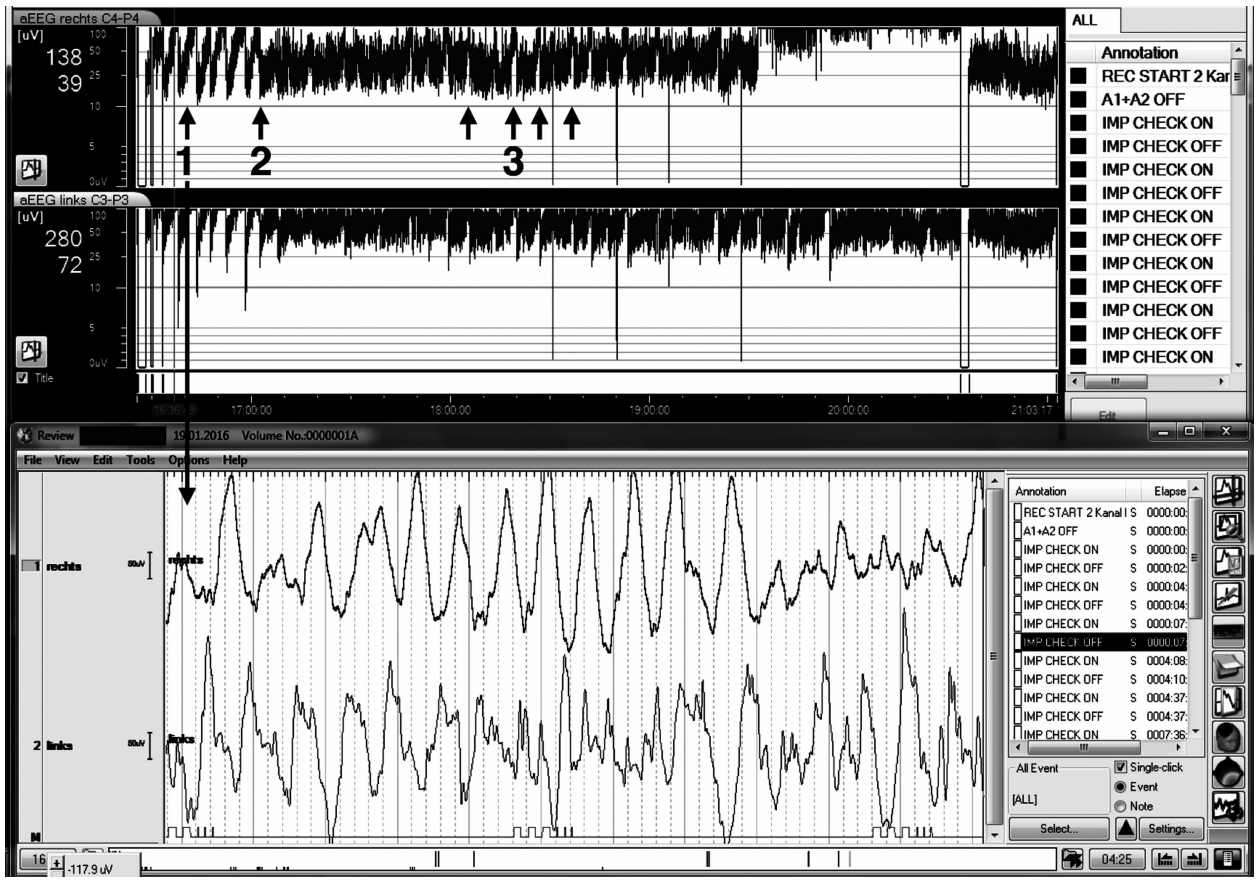

Fig. 2 Initial hours of amplitude-integrated electroencephalography (aEEG) monitoring. The upper two graphs show the right- and left-sided aEEG recording over 4 hours. The lower two graphs show the right- and left-sided actual raw EEG during the status epilepticus, which shows in the aEEG with a classic saw-tooth pattern (arrow 1). After intravenous application of lorazepam, the pattern changes and a background pattern becomes recognizable (arrow 2). But the patient showed continued seizure activity within a continuous background pattern (arrow 3).

pattern, repeated seizures were still identified (►**Fig. 2**, arrow 3) and, therefore, status epilepticus was ongoing. Because of the ineffectiveness of levetiracetam and lorazepam in combination to terminate the seizure activity, we started phenytoin of 15 mg/kg and 1 hour later a second dose of 10 mg/kg. After the second dose, the aEEG showed a major improvement in brain activity with termination of the status epilepticus. Only single pathological spike–wave complexes and very short single seizure activity were occasionally seen in the raw EEG recording (►**Fig. 3**). Phenytoin was continued at 3.5 mg/kg/day intravenously. After 3 hours, short single seizures again could be identified in the aEEG (►**Fig. 4**). An additional dose of levetiracetam was given and total dosage was increased to 50 mg/kg/day, which sufficiently terminated these single seizures. 36 hours after the identification of status epilepticus by the aEEG, the patient was free of any further seizure activity under therapy with levetiracetam and phenytoin and aEEG revealed a continuous background pattern (►**Fig. 5**). After another 48 hours of neuromonitoring and the absence of seizures, we discontinued phenytoin and continued with levetiracetam monotherapy at the same dose. We monitored the patient with aEEG for 3 more days, but no further seizure activity was observed. The patient was discharged to rehabilitation 37 days after admission with only mild impairment of the fine motor skills of his right hand.

Discussion

Existing guidelines for adult patients recommend an EEG for patients with encephalitis, who are comatose or have unexplained neurologic deficits, to rule out NCSE, as in this case.[13] "NCSE is a term used to denote a range of conditions in which electrographic seizure activity is prolonged and results in nonconvulsive clinical symptoms."[14] NCSE is a clinical problem with an effect on the outcome of the patient and is often underdiagnosed.[15]

Seizures have been identified as a predictor for an adverse outcome in many different neurologic pathologies: pediatric arterial ischemic stroke,[16] patients with central nervous system infections,[17,18] metabolic diseases,[19] and more.

Not only the general presence of seizures, but also the overall seizure burden including seizure frequency and duration is important with regard to the neurologic outcome.[20,21]

Currently, most information regarding seizures in pediatric intensive care units is obtained by EEGs with 21 electrodes either as single recording for 30 to 60 minutes or as a continuous EEG for 12 to 48 hours. Continuous EEG monitoring is considered essential to titrate antiepileptic therapy in recurrent status epilepticus and to identify recurrent NCSE.[22]

Amplitude-integrated EEG has become a widely accepted standard for neuromonitoring in neonatology[2] and, therefore,

This document was downloaded for personal use only. Unauthorized distribution is strictly prohibited.

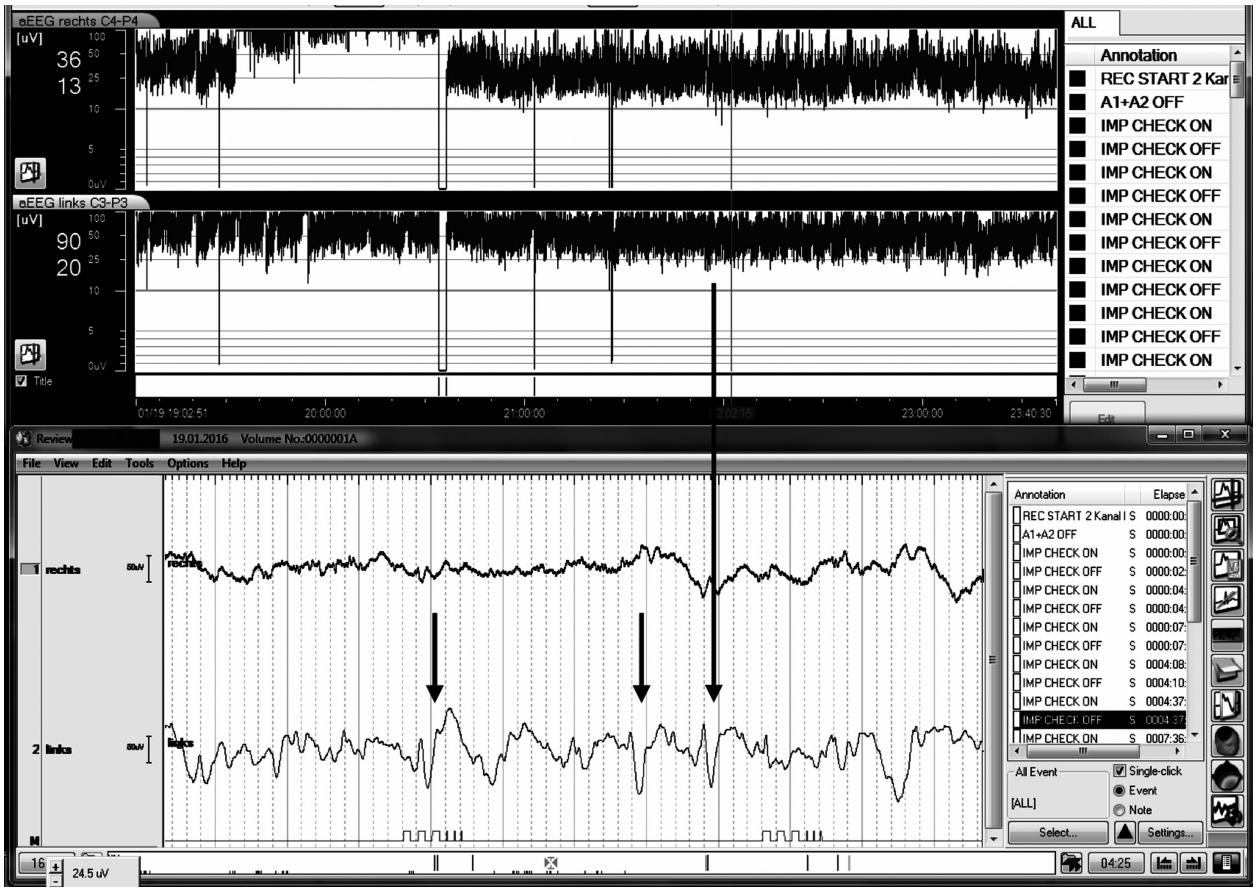

Fig. 3 Terminated seizure activity with rarely identifiable epileptiform patterns in the raw electroencephalogram.

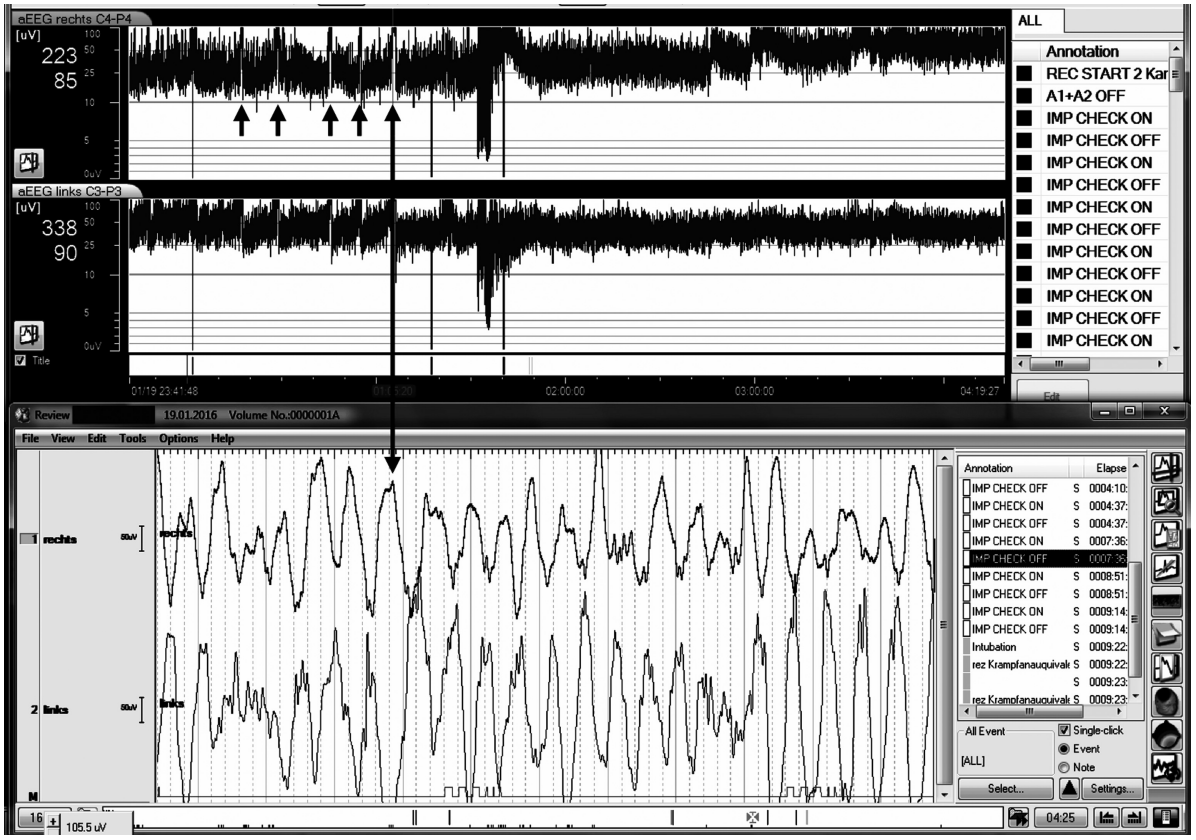

Fig. 4 Increasing repeated seizure activity marked with arrows.

This document was downloaded for personal use only. Unauthorized distribution is strictly prohibited.

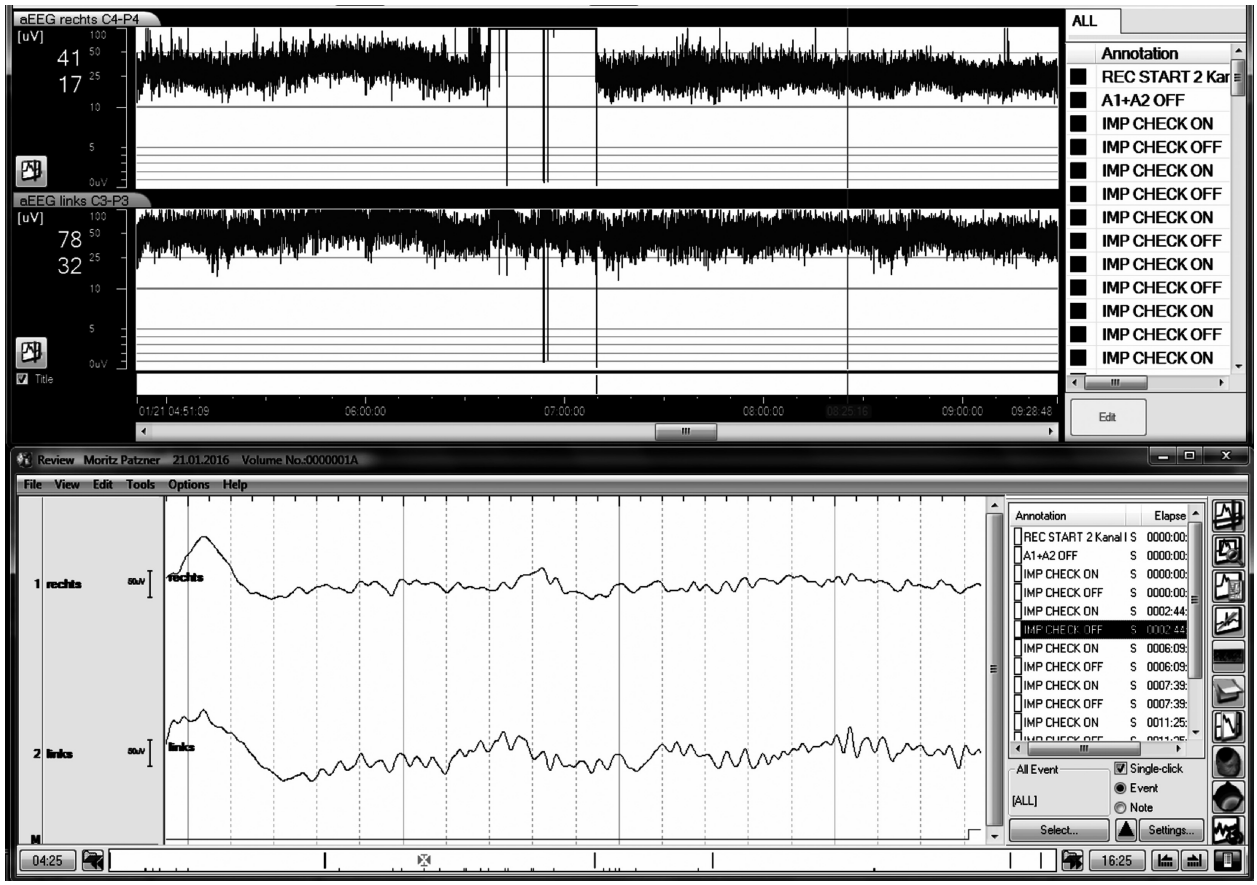

Fig. 5 Final seizure free continuous background pattern of the patient. Elevation of the signal in the middle of the recording on the right side was caused by artifacts.

many intensive care pediatricians who also trained in neonatology feel comfortable in using it. AEEG has the advantage of being easy to use, as it is easier to read and understand than a classic raw EEG. Because of its time-compressed signal, it is more suitable for long-term monitoring of intensive care unit patients. Indications and usefulness in neonatology include hypoxic-ischemic encephalopathy,[3] seizure detection and monitoring,[4] posthemorrhagic ventricular dilation,[6] and other forms of increased intracranial pressure, as well as encephalopathy in inborn errors of metabolism.[7] It also may be used in prediction of neurologic outcome in very small preterm infants.[8]

So far, the use of aEEG in children is mainly reported in case reports.[9] Applying some form of continuous neuromonitoring may clearly be beneficial for the pediatric intensive care unit, especially in patients with epilepsy.[23] Recently, aEEG also has been presented as a useful monitoring tool in adults with cardiac arrest.[24] Because of its ease of use, even for nonexperts in the field, aEEG has utility for the identification of seizures and for monitoring of appropriate treatment.[25]

In our case, aEEG allowed us to clearly identify the seizure activity with a higher level of certainty and helped us guide our antiepileptic therapy. As a result, we could minimize the seizure burden of our patient and, therefore, might have improved the overall neurologic outcome of the patient. The aEEG was easy to apply and to interpret in our pediatric intensive care setting. In addition, the aEEG helped us to identify the termination of seizures and, therefore, allowed us to reduce the number of antiepileptic drugs as early as possible. In addition, there was always the safety of rapid recognition if seizure activity recurred.

The reduced montage of 5 electrodes for the aEEG was sufficient in this case; guidelines consider the recommendations for using a standard montage with 21 electrodes weak with poor quality of evidence (grade 2c).[13] Nevertheless, the use of a reduced montage of electrodes is expected to result in lower sensitivity in seizure detection. The sensitivity in a montage with 7 electrodes has been reported as 93%[26] and in a montage with 4 electrodes as 68%.[27] The sensitivity of aEEG for seizure detection in pediatric patients still needs to be clarified; but in a hospital setting, where full EEG recording and assessment is not always available 24 hours per day and 7 days per week, aEEG might be a useful alternative.

In conclusion, we clearly saw a benefit for our patient and his medical treatment. Amplitude-integrated EEG is a helpful and easy-to-use tool in the pediatric intensive care setting. We believe that aEEG could be a valuable tool for use in pediatric neurocritical pathologies such as severe meningitis, traumatic brain injury, brain edema after ketoacidosis, and so on, especially if continuous EEG recording and assessment is not immediately available.

This document was downloaded for personal use only. Unauthorized distribution is strictly prohibited.

References

1 Maynard D, Prior PF, Scott DF. Device for continuous monitoring of cerebral activity in resuscitated patients. BMJ 1969;4(5682):545–546
2 Toet MC, Lemmers PMA. Brain monitoring in neonates. Early Hum Dev 2009;85(2):77–84
3 Yin X-J, Wei W, Han T, et al. Value of amplitude-integrated electroencephalograph in early diagnosis and prognosis prediction of neonatal hypoxic-ischemic encephalopathy. Int J Clin Exp Med 2014;7(4):1099–1104
4 Zhang D, Ding H, Liu L, et al. The prognostic value of amplitude-integrated eeg in full-term neonates with seizures. PLoS ONE 2013;8(11):e78960. Doi: 10.1371/journal.pone.0078960
5 Sohn JA, Kim HS, Lee EH, et al. Developmental change of amplitude-integrated electroencephalographic activity in preterm infants with intraventricular hemorrhage. Early Hum Dev 2013; 89(12):961–966
6 Olischar M, Klebermass K, Kuhle S, Hulek M, Messerschmidt A, Weninger M. Progressive posthemorrhagic hydrocephalus leads to changes of amplitude-integrated EEG activity in preterm infants. Childs Nerv Syst 2004;20(1):41–45
7 Olischar M, Shany E, Aygün C, et al. Amplitude-integrated electroencephalography in newborns with inborn errors of metabolism. Neonatology 2012;102(3):203–211
8 Song J, Xu F, Wang L, et al. Early amplitude-integrated electroencephalography predicts brain injury and neurological outcome in very preterm infants. Sci Rep 2015;5:13810. Doi: 10.1038/srep13810
9 Igarashi A, Okumura A, Komatsu M, et al. Amplitude-integrated EEG revealed nonconvulsive status epilepticus in children with non-accidental head injury. Eur J Paediatr Neurol 2014;18(6): 806–810
10 Mittnacht AJ, Rodriguez-Diaz C. Multimodal neuromonitoring in pediatric cardiac anesthesia. Ann Card Anaesth 2014;17(1):25–32
11 Galgano MA, Tovar-Spinoza Z. Multimodality neuromonitoring in pediatric neurocritical care: review of the current resources. Cureus 2015;7(11):e385. Doi: 10.7759/cureus.385
12 Glass HC, Wusthoff CJ, Shellhaas RA. Amplitude integrated EEG: the child neurologist's perspective. J Child Neurol 2013;28(10): 1342–1350
13 Claassen J, Taccone FS, Horn P, Holtkamp M, Stocchetti N, Oddo M; Neurointensive Care Section of the European Society of Intensive Care Medicine. Recommendations on the use of EEG monitoring in critically ill patients: consensus statement from the neurointensive care section of the ESICM. Intensive Care Med 2013;39(8):1337–1351
14 Walker M, Cross H, Smith S, et al. Nonconvulsive status epilepticus: Epilepsy Research Foundation workshop reports. Epileptic Disord 2005;7(3):253–296
15 Korff CM, Nordli DR Jr. Diagnosis and management of nonconvulsive status epilepticus in children. Nat Clin Pract Neurol 2007;3(9): 505–516
16 Mallick AA, Ganesan V, Kirkham FJ, et al. Outcome and recurrence one year after paediatric arterial ischaemic stroke in a population-based cohort. Ann Neurol 2016. Doi: 10.1002/ana.24626
17 Lingappa L, Konanki R, Patel R, Vooturi S, Jayalakshmi S. Clinical profile and outcome of refractory convulsive status epilepticus in older children from a developing country. Seizure 2016;36:31–35
18 Kim YS, Jung KH, Lee ST, et al. Prognostic value of initial standard EEG and MRI in patients with herpes simplex encephalitis. J Clin Neurol 2016;12(2):224–229
19 Singh A, Lomash A, Pandey S, Kapoor S. Clinical, biochemical and outcome profile of biotinidase deficient patients from tertiary centre in Northern India. J Clin Diagn Res 2015;9(12):SC08–SC10
20 Pardo AC. Impact of seizure burden in hypoxic ischemic encephalopathy. Pediatr Neurol Briefs 2015;29(10):74. Doi: 10.15844/pedneurbriefs-29-10-1
21 Hocker SE, Britton JW, Mandrekar JN, Wijdicks EF, Rabinstein AA. Predictors of outcome in refractory status epilepticus. JAMA Neurol 2013;70(1):72–77
22 Claassen J, Hirsch LJ, Emerson RG, Bates JE, Thompson TB, Mayer SA. Continuous EEG monitoring and midazolam infusion for refractory nonconvulsive status epilepticus. Neurology 2001; 57(6):1036–1042
23 Hyllienmark L, Amark P. Continuous EEG monitoring in a paediatric intensive care unit. Eur J Paediatr Neurol 2007;11(2):70–75
24 Friberg H, Westhall E, Rosén I, Rundgren M, Nielsen N, Cronberg T. Clinical review: continuous and simplified electroencephalography to monitor brain recovery after cardiac arrest. Crit Care 2013; 17(4):233. Doi: 10.1186/cc12699
25 Dericioglu N, Yetim E, Bas DF, et al. Non-expert use of quantitative EEG displays for seizure identification in the adult neuro-intensive care unit. Epilepsy Res 2015;109:48–56
26 Karakis I, Montouris GD, Otis JA, et al. A quick and reliable EEG montage for the detection of seizures in the critical care setting. J Clin Neurophysiol 2010;27(2):100–105
27 Young GB, Sharpe MD, Savard M, Al Thenayan E, Norton L, Davies-Schinkel C. Seizure detection with a commercially available bedside EEG monitor and the subhairline montage. Neurocrit Care 2009;11(3):411–416

This document was downloaded for personal use only. Unauthorized distribution is strictly prohibited.