Cardiac magnetic resonance techniques: Our experience on wide bore 3 tesla magnetic resonance system

Onkar B Auti[1,2], Kalashree Bandekar[2], Nikhil Kamat[2], Vimal Raj[1]

[1]Department of Radio-diagnosis, Narayana Health City, Bengaluru, Karnataka, [2]Department of Radio-diagnosis, Jupiter Hospital, Thane, Maharashtra, India

Correspondence: Dr. Onkar B Auti, Narayana Health City, Bommasandra, Bangalore - 560 099, Karnataka, India.
E-mail: auti.onkar@gmail.com

Abstract

Cardiovascular magnetic resonance (CMR) has become a widely adapted imaging modality in the diagnosis and management of patients with cardiovascular diseases. It provides unparalleled data of cardiac function and myocardial morphology. Majority of CMR imaging is currently being performed on 1.5 Tesla (T) MR systems. Over the last many years, the cardiac imaging protocols have been standardized and optimized in the 1.5T systems. 3T MR systems are now being used more and more in small and large institutions in our country due to their proven advantages in the field of neuro, body, and musculoskeletal imaging. Cardiac imaging on 3T system can be a double-edged sword. On one hand, it may provide nondiagnostic images due to significant artifacts, and on the other hand, it may complete the examination in quick time and provide excellent quality images. It is therefore important for the user to be aware of the potential pitfalls of CMR in 3T systems and also the necessary steps to avoid them. In this study, we discuss various challenges and advantages of performing CMR in a 3T system. We also present potential technical solutions to improve the image quality.

Key words: 3T magnetic resonance (MR) system; cardiac MR; Cardiovascular magnetic resonance techniques

Introduction

Cardiovascular magnetic resonance (CMR) has become a widely adapted imaging modality for the diagnosis of cardiovascular diseases.[1] CMR provides unparalleled data of cardiac function and myocardial morphology. Adaptation of CMR in day-to-day clinical practice has been relatively slow in India, primarily due to lack of appropriate expertise and wide availability of technology. A 1.5 Tesla (T) strength MR system has now become the workhorse of MR imaging worldwide. This is true for CMR also, and over the last couple of decades, CMR protocols on 1.5 T systems have been standardized and optimized to provide excellent images in the shortest possible time.

With advancements in technology, higher field strength magnets are now available for imaging. Of these higher field strengths, 3T systems are now widely available and are being increasingly used in clinical practice. The 3T systems have demonstrated advantages over the 1.5T system in a broad range of clinical applications like neuro, body and musculoskeletal imaging.[2-5] In CMR, 3T systems can be more of a bane rather than boon due to inherent technical issues which can lead to extensive image artifacts.[6]

Access this article online	
Quick Response Code:	Website: www.ijri.org
	DOI: 10.4103/ijri.IJRI_503_16

This is an open access article distributed under the terms of the Creative Commons Attribution-NonCommercial-ShareAlike 3.0 License, which allows others to remix, tweak, and build upon the work non-commercially, as long as the author is credited and the new creations are licensed under the identical terms.

For reprints contact: reprints@medknow.com

Cite this article as: Auti OB, Bandekar K, Kamat N, Raj V. Cardiac magnetic resonance techniques: Our experience on wide bore 3 tesla magnetic resonance system. Indian J Radiol Imaging 2017;27:404-12.

© 2017 Indian Journal of Radiology and Imaging | Published by Wolters Kluwer - Medknow

Over the last couple of years, there has been significant increase in the number of 3T installations in the country. With its proven benefits in other parts of body, there are no clinical concerns with this change in practice. There, however, remains some hesitancy to perform CMR imaging on 3T systems in India. In this study we describe possible challenges encountered in performing CMR on 3T system and also suggest appropriate technical solutions based on our clinical experience.

Clinical setting

We are one of the tertiary care hospitals that provide multispecialty care to the patients. In our imaging department we have a 3T MR system (Siemens Magnetom Verio, 70 cm bore) which was acquired a few years ago. Over the last couple of years, we have performed 450 CMR cases, out of which 255 cases were performed to assess for either cardiomyopathy or to assess myocardial viability. Rest of the cases (195) were performed to quantify myocardial and hepatic iron overload in patients with Thalassemia. Majority of these were adult patients with only a few pediatric cases. In our experience the wider bore of 70 cm was beneficial in only a small number of cases with regards to claustrophobia. There were a handful of cases that underwent a MR examination in our system but could not fit into the 60 cm system, due to broad shoulder span and increased upper body circumference.

Electrocardiographs (ECG) gating

A good ECG gating is essential to get good quality CMR images. Due to the higher field strength, ECG signals are often suboptimal leading to improper gating. It is essential to use MR compatible nonferromagnetic stickers. These are available in market and are made of graphite. The position of the ECG stickers on the patient body is also very crucial. In a 3T system multiple leads are positioned around the heart similar to the standard 12-lead ECG pattern. We have achieved better signal detection by using "L" pattern, whereby four leads are placed in the left parasternal aspect as shown in Figure 1. Patient's chest needs to be shaved for better lead contact with the chest wall.

Usually retrospective ECG gating is used for CMR examination. However, in case of arrhythmias, this may not be possible. In such cases, prospective ECG gating or arrhythmia rejection protocol can be utilized. Currently, most of the scanners are using vectocardiographic (VCG) approach instead of standard ECG triggering to avoid artifacts due to magneto-hydrodynamic effects of moving blood with the magnetic field.[7] In some cases instead of VCG, peripheral pulse gating may also be useful if the ECG signal is suboptimal.

Standard CMR protocol

The CMR examination protocols may consist of the following sequences:

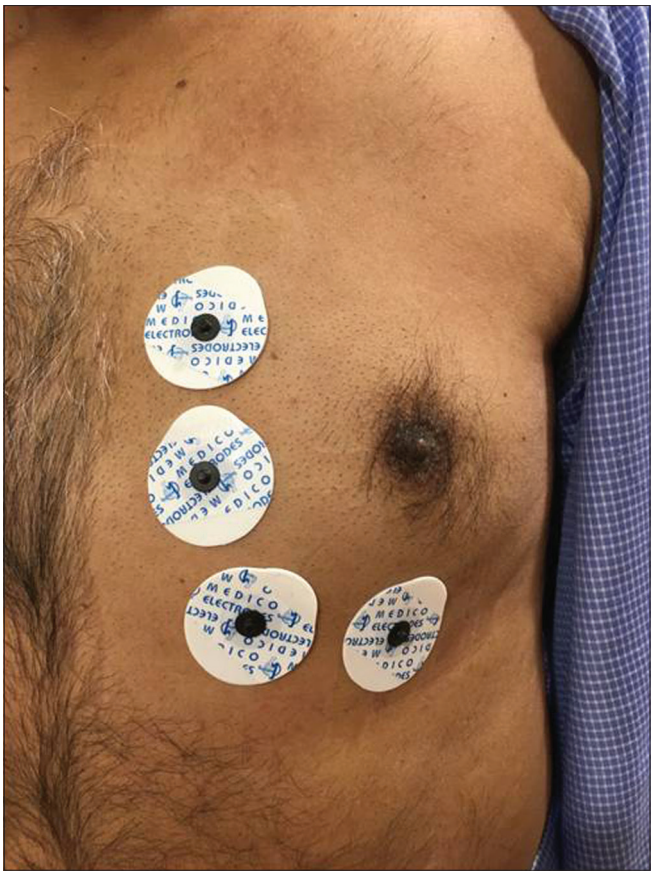

Figure 1: "L" pattern of ECG lead placement on patient's chest wall

- Localizer/Scanograms used to plan the study further and to ensure that the heart is in the iso center of the magnet
- Anatomical imaging: Free breathing or breath-hold examinations to review the broad anatomy of the heart, lungs, mediastinum, and the thoracic cavity
- Functional imaging: To review the dynamic function of the cardia and calculate multiple parameters such as ventricular volumes, stroke volumes, ejection fraction, etc
- Myocardial morphology imaging: This includes myocardial edema assessment along with T1 and T2 mapping
- Myocardial perfusion imaging (MPI)
- Late gadolinium enhancement (LGE) imaging
- Phase contrast (PC) imaging
- Myocardial and liver iron overload assessment
- Coronary artery imaging.

Localizers

These are standard sequences for all MR examinations and are acquired in all three planes. It is essential to get the heart in the iso center of the magnet to reduce artifacts and get best resolution. This step is very important in a 3T system and the technologists should ensure that this is achieved in every patient.

Anatomical imaging

These images are usually acquired in axial plane with addition of sagittal or coronal plane as per the preference of the local team. The images can be either acquired in a "black blood" (spin echo) or "white blood" (gradient echo) sequence. Either free breathing or breath-hold examination can be performed. On 3T system, these sequences are relatively faster and provide better resolution. Some pulsation artifacts may be apparent but often do not limit clinical interpretation. No specific changes need to be made on the 3T system for these images.

Functional/CINE imaging

ECG-gated steady-state free precession (SSFP) sequence is used to achieve functional/CINE imaging. This helps in analyzing myocardial contractility, ventricular volumes, and ejection fractions. These sequences are fast and have high signal-to-noise ratio (SNR) and blood-myocardium contrast.[8,9] Theoretically speaking, shift from 1.5 to 3T will increase the SNR by factor of 2. In many neuroimaging applications, this increase has been realized.[10] In cardiac and body applications, increase in SNR varies according to different applications and sequences. Often, changes in sequence parameters are required to adapt 1.5T sequences for 3T and these changes will decrease the expected theoretical increase in SNR.[11]

Increase in field strength from 1.5 to 3T, specific absorption rate (SAR) increases by four times. If the same parameters of 1.5T are used in 3T systems, the SAR limit is often exceeded as these sequences require multiple rapid sequential radiofrequency (RF) pulses. So, to meet the SAR requirements, modifications of the sequence are necessary, which include decrease in flip angle or an increase in repetition time (TR). Decrease in flip angle reduces SNR, while increase in TR increases susceptibility artifacts.[11]

Parallel imaging can also be used in 3T to reduce scan time as 3T has inherent more SNR than 1.5T. However, this reduction in scan time will cause SNR to reduce by the square root of the acquisition time.[12] Increase in SNR gained at 3T can be used to offset this reduction in SNR seen with parallel imaging techniques. The pairing of 3T and parallel imaging could reduce scan time by a factor of two with preservation of SNR at 1.5T values.[13]

SSFP images are more prone to susceptibility or dark-band artifacts related to the local-field inhomogeneities and the TR used. These artifacts are too minimal in 1.5T CMR to affect the actual imaging information. However, with increasing field strength, there will be increase in local-field inhomogeneities. As a result, these artifacts degrade the imaging quality on 3T CMR.[14] One way to reduce these artifacts would be to use shorter TR, so this will push the artifacts away from the determined imaging frequency.[15] However, decrease in TR will increase the SAR making its universal application difficult.

Another way to alleviate dark-band artifacts would be to use "frequency scout" imaging. It is a fast, frequency scout acquisition that can be utilized to determine the optimal resonance frequency offset to incorporate with gradient echo imaging.[16,17] The frequency scout offers a visual indication of the resonance offset to be employed to keep away dark bands from the imaging region of interest. In our practice, we use a frequency offset ranging from − 300 Hz to + 300 Hz with the interval of 50 Hz. We visually choose the optimal frequency in which dark bands are minimal and away from region of interest [Figure 2].

Incorporating frequency scout in routine protocol minimally increases the total examination time, but provides good quality diagnostic images [Figure 3].

Myocardial tagging is another technique used to assess wall motion. In this technique, black lines or grids are superimposed on and embedded in the myocardium at the beginning of a cine sequence, and the subsequent

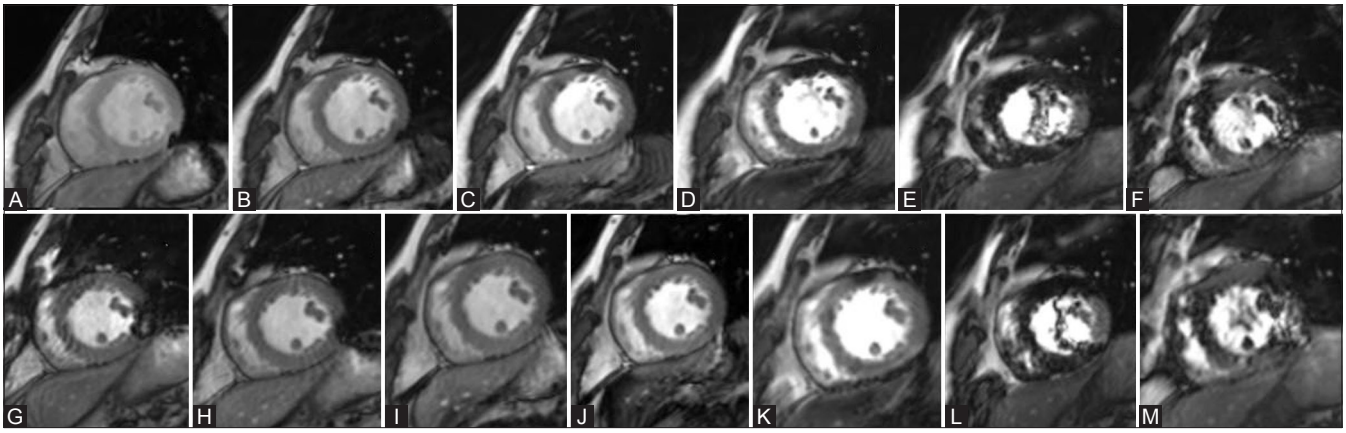

Figure 2 (A-M): Sequential frequency scout images (A-M) acquired in mid-cavity short-axis ranging from −300 Hz to +300 Hz with interval of 50 Hz. Images A, B, I, and J are devoid of artifacts, however, maximal blood myocardial contrast is seen in image J which would be preferred frequency to scan

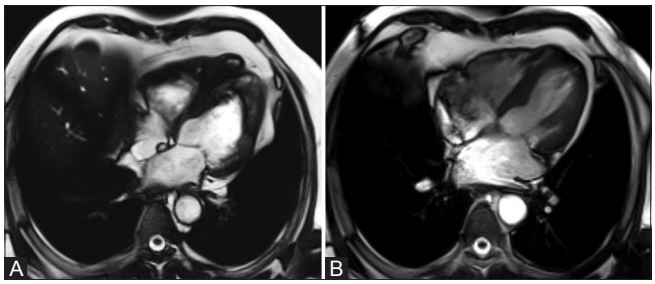

Figure 3 (A and B): (A) 4 ch view in end systole without frequency modulation. There are significant flow-related artifacts in LV and RV cavities. (B) 4 ch view in end systole in same patient. Flow-related artifacts in LV and RV cavities are eliminated after application of optimal frequency

deformation of these lines throughout the cardiac cycle is observed. Special RF prepulses known as spatial modulation of magnetization (SPAMM) or delays alternating with nutation for transient excitation (DANTE) are applied just before the start of contraction.[18] This sequence provides the objective assessment to left ventricular (LV) wall motion.

Myocardial morphology imaging

CMR has the unique ability of assessing myocardial morphology in a noninvasive manner. Short Tau Inversion Recovery (STIR) sequences are traditionally utilized to assess for myocardial edema. There is a difference between the null point of blood and inversion time of fat on 3T compared to 1.5T [Figure 4]. This needs to be taken into consideration while planning for the images. The increase in SNR compared to the 1.5T systems is very apparent in these sets of images.

New generation of myocardial mapping techniques are emerging, enabling direct quantitative assessment of myocardial tissue properties in absolute terms. These techniques involve T1-mapping and T2-mapping. The native T1-mapping relies on a normal range with small variability and has a high sensitivity to disease.[19,20] Elevated T1 times in the myocardium have been reported in myocardial infarction, infiltration and inflammation.[21-23] Its utility in diagnosis of amyloid cardiomyopathy is well established and being used widely.[23] T2-mapping can detect myocardial edema in various cardiac pathologies, including acute myocardial infarction, myocarditis, Tako-tsubo cardiomyopathy and heart transplant rejection.[24-27] However, baseline/native T1 and T2 values needs to be standardized for particular scanner and normal healthy population. We do not have any personal experience with these sequences as they were not part of the MR system at the time of procurement.

Myocardial perfusion imaging

MPI is used to determine global and regional myocardial perfusion to assess ischemia. This is a dynamic sequence where first pass of contrast through the myocardium is captured. These are images with high temporal resolution

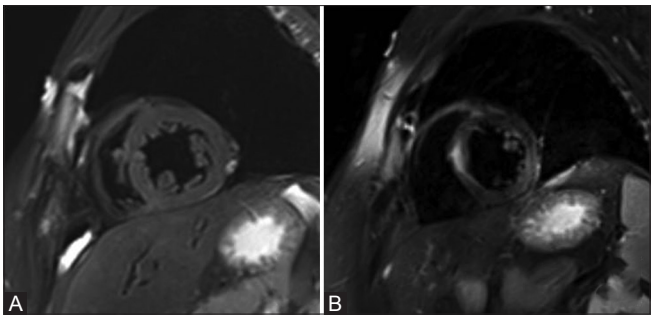

Figure 4 (A and B): (A) Short-axis mid-cavity STIR image showing normal appearance of myocardium. (B) Short-axis mid-cavity STIR image showing mid myocardial septal wall edema

and provide valuable diagnostic information in evaluation of intermediate risk patients with chest pain.[1,28]

At 1.5T strength there is compromise in the SNR and contrast to noise ratio (CNR) in MPI imaging to achieve rapid acquisition. Spatial resolution is often compromised to maintain good temporal resolution. This can lead to dark rim artifacts in the image that can be misinterpreted as perfusion defects.[29]

Perfusion imaging at 3T has great advantages over 1.5T systems, as the SNR doubles. This higher SNR can be used to increase either spatial or temporal resolution or can be applied to parallel imaging techniques that decrease image acquisition time.[29,30]

There is also an increase in the CNR between the 1.5 and the 3T system.[31] The T1 (longitudinal relaxation) time of myocardial tissue increases with higher field strength, while the dynamics of the gadolinium-based contrast agents does not change greatly. This phenomenon potentially increases contrast between perfused and nonperfused myocardial tissue and thus the higher CNR for perfusion images acquired at 3T.[31]

First-pass perfusion requires acquisition of three to four images for every heart beat. Pharmacological agents induce tachycardia during stress examination and reduce the R-R interval. At a 1.5T system spatial resolution is compromised to acquire rapid images during tachycardia. The same is not true in a 3T system and in our experience this was one set of images where 3T system is far superior to a 1.5T system [Figure 5].

Late gadolinium enhancement imaging

LGE of the myocardium allows virtual histological assessment and is a very important sequence to evaluate myocardial scar.[32] LGE imaging is used to assess myocardial infarction, infiltration and/or inflammation. It has become an integral part in preoperative assessment of patients with coronary artery disease to assess for the presence of viable and/or hibernating myocardium.

Amount of nonviable myocardium is inversely related to the likelihood of functional recovery after revascularization procedures.[33]

LGE imaging is done using an inversion recovery (IR) prepared gradient echo sequence. It depends on T1 recovery of myocardium after the inversion pulse to produce contrast between the abnormal myocardium containing gadolinium and normal myocardium with washed out gadolinium. The inversion time (TI) is optimized for individual patient using a TI scout sequence.[34] TI scout consists of multiple images according to particular TI for myocardium. Appropriate nulling time for myocardium is determined as the maximally dark myocardium. As shown in Figure 6, image "f" shows maximally dark myocardium and corresponding TI should be selected as nulling time for myocardium to acquire LGE images.

As mentioned previously, T1 of myocardial tissue increases with field strength and T1 of gadolinium chelates does not change greatly. Soon after contrast administration, there is no significant difference in relaxation times in the blood pool or myocardium at 1.5 and 3T. However, as the contrast agent starts to clear from the normal myocardium, the field-dependent T1 difference in the myocardium is again seen. This increases the null time (TI) of normal myocardium in 3T MR system. The prolonged T1 of normal myocardium at 3T theoretically increases the available contrast between infarcted and normal myocardium, thus increasing the CNR.[34,35]

There appears to be a significant increase in SNR of infarcted myocardium and CNR between normal and infarcted myocardium using phase-sensitive inversion recovery (PSIR) or inversion recovery fast-spoiled gradient echo (IR-FGE) sequences. This increase in SNR is mainly due to the increase in field strength and bulk magnetization from 1.5 to 3T.[35-37]

IR-FGE sequence is very sensitive to TI of the myocardium and small variation in TI can cause significant distribution in signal intensities. PSIR images reflect the sign of z–magnetization at the time of data acquisition. Once the polarity of signals are restored, normal myocardium remains dark compared to scar tissue over a larger range of TI. This, therefore, offers a wider nulling window for delayed enhancement images. On the contrary, IR-FGE provides greater spatial resolution compared to PSIR images.[38,39]

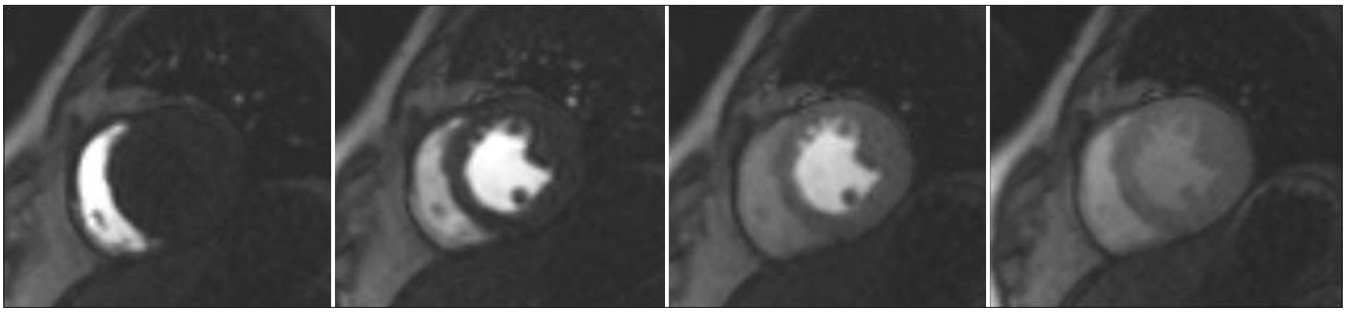

Figure 5: First pass perfusion images showing passage of contrast from heart chambers and myocardial enhancement

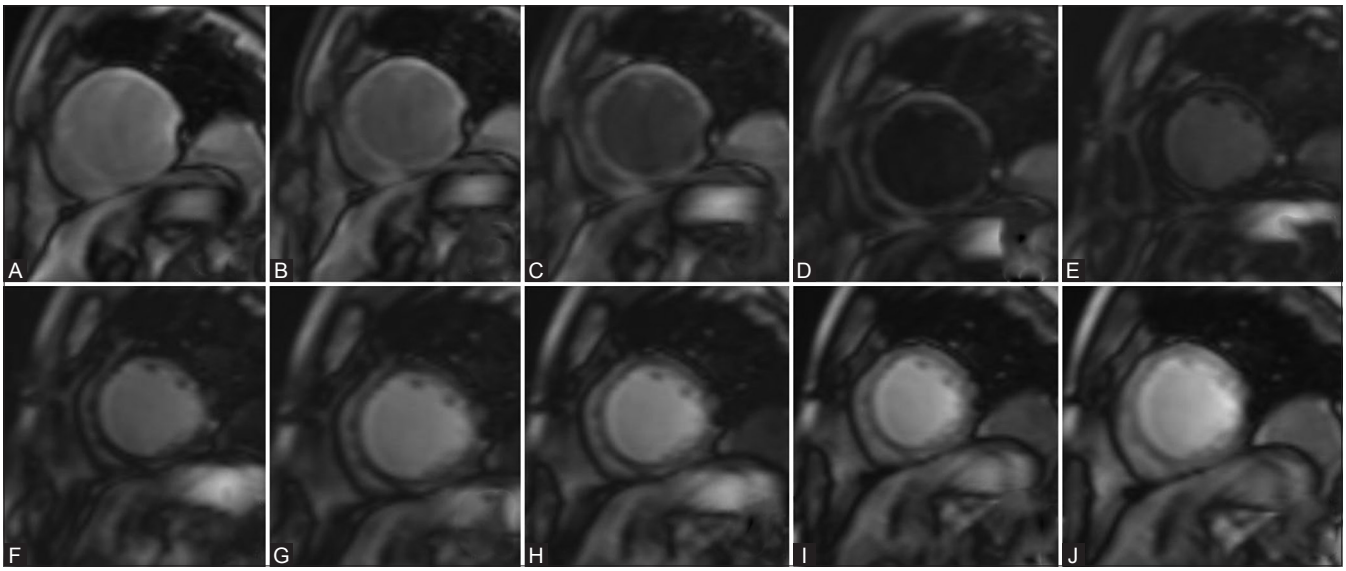

Figure 6 (A-J): TI scout demonstrating short-axis images of LV according to different inversion times

We used PSIR imaging at 3T and we found it effective. In our experience, infarct-to-myocardium contrast was superior at 3T [Figures 7 and 8]. However, the operator must be aware that timing parameters to null the myocardium will change at 3T (long TI).

For viability assessment we administer gadolinium contrast by hand injection. The usual dose of contrast is 0.1 mmol/kg and we start acquiring delayed enhancement images after 5 min of initial contrast administration. Some centers do not start until 10 min after contrast administration. In our experience, starting early allows us to repeat some images if the contrast in the blood pool is brighter than the desired levels.

Phase contrast imaging

PC imaging is an important part of CMR examination and allows quantification of flow and determining the direction. They could be performed either on breath-hold or on free breathing. It is important to acquire the images perpendicular to the direction of flow and planning may be required in two planes. It is also essential to adjust the maximum velocity on a per-case basis to avoid aliasing artifact. We did not find any significant artifacts or other difficulties in executing PC sequences on a 3T system [Figure 9]. In fact, there is increase in SNR due to noise reduction at 3T without significant impact upon velocity and flow.[40,41]

Iron overload quantification

T2 star (T2*) imaging is used in quantification of liver and myocardial iron overload in patients who undergo frequent blood transfusions, like thalassemia. Accurate quantification of iron overload is crucial in guiding the chelation therapy in these patients. MRI is the only robust noninvasive method to quantify myocardial iron load and has been shown to be very useful.[42]

Figure 7 (A-C): Delayed enhancement images in 4 ch, 2 ch, and short-axis, respectively. Note the normal nulling of myocardium

T2* relaxation refers to decay in transverse magnetization (TM) seen with gradient recalled echo sequence. Iron increases TM decay due to its paramagnetic property that leads to increase in magnetic inhomogeneities. In this technique, images are acquired with sequentially increasing the time to echo (TE). As TE increases, the signal intensity of a particular tissue decreases. This decrease in signal is more rapid in patients with iron overload compared to normal subjects. The amount of iron overload can be quantified by assessing the slope of the curve at which signals are dropping. For myocardial iron overload assessment, short axis views are acquired in mid cavity level and the signal decay calculation is made from the interventricular septum.[43,44] Both cardiac and liver iron overload assessment is performed at the same time. Ultrafast sequences to perform these studies have been tried and found useful in many international studies.[45]

We have done T2* imaging in 195 patients over 2 years on 3T MR system. Scanning protocol included T2* sequences for myocardium and liver with minimum possible TE and minimum TE interval. T2* values and conversion equations for iron quantification are different in 1.5 and 3T MR system, therefore different formulas appropriate for 3T should be used. We use software/Excel sheet of 3T conversion prepared by Storey *et al*.[46] For accurate quantification of iron, we use truncation method for curve fitting especially in cases of severe iron overload.[47]

Image acquisition and assessment can be a challenge on 3T, especially in patients with severe liver iron overload. While assessing the liver iron overload, there will be rapid decay in the signal in these patients. This only provides two to three data points for calculation before the curve reaches the bottom. Comparatively, on a 1.5T system three to five data points can be recorded in patients with severe iron overload as the signal decay is not that rapid. This may lead to inaccurate assessment of liver iron overload in this group of patients. In the same group of patients, acquiring cardiac images can be a challenge due to artifacts from the liver. To avoid this, recalibration/shim frequency has to be reapplied prior to acquiring the data.[48]

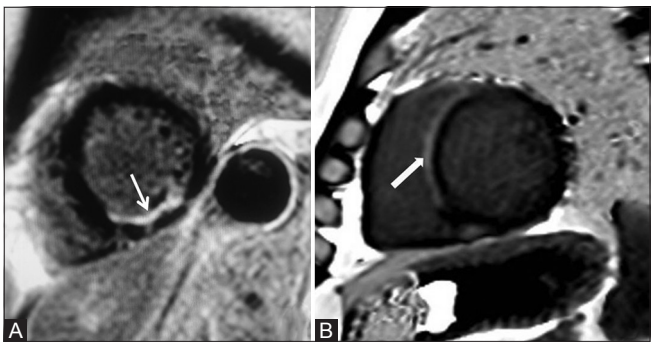

Figure 8 (A and B): Delayed enhancement images showing subendocardial enhancement (A) suggesting infarction and epicardial enhancement (B) suggesting inflammation/infiltration

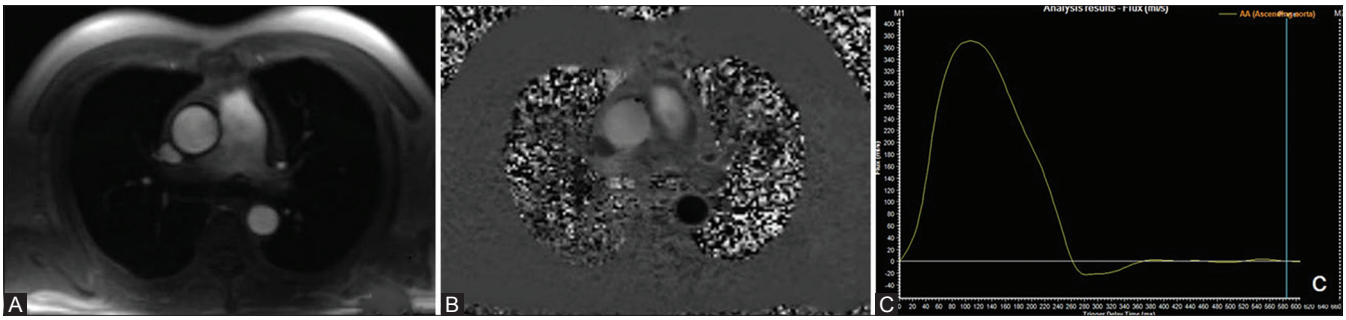

Figure 9 (A-C): Phase contrast (PC) imaging of ascending aorta (A and B). Note the graph of the aortic flow after calculation in software (C)

Coronary artery imaging

MRI is making major strides in assessment of coronary arteries over the last few years. Acquiring thin section images while freely breathing without any exposure to radiation is a major advantage on MRI. We use this frequently in determining the coronary anatomy in patients with suspected anomalous coronary anatomy. The ability of CMR to accurately diagnose coronary artery stenosis/plaque characterization is still uncertain. On 3T system, acquisition of the data is much faster compared to a 1.5T system and there is some reduction in the scan time. The SNR and CNR are also improved. No specific precaution needs to be taken in comparison to a 1.5T system.

Time factor

As 3T MR system has inherent high SNR, frequent usage of parallel imaging can be done to decrease the examination timing.[29] For example, short axis PSIR images through entire LV can be acquired in single breath-hold in 3T MR, which requires three breath-holds in 1.5T MR system. Over the last 2 years, we have optimized our cardiac MR protocol on the 3T system and are able to perform a viability assessment in 30 min. This used to take about 40–45 min in our 1.5T system. On a real-time basis, this difference may not be that apparent in all the centers as newer sequences are often acquired in 3T system on top of standard images, for example, T1 mapping. Moreover, in some patients, it is difficult to achieve homogenous magnetic field in spite of using frequency scout imaging which will give more susceptibility artifacts, and examination time increases even more than 1.5T. Imaging time may increase in postoperative patients with sternal sutures, metallic valves, stents, and clips as susceptibility artifacts will increase in these scenarios.

Wide bore MRI

Wide bore MR system was designed for the comfort of patients with claustrophobia or obesity. In current market the standard MR system has a bore of 60 cm, while the wide bore system has 70 cm. Large bore size increases the in-field inhomogeneity of the magnetic field, thereby producing more artifacts. Some newer advances in technology (see later) have aimed at reducing this problem and have achieved remarkable results.

Safety on 3T MRI

Metallic devices and implants behave differently under 1.5 and 3T MR systems due to basic increase in magnetic field strength. Metallic objects displaying weakly ferromagnetic qualities at 1.5T may exhibit substantial magnetic field interactions at 3T. It is important to assess safety of particular device on 3T MR.

Dr. Shellock conducted experiment to assess MR safety of 109 devices and implants on 3T and found only 4% as unsafe.[49] However, literature search is necessary for MR safety of particular metallic devices/implants before performing procedure. List of safe and unsafe devices for 3T MR system is available on www.mrisafety.com.

Advances in MR technology

Susceptibility artifacts remain a major challenge for CMR imaging at 3T. One vendor has introduced "Multi Transmit Technology" to circumvent this problem, whereby multiple RF sources are used rather than using conventional single RF source. For CMR, real-time RF modulations are performed to adapt the changing ECG and longitudinal magnetization. There is no need to perform multiple frequency scouts with this technology, thereby saving time and improving image quality.

Another vendor claims to acquire seven-dimensional data over a period of 8 min without the need for breath-hold. These data provide real-time, quantifiable data of the whole chest, which can be reconstructed in multiple planes.

Regardless of many promises offered by different vendors, complete assessment of MR system is necessary prior to purchasing a new system. Visit to established working sites and demonstration of few cases will help in making the right decision.

Overall, a 3T MR system brings in a newer promising era in imaging. Performing CMR on a 3T system is no longer a challenge and should be encouraged. We highlighted few of the tricks/precautions to perform CMR examination on 3T MR system in Table 1.

Financial support and sponsorship

Nil.

Table 1: Tricks/precautions to perform CMR on 3T

Sequences	Comments
Cine images (SSFP)	Frequency scout imaging Adjust shimming properly Reduce TR
STIR images	Check the inversion time for fat on 3T
T1-mapping	New additional sequence than 1.5T. T1 values have to be standardized according to the particular scanner and patient population.
Perfusion imaging	Has inherent more SNR and CNR than 1.5T Be careful about ring artifacts while reporting
LGE images	Nulling time (TI) of myocardium is greater compared to 1.5T Use PSIR sequence for faster acquisition.
T2* imaging	Use specific software/excel spreadsheet for 3T Use truncation method in cases of severe iron overload

Conflicts of interest

There are no conflicts of interest.

References

1. Patel MR, Spertus JA, Brindis RG, Hendel RC, Douglas PS, Peterson ED, *et al*. ACCF proposed method for evaluating the appropriateness of cardiovascular imaging. J Am Coll Cardiol 2005;46:1606-13.
2. Alvarez-Linera J. 3T MRI: Advances in brain imaging. Eur J Radiol 2008;67:415-26.
3. Couñago F, del Cerro E, Recio M, Díaz A, Marcos F. 3T functional MRI in prostate cancer: Clinical implications. Reports of Practical Oncology and Radiotherapy 2013;18:S93-4.
4. Krishnan S, Hecht E. Update on liver MRI at 3T. Imaging in Medicine 2011;3:51-65.
5. Mosher TJ. Musculoskeletal imaging at 3T: Current techniques and future applications. Magn Reson Imaging Clin N Am 2006;14:63-76.
6. Bernstein MA, Huston J, Ward HA. Imaging artifacts at 3.0T. J Magn Reson Imaging 2006;24:735-46.
7. Nacif MS, Zavodni A, Kawel N, Choi EY, Lima JA, Bluemke DA, *et al*. Cardiac magnetic resonance imaging and its electrocardiographs (ECG): Tips and tricks. Int J Cardiovasc Imaging 2011;28:1465-75.
8. Miller S, Simonetti O, Carr J, Kramer U, Finn J. MR imaging of the heart with cine true fast imaging with steady-state precession: Influence of spatial and temporal resolutions on left ventricular functional parameters. Radiology 2002;223:263-9.
9. Barkhausen J, Ruehm SG, Goyen M, Buck T, Laub G, Debatin JF. MR evaluation of ventricular function: True fast imaging with steady-state precession versus fast low-angle shot cine MR imaging: Feasibility study. Radiology 2001;219:264-9.
10. Fischbach F, Müller M, Bruhn H. Magnetic resonance imaging of the cranial nerves in the posterior fossa: A comparative study of T2-weighted spin-echo sequences at 1.5 and 3.0 tesla. Acta Radiologica 2008;49:358-63.
11. Voros S, Kramer C. Cardiovascular magnetic resonance imaging: State of the art. CCR 2005;1:181-8.
12. Wen H, Jaffer F, Denison T, Duewell S, Chesnick A, Balaban R. The evaluation of dielectric resonators containing H_2O or D_2O as RF coils for high-field MR imaging and spectroscopy. J Magn Reson B 1996;110:117-23.
13. Wintersperger B, Bauner K, Reeder S, Dietrich O, Sprung K, Reiser M, *et al*. Accelerated cardiac CINE MR imaging on multi-channel 3 Tesla: Comparison of signal parameters and volumetric accuracy to 1.5 Tesla. RöFo-Fortschritte auf dem Gebiet der Röntgenstrahlen und der bildgebendenVerfahren 2006;178.
14. Nael K, Fenchel M, Saleh R, Finn J. Cardiac MR imaging: New advances and role of 3T. Magn Reson Imaging Clin N Am 2007;15:291-300.
15. Scheffler K, Lehnhardt S. Principles and applications of balanced SSFP techniques. Eur Radiol 2003;13:2409-18.
16. Nayak KS, Lee HL, Hargreaves BA, Hu BS. Wideband SSFP: Alternating repetition time balanced steady state free precession with increased band spacing. Magn Reson Med 2007;58:931-8.
17. Deshpande VS, Shea SM, Li D. Artifact reduction in true-FISP imaging of the coronary arteries by adjusting imaging frequency. Magn Reson Med 2003;49:803-9.
18. Jeung MY, Germain P, Croisille P, El Ghannudi S, Roy C, Gangi A, *et al*. Myocardial tagging with MR imaging: Overview of normal and pathologic findings. Radiographics 2012;32:1381-98.
19. Chow K, Flewitt JA, Green JD, Pagona JJ, Friedrich MG, Thompson RB, *et al*. Saturation recovery single-shot acquisition (SASHA) for myocardial T1 mapping. Magn Reson Med 2014;71:2082-95.
20. Piechnik S, Ferreira V, Lewandowski A, Sado DM, White SK, Moon JC, *et al*. Normal variation of magnetic resonance T1 relaxation times in the human population at 1.5T using ShMOLLI. J Cardiovasc Magn Reson 2013;15:13.
21. Ferreira V, Piechnik S, Dall'Armellina E, Francis JM, Kardos A, Robson MD, *et al*. T1-mapping for the diagnosis of acute myocarditis using cardiovascular magnetic resonance: Comparison to T2-weighted and late gadolinium enhanced imaging. JACC Cardiovasc Imaging 2013;6:1048-58.
22. Puntmann VO, Voigt T, Chen Z, Mayr M, Karim R, Rhode K, *et al*. Native T1 mapping in differentiation of normal myocardium from diffuse disease in hypertrophic and dilated cardiomyopathy. JACC Cardiovasc Imaging 2013;6:475-84.
23. Karamitsos TD, Piechnik SK, Banypersad SM, Fontana M, Robson Md, Moon JC, *et al*. Noncontrast T1 mapping for the diagnosis of cardiac amyloidosis. JACC Cardiovasc Imaging 2013;6:488-97.
24. Thavendiranathan P, Walls M, Giri S, Rajgopalan S, Moore S, Raman SV, *et al*. Improved detection of myocardial involvement in acute inflammatory cardiomyopathies using T2 mapping. Circ Cardiovasc Imaging 2011;5:102-10.
25. Usman AA, Taimen K, Wasielewski M, Shah S, Giri S, Markl M, *et al*. Cardiac magnetic resonance T2 mapping in the monitoring and follow-up of acute cardiac transplant rejection: A pilot study. Circ Cardiovasc Imaging 2012;5:782-90.
26. Van Heeswijk RB, Feliciano H, Bongard C, Coppo S, Lauriers N, Locca D, *et al*. Freebreathing 3 T magnetic resonance T2-mapping of the heart. JACC Cardiovasc Imaging 2012;5:1231-9.
27. Verhaert D, Thavendiranathan P, Giri S, Mihai G, Rajgopalan S, Raman SV, *et al*. Direct T2 quantification of myocardial edema in acute ischemic injury. JACC Cardiovasc Imaging 2011;4:269-78.
28. Jerosch-Herold M, Muehling O, Wilke N. MRI of myocardial perfusion. Semin Ultrasound CT MR 2006;27:2-10.
29. Fenchel M, Kramer U, Nael K, Miller S. Cardiac magnetic resonance imaging at 3.0 T. Top Magn Reson Imaging 2007;18:95-104.
30. Gebker R, Jahnke C, Paetsch I, Kelle S, Schnackenburg B, Fleck E, *et al*. Diagnostic performance of myocardial perfusion MR at 3 T in patients with coronary artery disease. Radiology 2008;247:57-63.
31. Kim D, Axel L. Multislice, dual-imaging sequence for increasing the dynamic range of the contrast-enhanced blood signal and CNR of myocardial enhancement at 3T. J Magn Reson Imaging 2006;23:81-6.
32. Isbell DC, Kramer CM. Magnetic resonance for the assessment of myocardial viability. Curr Opin Cardiol 2006;21:469-72.
33. Kim RJ, Wu E, Rafael A, Chen EL, Parker MA, Judd RM, *et al*. The

use of contrast-enhanced magnetic resonance imaging to identify reversible myocardial dysfunction. N Engl J Med 2000;343:1445-53.

34. Klumpp B, Fenchel M, Hoevelborn T, Helber U, Scheule A, Claussen C, *et al*. Assessment of myocardial viability using delayed enhancement magnetic resonance imaging at 3.0 Tesla. Invest Radiol 2006;41:661-7.
35. Ligabue G, Fiocchi F, Ferraresi S, Barbieri A, Rossi R, Modena MG, *et al*. 3-Tesla MRI for the evaluation of myocardial viability: A comparative study with 1.5-Tesla MRI. Radiol Med 2008;113:347-62.
36. Huber A, Bauner K, Wintersperger BJ, Reeder SB, Stadie F, Mueller E, *et al*. Phase-sensitive inversion recovery (PSIR) single-shot true FISP for assessment of myocardial infarction at 3 Tesla. Invest Radiol 2006;41:148-53.
37. Bauner KU, Muehling O, Wintersperger BJ, Winnik E, Reiser MF, Huber A. Inversion recovery single-shot Turbo FLASH for assessment of myocardial infarction at 3 Tesla. Invest Radiol 2007;42:361-71.
38. Kellman P, Arai AE, Mcveigh ER, Aletras AH. Phase-sensitive inversion phase-sensitive inversion recovery for detecting myocardial infarction using gadolinium-delayed hyperenhancement. Magn Reson Med 2002;383:372-83.
39. Biglands J, Radjenovic A, Ridgway J. Cardiovascular magnetic resonance physics for clinicians: Part II. J Cardiovasc Magn Reson 2012;14:66.
40. Lotz J, Doker R, Noeske R, Felix R, Galanski M, Meyer GP, *et al*. *In vitro* validation of phase-contrast flow measurements at 3 T in comparison to 1.5 T: Precision, accuracy, and signal-to-noise ratios. J Magn Reson Imaging 2005;21:604-10.
41. Pai VM. Phase contrast using multiecho steady-state free precession. Magn Reson Med 2007;58:419-24.
42. Anderson LJ, Holden S, Davis B, Prescott E, Charrier CC, Bunce NH, *et al*. Cardiovascular T2-star (T2*) magnetic resonance for the early diagnosis of myocardial iron overload. Eur Heart J 2001;22:2171-9.
43. Anderson LJ, Westwood MA, Holden S, Davis B, Prescott E, Porter JB, *et al*. Myocardial iron clearance during reversal of siderotic cardiomyopathy with intravenous desferrioxamine: A prospective study using T2 ∗ cardiovascular magnetic resonance. Br J Haematol 2004;127:348-55.
44. Westwood MA, Anderson LJ, Firmin DN, Gatehouse PD, Lorenz CH, *et al*. Interscanner reproducibility of cardiovascular magnetic resonance T2 ∗ measurements of tissue iron in thalassemia. J Magn Reson Imaging 2003;18:616-20.
45. Abdel-Gadir A, Vorasettakarnkij Y, Ngamkasem H, Nordin S, Ako E, Tumkosit M, *et al*. Ultrafast CMR to deliver high volume screening of an at risk thalassemia population in the developing world: Preliminary results from the TIC-TOC study (Thailand and UK international collaboration in thalassaemia using an optimised ultrafast CMR protocol). J Cardiovasc Magn Reson 2016;18:39.
46. Storey P, Thompson A, Carqueville C, Wood J, de Freitas R, Rigsby C. R2* imaging of transfusional iron burden at 3T and comparison with 1.5T. J Magn Reson Imaging 2007;25:540-7.
47. He T, Kirk P, Firmin DN, Lam WM, Chu WC, Au WY, *et al*. Multi-center transferability of a breath-hold T2 technique for myocardial iron assessment. J Cardiovasc Magn Reson 2008;10:11.
48. Alam MH, Auger D, McGill LA, Smith GC, Wage R, Drivas P, *et al*. Comparison of 3 T and 1.5 T for T2* magnetic resonance of tissue iron. J Cardiovasc Magn Reson 2016;18.
49. Shellock FG. Biomedical implants and devices: Assessment of magnetic field interactions with a 3.0-Tesla MR system. J Magn Reson Imaging 2002;16:721-32.