Journal of Anatomy

*J. Anat.* (2017) **230**, pp444–460 doi: 10.1111/joa.12562

# Cranial joint histology in the mallard duck (*Anas platyrhynchos*): new insights on avian cranial kinesis

Alida M. Bailleul,[1] Lawrence M. Witmer[2] and Casey M. Holliday[1]

[1]*Department of Pathology and Anatomical Sciences, University of Missouri-School of Medicine, Columbia, MO, USA*
[2]*Department of Biomedical Sciences, Heritage College of Osteopathic Medicine, Ohio University, Athens, OH, USA*

## Abstract

The evolution of avian cranial kinesis is a phenomenon in part responsible for the remarkable diversity of avian feeding adaptations observable today. Although osteological, developmental and behavioral features of the feeding system are frequently studied, comparatively little is known about cranial joint skeletal tissue composition and morphology from a microscopic perspective. These data are key to understanding the developmental, biomechanical and evolutionary underpinnings of kinesis. Therefore, here we investigated joint microstructure in juvenile and adult mallard ducks (*Anas platyrhynchos*; Anseriformes). Ducks belong to a diverse clade of galloanseriform birds, have derived adaptations for herbivory and kinesis, and are model organisms in developmental biology. Thus, new insights into their cranial functional morphology will refine our understanding of avian cranial evolution. A total of five specimens (two ducklings and three adults) were histologically sampled, and two additional specimens (a duckling and an adult) were subjected to micro-computed tomographic scanning. Five intracranial joints were sampled: the jaw joint (quadrate-articular); otic joint (quadrate-squamosal); palatobasal joint (parasphenoid-pterygoid); the mandibular symphysis (dentary-dentary); and the craniofacial hinge (a complex flexion zone involving four different pairs of skeletal elements). In both the ducklings and adults, the jaw, otic and palatobasal joints are all synovial, with a synovial cavity and articular cartilage on each surface (i.e. bichondral joints) ensheathed in a fibrous capsule. The craniofacial hinge begins as an ensemble of patent sutures in the duckling, but in the adult it becomes more complex: laterally it is synovial; whereas medially, it is synostosed by a bridge of chondroid bone. We hypothesize that it is chondroid bone that provides some of the flexible properties of this joint. The heavily innervated mandibular symphysis is already fused in the ducklings and remains as such in the adult. The results of this study will serve as reference for documenting avian cranial kinesis from a microanatomical perspective. The formation of: (i) secondary articular cartilage on the membrane bones of extant birds; and (ii) their unique ability to form movable synovial joints within two or more membrane bones (i.e. within their dermatocranium) might have played a role in the origin and evolution of modern avian cranial kinesis during dinosaur evolution.

**Key words:** *Anas platyrhynchos*; articular cartilage; birds; chondroid bone; cranial joints; cranial kinesis; histology; ontogeny; sutures; synostoses; synovial joints.

## Introduction

Birds are the most diverse clade of terrestrial vertebrates, encompassing more than 10 000 extant species (Prum et al. 2015). Their skulls display cranial kinesis, a phenomenon that allows movements about many intracranial joints in addition to the jaw joint (Versluys, 1912). Avian cranial kinesis has been regarded as a key innovation, partly responsible for the extreme dietary dexterity of bird jaws and ultimately for the adaptive radiation of birds themselves (Bout & Zweers, 2001). The intracranial mobility of birds is in sharp contrast with turtles, crocodilians or mammals, which possess skulls that are tightly sutured or almost entirely synostosed (Novacek, 1993; Rieppel, 1993; Smith, 1993). Extensive cranial kinesis is also observed in squamates (i.e. in many lizards and in all ophidians; Gans, 1961; Rieppel, 1980, 1993; Herrel et al. 2000; Payne et al. 2011), and various degrees of cranial kinesis have been hypothesized to exist in several lineages of fossil tetrapods, including non-avian dinosaurs (Holliday & Witmer, 2008).

The general anatomy and functional morphology of avian cranial kinesis is relatively well understood (Bock,

*Correspondence*
*Alida M. Bailleul, Department of Pathology and Anatomical Sciences, University of Missouri-School of Medicine, 1 Hospital Drive, M263 Medical Science Building, Columbia, MO, 65211, USA.*
*E: bailleula@missouri.edu*

Accepted for publication *11 October 2016*
Article published online *6 December 2016*

© 2016 Anatomical Society

1960, 1964; Zweers, 1973; Bühler, 1981; Zusi, 1984, 1993; Baumel & Witmer, 1993; Bout & Zweers, 2001; Gussekloo & Bout, 2005; Holliday & Witmer, 2008; Van der Meij & Bout, 2008; Dawson et al. 2011). A few studies have documented this system from a developmental perspective with some histological data (Parker, 1869; De Beer & Barrington, 1934; De Beer, 1937; Jollie, 1957; Bellairs & Kamal, 1981). However, only a few studies have attempted to specifically draw connections between the histology of kinetic joints with their functional environment. The microanatomy of some joints in the chick (*Gallus gallus*) and the eastern rosella (*Platycercus eximius*) were investigated to understand the occurrence of avian secondary cartilage (Murray, 1963; Murray & Smiles, 1965; Hall, 1967, 1968). Craniofacial sutures in the chick embryo were studied to understand the occurrence of chondroid bone during skull development (Lengelé et al. 1990, 1996). Finally, Hall (1979) and Persson (1983) investigated the role of mechanical forces on the developing cranial joints in a handful of avian species by means of histological analyses. Most recently, Bailleul & Horner (2016) documented the microanatomy of some sutures and synchondroses in an ontogenetic series of emus (*Dromaius novaehollandiae*).

Thus, even though cranial kinesis as a behavioral phenomenon is arguably well understood in birds, we still understand little about the diversity and functional significance of skeletal tissues that form the joints that are key to intracranial mobility. Here we document and describe cranial joint histology of the domestic mallard duck (*Anas platyrhynchos;* Anseriformes). Ducks are perhaps the epitome of cranial kinesis as they employ incredibly rapid, coordinated kinetic movements about the quadrate, craniofacial hinge and palatal elements. They are commonly-used, easily-obtained game and domestic animals that serve as a model organism in developmental biology (Le Douarin, 2004; Tucker & Lumsden, 2004; Huang et al. 2008), *in vivo* kinematics using X-ray reconstruction of moving morphology (X-ROMM; Dawson et al. 2011), and evolutionary biology (Livezey, 1997; Iwaniuk et al. 2009; O'Connor, 2009; Hieronymus & Witmer, 2010). These historical, behavioral and anatomical foundations are key aids to testing hypotheses on the undoubtedly tangled relationship between form, function, development and evolution of the feeding apparatus of birds and other vertebrates.

We investigated the morphology of five cranial articulations (Fig. 1) using histological and 3D imaging techniques in two ontogenetic stages: in ducklings (3 days old); and in adult ducks. These include: (i) the jaw joint (quadrate-articular); (ii) otic joint (quadrate-squamosal); (iii) palatobasal joint (parasphenoid-pterygoid); (iv) mandibular symphysis (dentary-dentary); and (v) the craniofacial hinge (a zone of flexion involving the lacrimals, nasals, frontals and premaxillae). All of these articulations are major drivers of avian cranial kinesis (Zusi, 1993), except for the mandibular symphysis, which is akinetic.

### Joint classifications

Arthrological nomenclature derives largely from our understanding of mammalian anatomy in which functional and structural classes are used to describe joints (Archer et al. 2003; Marieb & Hoehn, 2015). The three main functional categories are: (i) synarthroses, articulations that allow no movement; (ii) amphiarthroses, those that allow 'little' movement; and (iii) diarthroses, those that allow free movement (a term often used synonymously with 'synovial joints'). Whereas the distinction between diarthroses and synarthroses is evident, there is no clear quantification of 'little' movement in amphiarthroses, making the term rather equivocal in utility. Within these three functional categories, mammalian joints are also divided into four structural sub-categories: (a) fibrous (synonymous with syndesmosis), such as craniofacial sutures; (b) cartilaginous, such as the basicranial synchondroses or epiphyseal plates of limb bones; (c) bony, which are synostoses; and (d) synovial joints possessing a synovial cavity, articular cartilage on both sides of the cavity and a fibrous sheath. While this relatively simple hierarchy works for mammals, it is not as easily applied to birds and other reptiles because of the spectrum of skeletal tissues and mobility found at various articulations (for example, sutures only fit in the 'synarthrosis' category for mammals; however, in some reptiles such as geckoes, the frontoparietal suture is kinetic, and therefore could be classified as an 'amphiarthrosis' or even a 'diathrosis'). Other variations may also stem from the embryological origins of the tissues themselves (Payne et al. 2011; Hall, 2015) and their mode of ossification, i.e. whether the skeletal elements forming the joint ossify directly, intramembranously from the mesenchyme, and/or indirectly via cartilage (the terms 'direct' and 'indirect ossification' were recently introduced by Hall, 2015). Tissue origins are important for recognizing avian secondary cartilage, a type of cartilage that can arise from the periosteum of pre-existing membrane bones (Hall, 2000). This information is available for each joint in Table 1. In the following sections, we will focus on describing the structural category of each joint, and save discussion on joint function for a subsequent contribution.

## Materials and methods

### Histological procedures

Five individuals (*Anas platyrhynchos*) were used for histological preparation and analysis: two 3-day-old domestic ducklings and three adult wild duck heads (based on published age at skeletal maturity and life span, ages of the adults can be estimated roughly between 1 and 10 years; Cherry & Morris, 2008). The duckling heads came from cadaveric specimens (Ramona Duck Farm, Westminister, CA, USA). Adult heads came from wild ducks obtained through legal hunting donated to the University of Missouri Vertebrate Collections (MUVC); these ducks were collected independently from

© 2016 Anatomical Society

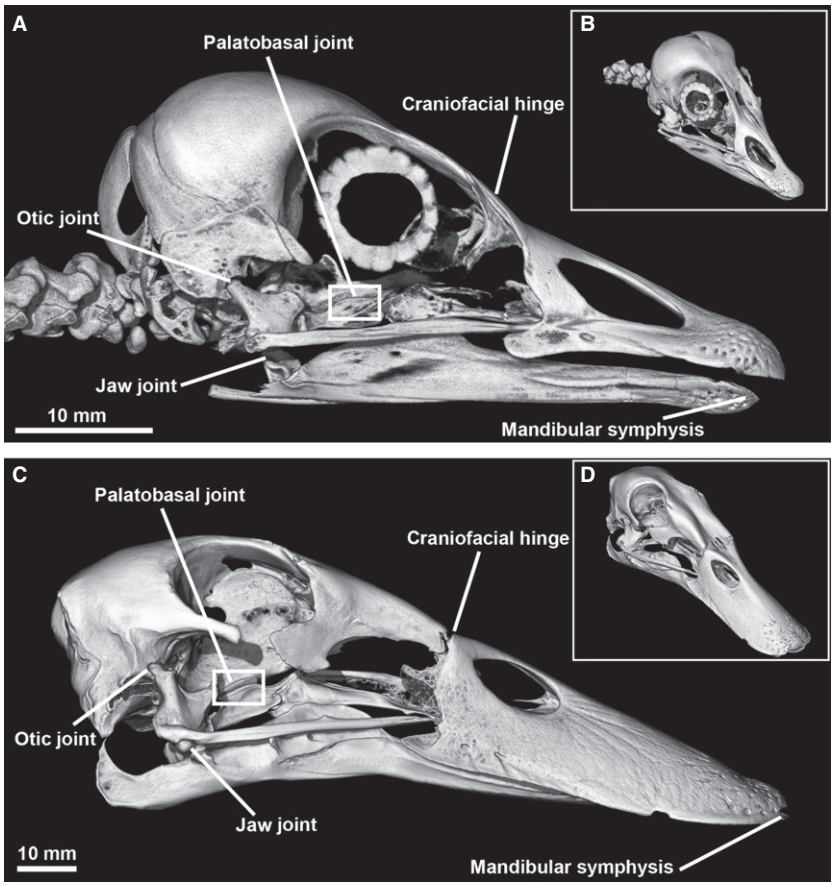


**Fig. 1** Three-dimensional micro-computed tomographic (microCT) reconstructions of the skulls of a juvenile (OUVC 10613) and an adult (OUVC 10252) mallard duck (*Anas platyrhynchos*) showing the five joints of interest. (A) Juvenile skull in right lateral view. (B) Juvenile skull in oblique dorsolateral view. (C) Adult skull in right lateral view. (D) Adult skull in oblique dorsolateral view.

the researchers and were not collected for the purpose of this research, thus not requiring animal care protocols. We are aware that the mixture of domestic and wild-caught mallards used in this study probably induced some environmental differences in their joint development and microstructure. However, because it was not possible to clearly identify epigenetic differences in the joints of our small sample, this matter (although important) will not be further discussed in this study.

The five joints of interest were extracted from frozen heads with a Dremel equipped with a rotating diamond blade. Keratin was carefully removed from the symphyses with a scalpel because keratin interferes with microtome blades. Extracted joints were then fixed in 10% neutral buffered formalin (NBF) for at least 48 h. They were then decalcified in solutions of Cal-Ex (Fisher Scientific) for 24–48 h at room temperature (and at 4 °C in the refrigerator overnight). After appropriate decalcification, samples were put back into NBF for 24 h and sent to an automated tissue processor overnight to be dehydrated into graded series of ethanol, cleared in xylene, and infiltrated with melted paraffin wax. Samples were then embedded in paraffin wax (Fisher Scientific). Sections were cut at 5 microns on a rotary microtome (Shandon Finesse Me+, ThermoFisher), placed in a warm water bath at 44 °C with gelatin (Sta-on Surgipath, Leica) and mounted on charged slides (Superfrost Plus, Fisher Scientific). Some blocks were further decalcified via surface decalcification for 1–3 h each. Mounted slides were then dried in an oven at 60 °C for 1 h. The jaw, otic and palatobasal joints were cut axially, the craniofacial hinge was cut parasagittaly, and the mandibular symphysis was cut horizontally (see orientation of cuts on Figs 2–7).

Slides were stained using a modified Masson's trichrome (Witten & Hall, 2003). Additional modifications from this protocol were carried out as follows: sections were deparaffinized with xylene for 10 min, dehydrated with graded series of ethanol for 6 min, rinsed in deionized water for 2 min, stained for 10 min with Mayer's acid hematoxylin (Sigma MSH-32), rinsed in running distilled water for 1 min, rinsed in Scott's tap water for 30 s, and rinsed again in deionized water for 1 min. Sections were subsequently stained with Xylidine Ponceau/Acid Fuschin for 2 min (equal volumes of 0.5% xylidine ponceau 2R CI no. 16150 in 1% acetic acid and 0.5% acid fuchsin CI no. 42685 in 1% acetic acid), rinsed for 10 s in deionized water, stained for 4 min with 1% phosphomolybdic acid, rinsed for 10 s in deionized water, stained with light green for 90 s (2% light green CI 42095 in 2% citric acid, diluted 1 : 10 with deionized water prior to use) and rinsed in deionized water. Sections were then dipped twice in 100% ethanol for 10 s (total of 20 s), cleared in xylene for 4 min, and finally coverslipped with Permount (Fisher Scientific).

Masson's trichrome was used as a connective tissue stain. It allows the visualization of mucopolysaccharides (cartilage matrix), high-tension collagen fibers (bone) and low-tension collagen fibers (connective tissues). Bone usually stains red, whereas cartilage stains green/blue. However, it is important to note that the identification of the different tissues presented in this paper (i.e. bone, chondroid bone, primary and secondary cartilage, other connective tissues) were based mostly on morphology rather than solely on stain color.

## Computed tomographic (CT) imaging

Histological data were coupled with osteological observations based on microCT scans of a duckling and an adult duck from

© 2016 Anatomical Society

**Table 1** Mode of ossification of the skeletal elements investigated in this study.

| Joint name | Skeletal elements/mode of ossification | |
|---|---|---|
| Jaw joint | Quadrate (endochondral) | Articular (endochondral) |
| Otic joint | Quadrate (endochondral) | Squamosal (membranous) |
| Palatobasal joint | Parasphenoid (membranous) | Pterygoid (membranous) |
| Symphysis | Dentary (membranous) | Dentary (membranous) |
| Craniofacial hinge | This joint forms within the frontal, lacrimal, premaxilla and nasal (all membranous bones) | |

Each skeletal element forming a joint can ossify indirectly via cartilage (commonly known as endochondral elements) or directly via intramembranous ossification (commonly known as membranous elements). These data are based on the embryological work of Couly et al. (1993). Note, however, that in skeletal elements that ossify indirectly via cartilage, intramembranous ossification can also occur at the same time from the periosteum (and/or after endochondral ossification is complete; see discussion in Hall, 2015, p. 15). Moreover, cartilage can arise secondarily from the periosteum of avian membrane bones and can be partly replaced by bone via endochondral ossification (avian secondary cartilage; Hall, 2000).

the Ohio University Vertebrate Collection (OUVC). The duckling (of unknown exact age) is a wild mallard that was provided as a salvage specimen by an area wildlife rehabilitation facility. The adult is a domestic mallard, obtained as a salvage specimen from a commercial duck processing facility. The duckling was scanned frozen, whereas the adult was scanned as a dry skull. Scans were conducted using a GE eXplore Locus *in vivo* Small Animal μCT scanner (Ohio University, Athens, OH, USA; 70 kV, 400 mA, interslice spacing: 45 μm for the duckling and 92 μm for the adult – 45 $\mu m^3$ voxels for the duckling and 92 $\mu m^3$ voxels for the adult). Datasets were rendered in three-dimensions using the software AVIZO LITE.

## Results

### Jaw joint: quadrate-articular

As expected, the jaw joint (quadrate-articular joint) is a synovial joint with articular cartilage on both joint surfaces and is sheathed by a fibrous capsule (Fig. 2). In the duckling, the quadrate and articular are not fully ossified and are mostly composed of hyaline cartilage (Fig. 2C–E). The articular possesses a deep fossa for m. depressor mandibulae, blood vessels and loose connective tissues (Fig. 2C). The two joint surfaces, separated by the synovial cavity, are entirely made of hyaline cartilaginous remnants of their embryonic anlagen (Fig. 2D,E; which is the Meckelian anlage for the articular). Hypertrophied calcified cartilage is less abundant than hyaline cartilage and is located farther away from the articular surface (Fig. 2F). No cartilage canals or marrow tubes were observed in this joint at this ontogenetic stage (Horner et al. 2001). The synovial cavity contains a meniscus-like portion of the quadratomandibular ligament on the lateral side of the joint (Fig. 2D).

In the adult duck, the elements are fully ossified, and the jaw joint has the overall same architecture as that of the duckling (i.e. with articular cartilage, a synovial cavity and a meniscus on the lateral side; Fig. 2I). The articular bone is now filled entirely by muscle fibers of m. depressor mandibulae (Fig. 2I). The articular cartilage is no longer composed of a homogenous hyaline cartilage, but instead it is composed of four distinct zones: (i) a blue superficial layer where the cells are oriented along the surface of the joint; (ii) another blue zone where cells are dividing and secreting cartilaginous matrix; (iii) a pink zone with numerous chondrons suggesting intensive cellular division; and (iv) a light purple zone of calcified cartilage directly adjacent to the subchondral bone plate (Fig. 2J,K). These four zones are also observed in the articular cartilage of mammalian synovial joints, and have previously been named: (i) superficial tangential zone; (ii) middle zone; (iii) deep zone; and (iv) calcified cartilage zone (Benninghoff, 1925). This zonal organization is observed through most of the joint, but some areas lack the pink, deep zone. The red/pink suggests the extensive presence of large collagen fibers (generally Type I collagen). The border between calcified and uncalcified cartilage, named the 'tidemark', can be more or less continuous (see the diffuse tidemark in Fig. 2K vs. the continuous one in Fig. 2L). Some areas have cells that are organized into columns, which is typical of fibrocartilage (and this arrangement in columns is often seen in mammalian articular cartilage; Fig. 2L). Note that this description and organization into different zones is perhaps unique to this 'adult' specimen, as articular cartilage zones vary in terms of content and abundance with growth, maturity and senescence.

### Otic joint: quadrate-squamosal

In both the ducklings and adults, the otic joint is synovial (Fig. 3). In the duckling, the synovial cavity is small (Fig. 3C,D). The articular cartilage of the quadrate is hyaline cartilage and, again, no cartilage canals or marrow tubes are observable at this stage (Fig. 3D). The squamosal shows a nodule of hypertrophied cartilage that differentiates from its periosteum, and because this element is a membrane bone, this nodule represents secondary cartilage (Fig. 3D,E). Secondary cartilage has already been found at this same joint in the developing chick and eastern rosella (Murray, 1963; Hall, 1967, 1968). The secondary cartilage is separated from the synovial cavity by a thick fibrous membrane, which is confluent with the primary cartilage of the prootic medially (Fig. 3D,E). A

© 2016 Anatomical Society

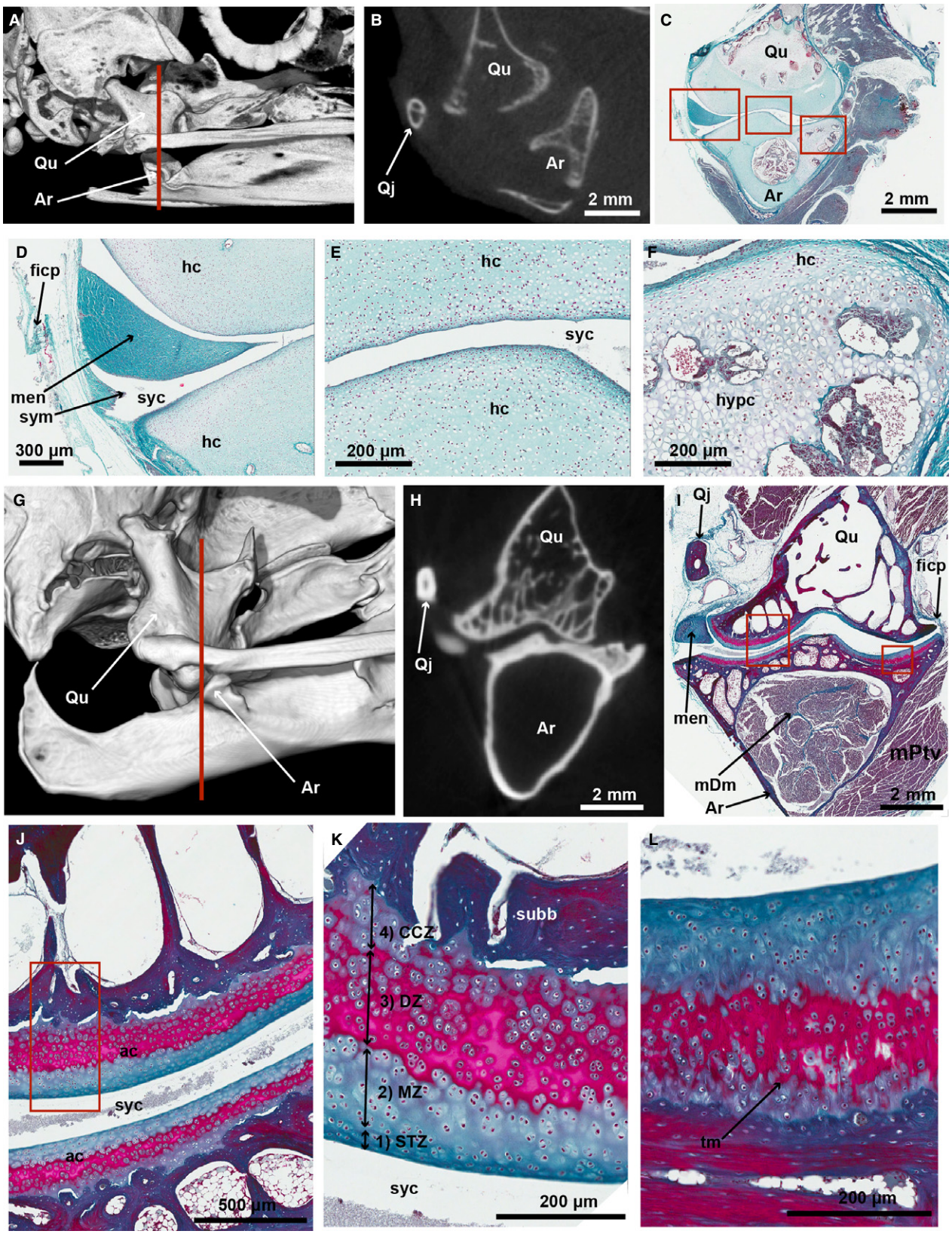


© 2016 Anatomical Society

non-chondrogenic layer lies between the hypertrophied cells of secondary cartilage and the non-hypertrophied cells of primary cartilage, and this narrow zone corresponds to the periosteum of the squamosal and the perichondrium of the prootic (Fig. 3E). In other sections, the secondary cartilage nodule of the squamosal fuses with the prootic, as in the chick (Murray, 1963). The secondary cartilage nodule is formed of three different zones (named by Hall, 1967, 1968): a zone of flattened germinal cells; a zone of hypertrophied cells (differentiated from the germinal cells); and a zone of endochondral ossification where chondrocytes are degrading and cartilage matrix is undergoing resorption (Fig. 3E).

In the adult duck, the otic joint has two articular contact zones separated by a combination of ligamentous and loose/vacuolated connective tissues within the synovial cavity (Fig. 3H). In the most dorsal contact zone, the quadrate is now fully ossified and the prootic has coossified with the squamosal (Fig. 3H–J). Although they are less distinct than on the jaw joint, the four articular cartilage zones are visible here as well. The articular cartilage on the squamosal is no longer hyaline but is now composed of fibrocartilage. The differentiation of the four zones is less pronounced on the squamosal than on the quadrate. Although it was not observed directly here, based on the observations of Hall (1967, 1968), we can safely hypothesize that: (i) the secondary cartilage of the duckling was entirely replaced by bone via endochondral ossification; and (ii) that the fibrous membrane was slowly transformed into a fibrocartilage. The layer within the periosteum that is able to produce secondary cartilage on one side can also supply chondrocytes to the fibrous membrane on the other side (Hall, 1968, p. 797; but note that the transdifferentiation/metaplasia of fibroblasts into chondroblasts cannot be ruled out). The articular cartilages on the most ventral contact zone are both composed of fibrocartilage (Fig. 3K,L). Because this contact zone was not present in the duckling, it must arise later during ontogeny.

### Palatobasal joint: parasphenoid-pterygoid

The palatobasal joint is formed between the parasphenoid rostrum (a membrane bone encasing the basisphenoid) and the pterygoids (which are also membranous bones; Fig. 4). In both the ducklings and adults, this joint is synovial. On the parasphenoid and the pterygoid, two different types of cartilage can be observed: a small amount of hypertrophic secondary cartilage (originating from their periosteum) and a large flat pad of non-hypertrophic hyaline cartilage (Fig. 4C–F). These two types of cartilage are separated by a thin non-chondrogenic layer, which corresponds undoubtedly to the periosteum of the membranous elements and the perichondrium of the hyaline cartilaginous pad (Fig. 4D,E). A similar arrangement has also been described in 1-day-old, 1-month-old and 2-month-old chicks (Hall, 1968). The dorsomedial cartilaginous pad of the pterygoid is a vestige of the palatoquadrate cartilage ('pterygoquadrate' in De Beer & Barrington, 1934), and the one on the ventrolateral surface of the parasphenoid is likely Parker's 'basipterygoid cartilaginous meniscus' (Parker, 1869, p. 791). Because the cartilaginous pad is not a fibrous meniscus, we will refer to this structure as the 'parasphenoid cartilaginous pad'. The two surfaces of the articular cartilages are flat, reflecting the rostrocaudal sliding motions that occur at this joint *in vivo*. More rostrally, the joint loses its synovial cavity and is instead connected via a syndesmosis composed of loose connective tissues. Small nodules of secondary cartilage are present on the pterygoids but not on the parasphenoid (data not shown). This syndesmodial arrangement, with secondary cartilage present only on the pterygoids, was also described in nestlings of the eastern rosella (Hall, 1967).

The adult articular cartilage on the two sides of the palatobasal joint are most likely remnants of the palatoquadrate cartilage and the parasphenoid cartilaginous pad, which fused to the pterygoid and the parasphenoid rostrum, respectively, during ontogeny. It is not clear how much of the secondary cartilage found in the ducklings contribute to the adult articular cartilage, but we hypothesize that most of it disappeared by resorption and subsequent endochondral ossification. The adult palatobasal joint possesses the same synovial organization as that of the duckling, but the adult joint is more discoidal (Fig. 4I,J) and its articular cartilage resembles that found on the quadrate and articular of adult ducks. It is made of three different layers: tangential, middle and calcified cartilage zone. In some areas, there is a faint pink stain that corresponded

**Fig. 2** Osteology and histology of the jaw joint of the mallard. (A) Three-dimensional computed tomographic (CT) reconstruction of the jaw joint of a duckling (OUVC 10613). (B) CT slice of the jaw joint indicated by the red line in (A). (C) Associated thin-section in a 3-day-old duckling (MUVC-AV39) indicated by the red line in (A). (D) Close-up of the left red box in (C). (E) Close-up of the middle red box in (C). (F) Close-up of the right red box in (C). (G) Three-dimensional CT reconstruction of the jaw joint of an adult duck (OUVC 10252). (H) CT slice of the jaw joint indicated by the red line in (G). (I) Associated thin-section in an adult duck (MUVC-AV38) indicated by the red line in (G). (J) Close-up of the left red box in (I). (K) Close-up of the red box in (J). (L) Close-up of the right red box in (I). ac, articular cartilage; Ar; articular; CCZ, calcified cartilage zone; DZ, deep zone; ficp, fibrous capsule; hc, hyaline cartilage; hypc, hypertrophied cartilage; mDm, m. depressor mandibulae; men, meniscus; mPtv, m. pterygoideus ventralis; MZ, middle zone; Qj, quadratojugal; Qu, quadrate; STZ, superficial tangential zone; sub, subchondral bone; syc, synovial cavity; sym, synovial membrane; tm, tidemark.

© 2016 Anatomical Society

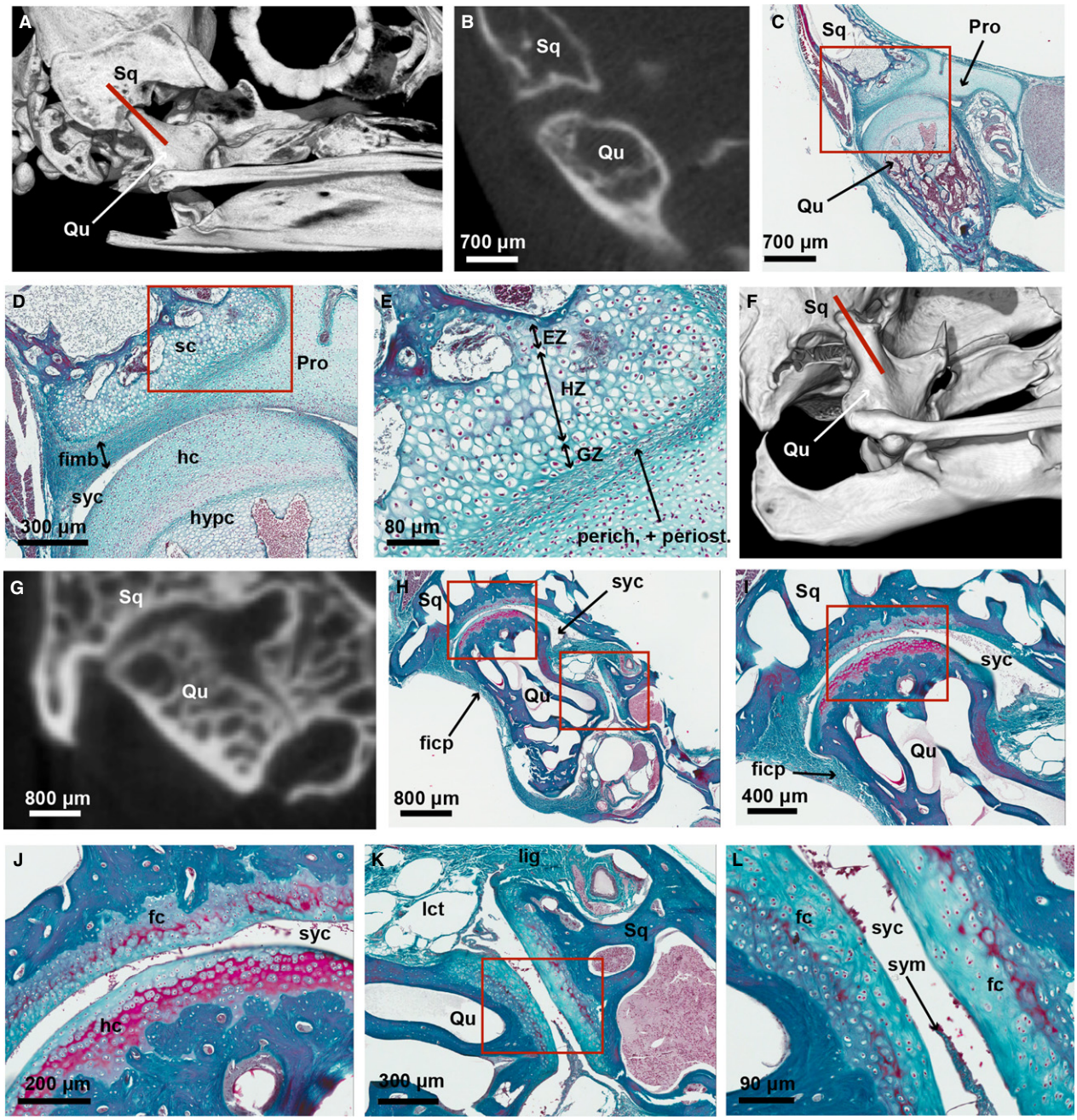


**Fig. 3** Osteology and histology of the otic joint of the mallard. (A) Three-dimensional computed tomographic (CT) reconstruction of the otic joint of a duckling (OUVC 10613). (B) CT slice of the otic joint indicated by the red line in (A). (C) Associated thin-section in a 3-day-old duckling (MUVC-AV39) indicated by the red line in (A). (D) Close-up of the red box in (C). (E) Close-up of the red box in (D). (F) Three-dimensional CT reconstruction of the otic joint of an adult duck (OUVC 10252). (G) CT slice of the otic joint indicated by the red line in (F). (H) Associated thin-section in an adult duck (MUVC-AV35) indicated by the red line in (F). (I) Close-up of the upper red box in (H). (J) Close-up of the red box in (I). (K) Close-up of the lower right red box in (H). (L) Close-up of the red box in (K). EZ, endochondral ossification zone; fc, fibrocartilage; ficp, fibrous capsule; fimb, fibrous membrane; GZ, germinative zone; hc, hyaline cartilage; hypc, hypertrophied cartilage; HZ, hypertrophic zone; lct, loose connective tissue; lig, ligament; MZ, middle zone; perich, perichondrium; periost, periosteum; Pro, prootic; Qu, quadrate; sc, secondary cartilage; Sq, squamosal; syc, synovial cavity; sym, synovial membrane.

earlier to the deep zone (Fig. 4K). The tidemark between calcified and uncalcified cartilage is clearer here than in the jaw joint or otic joint (Fig. 4K). The edges of the articular cartilage that are closest to the fibrous capsule slowly turn into a non-cartilaginous dense fibrous connective tissue (Fig. 4L).

© 2016 Anatomical Society

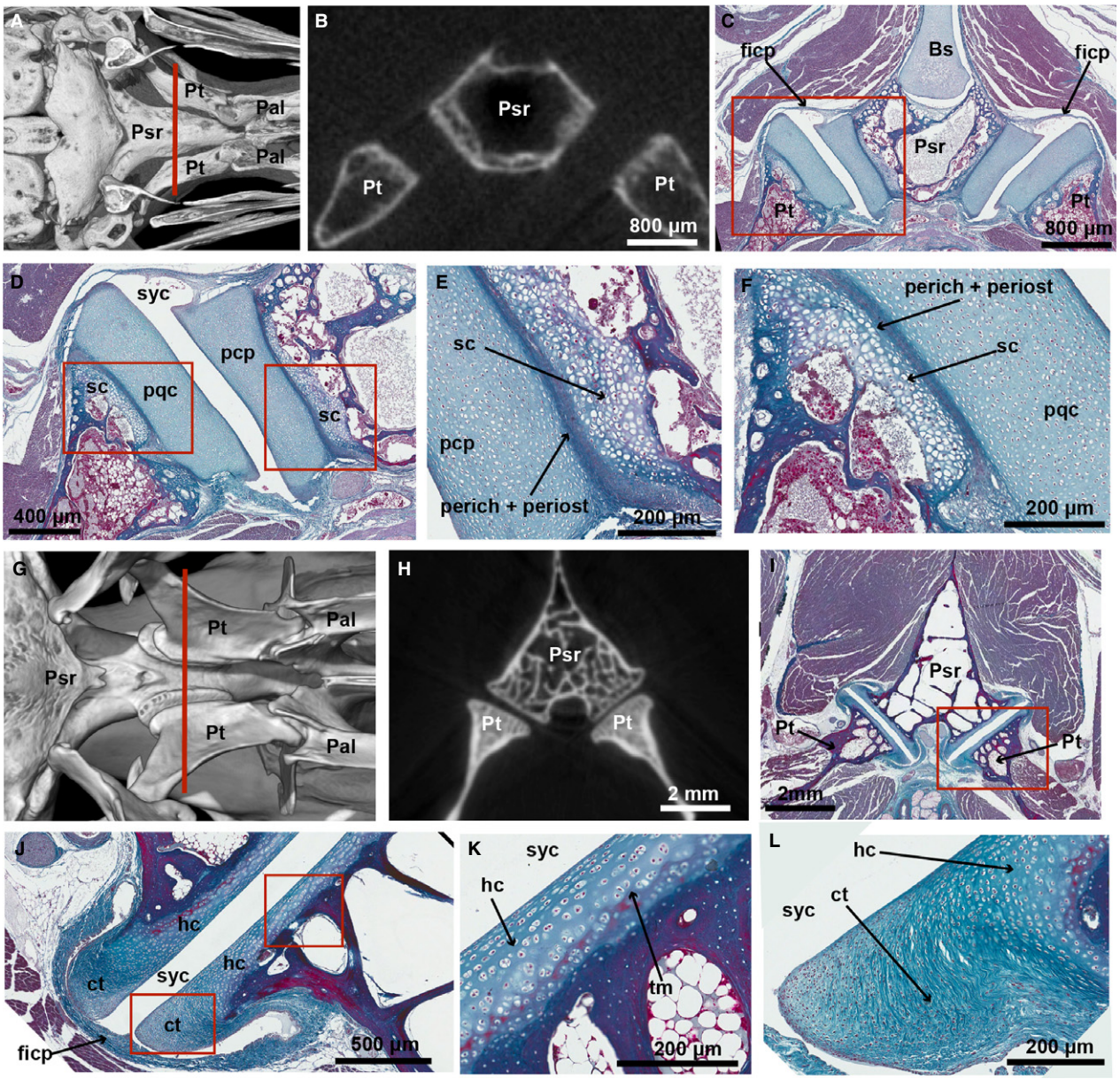


**Fig. 4** Osteology and histology of the palatobasal joint of the mallard. (A) Three-dimensional computed tomographic (CT) reconstruction of the palatobasal joint of a duckling in ventral view (OUVC 10613). (B) CT slice of the palatobasal joint indicated by the red line in (A). (C) Associated thin-section in a 3-day-old duckling (MUVC-AV40) indicated by the red line in (A). (D) Close-up of the red box in (C). (E) Close-up of the right red box in (D) (parasphenoid cartilaginous pad and secondary cartilage). (F) Close-up of the left red box in (D) (palatoquadrate cartilage and secondary cartilage). (G) Three-dimensional CT reconstruction of the palatobasal joint of an adult duck in ventral view (OUVC 10252). (H) CT slice of the palatobasal joint indicated by the red line in (G). (I) Associated thin-section in an adult duck (MUVC-AV38) indicated by the red line in (G). (J) Close-up of the red box in (I). (K) Close-up of the right red box in (J). (L) Close-up of the left red box in (J). Bs, basisphenoid; ct, connective tissue; fc, fibrocartilage; ficp, fibrous capsule; hc, hyaline cartilage; Pal, palatine; pcp, parasphenoid cartilaginous pad; perich, perichondrium; periost, periosteum; pqc, palatoquadrate cartilage; Psr, parasphenoid rostrum; Pt, pterygoid; sc, secondary cartilage; syc, synovial cavity.

## Craniofacial hinge: frontal-nasal-lacrimal-premaxilla complex

The craniofacial hinge (or prokinetic hinge, or zona flexoria craniofacialis; Zusi, 1993) of ducks is composed of the lacrimals, nasals, frontals and premaxillae (Figs 5 and 6). In the ducklings, each element is formed of thin, overlapping, often avascular struts separated from each other by sutures (Fig. 5). These struts are composed mostly of chondroid bone, a tissue that has cartilage-like, rounded cells embedded in a bone-like matrix (Fig. 5F–I). The rate of deposition of chondroid bone is extremely high (Goret-

© 2016 Anatomical Society

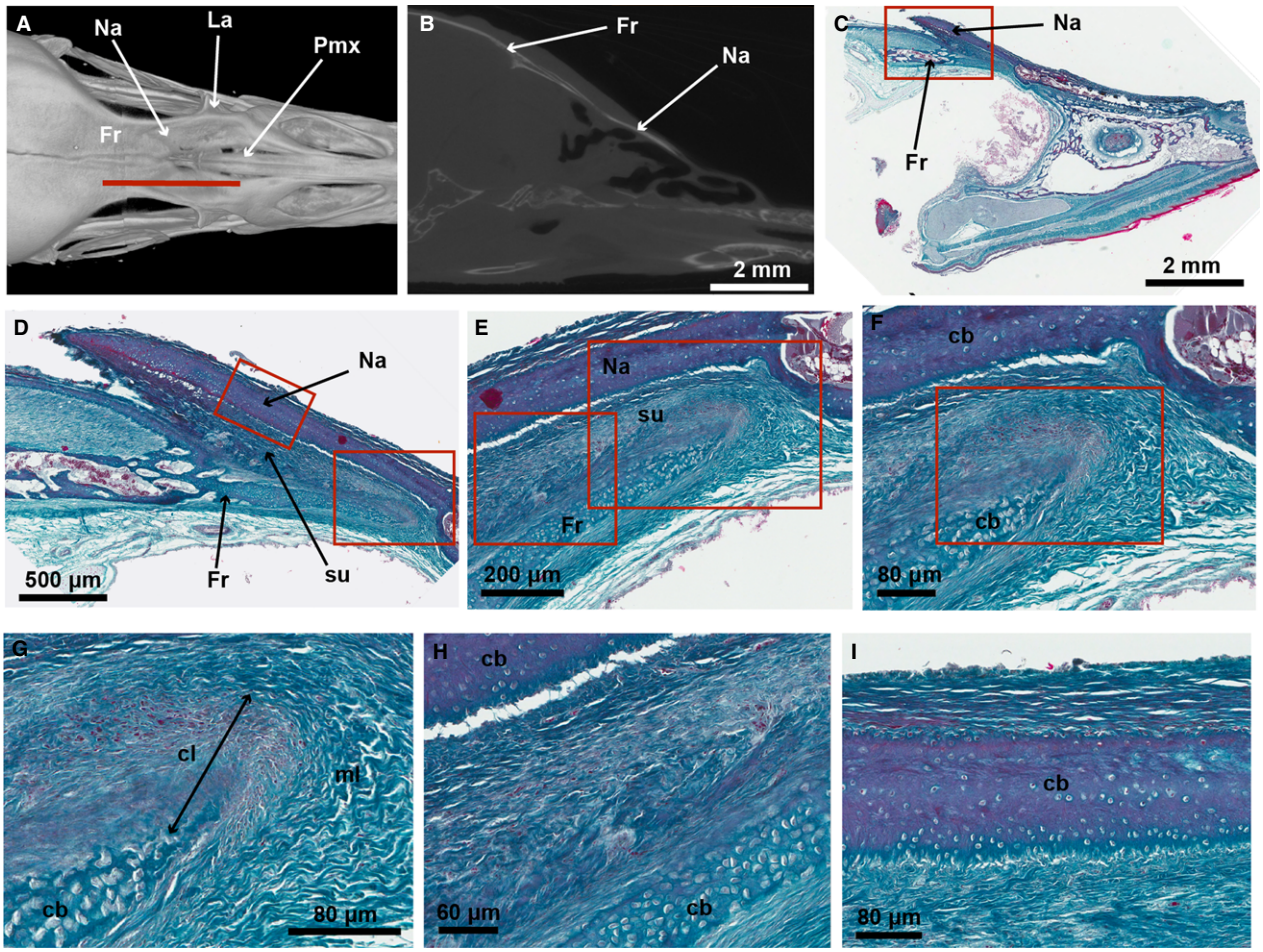


**Fig. 5** Osteology and histology of the craniofacial hinge of mallard ducklings. (A) Three-dimensional computed tomographic (CT) reconstruction of the craniofacial hinge of a duckling in dorsal view (OUVC 10613). (B) CT slice of the craniofacial hinge indicated by the red line in (A). (C) Associated thin-section in a 3-day-old duckling (MUVC-AV39) indicated by the red line in (A). (D) Close-up of the red box in (C). (E) Close-up of the right red box in (D). (F) Close-up of the right red box in (E). (G) Close-up of the red box in (F). (H) Close-up of the left red box in (E) showing an area where the cambial layer is not easily discernable. (I) Close-up of the nasal bone (left red box in D) showing that it is made of chondroid bone. cb, chondroid bone; cl, cambial layer; Fr, frontal; La, lacrymal; ml, middle layer; Na, nasal; Pmx, premaxilla; su, suture.

Nicaise, 1986; Huysseune & Verraes, 1986; Taylor et al. 1994; Gillis et al. 2006), and this tissue forms in response to mechanical forces (Lengelé, 1997; Rafferty & Herring, 1999). It has already been reported in the sutural areas of chick embryos (Lengelé et al. 1996). The surrounding sutures are composed of a dense connective tissue containing an osteogenic (i.e. cambial) layer and a non-osteogenic layer (Fig. 5E–G), although the distinction between these layers is not always clear (Fig. 5H). This organization (with one osteogenic and one non-osteogenic layer) is similar to

**Fig. 6** Osteology and sagittal sections of the craniofacial hinge of adult mallard ducks. (A) Three-dimensional computed tomographic (CT) reconstruction of the craniofacial hinge of an adult duck in dorsal view (OUVC 10252). (B) CT slice of the craniofacial hinge indicated by the upper red line in (A). (C) Associated thin-section in an adult duck (MUVC-AV38) indicated by the upper red line in (A). (D) Close-up of the left black box in (C). (E) Close-up of the black box in (D). The white arrows indicate aligned chondrocytes, resembling fibrocartilage. (F) Close-up of the right black box in (C) (showing the clear limit between the chondroid bone bridge and lamellar bone). (G) CT slice of the craniofacial hinge indicated by the lower red line in (A). (H) Associated thin-section in an adult duck indicated by the lower red line in (A). (I) Close-up of the black box in (H). (J) Close-up of the upper black box in (I). (K) Close-up of the black box in (J). (L) Close-up of the first black box below the chondroid bone bridge in (I). (M) Close-up of the second black box below the chondroid bone bridge in (I), showing the difference in thickness of the fibrous membrane on the cranial and facial sides. (N) Close-up of the third black box below the chondroid bone in (I), showing the differences between the fibrous membrane and fibrocartilage. (O) Close-up of the fourth black box below the chondroid bone bridge in (I), showing two articular surfaces made of fibrocartilage (secondary cartilage). cb, chondroid bone; ct, connective tissue; fc, fibrocartilage; ficp, fibrous capsule; fimb, fibrous membrane; lb, lamellar bone; Na, nasal; syc, synovial cavity.

© 2016 Anatomical Society

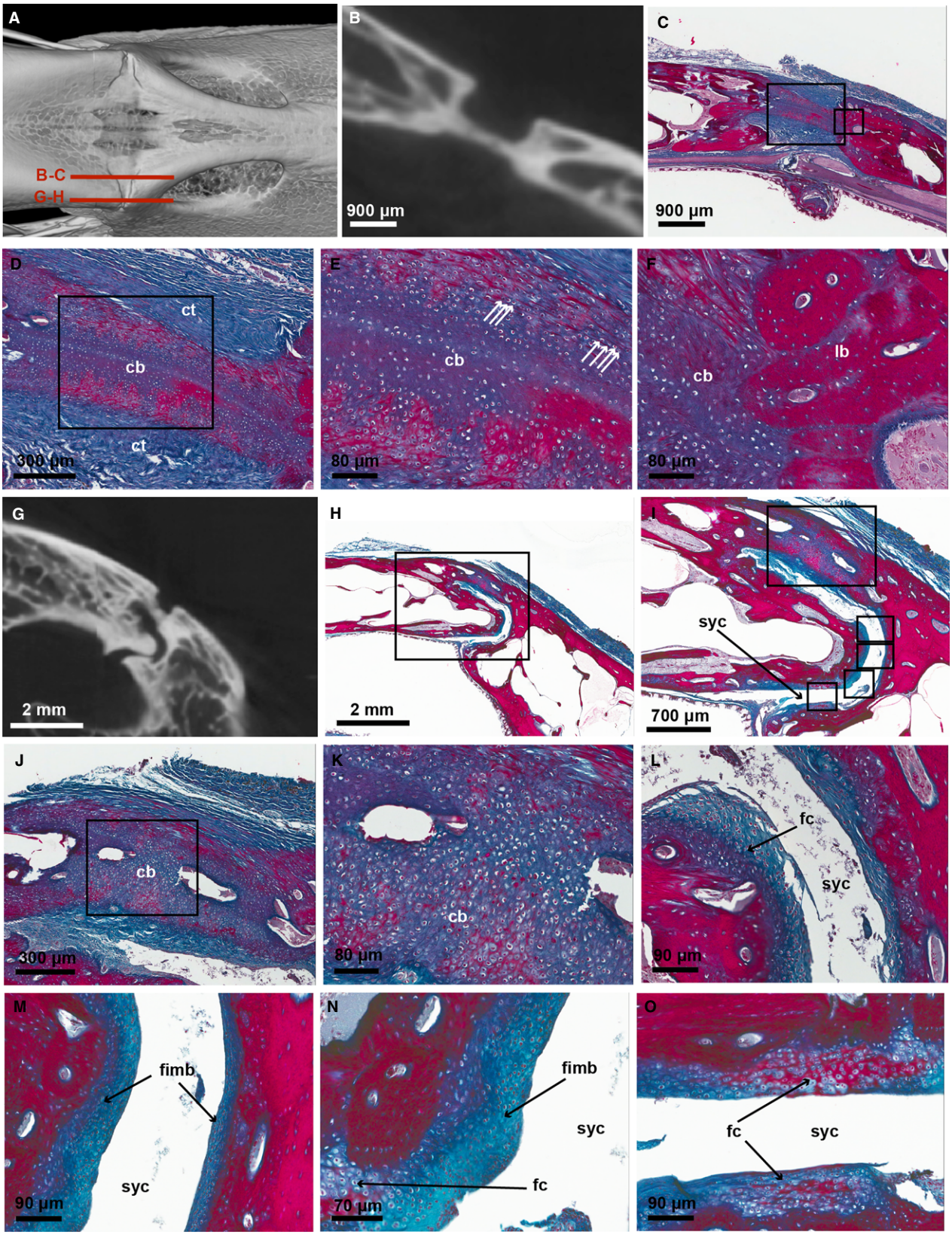


© 2016 Anatomical Society

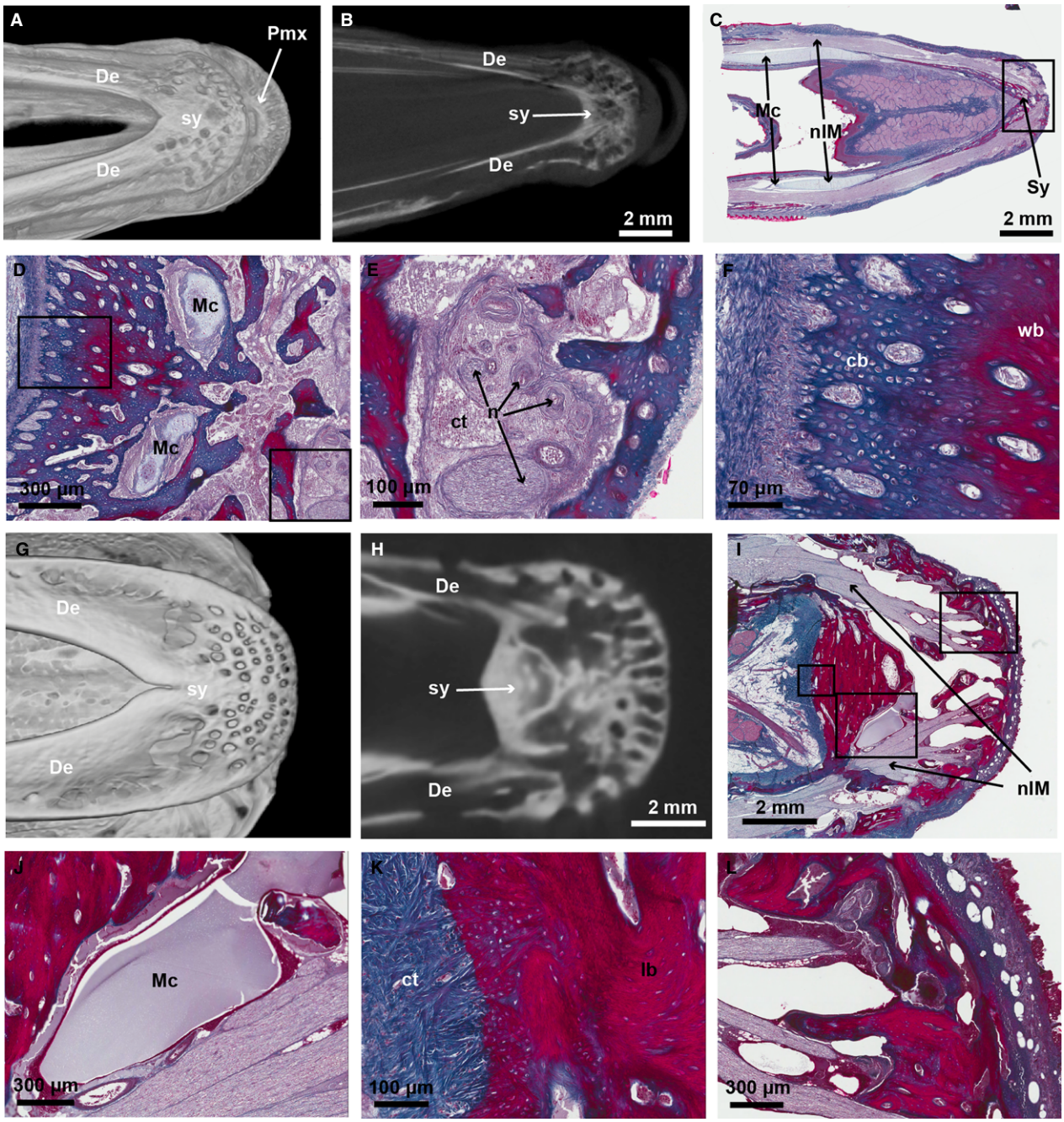


**Fig. 7** Osteology and histology of the mandibular symphysis of the mallard. (A) Three-dimensional computed tomographic (CT) reconstruction of the mandibular symphysis of a duckling (OUVC 10613) in ventral view. (B) CT slice of the mandibular symphysis oriented in the same plane as that of the paper. (C) Associated thin-section in a 3-day-old duckling (MUVC-AV39). (D) Close-up of the black box in (C). (E) Close-up of the right black box in (C). (F) Close-up of the left black box in (D). (G) Three-dimensional CT reconstruction of the mandibular symphysis of an adult duck (OUVC 10252) in ventral view. (H) CT slice of the mandibular symphysis oriented in the same plane as that of the paper. (I) Associated thin-section in an adult duck (MUVC-AV37). (J) Close-up of the lower black box in (I) showing Meckel's cartilage. (K) Close-up of the left black box in (I). (L) Close-up of the right black box in (I) (the tip of the beak). cb, chondroid bone; ct, connective tissue; De, dentary; lb, lamellar bone; Mc, Meckel's cartilage; n, nerve fibers; nIM, intramandibular nerve; Pmx, premaxillae; sy, symphysis; wb, woven bone.

that observed in the frontoparietal and the internasal sutures of growing emus (Bailleul & Horner, 2016), and of mammal sutures in general (Pritchard et al. 1956; Persson, 1973).

In the adult duck, the craniofacial hinge has a very different organization: medially, the nasals, frontals and premaxillae are fused and the sutures are synostosed, whereas laterally it is a complex joint involving a combination of

© 2016 Anatomical Society

synostosis and synovial joint (Fig. 6). Bühler described this organization as a flexion zone 'additionally stabilized by a pair of lateral synovial joints' (Bühler, 1981). At the macroscopic scale, the craniofacial hinge forms a trough running transversely across the base of the upper bill (Fig. 6A). Although CT data suggest that the thin bridge forming the trough and the adjacent thicker struts are made of bone (Fig. 6B), histology reveals that they are made of different skeletal tissues (Fig. 6C–F): the thin, avascular strut in the flexion zone is made of chondroid bone (Fig. 6E) just like the thin struts were in the ducklings (Fig. 5I), whereas the thicker struts are made of lamellar bone with secondary osteons (Fig. 6F). Again, we identify chondroid bone based on its cartilage-like rounded cells and its bone-like matrix (Fig. 6E). In the chondroid bone bridge of the craniofacial hinge, some cells are even oriented in lines, resembling fibrocartilage (Fig. 6E, arrows). Horizontal sections showed that this strut of chondroid bone is present across the entire joint (Fig. S1).

Laterally, the chondroid bone bridge is still observed, but it overlays a synovial joint between the lacrimal and the nasal bones (note that this synovial joint was not observed in the 3-day-old duckling; Fig. 6G–K). The chondroid bone bridge in this area is much more cellular than the previously described one (compare Fig. 6K and E). There is articular cartilage covering the surfaces of the synovial cavity, with thicker pads on the caudal side than on the rostral side (Fig. 6L,M). They do not share the same distinct zones as those that were described previously (i.e. on the adult quadrate, articular, pterygoid or parasphenoid), instead they appear to be a mix of fibrocartilage and thick fibrous membrane in which cartilage lacunae are not always present (Fig. 6L,M). On the rostral side of the joint, cartilage does not cover the entire surface, but instead a very thin fibrous membrane can be seen in some areas (Fig. 6M). Due to the membranous ossification of the lacrimal and nasal bones, these articular cartilages are by definition secondary cartilages. Such a synovial articulation between two membrane bones has already been reported in nestlings of the eastern rosella (Hall, 1967; although without mention of a chondroid bone bridge), but we show photomicrographs of this joint for the first time. Because this synovial joint was not observed in 3-day-old ducklings, it is concluded that it forms later on during ontogeny, and this delayed formation compared with that of the other joints was also reported in the eastern rosella (Hall, 1967).

### Mandibular symphysis: dentary-dentary

In the 3-day-old duckling, the two dentaries are already fused via a synostosis (Fig. 7; Eames & Schneider, 2008). The trabeculae are made of woven and chondroid bone as in the symphyses of other vertebrate species (Fig. 7F; Goret-Nicaise, 1984; Bailleul et al. 2016). Passing throughout the bony trabeculae are pockets of loose connective tissue, adipose tissue and intramandibular neurovasculature (Fig. 7E). This nerve runs along the whole length of the dentary and then branches once it arrives at the tip of dentary (Fig. 7C). The density of nerve fibers indicates that the symphysis is a sensory organ (Fig. 7C; Olsen, 2015). Meckel's cartilage passes obliquely from the caudoventral dentary into the mandibular symphysis rostrally, forming a cartilaginous core within the trabecular bone (Fig. 7C) rostrally within the synostosis (Fig. 7D). Meckel's cartilage has the appearance of a senescent/atrophied cartilage and no trace of endochondral ossification can be seen.

The adult duck symphysis is similar in organization to that of the duckling. The two dentaries are synostosed (which is typical of all living birds; Bühler, 1981), the intramandibular nerve permeates towards the most rostral part of the beak, and a senescent remnant of Meckel's cartilage remains (Fig. 7G–J). Here, the latter can only be seen on one side, and it appears even more senescent than that of the duckling (Fig. 7J). However, the adult synostosis is mostly made of lamellar bone (instead of woven bone; Fig. 7K), and there are large empty areas (Fig. 7I,L).

## Discussion

We explored the microanatomy of cranial articulations within the heads of juvenile and adult ducks. Overall, we found that most articulations are constructed differently despite their broad categorizations as sutures or synovial joints, suggesting a more refined understanding of joint diversity and its nomenclature is necessary. The tissue composition of these different types of sutural and synovial articulations likely reflects not only developmental patterns of participating cranial elements but also the biomechanical environment of the joint. This rich interplay between development, function and morphology is key to better understanding the evolution of cranial kinesis in birds and other vertebrates.

### Comparative joint microstructure

We described three different structural joint categories in the heads of mallard ducks: fibrous (i.e. sutures); bony (i.e. synostoses); and synovial joints. Within the five fibrous joints investigated here, sutures were only observed in the ducklings at the craniofacial hinge (Fig. 5), synostoses were observed at the mandibular symphysis in both ontogenetic stages (Fig. 7), and synovial joints formed the jaw, otic and palatobasal joints in both stages (Figs 2–4). The adult craniofacial hinge was a complex joint involving a combination of a synostosis and a synovial joint, for which no clear structural category exists (Fig. 6). A schematic representation of the adult microstructure of these joints is illustrated in Fig. 8.

The sutures observed in ducklings at the craniofacial hinge and the synostoses observed at the mandibular

© 2016 Anatomical Society

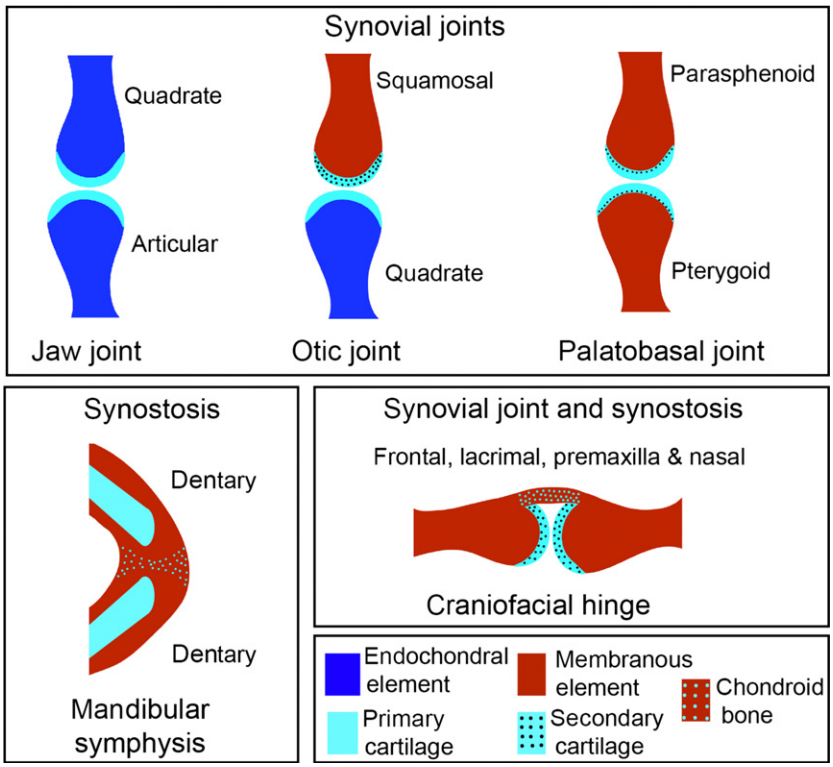


**Fig. 8** Schematic representation of the adult structure of the five joints investigated in this study. The jaw, otic and palatobasal joints are synovial. All membranous elements present secondary articular cartilage. The mandibular symphysis is a synostosis that involves primary cartilage (rods of Meckel's cartilage) and chondroid bone. The craniofacial hinge is a complex joint involving a synovial cavity with secondary articular cartilage and a bridge of chondroid bone. It can be classified as a combination of a synovial joint and a synostosis. For this joint, all four bones (the frontal, lacrimal, premaxilla and nasal) cross the flexion zone.

symphyses (Figs 5 and 7) did not present any unexpected results in this study. For example, the sutures showed a sutural periosteum with numerous osteoblasts and a non-osteogenic layer (Fig. 5). This architecture is similar to the overall sutural microstructure of mammals (Pritchard et al. 1956; Persson, 1973), and to that of some craniofacial sutures in growing emus (Bailleul & Horner, 2016). Moreover, finding chondroid bone in these sutural areas (Fig. 5F–I) was also not surprising, as it was also reported in the sutural areas of chick embryos (Lengelé et al. 1996), young emus (Bailleul & Horner, 2016), and in the developing skull of the American alligator (Vickaryous & Hall, 2008).

We found major microstructural variations among the four synovial joints that were investigated, and these variations are undoubtedly due to the fact that avian synovial joints have three different structural possibilities (Table 1): they may involve two endochondral elements (e.g. the jaw joint); one endochondral and one membranous element (e.g. the otic joint); or even two (or more) membranous elements (e.g. the synovial joint at the craniofacial hinge; Fig. 8). The major differences mentioned above are seen between the primary articular cartilage of endochondral bones and the secondary articular cartilage of membranous bones: in the adults, articular cartilage found within endochondral elements (i.e. quadrate and articular) shows the clearest distinctions between the four cartilage zones (Fig. 2J,K). These four zones were not observed in the jaw joint of lizards (also stained with Masson's trichrome; Payne et al. 2011), nor on the condylar cartilage of the dentary in human temporomandibular joints (TMJs; Weinmann & Sicher, 1964; Avery, 2006). The articular cartilage of endochondral elements (i.e. the quadrate and articular) presents the appearance of hyaline cartilage (Fig. 2K), which typically only possesses collagen II. However, the red/pink color in some of the layers suggests the presence of high amounts of Type I collagen fibers, which is a characteristic of fibrocartilage (but note, however, that collagen fiber subtypes can only truly be identified by immunohistochemistry). In contrast, the secondary articular cartilages of the adults appear much more fibrous and less hyaline: on the squamosal, the articular cartilage appears like typical mammalian fibrocartilage (Fig. 3J–L); and at the craniofacial synovial joint, articular cartilage is even more fibrous (i.e. a mix of fibrocartilage and thick fibrous membrane; Fig. 6L–N). This difference in fiber content may be due to their mode of formation in that adult secondary cartilages form within an already fibrous tissue (the fibrous membrane; Hall, 1967, 1968), whereas articular cartilages on endochondral elements are considered remnants of the hyaline cartilage anlagen (but see debates on the origin of articular cartilage in Khan et al. 2007). Fibrocartilage is not commonly found in the postcranial synovial joints of mammals, except as a reparative tissue in pathological conditions or during ageing (Tillmann, 1973; Huber et al. 2000; Madry et al. 2010; Hoemann et al. 2012). However, the TMJ, the only synovial joint within the skull of humans, appears to possess fibrocartilage rather than hyaline cartilage on its temporal bone during adulthood (Weinmann & Sicher, 1964; Thilander

© 2016 Anatomical Society

et al. 1976). The adult articular cartilage of the palatobasal joints of mallard ducks appears more hyaline than fibrous (Fig. 4J,K), perhaps because they are mostly derived from the hyaline palatoquadrate cartilage and the parasphenoid cartilaginous pad.

Categorizing these avian articular cartilages using standard mammal-based nomenclature (i.e. hyaline vs. fibrocartilage) presents a challenge for hypotheses of tissue homology and terminology that spans vertebrate clades. It has already been reported that the articular cartilage in the knee joint of chickens is 'neither a typical hyaline nor a typical fibrous cartilage' (Graf et al. 1993). Moreover, almost all the articular cartilages of the mallard ducks (and especially in the jaw joint) appeared to have Type I collagen fibers deep within the cartilage. In mammalian articular cartilage, when Type I collagen is present, it is found mostly in the superficial chondrocytes at the articular surface (e.g. in rat limb joints; Sasano et al. 1996). This finding suggests that avian and mammalian cartilages are different, and trying to 'fit' avian cartilages into mammalian categories may be misguided. Instead, using both histology and immunohistochemistry, a more thorough classification system of avian, archosaur and, more broadly, amniote cartilages is likely required before clear form-function, developmental and evolutionary hypotheses can be tested.

## Functional joint histology

Skeletal tissues, such as hyaline cartilage and fibrocartilage, should reflect the different mechanical environments found within synovial joints, because tissues are known to respond to loading in predictable ways (Wolff, 1870, 1892; Carter, 1987; Frost, 1999). For example, the proteoglycans of hyaline cartilage resist compression, whereas the large collagen fibers within fibrocartilage resist shear and tension (Myers & Mow, 1983). Evidence of a form-function relationship has been established for avian secondary cartilage: it arises and is maintained by intermittent compression and/or shear (Hall, 1967, 1972, 1979, 1986; Solem et al. 2011). The mechanobiology of chondroid bone is less understood: it arises in sites that experience tension (at the sutural borders of growing chicks; Lengelé, 1997) or high compressive loads (in a pig suture; Rafferty & Herring, 1999). In the present study, we found chondroid bone within the bending zone of the craniofacial hinge (Figs 5 and 6), where the tissue experiences bending during prokinetic movements (Dawson et al. 2011). By definition, any material in bending will experience tension on one surface and compression on the opposite (Gere, 2001). Because the entire craniofacial bridge was formed of chondroid bone, we hypothesize that this tissue arises in zones that experience high levels of strain, regardless of whether it be tension, compression or even shear. Furthermore, we hypothesize that chondroid tissue has intermediate biomechanical characteristics between those of typical bone and cartilage, and that it facilitates movements within the flexion zone of mallard ducks (in other words, flexion could be mediated specifically by chondroid bone). Combining these microstructural data with mechanical analyses will shed light on the mechanobiology of avian flexion zones and other chondroid bone-mediated articulations.

Additional histological data are necessary to fully understand the mode of formation of this bridge of chondroid bone within the craniofacial hinge. However, our preliminary data suggest that the bridge forms within the bones (not between the bones), as the frontals, premaxillae and nasals all cross the hinge in ducklings (Fig. 5A). Chondroid bone is known to be formed in response to stress, and then resorbed and replaced by lamellar bone once the mechanical forces due to growth are reduced (Lengelé, 1997). Because it is found in small quantity in the ducklings and in great quantity in the adults, it is safe to hypothesize that this chondroid bone was maintained throughout ontogeny (i.e. it was not resorbed), and its consistent presence is induced by the stress this region receives during feeding. However, another possible explanation is that this bridge also forms via metaplasia from the dense connective tissues that surround it. Indeed, the most dorsal and ventral parts of the bridge are more fibrous (i.e. resembling fibrocartilage) than the deeper, more internal zones of the bridge (Fig. 6E), suggesting a possible superficial incorporation of pre-formed collagen fibers. Our hypotheses can only be confirmed with a denser ontogenetic and histological sample of this joint in the mallard duck (because our data have a wide 'gap' in age from 3-day-old ducklings to adults). Investigating this flexion zone in other species of birds, but also the potentially similarly-built jugal and palatine flexion zones (Bühler, 1981), will also reveal if its mode of formation is a species-specific or a highly conserved mechanism.

## Insights into the evolution and origin of avian cranial kinesis

Modern birds are far more kinetic than their dinosaurian ancestors (Holliday & Witmer, 2008). Numerous morphological changes occurred to achieve this innovation in cranial function, including miniaturization, loss of bones, bony fusions, pneumatization, and the formation of secondary articulations (Holliday & Witmer, 2008). However, the tempo and mode of these acquisitions remain unclear, particularly in how the cranial articulations changed in composition and morphology. The results of the present study combined with those of previous investigations (Hall, 2000; Holliday & Witmer, 2008; Bailleul et al. 2012, 2013) now enable us to also track the microscopic changes in joint morphology that led to avian cranial kinesis. Thus far, we have found two major microstructural characteristics in the heads of birds that are not shared with other extant sauropsids: extant birds can: (i) form articular cartilage on their membrane bones via secondary cartilage; and (ii) they can form

© 2016 Anatomical Society

synovial joints between two membrane bones (i.e. within the dermatocranium); whereas other extant reptiles can only build sutures (not synovial joints) between membrane bones.

The unique ability of birds among extant sauropsids to form articular secondary cartilage comes from the bi-potentiality of their periosteal stem cells (Hall, 2000). Functionally, this translates as having articular cartilage always present on the two sides of the synovial cavity, regardless of whether or not a membranous element forms the joint. In non-avian sauropsids, synovial joints involving a membranous and an endochondral element only have articular cartilage on the endochondral bone. For example, the otic joint of the mallard duck has cartilage on both the endochondral quadrate and the membranous squamosal (Fig. 3), whereas in geckos, this joint only has articular cartilage on the endochondral quadrate (Payne et al. 2011). The epipterygoid-pterygoid joint of lizards only has articular cartilage on the endochondral epipterygoid (fig. 3F in Payne et al. 2011). Among non-avian dinosaurs, so far, secondary cartilage has been found at articulations between the surangular-quadrate portion of the jaw joint, a presumably secondary articulation between the jugal and coronoid process, and around alveoli in the ornithischian dinosaur *Hypacrosaurus* (Bailleul et al. 2012, 2013), suggesting the ability to form secondary cartilage may be shared by many dinosaur clades and not just avian dinosaurs. However, more data are needed to understand the distribution of this trait.

It is reasonable to hypothesize that biomechanical differences exist between synovial joints that have two articular surfaces and those possessing only one articular surface, because articular cartilage has cushioning, shock-absorbing properties. Here, we propose two new terms to further describe these two types of joints: bichondral and unichondral synovial joints, respectively. Even though secondary cartilage has not yet been investigated in extinct saurischian dinosaurs, it is fair to hypothesize that it became more abundant during the dinosaur-bird transition and played a biomechanical role in the origins of avian cranial kinesis by allowing the formation of novel, bichondral synovial joints (also see discussion in Bailleul et al. 2013), instead of fibrous sutures (which were presumably less kinetic).

Despite the acquisition of secondary cartilage and its potential role in avian cranial kinesis, equally extreme forms of kinesis found in lepidosaurs and secondary articulations in non-dinosaurian archosaurs are not mediated by secondary cartilage (Irwin & Ferguson, 1986), showing that secondary cartilage is not a *sine qua non* condition for cranial kinesis. For example, crocodilians appear to be incapable of forming secondary cartilage (Hall, 2000; Vickaryous & Hall, 2008), and instead they appear to employ a thick layer of dense connective tissues over the membranous pterygomandibular joint of American alligators (data not shown). Cranial kinesis in lizards and snakes is mediated by highly extensible fibrous tissues that cross the mandibular symphysis (Holliday et al. 2010) and other joints but not by secondary cartilage. Finally, kinesis can be mediated by vestiges of chondrocranial elements like the palatoquadrate cartilage. In lizards and ducks, so far, it appears that the palatoquadrate cartilage remains as an articular surface between the pterygoid and parasphenoid. Because the palatoquadrate cartilage is a vestige of the ancestral mandibular arch, these are examples of exaptation, where an ancestral cartilaginous structure was reallocated and used as articular cartilage. Perhaps additional examples of cushioning, articular tissues are more abundant than previously thought in the skulls of reptiles, including in non-avian dinosaurs.

Lastly, and most importantly, birds can form synovial joints between their membrane bones (in other words, within their dermatocranium, e.g. at the craniofacial hinge, Fig. 6; the pterygoid-palatine articulation, data not shown; Hall, 1967). To our knowledge, no synovial joint exists between two membrane bones in any other clade of extant sauropsid and, instead, these articulations are always sutures or synostoses (which are relatively akinetic when compared with synovial joints). Perhaps this ability to form synovial joints in membranous areas of the skull where other reptiles cannot, likely facilitated the origin of avian cranial kinesis among non-avian dinosaurs. Further investigation of cranial joint histology in extant sauropsids and non-avian dinosaurs is needed to assess what kind of tissues played a role in the shaping of this evolutionary innovation. The present study still provides considerable advances in our understanding of extant bird joints and cranial kinesis.

## Acknowledgements

The authors thank Ramona Duck Farm for specimens; Kathy Shaw and Diane McDonnell for histological training and assistance; Carolynn Park at the Histology Laboratory of MU. The authors also thank Mikhail Kovalenko for whole-slide imaging and scanning. The authors are indebted to Brian K. Hall, Matthew Vickaryous, Andrew Gillis and Kevin Middleton for discussions and insights. AMB is especially indebted to Brian K. Hall for his discussions and insights on secondary cartilage. This research was funded by US National Science Foundation (NSF) grant IOS 1457319 to CMH, the Department of Pathology and Anatomical Sciences at MU, and NSF grants IOB-0517257, IOS-1050154, IOS-1456503 to LMW.

## References

**Archer CW, Dowthwaite GP, Francis-West P** (2003) Development of synovial joints. *Birth Defects Res C Embryo Today* **69**, 144–155.

**Avery JK, Chiego DJ** (2006) *Essentials of Oral Histology and Embryology: a Clinical Approach*. St. Louis, Missouri: Mosby Elsevier.

**Bailleul AM, Horner JR** (2016) Comparative histology of some craniofacial sutures and skull-base synchondroses in non-avian

© 2016 Anatomical Society

dinosaurs and their extant phylogenetic bracket. *J Anat* **229**, 252–285.

**Bailleul AM, Hall BK, Horner JR** (2012) First evidence of dinosaurian secondary cartilage in the post-hatching skull of *Hypacrosaurus stebingeri* (Dinosauria, Ornithischia). *PLoS ONE* **7**, e36112.

**Bailleul AM, Hall BK, Horner JR** (2013) Secondary cartilage revealed in a non-avian dinosaur embryo. *PLoS ONE* **8**, e56937.

**Bailleul AM, Nyssen-Behets C, Lengelé B, et al.** (2016) Chondroid bone in dinosaur embryos and nestlings (Ornithischia: Hadrosauridae): insights into the growth of the skull and the evolution of skeletal tissues. *CR Palevol* **15**, 49–64.

**Baumel J, Witmer L** (1993) Osteologia. In: *Handbook of Avian Anatomy: Nomina Anatomica Avium*. (ed Baumel JJ), pp. 45–132. Cambridge, Massachusetts: Publications of the Nuttall Ornithological Club.

**Bellairs A, Kamal A** (1981) The chondrocranium and the development of the skull in recent reptiles. *Biol Reptilia* **11**, 1–264.

**Benninghoff A** (1925) Form und Bau der Gelenkknorpel in ihren Beziehungen zur Funktion. *Cell Tissue Res* **2**, 783–862.

**Bock WJ** (1960) Secondary articulation of the avian mandible. *Auk* **77**, 19–55.

**Bock WJ** (1964) Kinetics of the avian skull. *J Morphol* **114**, 1–41.

**Bout RG, Zweers GA** (2001) The role of cranial kinesis in birds. *Comp Biochem Physiol A: Mol Integr Physiol* **131**, 197–205.

**Bühler P** (1981) Functional anatomy of the avian jaw apparatus. *Form Funct Birds* **2**, 439–468.

**Carter DR** (1987) Mechanical loading history and skeletal biology. *J Biomech* **20**, 1095–1109.

**Cherry P, Morris TR** (2008) *Domestic Duck Production: Science and Practice*. Cambridge, Massachusetts: CABI.

**Couly GF, Coltey PM, Le Douarin NM** (1993) The triple origin of skull in higher vertebrates: a study in quail-chick chimeras. *Development* **117**, 409–429.

**Dawson MM, Metzger KA, Baier DB, et al.** (2011) Kinematics of the quadrate bone during feeding in mallard ducks. *J Exp Biol* **214**, 2036–2046.

**De Beer G** (1937) *The Development of the Vertebrate Skull*. Oxford: Clarendon Press.

**De Beer G, Barrington E** (1934) The segmentation and chondrification of the skull of the duck. *Philos Trans R Soc B* **223**, 411–467.

**Eames BF, Schneider RA** (2008) The genesis of cartilage size and shape during development and evolution. *Development* **135**, 3947–3958.

**Frost HM** (1999) Joint anatomy, design, and arthroses: insights of the Utah paradigm. *Anat Rec* **255**, 162–174.

**Gans C** (1961) The feeding mechanism of snakes and its possible evolution. *Integr Comp Biol* **1**, 217–227.

**Gere JM** (2001) *Mechanics of Materials*. Pacific Grove, CA: Brooks/Cole.

**Gillis J, Witten P, Hall B** (2006) Chondroid bone and secondary cartilage contribute to apical dentary growth in juvenile Atlantic salmon. *J Fish Biol* **68**, 1133–1143.

**Goret-Nicaise M** (1986) *La Croissance de la Mandibule Humaine: Conception Actuelle*. Brussels: Université catholique de Louvain.

**Goret-Nicaise M, Lengele B, Dhem A** (1984) The function of Meckel's and secondary cartilages in the histomorphogenesis of the cat mandibular symphysis. *Arch Anat Microsc Morphol Exp* **73**, 291–303.

**Graf J, Stofft E, Freese U, et al.** (1993) The ultrastructure of articular cartilage of the chicken's knee joint. *Int Orthop* **17**, 113–119.

**Gussekloo SW, Bout RG** (2005) The kinematics of feeding and drinking in palaeognathous birds in relation to cranial morphology. *J Exp Biol* **208**, 3395–3407.

**Hall BK** (1967) The distribution and fate of the adventitious cartilage in the skull of the eastern rosella, *Platycerus eximius* (Aves: Psittaciformes). *Aust J Zool* **15**, 685–698.

**Hall BK** (1968) The fate of adventitious and embryonic articular cartilage in the skull of the common fowl, *Gallus domesticus* (Aves: Phasianidae). *Aust J Zool* **16**, 795–805.

**Hall BK** (1972) Immobilization and cartilage transformation into bone in the embryonic chick. *Anat Rec* **173**, 391–403.

**Hall B** (1979) Selective proliferation and accumulation of chondroprogenitor cells as the mode of action of biomechanical factors during secondary chondrogenesis. *Teratology* **20**, 81–91.

**Hall BK** (1986) The role of movement and tissue interactions in the development and growth of bone and secondary cartilage in the clavicle of the embryonic chick. *J Embryol Exp Morphol* **93**, 133–152.

**Hall BK** (2000) *The Evolution of the Neural Crest in Vertebrates*, pp. 101–113. London: Portland Press.

**Hall BK** (2015) *Bones and Cartilage: Developmental and Evolutionary Skeletal Biology*. San Diego, CA: Elsevier Science and Technology Book.

**Herrel A, Aerts P, De Vree F** (2000) Cranial kinesis in geckoes: functional implications. *J Exp Biol* **203**, 1415–1423.

**Hieronymus TL, Witmer LM** (2010) Homology and evolution of avian compound rhamphothecae. *Auk* **127**, 590–604.

**Hoemann CD, Lafantaisie-Favreau C-H, Lascau-Coman V, et al.** (2012) The cartilage-bone interface. *J Knee Surg* **25**, 085.

**Holliday CM, Gardner NM, Paesani SM, Douthitt M, Ratliff JL** (2010) Microanatomy of the mandibular symphysis in lizards: patterns in fiber orientation and Meckel's cartilage and their significance in cranial evolution. *Anat Rec* **293**, 1350–1359.

**Holliday CM, Witmer LM** (2008) Cranial kinesis in dinosaurs: intracranial joints, protractor muscles, and their significance for cranial evolution and function in diapsids. *J Vertebr Paleontol* **28**, 1073–1088.

**Horner JR, Padian K, de Ricqlès A** (2001) Comparative osteohistology of some embryonic and perinatal archosaurs: developmental and behavioral implications for dinosaurs. *Paleobiology* **27**, 39–58.

**Huang Y, Li N, Burt D, et al.** (2008) Genomic research and applications in the duck (*Anas platyrhynchos*). *Worlds Poult Sci J* **64**, 329–341.

**Huber M, Trattnig S, Lintner F** (2000) Anatomy, biochemistry, and physiology of articular cartilage. *Invest Radiol* **35**, 573–580.

**Huysseune A, Verraes W** (1986) Chondroid bone on the upper pharyngeal jaws and neurocranial base in the adult fish *Astatotilapia elegans*. *Am J Anat* **177**, 527–535.

**Irwin C, Ferguson M** (1986) Fracture repair of reptilian dermal bones: can reptiles form secondary cartilage? *J Anat* **146**, 53–64.

**Iwaniuk AN, Olson SL, James HF** (2009) Extraordinary cranial specialization in a new genus of extinct duck (Aves: Anseriformes) from Kauai, Hawaiian Islands. *Zootaxa* **2296**, 47–67.

**Jollie MT** (1957) The head skeleton of the chicken and remarks on the anatomy of this region in other birds. *J Morphol* **100**, 389–436.

© 2016 Anatomical Society

**Khan I, Redman S, Williams R, et al.** (2007) The development of synovial joints. *Curr Top Dev Biol* **79**, 1–36.

**Le Douarin NM** (2004) The avian embryo as a model to study the development of the neural crest: a long and still ongoing story. *Mech Dev* **121**, 1089–1102.

**Lengelé B** (1997) *Le Tissu Chondroïde Dans le Squelette en Croissance*, p. 224. Brussels: Université Catholique de Louvain.

**Lengelé B, Dhem A, Schowing J** (1990) Early development of the primitive cranial vault in the chick embryo. *J Craniofac Genet Dev Biol* **10**, 103–112.

**Lengelé B, Schowing J, Dhem A** (1996) Embryonic origin and fate of chondroid tissue and secondary cartilages in the avian skull. *Anat Rec* **246**, 377–393.

**Livezey BC** (1997) A phylogenetic analysis of basal Anseriformes, the fossil Presbyornis, and the interordinal relationships of waterfowl. *Zool J Linn Soc* **121**, 361–428.

**Madry H, van Dijk CN, Mueller-Gerbl M** (2010) The basic science of the subchondral bone. *Knee Surg Sports Traumatol Arthrosc* **18**, 419–433.

**Marieb EN, Hoehn KN** (2015) *Human Anatomy & Physiology, Global Edition*. New York: Pearson Education Limited.

**Murray PDF** (1963) Adventitious (secondary) cartilage in the chick embryo: and the development of certain bones and articulations in the chick skull. *Aust J Zool* **11**, 368–430.

**Murray P, Smiles M** (1965) Factors in the evocation of adventitious (secondary) cartilage in the chick embryo. *Aust J Zool* **13**, 351–381.

**Myers ER, Mow VC** (1983) Biomechanics of cartilage and its response to biomechanical stimuli. In: *Cartilage, Structure, Junction, and Biochemistry*. (ed. Hall B), pp. 313–337. New York: Academic Press.

**Novacek MJ** (1993) Patterns of diversity in the mammalian skull. *Skull* **2**, 438–545.

**O'Connor PM** (2009) Evolution of archosaurian body plans: skeletal adaptations of an air sac-based breathing apparatus in birds and other archosaurs. *J Exp Zool A Ecol Genet Physiol* **311**, 629–646.

**Olsen AM** (2015) Exceptional avian herbivores: multiple transitions toward herbivory in the bird order Anseriformes and its correlation with body mass. *Ecol Evol* **5**, 5016–5032.

**Parker WK** (1869) On the structure and development of the skull of the common fowl (*Gallus domesticus*). *Philos Trans R Soc Lond* **159**, 755–807.

**Payne SL, Holliday CM, Vickaryous MK** (2011) An osteological and histological investigation of cranial joints in geckos. *Anat Rec* **294**, 399–405.

**Persson M** (1973) Structure and growth of facial sutures: histologic, microangiographic and autoradiographic studies in rats and a histologic study in man. *Odontologisk Revy* **24**(Suppl. 26), 1–146.

**Persson M** (1983) The role of movements in the development of sutural and diarthrodial joints tested by long-term paralysis of chick embryos. *J Anat* **137**, 591.

**Pritchard J, Scott J, Girgis F** (1956) The structure and development of cranial and facial sutures. *J Anat* **90**, 73–86.

**Prum RO, Berv JS, Dornburg A, et al.** (2015) A comprehensive phylogeny of birds (Aves) using targeted next-generation DNA sequencing. *Nature* **526**, 569–573.

**Rafferty KL, Herring SW** (1999) Craniofacial sutures: morphology, growth, and *in vivo* masticatory strains. *J Morphol* **242**, 167–179.

**Rieppel O** (1980) The evolution of the ophidian feeding system. *Zool Jahrb Anat* **103**, 551–564.

**Rieppel O** (1993) Patterns of diversity in the reptilian skull. In: *The Skull, Volume 2: Patterns of Structural and Systematic Diversity*. (eds Hanken J, Hall BK), pp. 344–390. Chicago: The University of Chicago Press.

**Sasano Y, Furusawa M, Ohtani H, et al.** (1996) Chondrocytes synthesize type I collagen and accumulate the protein in the matrix during development of rat tibial articular cartilage. *Anat Embryol* **194**, 247–252.

**Smith KK** (1993) The form of the feeding apparatus in terrestrial vertebrates: studies of adaptation and constraint. *Skull* **3**, 150–196.

**Solem RC, Eames BF, Tokita M, et al.** (2011) Mesenchymal and mechanical mechanisms of secondary cartilage induction. *Dev Biol* **356**, 28–39.

**Taylor L, Hall B, Miyake T, et al.** (1994) Ectopic ossicles associated with metacercariae of *Apophallus brevis* (Trematoda) in yellow perch, *Perca ftavescens* (Teleostei): development and identification of hone and chondroid bone. *Anat Embryol* **190**, 29–46.

**Thilander B, Carlsson GE, Ingervall B** (1976) Postnatal development of the human temporomandibular joint I. A histological study. *Acta Odontol Scand* **34**, 117–126.

**Tillmann B** (1973) Zur Lokalisation von degenerativen Veränderungen am Femurkopf bei der Coxarthrose. *Z Orthop* **111**, 23–27.

**Tucker AS, Lumsden A** (2004) Neural crest cells provide species-specific patterning information in the developing branchial skeleton. *Evol Dev* **6**, 32–40.

**Van der Meij MA, Bout RG** (2008) The relationship between shape of the skull and bite force in finches. *J Exp Biol* **211**, 1668–1680.

**Versluys J** (1912) Das Streptostylie-Problem und die Bewegung im Schädel bei Sauropsida. *Zoologische Jahrbücher, Abteilung für Anatomie und Ontogenie der Tiere* **2**(Suppl. 15), 545–716.

**Vickaryous MK, Hall BK** (2008) Development of the dermal skeleton in *Alligator mississippiensis* (Archosauria, Crocodylia) with comments on the homology of osteoderms. *J Morphol* **269**, 398–422.

**Weinmann J, Sicher H** (1964) *Histology of the Temporomandibular Joint*, pp. 71–101. Springfield, IL: CC Thomas.

**Witten PE, Hall BK** (2003) Seasonal changes in the lower jaw skeleton in male Atlantic salmon (*Salmo salar* L.): remodelling and regression of the kype after spawning. *J Anat* **203**, 435–450.

**Wolff J** (1870) Über die innere Architecture des Knochen und ihre Bedeutung für die Frage vom Knochenwachstum. *Virchow's Arch* **50**, 389.

**Wolff J** (1892) Das gesetz der transformation der knochen. *Dtsch Med Wochenschr* **19**, 1222–1224.

**Zusi RL** (1984) A functional and evolutionary analysis of rhynchokinesis in birds. *Smithson Contrib Zool* **395**, 1–40.

**Zusi RL** (1993) Patterns of diversity in the avian skull. In: *The Skull: Patterns of Structural and Systematic Diversity*. (eds Hanken J, Hall B), pp. 391–437. Chicago, IL: The University of Chicago Press.

**Zweers GA** (1973) Structure, movement, and myography of the feeding apparatus of the mallard (*Anas platyrhynchos* L.): a study in functional anatomy. *Nether J Zool* **24**, 323–467.

## Supporting Information

Additional Supporting Information may be found in the online version of this article:

**Fig. S1.** Osteology and horizontal sections of the craniofacial hinge of adult mallard ducks.

© 2016 Anatomical Society