Journal of Pediatric Genetics 1 (2012) 25–31
DOI 10.3233/PGE-2012-006
IOS Press

Fused teeth, macrodontia and increased caries are characteristic features of neurofibromatosis type 1 patients with *NF1* gene microdeletion

Ryosuke Kobayashi[a,*], Kensuke Matsune[b] and Hirofumi Ohashi[c]
[a]*Department of Pediatric Dentistry, Nihon University Graduate School of Dentistry at Matsudo, Chiba, Japan*
[b]*Department of Pediatric Dentistry, Nihon University School of Dentistry at Matsudo, Chiba, Japan*
[c]*Division of Medical Genetics, Saitama Children's Medical Center, Saitama, Japan*

Received 6 December 2010
Accepted 25 December 2010

Abstract. Neurofibromatosis type 1 (NF1) is the most common genetic condition caused by *NF1* gene alteration. A 1.5 Mb submicroscopic deletion encompassing the entire *NF1* gene, is known to be responsible for approximately 5% of NF1 cases. Patients with *NF1* deletion, compared to those with *NF1* mutation tend to exhibit more severe phenotypes. To know the possible differences in oral/dental features between *NF1* deletion and *NF1* mutation patients, we examined four patients with *NF1* deletion and three with *NF1* mutation to compare their oral manifestations. Fused teeth in the mandibular anterior region were found only in the patients with deletion (2/4). Macrodontia was noted in all four patients with an *NF1* deletion. Although macrodontia was also found in one patient with a mutation, it was relatively mild compared to the deletion patients. Dental caries were observed in both *NF1* deletion (4/4) and mutation (2/3) patients. However, patients with *NF1* deletions showed more apparently severe caries (average number of dental caries 12.8) than those with *NF1* mutation (average number 5.5). Other features also noted in patients with both deletions and mutations were high-arched palate, hypodontia and malocclusion. Our study might suggest that fused teeth, macrodontia and increased dental caries are distinctive manifestations of *NF1* deletion. Providing comprehensive dental care from early infancy would be very important to prevent dental caries especially in patients with *NF1* deletion.

Keywords: Neurofibromatosis type 1, *NF1* gene deletion, fused teeth, macrodontia, caries

1. Introduction

Neurofibromatosis type 1 (NF1) is the most common autosomal dominant genetic condition caused by *NF1* gene alteration. It affects 1 in 3,000 individuals and is characterized by multiple café au lait spots, neurofibromas, and axillary/inguinal freckling [1,2]. Other features associated with the disease include iris Lisch nodules, optic glioma, skeletal dysplasia, plexiform neurofibromas, and mental retardation/learning disability. Although tumors in the oral and facial areas have been frequently reported in association with NF1, the dental manifestations have not been fully characterized so far. To our knowledge, impacted teeth, displaced teeth, missing teeth, supernumerary teeth, increased dental caries, early primary tooth eruption, malocclusion, and periapical cemental dysplasia (in adult female patients) have been reported in patients with NF1 [3–7].

A submicroscopic deletion which is usually 1.5 Mb in size and involves the entire *NF1* gene and more than 20 genes adjacent to *NF1* gene is known to be responsible for approximately 5% of NF1 cases [8,9]. Patients

*Corresponding author: Ryosuke Kobayashi, Department of Pediatric Dentistry, Nihon University Graduate School of Dentistry at Matsudo, 2-870-1 Sakaecho-Nishi, Matsudo, Chiba 271-8587, Japan. Tel.: +81 47 360 9430; Fax: +81 47 360 9429; E-mail: mary07007@g.nihon-u.ac.jp.

2146-4596/12/$27.50 © 2012 – IOS Press and the authors. All rights reserved

This document was downloaded for personal use only. Unauthorized distribution is strictly prohibited.

with *NF1* deletions, compared to those with *NF1* mutations, tend to exhibit characteristic phenotypes such as facial dysmorphism, mental retardation and learning disability, plexiform neurofibromas, skeletal anomalies and cardiovascular defects, likely due to the involvement of contiguous genes around *NF1* [8,10–14]. However, the possible differences in oral/dental features between *NF1* deletion and *NF1* mutation patients have not been investigated in detail. We examined four patients with *NF1* deletion and three with *NF1* mutation to compare their oral manifestations.

2. Materials and methods

2.1. Patients

A total of seven patients were examined at Saitama Children's Medical Center; four (one male, three females; aged 5–12 yr) were identified as having a microdeletion including the *NF1* gene, and three (two males, one female; aged 5-12 yr) were identified as having a mutation of the *NF1* gene. Microdeletions were analyzed by fluorescence in situ hybridization analysis of metaphase chromosomes from peripheral blood, using a total of seven bacterial artificial chromosome clones comprising the bacterial artificial chromosome clone including *NF1* (RP11-876L22) and six neighboring clones (RP11-96L17, RP11-946G8, RP11-525H19, RP11-278E4, RP11-164M10, and RP11-55J8). The results showed that a deletion of approximately 1.5 Mb was detected in all four patients. Mutation analysis using genomic DNA extracted from peripheral blood was performed by means of polymerase chain reaction and direct sequencing of the coding regions for all exons. The results identified a splice mutation (c.1185+1G<A) in patient 5 and nonsense mutations (c.574C>T and c.3986C>G, respectively) in patients 6 and 7. Clinical manifestations are shown in Table 1. Neurofibromas of the oral and maxillofacial region were not present in any patient. This study protocol was approved by the Ethics Committee of Saitama Children's Medical Center and proper informed consents were obtained from the patients and their legal guardians of the patients.

2.2. Examination of craniofacial and oral condition by dental casts and radiographs

Palate morphology, occlusion, tooth size, and dental arch were evaluated by intraoral examination and dental cast studies. The relationship of the skeletal and dental structures and congenital hypodontia were evaluated on lateral cephalograms and orthopantomographs. The dimensions of the crown and dental arch were measured using a caliper with a resolution accuracy of 0.01 mm. Lateral cephalometric analysis was performed based on the method developed by Iizuka and Ishikawa [15] (Fig. 1). All data in this study (tooth size, dental arch form size, cephalometric findings) were compared with normal values in Japanese individuals.

Table 1
Clinical manifestations of the seven patients with neurofibromatosis type 1

	Deletion				Mutation		
Patients	1	2	3	4	5	6	7
Gender	F	M	F	F	M	F	M
Age (Years)	12	5	5	6	12	5	6
Height (SD)	−0.68	1.02	−0.41	0.57	−1.02	−1.50	−0.08
Occipito-frontal circumference	−1.27	1.90	0.31	0.50	0.00	0.29	2.80
Mental retardation	−	+	+	−	−	−	−
Facial dysmorphism	+	+	+	+	−	+	−
Café au leit spots	+	+	+	+	+	+	+
Neurofibroma	+	+	−	−	−	+	−
Plexifrom neurofibroma	−	−	−	−	−	+	−
Optic glioma	−	−	−	−	+	−	−
Brain MRI	UBO	UBO	UBO	UBO	UBO astrocytoma	UBO	UBO
Others		Calcifying epithelioma	VUR, urachal cyst	Preauricular tag			Pes planovalgus

This document was downloaded for personal use only. Unauthorized distribution is strictly prohibited.

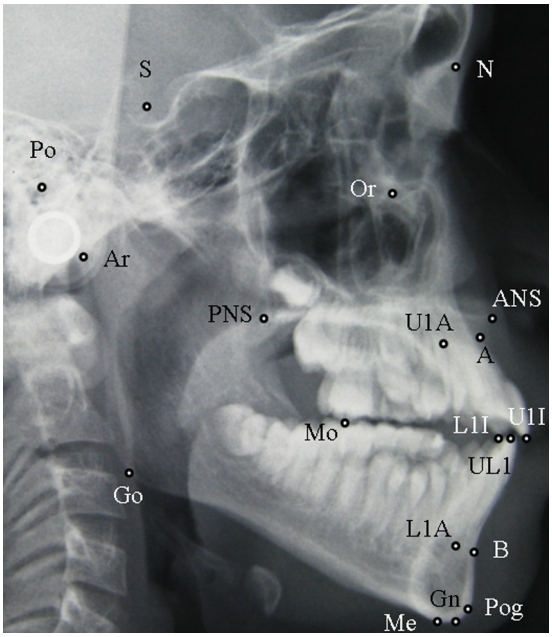

Fig. 1. Landmark points, angles and lines used in cephalometric analysis. Landmarks: N = Nasion; Or = Orbitale; S = Sella turcica; Po = Porion; Ar = Articulare; Go = Gonion; Me = Menton; Gn = Gnathion; Pog = Pogonion; B = B-point; A = A-point; ANS = Anterior nasal spine; Mo = Molar occlusion; U1A = Upper central incisor root apex; U1I = Upper central incisor edge; L1A = Lower central incisor root apex; L1I = Lower central incisor edge; UL1I = Middle of U1I and L1I. Angles: Convexity = N-A line to the A-Pog line; A-B plane = N-Pog line to the A-B line; SNA = S-N line to the N-A line; SNB = S-N line to the N-B line; Facial angle = Po-Or line to the N-Pog line; SNP = S-N line to the N-Pog line; Y axis = Po-Or line to the S-Gn line; SN-S.Gn = S-N line to the S-Gn line; Mandibular plane = Po-Or line to the Me-the lower border of the mandible line; Gonial angle = Ar-the posterior border of the ramus of the mandible line to the Me-the lower border of the mandible line; GZN = S-N line to the Ar-the posterior border of the ramus of the mandible line; FH to SN = Po-Or line to the S-N line; U-1 to FH plane = U1I-U1A line to the Po-Or line; U-1 to SN plane = U1I-U1A line to the S-N line; L-1 to mandibular = L1I-L1A line to the Me-the lower border of the mandible; Interincisal = U1A-U1I line to the L1A-L1I line; Occlusal plane = Po-Or line to the Mo-UL1I line.

3. Results

Oral manifestations noted in seven patients are summarized in Table 2. The prevalence of high-arched palate was high in both the *NF1* deletion and mutation patients (deletion 3/4, mutation 2/3). Dental caries occurred more frequently in all four patients with *NF1* deletion and two of the three patients with *NF1* mutation, but tooth decay was more severe in the patients with deletion compared with those with mutation, with an average of 12.8 affected teeth [10–16] in the former and 5.5 teeth (4 and 7) in the latter type. While mutation type patients showed caries only in the posterior teeth with less dental plaque, deletion type patients had caries both in the anterior and posterior teeth and also had more dental plaque as well (Fig. 2). Fused teeth were present in the mandibular anterior region in two out of four of the patients with *NF1* deletion (Patients 2 and 3). Panoramic radiographs showed congenital hypodontia of the permanent teeth in both these patients (Patient 2: bilateral second mandibular premolars and left mandibular first premolar; Patient 3: bilateral maxillary and mandibular second premolars and left mandibular incisor), with hypodontia of the succeeding permanent teeth for the fused teeth in patient 3. In the patients with *NF1* mutation, hypodontia (bilateral maxillary second premolars) was present in one out of three patients (Fig. 3). In terms of tooth size, macrodontia was present in all four *NF1* deletion patients and in one out of three mutation patients. The number of teeth greater than 2 SD larger than normal averaged 7.8 in patients with *NF1* deletion (4–13 teeth). Only three teeth exhibited macrodontia in the single *NF1* mutation patient (Table 3). Malocclusion was present in one out of four patients with *NF1* deletion (Patient 1: crowding) and one of the patients with *NF1* mutation (Patient 6: open bite). The dental crowding in patient 1 (deletion type) was associated with the patient's narrow dental arch and severe macrodontia (Table 4). In patient 6 (mutation type), it was judged to be caused by tongue thrusting. Lateral cephalometric analysis showed a tendency toward a dolichofacial pattern in the patients with *NF1* deletion with maxillary protrusion, and a tendency toward labioclination of the maxillary central incisors in those with *NF1* mutation (Table 5).

4. Discussion

The intraoral characteristics seen commonly in both deletion and mutation patients studied were high-arched palate, hypodontia, macrodontia, malocclusion and increased dental caries. Fused teeth were found only in the patients with deletion. Fusion of teeth is a relatively rare dental anomaly observed in the general population at a frequency of 4.10% [16]. Therefore, the fact that we observed fused teeth in two of four patients with *NF1* deletion suggests that it may be a characteristic feature of *NF1* deletion. It is noteworthy that both patients (Patients 2 and 3) who exhibited hypodontia had fused teeth. Macrodontia was noted in all four patients with *NF1* deletion. Macrodontia is a rare dental anomaly which may occur in isolation or

This document was downloaded for personal use only. Unauthorized distribution is strictly prohibited.

Table 2
Oral anomalies in seven patients

	Deletion				Mutation			Total	
Patient	1	2	3	4	5	6	7	Deletion	Mutation
High-arched palate	+	+	−	+	+	−	+	3/4	2/3
Fused teeth	−	+	+	−	−	−	−	2/4	0/3
Hypodontia	−	+	+	−	−	−	+	2/4	1/3
Macrodontia	+	+	+	+	−	+	−	4/4	1/3
Dental caries	+ (10/23)	+ (10/19)	+ (15/19)	+ (16/22)	+ (7/22)	+ (4/24)	− (0/22)	4/4	2/3
Malocclusion	+ Crowding, narrow dental arch	−	−	−	−	+ Open bite	−	1/4	1/4

Parenthesis represents the number of dental caries/the total of present teeth.

Fig. 2. Oral photographs of seven patients. Patients 1–4: deletion, patients 5–7: mutation.

as a component of syndromes such as KBG syndrome, "polydactyly, postaxial, with dental and vertebral anomalies", XXY and XYY male, and hemihyperplasia [17–21]. However, to our knowledge, macrodontia has not been described previously in NF1. Although macrodontia was also found in one patient with a mutation, it was relatively mild compared to the deletion patients, with only three large teeth having a width that exceeded 2 SD. Thus, macrodontia can be considered a distinctive feature of patients with *NF1* deletion. Dental caries was observed in both *NF1* deletion (4/4) and mutation (2/3) patients. However, patients with *NF1* deletion showed apparently severe caries (average number of dental caries 12.8) than those with *NF1* mutation (average number 5.5). Tucker et al. [5], on the basis of a questionnaire study of 37 families of children with NF1, reported that individuals with NF1 had a significantly higher average number of dental caries (8.1 ± 6.6) than their siblings without NF1 (5.5 ± 5.8). Unfortunately, no genetic investigation of the *NF1* gene was performed in their study. The authors mentioned some possibilities to account for increased dental caries in NF1 patients, including vitamin D deficiency, reduced bone mineralization (osteopenia or osteoporosis), and misregulation of various growth factor receptors. In addition, the author proposed that impaired mental capacity in NF1 patients might be a risk factor for excessive caries due to poor oral care. Our deletion patients tended to show poor oral hygiene indicated by the high plaque levels on oral examination. This could be explained by the reduced ability to perform dental care due to mental retardation. Nonetheless, the cause is still unknown and further studies are necessary. Malocclusion was not frequently seen in the patients examined. Patient 1 with

This document was downloaded for personal use only. Unauthorized distribution is strictly prohibited.

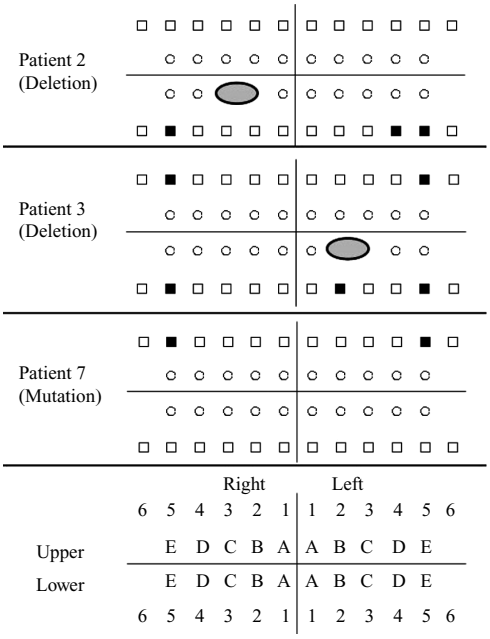

Fig. 3. Fused primary teeth and missing permanent teeth noted in patients 2, 3 with NF1 deletion, and missing permanent teeth observed in patient 7 with NF1 mutation. ⬭, Fused primary teeth. ■, Congenitally missing permanent tooth.

NF1 deletion had crowding, and patient 6 exhibited open bite. The former might be associated with macrodontia and a narrow dental arch, while the latter was likely due to tongue thrusting. Lateral cephalometric analysis showed a tendency toward a dolichofacial pattern in the patients with *NF1* deletion with maxillary protrusion, and a tendency toward labioclination of the maxillary central incisors in those with *NF1* mutation.

Grisart et al. [22] reported a family with microduplication of the identical *NF1* microdeletion region, in which patients showed moderate to borderline normal mental impairment, early onset of baldness and dental enamel hypoplasia. The author hypothesized that gene(s) responsible for dental enamel hypoplasia might reside in the deleted interval, although no candidate gene has been identified.

In conclusion, we evaluated seven NF1 patients, four with *NF1* deletion and three with *NF1* mutation, and found that fused teeth, macrodontia and excessive dental caries are distinctive manifestations of *NF1* deletion. Providing comprehensive dental care from early infancy would be very important to prevent dental caries especially in patients with *NF1* deletion.

Table 3
Size of the teeth in seven patients

Patient	Deletion								Mutation					
	1		2		3		4		5		6		7	
	Right	Left	Right	Left	Right	Left	Right	Left	Right	Left	Right	Left	Right	Left
Primary teeth														
Maxillary														
Central incisor			2.05	2.00	2.97	1.43	−0.41	−0.57			0.30	−0.51	0.45	−0.08
Lateral incisor			1.37	1.40	1.22	1.08	0.46	−1.51			1.22	1.27	−0.37	−0.29
Cuspid			2.28	2.19	2.30	2.82	−0.21	−0.67			0.12	0.15	−0.93	−0.93
First molar			1.71	1.73	3.03	1.78	1.43	1.65			2.38	2.13	0.83	0.15
Second molar	2.16		1.29	1.12	2.30	2.78	0.48	−0.62	−0.78		1.24	1.00	−0.59	0.32
Mandibular														
Central incisor			0.67	0.93	2.14	2.14	0.55	−0.55						
Lateral incisor				1.26	1.76		2.00	2.31			0.21	0.86	−0.82	−0.97
Cuspid				2.44	0.71		−0.43	0.36			0.43	2.75	0.15	0.44
First molar			1.77	1.81	1.80	2.24	2.27	2.24		0.19	0.36	1.27	−1.56	−1.23
Second molar	1.33	1.13	0.71	0.71	1.24	1.78	−1.40	−1.67	−0.69	−0.61	−0.38	−0.55	0.94	0.78
Permanent teeth														
Maxillary														
Central incisor	4.78	4.39							−0.59	−0.74				
Lateral incisor	3.27	2.78							0.65	0.39				
Cuspid		3.77												
First premolar		3.69												
First molar	1.20	1.53							−2.59	−1.61	−0.57			
Mandibular														
Central incisor	4.03	4.19							−0.30	−0.40	1.14	1.33	−0.12	1.00
Lateral incisor	3.10	4.00							−0.33	0.09				
Cuspid	3.03	3.05												
First molar	1.82	1.52							−1.78	−0.98				

Tooth size represents the distance from the medial to distal. Unit, SD.

This document was downloaded for personal use only. Unauthorized distribution is strictly prohibited.

Table 4
Dental arch measurements in seven patients

	Deletion				Mutation		
Patient	1	2	3	4	5	6	7
Maxillary							
W_C		2.04	2.11	−1.09		0.15	−0.42
W_E		0.32	2.27	−2.10		−1.22	−1.73
L_{AE}		1.27	0.76	−0.37		0.77	0.25
W_3	No data				No data		
W_6	−2.19				1.77		
L_{16}	2.37				0.66		
Mandibular							
W_C		No data	No data	0.48		2.69	0.88
W_E		0.40	−0.12	0.34		0.53	−0.96
L_{AE}		−0.36	−0.68	−2.18		No data	No data
W_3	No data				No data		
W_6	−2.78				1.95		
L_{16}	2.07				1.51		

The W_C, W_3, W_E, W_6 represents the distance between the primary cuspids, the cuspids, the primary second molars, the first molars. The L_{AE} represents the length from the distal surface of the primary second molars to the primary incisors central point. The L_{16} represents the length from the mesial surface of the first molars to the incisors central point. Unit, SD.

Table 5
Lateral cephalometric analysis in seven patients

	Deletion				Mutation		
Patient	1	2	3	4	5	6	7
Skeletal							
Convexity	−0.83	2.35	5.63	3.14	−0.61	1.16	−1.49
A-B plane	1.53	−0.31	−0.52	−0.46	1.53	−1.98	1.68
SNA	−0.71	−0.32	2.74	1.49	1.24	−1.56	−0.49
SNB	−0.38	−1.02	1.29	1.02	1.74	−3.55	−0.18
Facial angle	0.14	−1.54	−1.08	−0.77	3.52	1.23	0.23
SNP	−0.74	−1.27	0.06	−0.16	1.41	−2.36	2.04
Y-axis	0.80	1.77	2.06	2.19	−2.38	−2.66	1.58
SN-S·Gn	1.89	1.82	1.09	1.40	−0.94	1.40	0.78
Mandibular plane	2.51	2.65	1.62	2.87	−2.91	−1.76	0.55
Gonial angle	0.39	0.96	−1.32	2.32	−1.12	−0.34	−0.11
GZN	1.85	0.61	1.51	0.39	0.63	1.44	0.13
FH to SN	0.96	−0.21	−1.56	−0.90	1.31	3.94	−1.22
Denture							
U-1 to FH plane	1.18	−0.31	0.07	−3.41	3.84	4.66	1.22
U-1 to SN plane	0.77	−0.34	0.66	1.30	3.14	2.10	1.87
L-1 to mandibular	−0.47	0.80	1.65	−1.85	−0.64	2.04	0.09
Interincisal	−1.36	−1.09	−1.41	−0.86	−1.21	−3.50	−1.33
Occlusal plane	−0.06	1.00	2.02	0.88	−2.64	−1.69	2.04

Unit, SD.

Acknowledgement

The authors are grateful to Prof. Takahide Maeda for his helpful advice. We also thank to Dr. Kenji Shimizu and Dr. Yasuo Takahashi for their invaluable assistance. This study was funded in part by a Grant for the Support of Projects for Strategic Research at Private Universities by the Ministry of Education, Culture, Sports, Science and Technology (MEXT; 2008–2012), and by a grant from the Ministry of Health, Labor and Welfare, Japan.

This document was downloaded for personal use only. Unauthorized distribution is strictly prohibited.

References

[1] Friedman JM. Epidemiology of neurofibromatosis type 1. Am J Med Genet 1999; 89: 1–6.

[2] Crawford AH, Schorry EK. Neurofibromatosis in children: the role of the orthopaedist. J Am Acad Orthop Surg 1999; 7: 217–30.

[3] Shapiro SD, Abramovitch K, Van Dis ML, Skoczylas LJ, Langlais RP, Jorgenson RJ, et al. Neurofibromatosis: oral and radiographic manifestations. Oral Surg Oral Med Oral Pathol 1984; 58: 493–8.

[4] Friedrich RE, Giese M, Schmelzle R, Mautner VF, Scheuer HA. Jaw malformations plus displacement and numerical aberrations of teeth in neurofibromatosis type 1: a descriptive analysis of 48 patients based on panoramic radiographs and oral findings. J Craniomaxillofac Surg 2003; 31: 1–9.

[5] Tucker T, Birch P, Savoy DM, Friedman JM. Increased dental caries in people with neurofibromatosis 1. Clin Genet 2007; 72: 524–27.

[6] Lammert M, Friedrich RE, Friedman JM, Mautner VF, Tucker T. Early primary tooth eruption in neurofibromatosis 1 individuals. Eur J Oral Sci 2007; 115: 425–26.

[7] Visnapuu V, Peltonen S, Ellilä T, Kerosuo E, Väänänen K, Happonen RP, et al. Periapical cemental dysplasia is common in women with NF1. Eur J Med Genet 2007; 50: 274–80.

[8] Venturin M, Guarnieri P, Natacci F, Stabile M, Tenconi R, Clementi M, et al. Mental retardation and cardiovascular malformations in NF1 microdeleted patients point to candidate genes in 17q11.2. J Med Genet 2004; 41: 35–41.

[9] Kluwe L, Siebert R, Gesk S, Friedrich RE, Tinschert S, Kehrer-Sawatzki H, et al. Screening 500 unselected neurofibromatosis 1 patients for deletions of the NF1 gene. Hum Mutat 2004; 23: 111–6.

[10] Kayes LM, Burke W, Riccardi VM, Bennett R, Ehrlish P, Rubenstein A, et al. Deletions spanning the neurofibromatosis 1 gene: identification and phenotype of five patients. Am J Hum Genet 1994; 54: 424–36.

[11] Cnossen MH, van der Est MN, Breuning MH, van Asperen CJ, Breslau-Siderius EJ, van der Ploeg AT, et al. Deletions spanning the neurofibromatosis type 1 gene: implications for genotype-phenotype correlations in neurofibromatosis type 1? Hum Mutat 1997; 9: 458–64.

[12] Lepping KA, Kaplan P, Viskochil D, Weaver M, Ortenberg J, Stepheens K. Familial neurofibromatosis 1 microdeletions: cosegregation with distinct facial phenotype and early onset of cutaneous neurofibromata. Am J Med Genet 1997; 73: 197–204.

[13] Tonsgard JH, Yelavarthi KK, Cushner S, Short MP, Lindgren V. Do NF1 gene deletions result in a characteristic phenotype? Am J Med Genet 1997; 73: 80–6.

[14] Mautner VF, Kluwe L, Friedrich RE, Roehl AC, Bammert S, Högel J, et al. Clinical characterisation of 29 neurofibromatosis type-1 patients with molecularly ascertained 1.4 Mb type-1 NF1 deletions. J Med Genet 2010; 47: 623–30.

[15] Iizuka T, Ishikawa F. Normal standards for various cephalometric analysis in Japanese adults. Nippon Kyousei Shika Gakkai Zasshi 1957; 16: 4–12 (in Japanese).

[16] Shi S, Machida Y, Yonezu T. The prevalence of fused teeth in Japanese and Chinese children. Shika Gakuho 1993; 93: 631–8 (in Japanese).

[17] Herrmann J, Pallister PD, Tiddy W, Opitz JM. The KBG syndrome-a syndrome of short stature, characteristic facies, mental retardation, macrodontia and skeletal anomalies. Birth Defects Orig Artic Ser 1975; 11: 7–18.

[18] Rogers JG, Levin LS, Dorst JP, Temtamy SA. A postaxial polydactyly-dental-vertebral syndrome. J Pediatr 1977; 90: 230–35.

[19] Alvesalo L, Portin P. 47, XXY males: sex chromosomes and tooth size. Am J Hum Genet 1980; 32: 955–9.

[20] Alvesalo L, Osborne RH, Kari M. The 47,XYY male, Y chromosome, and tooth size. Am J Hum Genet 1975; 27: 53–61.

[21] Alvesalo L, Kari M. Sizes of deciduous teeth in 47, XYY males. Am J Hum Genet 1977; 29: 486–9.

[22] Grisart B, Rack K, Vidrequin S, Hilbert P, Deltenre P, Verellen-Dumoulin C, et al. NF1 microduplication first clinical report: association with mild mental retardation, early onset of baldness and dental enamel hypoplasia? Eur J Hum Genet 2008; 16: 305–11.

This document was downloaded for personal use only. Unauthorized distribution is strictly prohibited.