Original Article

Cone Beam Computed Tomographic Assessment of Bifid Mandibular Condyle

Leila Khojastepour[1], Shirin Kolahi[2], Nazi Panahi[2], Abdolaziz Haghnegahdar[3]✉

[1]Professor, Department of Oral and Maxillofacial Radiology, School of Dentistry, Shiraz University of Medical Sciences, Shiraz, Iran
[2]Postgraduate Student, Department of Oral and Maxillofacial Radiology, School of Dentistry, Shiraz University of Medical Sciences, Shiraz, Iran
[3]Assistant Professor, Department of Oral and Maxillofacial Radiology, School of Dentistry, Shiraz University of Medical Sciences, Shiraz, Iran

Abstract
Objectives: Differential diagnosis of bifid mandibular condyle (BMC) is important, since it may play a role in temporomandibular joint (TMJ) dysfunctions and joint symptoms. In addition, radiographic appearance of BMC may mimic tumors and/or fractures. The aim of this study was to evaluate the prevalence and orientation of BMC based on cone beam computed tomography (CBCT) scans.
Materials and Methods: This cross-sectional study was performed on CBCT scans of paranasal sinuses of 425 patients. In a designated NNT station, all CBCT scans were evaluated in the axial, coronal and sagittal planes to find the frequency of BMC. The condylar head horizontal angulations were also determined in the transverse plane. T-test was used to compare the frequency of BMC between the left and right sides and between males and females.
Results: Totally, 309 patients with acceptable visibility of condyles on CBCT scans were entered in the study consisting of 170 (55%) females and 139 (45%) males with a mean age of 39.43±9.7 years. The BMC was detected in 14 cases (4.53%). Differences between males and females, sides and horizontal angulations of condyle of normal and BMC cases were not significant.
Conclusion: The prevalence of BMC in the studied population was 4.53%. No significant difference was observed between males and females, sides or horizontal angulations of the involved and uninvolved condyles.
Keywords: Mandibular Condyle; Prevalence; Cone-Beam Computed Tomography
Journal of Dentistry, Tehran University of Medical Sciences, Tehran, Iran (2015; Vol. 12, No. 12)

✉ Corresponding author:
A. Haghnegahdar, Department of Oral and Maxillofacial Radiology, School of Dentistry, Shiraz University of Medical Sciences, Shiraz, Iran

ahagh@sums.ac.ir

Received: 17 June 2015
Accepted: 4 November 2015

INTRODUCTION

Bifid mandibular condyle is an uncommon anomaly with an unclear origin, which was first described in 1941 by Hardlicka [1]. The condylar head is divided into two partially or completely separated lobes by a rift or a deep groove. The separating groove can be oriented anteroposteriorly or mediolaterally to determine the spatial relationship of the heads [2]. Several theories exist about the origin of BMC, mainly suggesting traumatic or developmental origin [2-4]. Trauma to the mandible or face may cause condylar fracture. If so, the broken condylar head will be displaced anteriorly due to the function of the lateral pterygoid muscle.

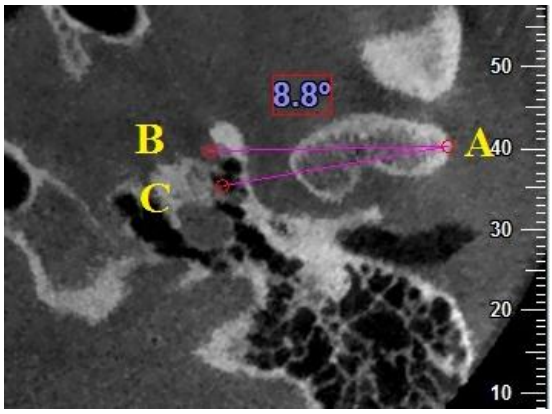

Fig. 1. Horizontal angle of a bifid left mandibular condyle on a transverse plane based on the axial cross-section. AB: Horizontal line; AC: The long axis of condyle

Gradually, a new head will grow up over the mandibular neck, in response to the functional demands with an anteroposterior orientation between the two heads [5,6]. Some believe that extended remaining of a fibro-vascular tissue over the developing condyles during the fetal period may result in BMC formation [3]. This type of BMC is usually bilateral and mediolaterally oriented [7]. Although the mediolateral type of BMC is considered to be developmentally formed, some exceptions with traumatic origin have been reported [8]. There is also a concept that only anteroposterior division of the condyles can be considered as a true BMC [9]; BMC is believed to play a role in some cases of temporomandibular joint disorder (TMD), and joint symptom [4]. On the other hand, radiographic appearance of BMC can mimic vertical condylar fractures, which confuses the physicians in cases of trauma to the face [2]. No treatment is indicated unless pain or functional disorders are present with the case [2]. Thus, differential diagnosis is important in cases of trauma to the face and TMD.

Most cases of BMC are discovered accidentally during routine dental radiographic examinations, more commonly on panoramic views taken for other dental purposes [2,3,10]. There is still a need for more epidemiologic research on the incidence and probable role of BMC in general health [3,4]. Considering the availability of only a few reports on BMC three-dimensionally, this study was designed to evaluate the incidence of BMC in a south Iranian population using CBCT since CBCT typically imposes a lower dose to patients compared to conventional radiography and computed tomography [11].

MATERIALS AND METHODS

This cross-sectional study was performed to assess the frequency of BMC and condylar head orientation on the transverse plane based on 425 CBCT scans of paranasal sinuses in Shiraz, Iran. These CBCT scans had been ordered as part of preoperative records for patients seeking rhinoplasty in an otolaryngology clinic. All CBCT scans were obtained in upright position, using a NewTom VGi scanner (QR srl, Verona, Italy), in a 15×15 field of view (FOV) and standard resolution mode (0.3mm voxel size). Presence of space occupying lesions within the TMJ area and lack of demographic information were considered as the exclusion criteria. Only the cases in whom, both condyles were within the FOV of CBCT scans were included. The CBCT scans were reviewed in NNT station (QR srl, Verona, Italy) by an experienced oral and maxillofacial radiologist. Horizontal angulations of each condyle were determined by measuring the angle between the long axis of the condyle in the axial cross-section with the largest mediolateral dimension and an imaginary horizontal line (Fig. 1). The left and right condylar heads were evaluated for presence of bifidity separately in the axial, coronal and sagittal planes. Considering the condylar head orientation, true sagittal and coronal cross-sections were prepared at a thickness of 1mm with 0.5mm interval, over the largest mediolateral dimension of the condyle in the axial plane. The Ethics Committee of Shiraz University of Medical Sciences approved the study and informed consents were obtained of all the participants.

Fig. 2. Coronal cross-sections (0.5mm thickness) of the cases with (A) unilateral and (B) bilateral bifid mandibular condyles

Statistical analysis:

SPSS software version 17.0 (Chicago, IL, USA) was used for data analysis. P-value less than 0.05 was considered statistically significant. Frequency of BMC was compared between the left and right sides and between males and females using t-test.

RESULTS

The CBCT records of 309 patients including 170 females (55%) and 139 males (45%) with a mean age of 29.43±9.7 years were entered in the study. The BMC was detected in 14 of them (seven females and seven males), which comprised 4.53% of the total population (Figs. 2 and 3).

There was no significant difference in the incidence of BMC between males and females. Eleven BMCs (3.56% of the population) were unilateral, while bilateral condylar head bifidity was detected only in three cases. Interestingly, all the bilateral cases were observed in males. Five unilateral cases were detected on the right side and six in the left side.

The mean horizontal angulations of the condyles in normal individuals were calculated to be 22.6±6° versus 24.02±4.33° in BMC cases, implying no significant difference (P=0.64). Similarly, there was no significant difference in the mean horizontal angulation values between men (23.2±5.8°) and women (22.21±5.96°).

DISCUSSION

Since BMC may play a role in TMDs or be mistaken for a condylar fracture, its differential diagnosis is of great importance. Many epidemiologic studies have been conducted to estimate the real incidence of BMC all over the world, with a wide variability in results. Most of the researches on BMC incidence were conducted on panoramic views, since it is a wide-spread, low cost, relatively low radiation dose, and easy to access radiographic technique, which visualizes a large volume of dental and supporting structures, including the rami and condyles. Besides, a large number of people have already taken panoramic views for dental purposes, which can be used in epidemiologic studies as a pre-existing sample source. Unfortunately, there are some serious limitations with the panoramic technique in this regard.

Due to superimpositions, some cases may be missed as in any other two-dimensional view. Partial BMCs are hard to detect on panoramic views and mediolateral BMCs may be seen as anteroposterior ones, if the condyles' horizontal angulations are large enough. The great discrepancy in the results of studies performed on panoramic views may be attributed to these limitations in part. Cho and Jung believed that panoramic views either under- or over-estimated the incidence of bifidity [10].

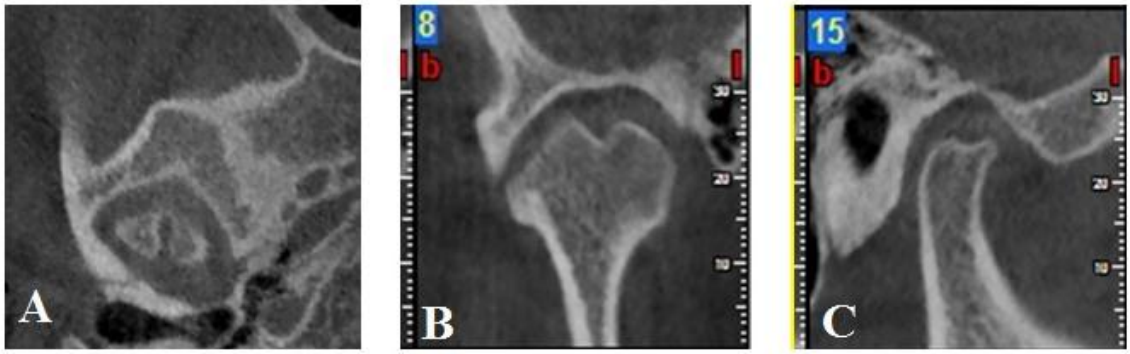

Fig. 3. (A) Axial, (B) corrected coronal and (C) corrected sagittal cross-sections of a case with right condylar head bifidity

On the other hand, there is no universally accepted protocol to diagnose BMC on panoramic views, and judgments are subjective. Since the introduction of CBCT, dental imaging improved by versatile abilities of this three-dimensional imaging modality. Yet, relatively low doses of radiation are delivered to patients and images are prepared in a really short time by a single rotation of the machine. Deleting superimpositions brings the chance to observe the anatomical structures of interest precisely, and multi-planar images enable the physician to evaluate the interested structure in proper plane.

As the operator can observe the condyles conspicuously, the probability of false positive and false negative diagnoses is significantly reduced, although the need for a standard scale to classify the severity of separations of the heads still exists. The CBCT imaging is not used as widely as the panoramic views because of the nature of this technique. Thus, the existing source of CBCT records is slightly different from the normal population compared with panoramic images. This slightly biases the epidemiologic studies performed on CBCT scans. The incidence of BMC in the current study was slightly higher than that in previous reports on the same population [12], but considering the advantages of three-dimensional imaging, it is negligible.

Most researchers believe that the incidence of BMC is increasing, as more radiographic examinations of higher quality are becoming available [3-5,7]. Menezes et al. reported an incidence of 0.018% for BMC in a Brazilian population on panoramic views [13]. About 78% of cases were unilateral, and female to male ratio was 3 to 1 [13]. Miloglu et al. evaluated 10,200 panoramic views and reported an incidence of 0.3% for BMC in a Turkish population [4]. Sahman et al. reported the prevalence of BMC to be 0.52% in Turkey, using panoramic radiographies as the screening tool [14]. Later, employing CT scan images, they reported a higher rate of about 1.82% in the same population [3]. Using CBCT records, Cho and Jung compared the prevalence of BMC in asymptomatic and symptomatic subjects with TMJ problems and no traumatic history and found no significant difference between them. They concluded that the presence of BMC would not lead to any TMJ symptoms or cause osseous changes [10]. We have already reported a high rate of BMC (3.5%) in an Iranian population [12] while in the current study, we found that 4.53% of CBCT records revealed BMC in patients of the same population. The new rate, although close to the previous one, is slightly higher. This difference can be attributed to the advantages of CBCT that eliminates superimpositions in the images of the

condyles. Use of this advanced modality improves the reliability of results. This finding is in accordance with the results of Sahman et al, who reported a higher rate for BMC in CT records compared to panoramic images in the same country [3,14]. It is worthy to mention that the lack of conspicuous criteria to diagnose BMC on panoramic images may be less important for CBCT scans, because of higher reliability of multi-planar images provided by this modality. Similarly, we believe that this will improve the agreement between different observers, and reduces the need to employ multiple observers in such studies, which requires the inter-observer agreement to be in an acceptable level. In most studies, the ratio of unilateral cases of BMC to bilateral form is about 3 to 1 [3,4,7,12,14].

The results of the current study are compatible with this ratio, using a three-dimensional imaging modality (nearly 4 to 1). Our results (seven females and seven males), are also in accordance with the afore-mentioned mean female to male ratio for BMC prevalence, which is about 1.3 to 1.0. However, Menezes et al. reported a much higher prevalence in females (3.5 to 1.0) [13]. Finally, we believe that panoramic views face some limitations in detection of BMCs although they provide opportunities for screening purposes. Oblique forms and partial bifid condyles are hard to discover using panoramic and other conventional imaging techniques [3,4]. Should the angulations of the condyle in the transverse plane are large enough, the mediolateral form of BMC may be diagnosed as an anteroposterior type. More advanced imaging techniques should be ordered, at least for symptomatic cases of BMCs or when treatment plans are to be conducted [3,4,7]. Last but not least, CBCT imaging may be an invaluable modality, considering its low dose of radiation (compared to CT scan), the short time needed (compared to magnetic resonance imaging), and high reliability of the produced images.

CONCLUSION

The prevalence of BMC in the studied population was 4.53%, which was slightly higher than that in previous reports. No significant difference was detected between males and females, sides and condylar horizontal angulations of patients with normal and bifid condyles.

ACKNOWLEDGEMENT

The authors thank the Vice-chancellor of Shiraz University of Medical Sciences for supporting this research (Grant 5363) and Dr. Vosough from the Dental Research Development Center at the School of Dentistry for his assistance in statistical analysis.

REFERENCES

1- Hrdlička A. Lower jaw: double condyles. Am J Phys Anthropol.1941 Mar;28(1):75-89.

2- White SC, Pharoah MJ. Oral radiology: principles and interpretation. St. Louis, Missouri, Elsevier- Mosby,2014:504.

3- Sahman H, Sisman Y, Sekerci AE, Tarim-Ertas E, Tokmak T, Tuna IS. Detection of bifid mandibular condyle using computed tomography. Med Oral Patol Oral Cir Bucal. 2012 Nov 1;17(6):e930-4.

4- Miloglu O, Yalcin E, Buyukkurt M, Yilmaz A, Harorli A. The frequency of bifid mandibular condyle in a Turkish patient population. Dentomaxillofac Radiol. 2010 Jan;39(1):42-6.

5-Tanner JM, Friedlander AH, Chang TI. Bilateral bifid mandibular condyles diagnosed with three-dimensional reconstruction. Dento-maxillofac Radiol. 2012 Dec;41(8):691-5.

6- Szentpétery A, Kocsis G, Marcsik A. The problem of the bifid mandibular condyle. J Oral Maxillofac Surg. 1990 Dec;48(12):1254-7.

7- Alpaslan S, Özbek M, Hersek N, Kanlı A, Avcu N, Fırat M. Bilateral bifid mandibular condyle. Dentomaxillofac Radiol. 2004 Jul;33(4):274-7.

8- Loh FC, Yeo JF. Bifid mandibular condyle. Oral Surg Oral Med Oral Pathol. 1990 Jan;69(1):24-7.
9- Dennison J, Mahoney P, Herbison P, Dias G. The false and the true bifid condyles. Homo. 2008;59(2):149-59.
10- Cho BH, Jung YH. Nontraumatic bifid mandibular condyles in asymptomatic and symptomatic temporomandibular joint subjects. Imaging Sci Dent. 2013 Mar;43(1): 25-30.
11- Gunduz K, Buyuk C, Egrioglu E. Evaluación de la Prevalencia de Cóndilo Mandibular Bífido Detectado en Tomografía Computadorizada Cone-Beam en una Población Turca. Int J Morphol. 2015 Mar;33 (1):43-7.
12- Haghnegahdar AA, Bronoosh P, Khojastepour L, Tahmassebi P. Prevalence of Bifid Mandibular Condyle in a Selected Population in South of Iran. J Dent (Shiraz). 2014 Dec;15(4):156-60.
13- Menezes A, de Moraes Ramos F, de Vasconcelos-Filho J, Kurita L, de Almeida S, Haiter-Neto F. The prevalence of bifid mandibular condyle detected in a Brazilian population. Dentomaxillofac Radiol. 2008 May;37(4):220-3.
14- Sahman H, Sekerci AE, Ertas ET, Etoz M, Sisman Y. Prevalence of bifid mandibular condyle in a Turkish population. J Oral Sci. 2011 Dec;53(4):433-7.