

Oncology

An Asymptomatic Primary Renal Carcinoid Tumor: A Case Report



Colin S. Linke*, Scott Shie

Parkview Regional Medical Center, 11109 Parkview Plaza Dr, Fort Wayne, IN 46825, USA

ARTICLE INFO

Article history:

Received 22 April 2016

Accepted 27 April 2016

Keywords:

Carcinoid tumor

Primary

Renal

ABSTRACT

Primary renal carcinoid tumors are exceedingly rare, with less than 100 total cases being documented in world literature. A 32-year old male was referred to our service for a slow-growing, renal mass, which was first diagnosed 9-years prior. The patient was successfully treated with radical nephrectomy. In this article, we present our case report on an asymptomatic primary renal carcinoid tumor.

© 2016 The Authors. Published by Elsevier Inc. This is an open access article under the CC BY-NC-ND license (<http://creativecommons.org/licenses/by-nc-nd/4.0/>).

Introduction

Primary carcinoid tumors of the kidney are extremely rare neoplasms, with less than 100 cases being documented in world literature. Therefore, not much is known about the pathogenesis and prognosis of these tumors. Carcinoid tumors are low-grade, malignant neoplasms, which most classically present within the gastrointestinal tract and lungs.¹ The purpose of this article is to present our clinical workup and surgical intervention of this rare urological neoplasm.

Case presentation

A 32-year old male presented as a urology consult for a right kidney mass. He has a significant past medical history of recurrent nephrolithiasis without surgical intervention. During imaging of the kidney stones, a right kidney mass was incidentally found. The lesion had at least doubled in size since it was first diagnosed 9-years ago. He denies gross hematuria and lower urinary tract symptoms. He also denies flank pain, abdominal pain, fevers, chills, or unintentional weight loss. He denies any family history of urologic malignancies. He has a 7.5 pack/year smoking history. CT scan reveals that the mass is solid and enhancing, measuring $3.8 \times 3.9 \times 3.5$ cm (Fig. 1). At the patient's request, a PET-CT fusion test was ordered, which showed normal FDG uptake in the right kidney mass, and no abnormal FDG uptake throughout the body.

Given the enlarging size and the probability that this was a cancerous mass, the patient elected to undergo robotic assisted laparoscopic right radical nephrectomy. After the kidney had been

removed in surgery, several nodal packets were observed along the lateral margin of the cava. Therefore, a paracaval lymph node dissection (2.5 cm) was also performed. Pathological analysis revealed that the mass was a $5.0 \times 5.0 \times 4.0$ poorly circumscribed, friable tumor that filled the renal sinus and adjacent tissue. The mass was pushing into the helium, and was less than 0.1 cm from the fatty margin. All margins were negative. Microscopic analysis revealed the neoplastic cells to have tall columnar cytoplasm with a uniform oval nucleus. There were not any mitoses observed. The neoplastic cells were strongly positive for chromogranin and synaptophysin (Figs. 2 and 3). The cells were negative for cytokeratin 7, cytokeratin 20, and prostate specific antigen. The proliferation marker Ki-67 was positive in less than 2% of the nuclei. Extensive sectioning of the right kidney revealed focal invasion into the capsule, with a few nests of tumors found in the fat outside of the capsule. These are described as “floaters” and not “true” invasive carcinoma. This was therefore determined to be a primary carcinoid tumor by pathological analysis. Furthermore, the right paracaval lymph node was found to have been replaced microscopically by malignant neoplasm. The staging was determined to be pT3aN1.

After the nephrectomy, the recommendations by the oncology service were to manage this disease similarly to a regular carcinoid tumor without carcinoid syndrome. In this case, we would monitor him with urine and blood tests done at regular intervals checking specifically for serotonin and chromogranin A. Upon 1-month follow-up, both the chromogranin A and serotonin levels were within normal ranges.

Discussion

Carcinoid tumors have been described by Zuetenhorst et al as neuroendocrine tumors that are derived from neurochromaffin

* Corresponding author.

E-mail address: colin.linke@lmunet.edu (C.S. Linke).

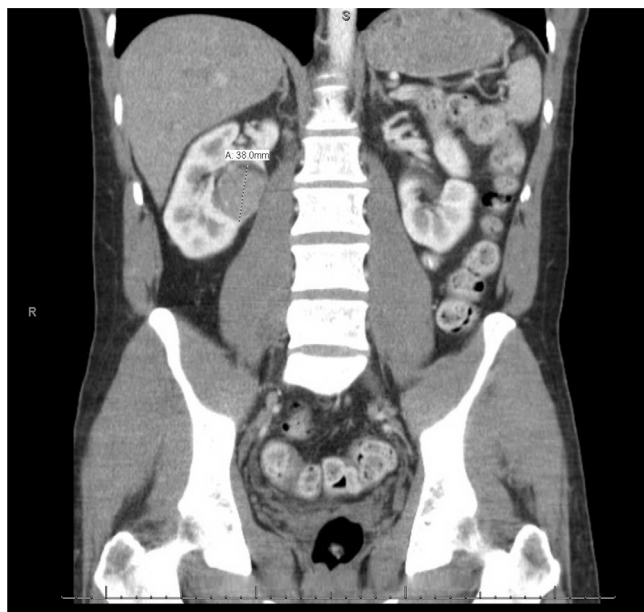


Figure 1. Posterior medial interlobar lesion that has close proximity to the hilum without vascular invasion.

cells, which can be found throughout the body.² Patients with carcinoid tumors are classically only symptomatic if their lesion produces vasoactive peptides (producing flushing, diarrhea, wheezing, etc.).² The patient described here was without any symptoms, and the renal carcinoid only being found due to the imaging for his kidney stones. According to Omiyale et al, 25–30% of primary renal carcinoid tumors are found incidentally. Other commonly reported symptoms are abdominal/flank pain, hematuria, constipation, urinary frequency, fever, weight loss, epigastric discomfort, and abdominal mass on physical exam.³ It should be noted that within the documented cases, neuroendocrine syndromes are rare, with the incidence being 12.7%.³

The majority of renal carcinoid tumors described in the literature are histologically analogous to carcinoids found elsewhere, featuring low mitotic activity, without necrosis, and arranged in a trabecular pattern with a nested pattern.³ The origin of the renal carcinoid tumor is of debate, given that neuroendocrine cells are not found in normal renal parenchyma. It has been proposed that

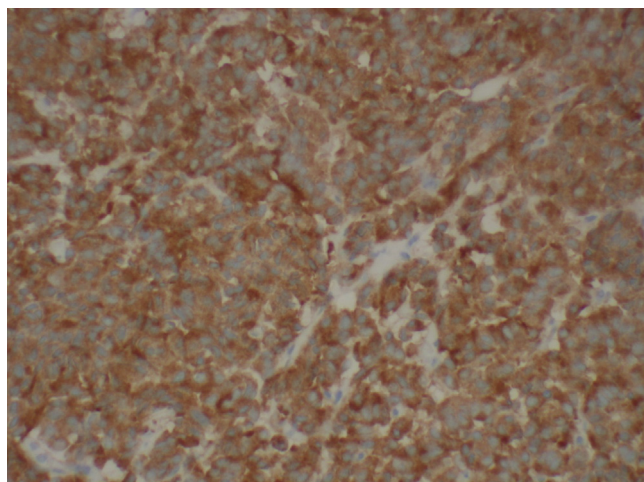


Figure 2. Resected tumor slide showing synaptophysin positivity.

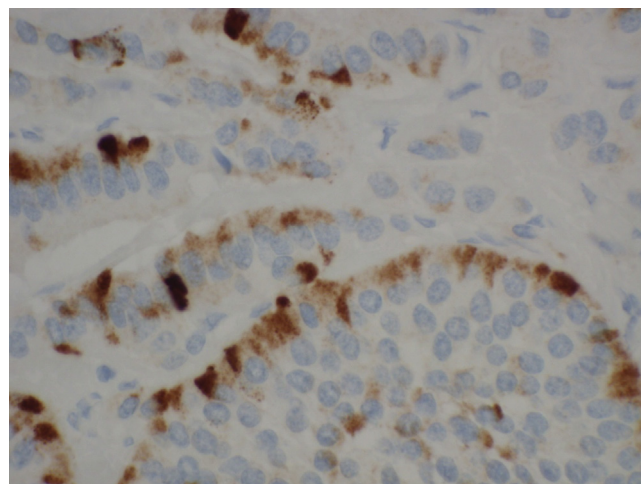


Figure 3. Resected tumor slide showing chromogranin positivity.

the tumor has an embryologic association, with the tumor being derived from misplaced neural crest cells in the kidney's hilum.¹ The carcinoid described in this case showed no necrosis, no mitoses, and a proliferation marker Ki-67 positivity in less than 2% of cells. Therefore, our case can be considered a typical carcinoid. According to Omiyale et al, the only predictive prognostic measure of these tumors is staging. However, survival rates are excellent, with 73.1% of patients without evidence of disease after treatment.³

Conclusion

Due to the rarity of published data on renal carcinoid tumors, it is difficult to assess their prognosis. It has been shown that renal carcinoid tumors are more common in patients with horseshoe kidney, with a 62-fold increase in relative risk.⁴ In understanding the indolent nature of carcinoid tumors of the kidney, it is well within reason that our patient's lesion could have started even greater than 9-years ago.

Consent

All appropriate consents, permissions, and releases were obtained for this paper.

Funding disclosure

This research did not receive any specific grants from funding agencies in the public, commercial, or not-for-profit sectors.

Conflict of interest

None.

References

1. Kanodia K, Vanikar AV, Patel RD, et al. Primary renal carcinoid tumor. *Saudi J Kidney Dis Transpl.* 2013;24:988–990.
2. Zeutenhorst JM, Taal BG. Metastatic carcinoid tumors: a clinical review. *Oncologist.* 2005;10:123–131.
3. Omiyale AO, Venyo AK. Primary carcinoid tumour of the kidney: a review of the literature. *Adv Urol.* 2013;2013:579396.
4. Tal R, Lask DM, Livne PM. Metastatic renal carcinoid: case report and review of the literature. *Urology.* 2003;61:838. xv-838xvii.