Dental Research Journal

Original Article

The use of platelet-rich fibrin (PRF) and PRF-mixed particulated autogenous bone graft in the treatment of bone defects: An experimental and histomorphometrical study

Nesligül Niyaz Kökdere, Timuçin Baykul, Yavuz Findik

Department of Oral and Maxillofacial Surgery, Faculty of Dentistry, Süleyman Demirel University, Isparta, Turkey

ABSTRACT

Background: Various materials and techniques have been developed to facilitate bone healing process and reduce its healing period. In recent studies, it is pointed out that, platelet-rich fibrin (PRF) which is derived autogenously from the own blood of the individuals, increase regeneration and accelerate the healing of the wound, due to the consisting various growing factors. The aim of the experimental study is to evaluate the efficiency of PRF and PRF/autogenous graft combination on bone healing in different time intervals.

Materials and Methods: A total of 24 skeletally mature New Zealand rabbits were used. Animals were divided randomly into two groups. Two bone defects with a diameter 3, 3 mm were created on the right and left tibia in all group animals. Only particulate autogeneous bone graft, only PRF, combination of PRF and autogeneous bone graft and empty bone cavity, were performed to all animals. The animals in the first experimental group were sacrificed after 30 days. The animals in the second experimental group were sacrificed after 60 days from the operation. Histomorphometrical and statistical analysis was performed. The data were analyzed using Tukey test ($P < 0.05$ for osteoblast number, $P < 0.01$ for osteoclast and new bone area values).

Results: Histomorphometrical analyzes showed that either PRF used alone or used in conjuction with autogenous bone graft, PRF accelerated the healing of the bone defects. There were statistically significant differences in osteoblast, osteoblast and new bone area values in PRF alone and autogenous graft with PRF than the other groups.

Conclusion: Our preliminary result demonstrated that PRF increase new bone formation and has a positive effect on early bone healing.

Key Words: Bone defect, bone healing, platelet-rich fibrin

Received: December 2014
Accepted: March 2015

Address for correspondence:
Dr. Yavuz Findik,
Department of Oral and Maxillofacial Surgery,
Faculty of Dentistry,
Süleyman Demirel University, Isparta,
Turkey.
E-mail: yavuzfindik32@hotmail.com

INTRODUCTION

Fibrin glue was the first blood-related product used in surgery, in the 1980s. At that time, fibrin glue was used as a hemostatic agent and surgical glue. Many authors then stated that it was used because of its positive effects on tissue healing.[1] In the following years, transforming growth factor b (TGF-β) in the platelets were discovered, and many studies were performed for hard-soft tissue healing and regeneration.[2] In the

Access this article online

Website: www.drj.ir
www.drjjournal.net
www.ncbi.nlm.nih.gov/pmc/journals/1480

This is an open access article distributed under the terms of the Creative Commons Attribution-NonCommercial-ShareAlike 3.0 License, which allows others to remix, tweak, and build upon the work non-commercially, as long as the author is credited and the new creations are licensed under the identical terms.

For reprints contact: reprints@medknow.com

How to cite this article: Kökdere NN, Baykul T, Findik Y. The use of platelet-rich fibrin (PRF) and PRF-mixed particulated autogenous bone graft in the treatment of bone defects: An experimental and histomorphometrical study. Dent Res J 2015;12:418-24.

1990s, with the rapid development of the techniques and equipment, platelet-rich plasma (PRP), which contained a higher concentration of platelets than fibrin glue, was available. The first PRP study in the field of oral surgery was introduced by Whitman *et al*. in 1997.[3]

Platelet-rich fibrin (PRF) is a modification of PRP. Although introduced a decade ago, it is still used in many medical specialties as well as in oral and maxillofacial surgery. It is indicated for alveolar bone augmentation, sinus lift procedure, extraction socket preservation, defect reconstruction following cyst enucleation or tumor excision, and also alveolar cleft repair. PRF is an autologous fibrin with a large quantity of platelets and leukocyte cytokines.[4] This concentrate contains high levels of growth factors, including the platelet-derived growth factor (PDGF), TGF, vascular endothelial growth factor, insulin-like growth factor (IGF), and epidermal growth factor (EGF).[5] These growth factors play a central role in hemostasis and the bone healing process, which makes PRF advantageous. Platelet growth factors are a well-known source of healing cytokines, usable for clinical applications. In many studies, PRF has a direct or indirect effects on bone regeneration in bone grafting or bone defect healing.[6-8] In the literature, authors have reported many advantages of PRF for bone regeneration.[9] There are also much controversies in the literature over the use of different grafts as bone substitutes.[10] The ideal biomaterials should provide osteoconductive and osteoinductive features similar to autogenous bone grafts, which are still considered the gold standard in reconstructive bone surgery. However, there is no ideal biomaterial. Although some studies have focused on the applications of PRF, few used animal models for experiments on bone regeneration with sole or combined applications of PRF and autogenous bone graft. The aim of the experimental study was to evaluate the efficiency of only PRF and a PRF/autogenous bone graft combination on bone healing at different time intervals.

MATERIALS AND METHODS

Twenty-four 6-8-month-old male New Zealand white rabbits with an average weight of 2.7 kg (range 2.5-3.0 kg) were used in this experimental study. The animal study protocol was approved by the Animal Studies Review Committee and was in accordance with institutional guidelines (University of Süleyman Demirel, Isparta, Turkey). The animals were housed in an experimental animal room (22°C, 55% humidity, and a 12-h light/dark cycle) and fed a standard laboratory diet and water. These rabbits were randomly divided into two groups (Group A and Group B). Group A animals were sacrificed after 30 days, and Group B animals were sacrificed after 60 days after the operation. In all groups, two defects were osteotomized in the right tibial bone, and two defects were osteomized in the left tibia in same rabbit as defects named as 1, 2, 3, and 4. Defect 1 was filled with particulated autogenous bone graft; defect 2 was left empty; defect 3 was filled with PRF and particulate autogenous bone; defect 4 was filled only with PRF [Figure 1].

The results are expressed as the mean ± standard deviation. Statistical analysis was performed using the SPSS 16.0 software package program (IBM, Armonk, NY, USA). The Tukey was used to compare data between the groups ($P < 0.05$ for osteoblast number, $P < 0.01$ for osteoclast and new bone area values).

Platelet-rich fibrin preparation method

The detailed procedure has been extensively described in previous publications.[11] After general anesthesia, 6-8 mL of blood was obtained from the central artery of the ear. It was then transferred to plastic tubes (Vacuette, Greiner Bio-One, GmbH, Kremsmunster, Austria) and centrifuged for 12 min at 2700 rpm (Hettich, Tuttlingen, Germany). After centrifugation, the blood separated into three layers. The middle layer, which represents PRF (0.6-0.8 mL), was taken.

Surgical procedure

After general anesthesia was delivered with 100 mg/kg ketamine HCl (Ketalar; Parke Davis, Wellington, New

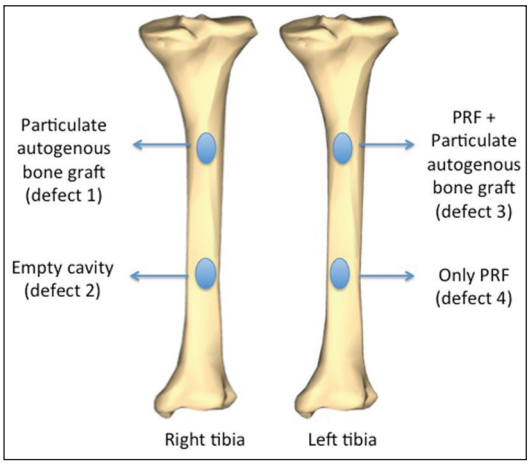

Figure 1: View of the defects.

Zealand) and 10 mg/kg xylazine HCl (Ketasol; Richter Pharma AG, Weis, Austria), the right and left tibial areas were shaved, and the skin was washed with a 10% povidone iodine solution (Poviiodeks, Kimpa, Turkey). After a skin incision in the tibial area, the subcutaneous tissues were dissected down to the periosteum, and a periosteal incision was made on the tibia. With a standard trephine bur under irrigation with saline, 2 pieces of mono cortical block bone grafts 3, 3 mm in diameter and 2 mm in depth, were osteotomized from both right and left tibias. These bone defects were nearly 2.5-3-mm away from each other [Figure 2]. After the cortical grafts were obtained, the grafts were particulated with a bone mill. The first defect on the right tibia was filled with only particulate bone; the second defect on the right tibia was left empty. The first defects on the left tibia were filled with particulate graft combined with PRF, and the second defect in the left tibia was filled with only PRF. We did not use any type of membrane to cover the grafted areas. The periosteum, muscle fascia, and skin were then sutured in separate layers. These procedures were performed on both the left and the right tibias of all rabbits in all groups. An analgesic (1 mg/kg tramadol, Contramal; Abdi Ibrahim, Istanbul, Turkey) and an antibiotic (25 mg/kg cefazolin, Cefamezine; Eczacıbas, Istanbul, Turkey) were administered intramuscularly preoperatively and twice per day for 3 postoperative days. Group A animals were sacrificed after 30 days, and Group B animals were sacrificed 60 days after the operation. The tibias were fixed in 10% formalin and underwent a histomorphometric evaluation.

Histomorphometric evaluation

Each specimen was fixed in 10% formaldehyde solution at least 72 h. For a dehydration procedure, TBD-2 (Merck, Darmstadt, Germany) was used and embedded in paraffin. Serial cross-sections (4 μm) were cut through the larger diameter of the defect and stained with hematoxylin-eosin (HE). The HE stains revealed the cellular reactions indicating bone formation. The slides were photographed with the use of a virtual slide system (Nikon Eclipse E-400, Nikon, Tokyo, Japan and Nikon Coolpix 5000, Tokyo, Japan). The images were analyzed by Clemex Vision Lite 3.5 image analysis program (Clemex Technologies, Quebec, Canada). Newly formed bone area, osteoblast, and osteoclast numbers were evaluated [Figures 3 and 4].

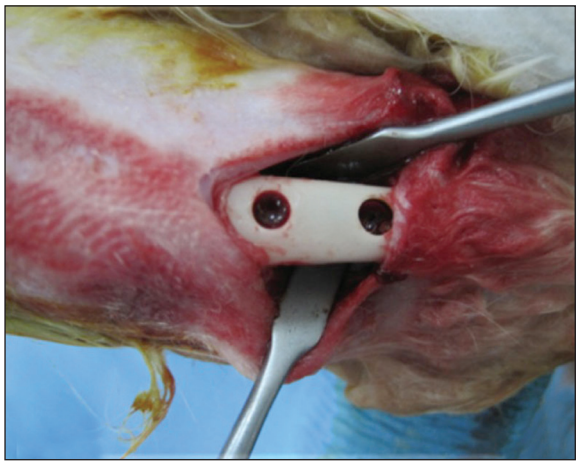

Figure 2: Bone defects were nearly 2.5-3-mm away from each other.

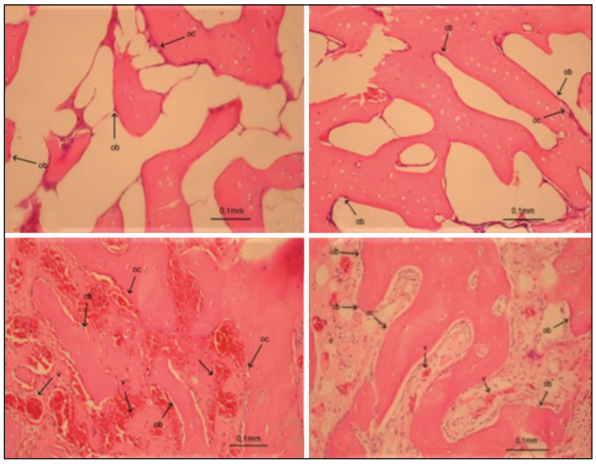

Figure 3: Histological view of the defects of Group A.

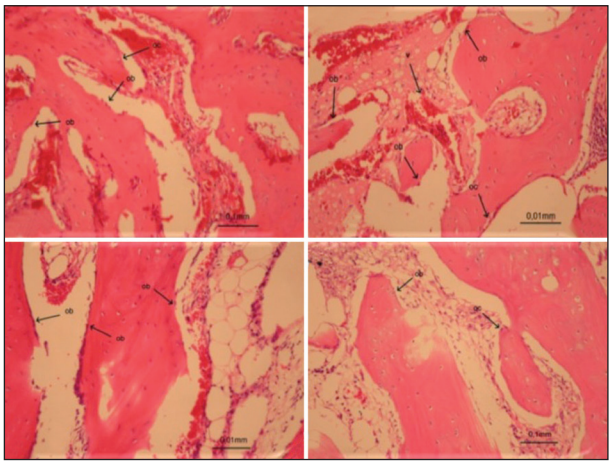

Figure 4: Histological view of the defects of Group B.

RESULTS

After the surgery, 1 rabbit died as a result of a fungal infection. During sacrifice, tibia fractures were seen in 3 rabbits. The animals with fractures were excluded from the study. In the histomorphometric evaluation, 3 rabbit tibias were excluded because of inappropriate cross-section. The remaining 17 animals (34 tibias)

recovered well from the surgical procedure, without any signs of inflammation or abscess formation.

Table 1 displays comparisons of the osteoblast number of Group A and Group B for all defects. In Group A and Group B, no difference was detected between defect 1 and defect 2 (Group A 36.42 ± 2.31, Group B 39.22 ± 2.00, $P < 0.05$) ($P = 0.0511$). There were no statistical differences in terms of the osteoblast number between the defect 3 and defect 4 ($P = 0.0626$). There were also differences in the osteoblast number between defect 3 and defect 4 and defect 2 and defect 1 ($P = 0.0216$).

Table 2 displays a comparison of the osteoclast number in Group A and Group B for all defects ($P < 0.01$). There were differences in the osteoclast numbers of Group A (3.00 ± 0.361) and Group B (1.500 ± 0.211) ($P = 0.0016$). In Group A, no difference was detected between defect 1 and defect 2 ($P = 0.0221$). There were no statistical differences in terms of the osteoblasts number between defect 3 and defect 4 ($P = 0.0208$) There were also differences in the osteoblasts number between defect 3 and defect 4 and defect 2 and defect 1. The same results were detected in Group B.

Table 3 presents a comparison of the newly formed bone area of Group A and Group B for all defects ($P < 0.01$). There were differences in the newly formed bone area in Group A (302725 ± 11930) and Group B (318994 ± 11621) ($P = 0.0036$). No difference was detected between defect 3 and defect 4 in Group A and Group B ($P = 0.0216$). There were also differences in the newly formed bone area between defect 3 and defect 4 and defect 1 and defect 2 in all groups.

Table 1: Number of osteoblasts of groups ($P < 0.05$)

Osteoblast number	Group A	Group B	Main
1 (autogenous)	23.56	32.75	27.88
2 (empty)	26.56	34.13	30.12
3 (PRF+autogenous)	44.78	44.13	44.47
4 (PRF)	50.78	45.88	48.47
Main (all defects)	36.42	39.22	

PRF: Platelet-rich fibrin.

Table 2: Number of osteoclasts of the groups ($P < 0.01$)

Osteoclast number	Group A	Group B	Main
1 (autogenous)	4.111	2.375	3.294
2 (empty)	4.333	2.000	3.235
3 (PRF+autogenous)	2.000	0.875	1.471
4 (PRF)	1.556	0.750	1.176
Main (all defects)	3.000	1.500	

PRF: Platelet-rich fibrin.

DISCUSSION

Many studies seek to improve bone grafting techniques in oral and maxillofacial surgery applications to reduce the bone healing time and risk of complications and to develop more mature bone.[12] Bone metabolism is arranged with chemicals and electrical and mechanical stimulants; during bone healing, platelets, macrophages, and fibroblasts are known to secrete many growth factors.[13]

Platelet-rich fibrin, as a fibrin biomaterial, carries the favorable constituents present in a blood sample such, as a large quantity of platelets and leukocyte cytokines.[4] Concentrated platelets contain many growth factors, including the PDGF, TGF-β, IGF, EGF, fibroblast growth factor, and bone morphogenic protein.[5] These growth factors play a central role in hemostasis, angiogenesis, osteoblastic proliferation and differentiation which makes PRF advantageous. Its molecular structure and low thrombin concentration are optimum for the migration of endothelial cells and fibroblasts.[14] PRF allows a significant postoperative protection of the surgical site and seems to accelerate the integration, maturation, and remodeling, while enhancing bone graft density.

The use of PRF during bone grafting offers the following four advantages. First, PRF plays an important mechanical role in maintaining and serving the grafted materials. Second, the fibrin network at the regenerative site facilitates cellular migration, vascularization, and survival of the graft. According to our results, defect 3 presented far more osteoblasts and newly formed bone area values than defect 1. Thus, PRF keeps graft particles together

Table 3: New bone area values of the groups ($P < 0.01$)

New bone area	1 (autogenous)	2 (empty)	3 (PRF + autogenous)	D (PRF)	Main (all defects)
Group A	265,962	263,477	347,027	334,436	302,725
Group B	280,512	283,507	366,541	345,417	318,994
Main	272,809	272,903	356,210	339,603	

PRF: Platelet-rich fibrin.

and provides suitable areas for formation of new bone, especially during the early bone healing period. Third, the platelet cytokines (PDGF, TGF-β, and IGF-1) are gradually released as the fibrin matrix is resorbed, thus creating a continual process of healing. Finally, the presence of leukocytes and cytokines in the fibrin network can play a significant role in the self-regulation of inflammatory and infectious phenomena within the grafted material.[15] In our experimental study, according to results, especially in defects 3 and 4 for both groups A and B, the number of osteoblasts and newly formed bone area values were much higher than in defects 1 and 2. These results supported the above advantages of the PRF in bone defect healing.

The remodeling period consists of the combined duration of the resorption, the osteoclastic reversal and the formation periods of bone growth and development. This period is 3-6 months in humans and only 6 weeks in rabbits.[16] Based on these data, in our study, recovery at the end of days 30 and 60 assessed bone healing in the rabbit tibia; at the end of this period, the animals were sacrificed.

In our study, comparisons have been made between the Group A and Group B defects in order to assess the bone healing of all equivalent defects between the all groups at different time intervals. For defects with PRF, after the 1st- and 2nd-month findings, significant differences were not observed in terms of the number of osteoblasts or new bone formation area values. This finding supports the fact that PRF promotes early bone healing. However, for all defects of Groups A and B, there were more osteoclasts in Group A, which is statistically significant. Osteoclastic activity in Group A was greater than in Group B due to osteoclast life and activity decrease at the end of the 2-week healing process. Osteoblasts and osteoclasts mechanisms work in opposition. During bone formation, osteoclastic activity decreases and osteoblast activation increases.[17] In our study, the number of osteoclasts compared to the number of osteoblasts in all defects provided exactly opposing quantitative findings, and this proves the reliability and accuracy of our results. According to our findings, between Group A and Group B, healing potential was the same, but in the case of long-term analysis of results, there were no advantages, especially when considering that in clinical trials, early rapid bone formation can be positive.

Several studies have reported a positive effect of PRF on bone regeneration in a graft. When platelet products are added to different kinds of graft materials, a more predictable outcome is derived after bone augmentations.[4,18-20]

The literature includes few studies using only PRF or graft materials with different characteristics combined with PRF. In an animal study, Lee *et al*. have demonstrated that clinical outcomes are better using autogenous bone mixed with platelet-enriched fibrin glue than using autogenous bone alone.[21] Tatullo *et al*. conducted histological and clinical evaluations of 60 patients who underwent surgery before implant surgery.[22] The experimental group received bovine bone graft material combined with PRF, whereas the control group received only bovine bone graft material. The results revealed that PRF led to the production of new bone, even at 106 days. Ozdemir *et al*. assessed the effects of PRF on bone augmentation in an animal model.[23] PRF and bovine bone showed a greater area of new bone formation than the other two groups at 3 months. In other study, authors investigated the effects of PRF associated or not with Bio-Oss on bone defects in the calvaria of rats. A critical-size defect of 5-mm diameter was performed in the calvaria of 48 rats and they concluded that PRF had a positive effect on bone regeneration only when associated with Bio-Oss.[24] Similarly in other study, authors have compared healing properties of PRF and its combination with a ceramic synthetic material (graft) composed of hydroxyapatite and b-tricalcium phosphate (b-TCP) in an animal model and they stated that PRF addition of the ceramic material significantly increased the formation of new bone, providing a better substrate for bone regeneration.[25]

In another study, authors revealed a histomorphometric increase in bone formation with the addition of PRF to biphasic calcium phosphate in surgically created defects in sheep tibia.[26] In a study, PRF had a positive effect on bone formation after 8 weeks after sacrifice, when used alone or combined with autogenous bone.[27] We, however, evaluated the early bone healing 4 weeks after sacrifice and compared it to the results 8 weeks later. According to our results, the new bone formation area was not statistically significant between the Group A (302.725 ± 11.930) and Group B (318.994 ± 11.621) for all defects. The number of osteoblasts was not statistically significant in Group A (36.42 ± 2.31) or Group B (39.22 ± 2.00) for all defects ($P < 0.05$). These results showed that PRF was

very effective in early bone healing. In a study of the PRF/β-TCP combination group, more new bone formation, including osteoblasts and osteocytes in the connective tissue, was observed than the other groups.[28] The authors stated that it was thought that PRF accelerates the healing effect by keeping the particles of β-TCP together via its adhesive property and attaching them tightly to the walls of the cavity. Similarly, in our study, more new bone formation and osteoblasts were obtained with the autogenous particulate bone grafts combined with PRF than the other groups. PRF kept the autogenous particulate bone together, so we did not need an additional membrane for stabilization of the graft particles. According to our results, further studies could be done using different applications to assess PRF and autogenous grafts together at different time intervals, such as with alveolar grafting operations.

In oral and maxillofacial surgery applications, rehabilitation of the bone defects requires more than a 3-6-month interval after bone grafting. Thus, the growth factors that cause differences in osteogenic effects at early stages may have little or no effect in the long-term. Our study showed that defects 3 and 4 for both Group A and Group B showed more new bone formation than the subgroups 1 and 2; hence, it can be inferred that applying growth factors to bone defects results in greater osteogenic effects than applying nothing. The capacity of PRF to induce the growth of osteoblasts can help to increase the new bone regeneration when used alone. Within the limitations of this experimental study, it can be concluded that PRF in addition to particulate autogenous bone graft may favor the formation of new bone and PRF keep the graft particles together. Based on our results, applying PRF to the bone defects may accelerate the bone graft healing and shorten the time period for rehabilitation. The hemostatic effect of the PRF (stopping bleeding in a short time) is important for keeping graft particles together in the bone defects; so in such defects, this may reduce the necessity of using the membrane to stabilize graft particles.

Financial support and sponsorship

This study was supported and funded by the Süleyman Demirel University, Scientific Research Projects Unit.

Conflicts of interest

The authors of this manuscript declare that they have no conflicts of interest, real or perceived, financial or non-financial in this article.

REFERENCES

1. Niekisch R. Application possibilities of fibrin glue in dentistry and maxillofacial surgery. Zahn Mund Kieferheilkd Zentralbl 1980;68:555-61.
2. Tamimi FM, Torres J, Tresguerres I, Clemente C, López-Cabarcos E, Blanco LJ. Bone augmentation in rabbit calvariae: Comparative study between Bio-Oss and a novel beta-TCP/DCPD granulate. J Clin Periodontol 2006;33:922-8.
3. Whitman DH, Berry RL, Green DM. Platelet gel: An autologous alternative to fibrin glue with applications in oral and maxillofacial surgery. J Oral Maxillofac Surg 1997;55:1294-9.
4. Toffler M, Toscano N, Holtzclaw D, Corso MD, Dohan DM. Introducing Choukroun's platelet rich fibrin (PRF) to the reconstructive surgery milieu. J Implant Adv Clin Dent 2009;1:22-31.
5. Dohan DM, Choukroun J, Diss A, Dohan SL, Dohan AJ, Mouhyi J, *et al.* Platelet-rich fibrin (PRF): A second-generation platelet concentrate. Part II: Platelet-related biologic features. Oral Surg Oral Med Oral Pathol Oral Radiol Endod 2006;101:e45-50.
6. Kaigler D, Silva EA, Mooney DJ. Guided bone regeneration using injectable vascular endothelial growth factor delivery gel. J Periodontol 2013;84:230-8.
7. Panda S, Ramamoorthi S, Jayakumar ND, Sankari M, Varghese SS. Platelet rich fibrin and alloplast in the treatment of intrabony defect. J Pharm Bioallied Sci 2014;6:127-31.
8. Barone A, Ricci M, Romanos GE, Tonelli P, Alfonsi F, Covani U. Buccal bone deficiency in fresh extraction sockets: A prospective single cohort study. Clin Oral Implants Res 2014 Mar 31. doi: 10.1111/clr.12369. [Epub ahead of print].
9. He L, Lin Y, Hu X, Zhang Y, Wu H. A comparative study of platelet-rich fibrin (PRF) and platelet-rich plasma (PRP) on the effect of proliferation and differentiation of rat osteoblasts *in vitro*. Oral Surg Oral Med Oral Pathol Oral Radiol Endod 2009;108:707-13.
10. Billström GH, Blom AW, Larsson S, Beswick AD. Application of scaffolds for bone regeneration strategies: Current trends and future directions. Injury 2013;44 Suppl 1:S28-33.
11. Bae JH, Kim YK, Kim SG, Yun PY, Kim JS. Sinus bone graft using new alloplastic bone graft material (Osteon)-II: Clinical evaluation. Oral Surg Oral Med Oral Pathol Oral Radiol Endod 2010;109:e14-20.
12. Raghoebar GM, Schortinghuis J, Liem RS, Ruben JL, van der Wal JE, Vissink A. Does platelet-rich plasma promote remodeling of autologous bone grafts used for augmentation of the maxillary sinus floor? Clin Oral Implants Res 2005;16:349-56.
13. Boden SD. Bioactive factors for bone tissue engineering. Clin Orthop Relat Res 1999 Oct;(367 Suppl):S84-94.
14. Prakash S, Thakur A. Platelet concentrates: Past, present and future. J Maxillofac Oral Surg 2011;10:45-9.
15. Simonpieri A, Del Corso M, Sammartino G, Dohan Ehrenfest DM. The relevance of Choukroun's platelet-rich fibrin and metronidazole during complex maxillary rehabilitations using bone allograft. Part II: Implant surgery, prosthodontics, and survival. Implant Dent 2009;18:220-9.
16. Parfitt A. Bone forming cells in clinical conditions. In: Hall B, editor. The Osteoblast and Osteocyte. UK: Telford Press; 1990. p. 351-429.

17. Hall BK, Miyake T. Divide, accumulate, differentiate: Cell condensation in skeletal development revisited. Int J Dev Biol 1995;39:881-93.
18. Dohan DM, Del Corso M, Diss A, Mouhyi J, Charrier JB. Three-dimensional architecture and cell composition of a choukroun's platelet-rich fibrin clot and membrane. Ann Maxillofac Surg 2011;1:53-7.
19. Choukroun J, Diss A, Simonpieri A, Girard MO, Schoeffler C, Dohan SL, *et al.* Platelet-rich fibrin (PRF): A second-generation platelet concentrate. Part V: Histologic evaluations of PRF effects on bone allograft maturation in sinus lift. Oral Surg Oral Med Oral Pathol Oral Radiol Endod 2006;101:299-303.
20. Sohn DS, Moon JW, Moon YS, Park JS, Jung HS. The use of concentrated growth factor (CGF) for sinus augmentation. J Oral Implant 2009;38:25-38.
21. Lee HJ, Choi BH, Jung JH, Zhu SJ, Lee SH, Huh JY, *et al.* Maxillary sinus floor augmentation using autogenous bone grafts and platelet-enriched fibrin glue with simultaneous implant placement. Oral Surg Oral Med Oral Pathol Oral Radiol Endod 2007;103:329-33.
22. Tatullo M, Marrelli M, Cassetta M, Pacifici A, Stefanelli LV, Scacco S, *et al.* Platelet Rich Fibrin (P.R.F.) in reconstructive surgery of atrophied maxillary bones: Clinical and histological evaluations. Int J Med Sci 2012;9:872-80.
23. Ozdemir H, Ezirganli S, Isa Kara M, Mihmanli A, Baris E. Effects of platelet rich fibrin alone used with rigid titanium barrier. Arch Oral Biol 2013;58:537-44.
24. Oliveira MR, deC Silva A, Ferreira S, Avelino CC, Garcia IR Jr, Mariano RC. Influence of the association between platelet-rich fibrin and bovine bone on bone regeneration. A histomorphometric study in the calvaria of rats. Int J Oral Maxillofac Surg 2014 Dec 30. pii: S0901-5027(14)00473-1.
25. Nacopoulos C, Dontas I, Lelovas P, Galanos A, Vesalas AM, Raptou P, *et al.* Enhancement of bone regeneration with the combination of platelet-rich fibrin and synthetic graft. J Craniofac Surg 2014;25:2164-8.
26. Bölükbasi N, Yeniyol S, Tekkesin MS, Altunatmaz K. The use of platelet-rich fibrin in combination with biphasic calcium phosphate in the treatment of bone defects: A histologic and histomorphometric study. Curr Ther Res Clin Exp 2013; 75:15-21.
27. Pripatnanont P, Nuntanaranont T, Vongvatcharanon S, Phurisat K. The primacy of platelet-rich fibrin on bone regeneration of various grafts in rabbit's calvarial defects. J Craniomaxillofac Surg 2013;41:e191-200.
28. Yilmaz D, Dogan N, Ozkan A, Sencimen M, Ora BE, Mutlu I. Effect of platelet rich fibrin and beta tricalcium phosphate on bone healing. A histological study in pigs. Acta Cir Bras 2014;29:59-65.