British Heart Journal, 1973, 35, 805–810.

Bundle of His recordings in congenital heart disease[1]

Grace S. Wolff, Michael D. Freed, and R. Curtis Ellison

From the Department of Cardiology, The Children's Hospital Medical Center, and the Department of Pediatrics, Harvard Medical School, Boston, Massachusetts, and the Division of Pediatric Cardiology of the Albany Medical Center Hospital, Albany, New York, U.S.A.

Bundle of His recordings were obtained from 34 children with congenital heart disease. Except for patients with endocardial cushion defect or L*-transposition of the great arteries recordings were obtained by usual methods. In endocardial cushion defect it was necessary to position the electrode catheter more posteriorly, and in* L*-transposition of the great arteries recordings were obtained in the subaortic region. Both instances reflect anatomical variations in the conduction system previously described.*

The recorded atrial to His depolarization time (AH interval) and the His to ventricular depolarization time (HV interval) were normal in all patients without heart block and tended to increase with age. Two patients with complete heart block after operation were found to have block distal to the His bundle recording site, while in the patients with congenital complete heart block it was proximal to this site.

The recording of bundle of His electrograms had been reported in the intact human heart as early as 1960 when Giraud *et al.* (1960) reported his findings in patients with atrial septal defect. However, it had not been employed widely until Scherlag *et al.* described the catheter technique in 1969. Since that time, the method has been extensively used in the study of AV conduction in adults (Berkowitz *et al.*, 1969; Castillo and Castellanos, 1970; Cohen *et al.*, 1969; Damato and Lau, 1969; Damato *et al.*, 1969a, b, c; Lau *et al.*,1969; Massumi, 1970; Narula and Samet, 1970), and some reports have commented on its use in congenital heart defects (Abella *et al.*, 1972; Brodsky *et al.*, 1971; Cohen, Samet, and Yeh, 1970; Kelly *et al.*, 1972; Roberts and Olley, 1972; Torresani *et al.*, 1969; Watson, Emslie-Smith, and Lowe, 1967).

This study was undertaken to determine the feasibility of obtaining His bundle recordings in complex congenital heart defects, especially those such as corrected transposition of the great vessels and endocardial cushion defects where anatomical abnormalities of the conducting system have been demonstrated. It was also sought to define further the AV conduction in patients with congenital and acquired complete heart block.

Received 2 February 1973.

[1] Supported in part by grants from the National Institutes of Health, Bethesda, Maryland, and from the General Research Support, The Children's Hospital Medical Center, Boston, Massachusetts, U.S.A.

Subjects and methods

His bundle recordings were obtained in 34 children between the ages of 2 months and 18 years (median age =5·5 years) who underwent cardiac catheterization in the postabsorptive state. Diagnoses included ventricular septal defect, atrial septal defect, Fallot's tetralogy, endocardial cushion defect, pulmonary stenosis, complete transposition of the great arteries, corrected transposition of the great arteries, congenital complete heart block, acquired complete heart block, and cardiomyopathy.

Children over the age of 1 year were premedicated with pethidine compound (promethazine, chlorpromazine, and pethidine); children under the age of 1 year received no premedication. The studies were performed using an approach from the lower extremity. Recordings were made using a bipolar or tripolar electrode catheter according to the method described by Scherlag *et al.* (1969). Occasionally a multipolar (3 paired) electrode catheter was used.

Some modification of the method was necessary with reference to catheter placement in order to record the His potential in corrected transposition of the great arteries and endocardial cushion defect. In the former, recordings were obtained in the subaortic region, with the catheter being inserted via the retrograde arterial route or antegradely by entering the subaortic region via a ventricular septal defect. In the latter it was placed in a more posterior position than usual near the tricuspid septal leaflet. In all other defects it was possible to record the His deflection at or near the septal leaflet of the tricuspid valve. Pacing studies at the His bundle and the right ventricular endocardium were undertaken in Case 31 with congenital complete heart block.

The time from atrial to His bundle depolarization (AH interval) was measured from the initial wave of atrial activation recorded with the intracardiac electrode to the first fast wave of His bundle activation. The time from His bundle to ventricular depolarization (HV interval) was measured from the initial fast wave of His activation to the earliest wave of ventricular activation, whether this occurred on the surface electrocardiogram or on the intracardiac electrogram.

Results

The AH intervals varied between 52 and 131 milliseconds (msec), as listed in the Table. There was a tendency for the AH interval to increase with age. The HV intervals varied between 22 and 50 msec, and also showed a tendency to increase with age. The duration of the His deflection (H duration) was 8 to 15 msec.

Abnormalities were found in 2 patients with nodal rhythm (in whom no AH intervals were recorded) and in 6 patients with complete heart block. In 4 patients with complete heart block, the block was found to be proximal to the recorded bundle of His. In all 4, the HV interval was normal, ranging from

TABLE *Heart rate (HR), atrial to His depolarization time (AH), His to ventricular depolarization time (HV), and duration of His deflection (H duration) in the various cardiac defects*

Case No.	*Age*	*Defect*	*Medication*	*HR per min*	*AH (msec)*	*HV (msec)*	*H duration (msec)*
1	3 mth	Ventricular septal defect	Digoxin	166	68	28	11
2	4 mth	Ventricular septal defect	Digoxin	107	60	32	8
3	4 mth	Ventricular and atrial septal defect	Digoxin	187	Nodal	22	8
4	7 mth	Ventricular septal defect	Digoxin, diuretics	107	70	31	8
5	3 yr 8 mth	Ventricular septal defect		136	73	31	12
6	7 yr 11 mth	Ventricular septal defect post-op.	Digoxin	88	91	50	9
7	11 yr	Ventricular septal defect		79	75	38	10
8	11 yr	Ventricular septal defect		93	92	40	8
9	1 yr 7 mth	Atrial septal defect		125	89	36	11
10	5 yr 3 mth	Fallot		100	52	32	10
11	5 yr 7 mth	Fallot		94	63	35	9
12	6 yr 2 mth	Fallot	Digoxin	75	Nodal	50	9
13	7 yr 11 mth	Fallot		75	130	48	11
14	8 yr 6 mth	Fallot		100	98	29	11
15	8 yr 9 mth	Fallot		107	102	40	12
16	10 yr	Fallot		125	62	46	8
17	2 mth	Pulmonary stenosis		150	79	38	15
18	1 yr 7 mth	Pulmonary stenosis		90	80	31	10
19	2 yr 3 mth	Pulmonary stenosis		125	67	22	10
20	3 yr 9 mth	Pulmonary and aortic stenosis		100	70	40	9
21	8 yr 10 mth	Pulmonary stenosis		107	91	41	13
22	9 yr 8 mth	Pulmonary stenosis and persistent ductus arteriosus		88	120	31	13
23	8 mth	D-transposition of great arteries	Digoxin	183	62	39	12
24	8 mth	Cardiomyopathy	Digoxin	136	97	33	13
25	1 yr	Endocardial cushion defect ASD ostium primum	Digoxin, diuretics	125	95	28	10
26	1 yr 6 mth	Endocardial cushion defect ASD ostium primum		125	131	28	10
27	5 yr 9 mth	Endocardial cushion defect	Digoxin	100	105	40	14
28	9 yr	Corrected transposition of great arteries, single ventricle		75	102	30	13
29	7 yr 3 mth	Congenital complete heart block (corrected transposition, ventricular septal defect, pulmonary stenosis)		a=107 v=85	—	35	10
30	5 mth	Congenital complete heart block		a=107 v=48	—	35	10
31	8 yr	Congenital complete heart block		a=80 v=68	—	32	7
32	7 yr 6 mth	Acquired complete heart block, Fallot, post-catheterization		a=104 v=64	—	40	8
33	8 yr 5 mth	Acquired complete heart block (ASD[I], ostium primum, postop.)		a=94 v=47	118	—	15
34	18 yr	Acquired complete heart block (ventricular septal defect, postop.)		a=95 v=47	70	—	15

32 to 40 msec. Of these 4 patients, 2 (Cases 30 and 31) had congenital heart block with no associated cardiac lesions. During His pacing in Case 31, the interval from the stimulus artefact to ventricular depolarization was equal to the HV interval recorded during spontaneous rhythm. Case 29 had complete heart block associated with corrected transposition of the great arteries, a ventricular septal defect, and pulmonary stenosis. One other patient (Case 32) who had Fallot's tetralogy, developed complete heart block proximal to the recorded His bundle during cardiac catheterization.

Two patients were found to have the block distal to the recorded bundle of His; in both cases, the block developed after cardiac surgery. Normal values were found for the AH interval. In Case 33, the block developed during surgical closure of an ostium primum atrial septal defect; Case 34 developed block during surgical closure of a ventricular septal defect.

There were no complications attendant upon the study of the conduction system.

Discussion

The data suggest that the prolongation of the PR interval which occurs with increasing age is related to an increase in both the AH and the HV intervals. This is in agreement with Abella *et al.* (1972) who showed such an age dependent variation in their study of 100 children. Brodsky *et al.* (1971) found that the prolongation occurred proximal to the His bundle, and Roberts and Olley (1972) found that it was distal. Some of the disagreement may relate to the various methods of measurement employed by different authors, for, unfortunately, a uniform method has not been established. The method employed here, using the initial deflection in the intracardiac tracing to indicate the onset of atrial activity, was the same as that used by Roberts and Olley (1972). Even when similar methods are used, slight differences in time intervals may be related to inability to ensure a uniform site of recording using the catheter technique. Measurements of these intervals directly during open heart surgery may help establish normal values with greater accuracy. Studies by Kupersmith *et al.* (1972) using such a technique have demonstrated HV intervals similar to those obtained by catheter.

Anatomical studies have shown the ingenuity of the conduction system in maintaining its integrity despite anatomical abnormalities involving its normal course (Lev, 1959, 1960, 1962; Lev, Licata, and May, 1963). The electrophysiological findings in this study accord with the anatomical evidence. Lev (1962) and Rosenbaum, Elizari, and Lazzari (1970) have described the course of the normal conduction system. They indicate that the atrioventricular (AV) node originates between the coronary sinus and the septal leaflet of the tricuspid valve. The bundle of His begins at the terminal portion of the node and enters the central fibrous body as the 'penetrating portion'. Then, it passes leftward to become the 'branching portion' at the site of the pars membranacea septi from whence it gives off the posterior radiation of the left bundle. It then courses rightward before giving off the anterior division of the left bundle and the single right bundle. In the present study the fact that His bundle recordings were obtained at the tricuspid valve with relative ease from patients with ventricular septal defect and Fallot's tetralogy reflects the more nearly normal anatomy of the initial (penetrating) portion of the bundle. In ventricular septal defect (Lev, 1960) and in tetralogy of Fallot (Lev, 1959) the bundle maintains close proximity to the defect even when the defect involves the site of the pars membranacea.

However, it was more difficult to obtain recordings in patients with endocardial cushion defects, either partial or complete. It was necessary to place the catheter in a more posterior position near the tricuspid septal leaflet. This relates to the location of the bundle in these defects, as described by Lev (1962). The abnormal posterior position of the bundle in cushion defects has notable surgical implications. Not uncommonly complete heart block attends the surgical correction of these defects (Fryda, Kaplan, and Helmsworth, 1971). This complication shows the need for alteration in technique to prevent interruption of the bundle. Catheter recordings have added valuable information concerning the location of the bundle and should indicate the obvious need for direct recordings during the corrective open heart procedures. Kaiser *et al.* (1970) have described this technique in detail. In fact, direct vision recordings are easier to obtain than those obtained by catheter. Such recordings have been undertaken routinely in the repair of partial or complete cushion defects at one of the two centres (AMCH) from which this report originates. The technique has been found efficient, reliable, and helpful in preventing surgical heart block.

Recordings were obtained with great difficulty in corrected transposition of the great arteries, with or without associated defects. The bundle takes a peculiar course in this anomaly, which, as indicated by Lev *et al.* (1963), is longer than normal and is a mirror-image of normal. We obtained His electrograms in 2 patients with corrected transposition by placing the catheter in the subaortic region (Fig. 1), but were unsuccessful in 6 patients with this lesion

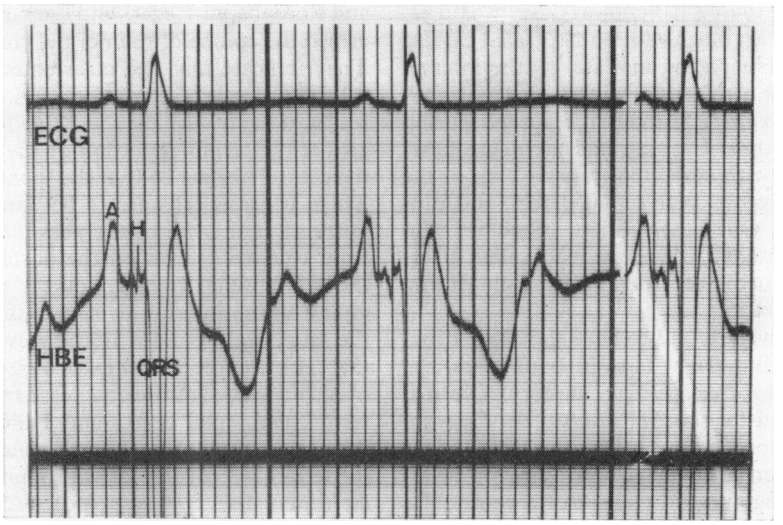

FIG. 1 *Case 28 with corrected transposition of great arteries. Standard electrocardiogram (ECG) and His bundle electrogram (HBE), time lines = 40 msec. Atrial to His depolarization time (AH interval), 102 msec. His to ventricular depolarization (HV interval), 30 msec.*

in recording the His bundle from the right side. This may relate to the abnormal course of the bundle and to its greater accessibility from the left side of the heart. The normal HV interval in our 2 cases indicates that neither the increased length of the bundle nor its peculiar course alters its configuration or conduction time. However, the natural vulnerability of the conduction system in corrected transposition may relate to this course since 3 of the 6 patients studied had either complete AV dissociation or arrhythmias. Friedberg and Nadas (1970) reported an incidence of AV disturbances in 32 per cent of their 60 cases of corrected transposition. Repair of defects associated with this are difficult partly because of the mechanical impediment imposed by the anatomically inverted ventricles and

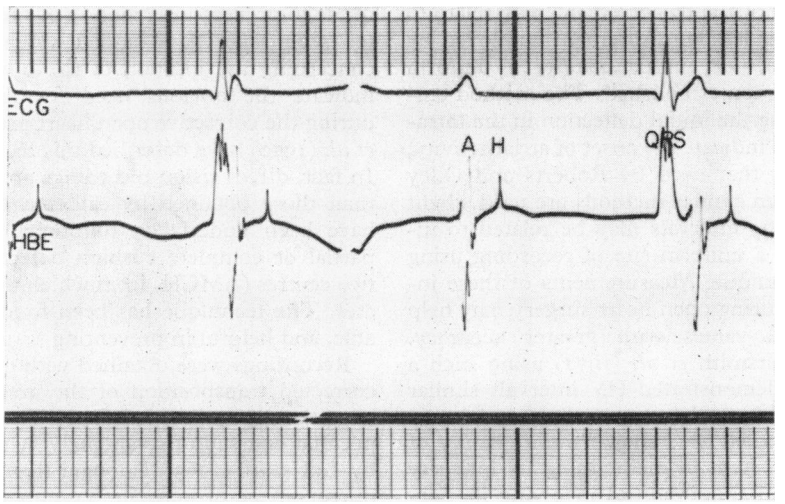

FIG. 2 *Case 33 with surgically acquired complete heart block. Standard electrocardiogram (ECG) and His bundle electrogram (HBE), time lines = 40 msec. AH interval 118 msec. Interruption of conduction occurs distal to the recorded bundle of His.*

partly because of the abnormal course of the conduction system. By combining the information from catheter recordings with intraoperative recordings for delineating the bundle of His, acquired conduction disturbances may be obviated.

In our 2 patients with congenital complete heart block without associated lesions, the site of block was found to be proximal to the His bundle. A QRS complex of normal configuration and duration was found in the standard electrocardiograms of these 2 patients, as well as in the other 2 patients (Cases 29 and 32) with blocks proximal to the bundle of His. However, a narrow QRS complex may also be found when the block is more distal. Of our 2 patients with complete heart block after operation, both were found to have blocks distal to the bundle of His recording. One of these (Case 33, Fig. 2) had a normal QRS configuration on the standard electrocardiogram. This probably represents a focal block within the bundle of His, with the pacemaker being within the lower bundle but distal to the block. The failure to record the latter deflection suggests that the pacemaker must have been very low in the bundle and inaccessible to the catheter electrode.

It is apparent from these studies that His electrograms reflect the anatomical situation in congenital heart disease. In ventricular septal defect and Fallot's tetralogy they lend electrophysiological support to the more normal course of the penetrating portion of the bundle. When gross aberrations of the conduction system are present, as in endocardial cushion defect and corrected transposition of the great arteries, modifications of techniques of recordings are necessary. Catheter methods have helped to locate the conduction system. More importantly, they suggest the value of these electrophysiological studies in the surgical situation where the greatest therapeutic benefit will be appreciated directly.

References

Abella, J. B., Teixeira, O. H. P., Misra, K. P., and Hastreiter, A. R. (1972). Change of atrioventricular conduction with age in infants and children. *American Journal of Cardiology*, **30**, 876.

Berkowitz, W. D., Wit, A. L., Law, S. H., Steiner, C., and Damato, A. N. (1969). The effects of propranolol on cardiac conduction. *Circulation*, **40**, 855.

Brodsky, S. J., Mirowski, M., Krovetz, L. J., and Rowe, R. D. (1971). Recordings of His bundle and other conduction tissue potentials in children. *Journal of Pediatrics*, **79**, 61.

Castillo, C. A., and Castellanos, A. (1970). His bundle recordings in patients with reciprocating tachycardias and Wolff-Parkinson-White syndrome. *Circulation*, **42**, 271.

Cohen, L. S., Samet, P., and Yeh, B. K. (1970). Analysis of A-V conduction in children using His bundle electrograms (abstract). *Circulation*, **42**, Suppl. III, 80.

Cohen, S. I., Lau, S. H., Scherlag, B. J., and Damato, A. N. (1969). Alternate patterns of premature ventricular excitation during induced atrial bigemny. *Circulation*, **39**, 819.

Damato, A. N., and Lau, S. H. (1969). His bundle rhythm. *Circulation*, **40**, 527.

Damato, A. N., Lau, S. H., Berkowitz, W. D., Rosen, K. M., and Lisi, K. R. (1969a). Recording of specialized conduction fibres (A-V nodal, His bundle, and RBB) in man using an electrode catheter technic. *Circulation*, **39**, 435.

Damato, A. N., Lau, S. H., Helfant, R. H., Stein, E., Berkowitz, W. D., and Cohen, S. I. (1969b). A study of atrioventricular conduction in man using electrode catheter recordings of His bundle activity. *Circulation*, **39**, 287.

Damato, A. N., Lau, S. H., Patton, R. D., Steiner, C., and Berkowitz, W. D. (1969c). A study of A-V conduction in man using premature atrial stimulation and His bundle recordings. *Circulation*, **40**, 61.

Friedberg, D. Z., and Nadas, A. S. (1970). Clinical profile of patients with congenital corrected transposition of the great arteries. A study of 60 cases. *New England Journal of Medicine*, **282**, 1053.

Fryda, R. J., Kaplan, S., and Helmsworth, J. A. (1971). Postoperative complete heart block in children. *British Heart Journal*, **33**, 456.

Giraud, G., Peuch, P., Latour, H., and Hertault, J. (1960). Variations de potentiel liées à l'activité du système de conduction auriculoventriculaire chez l'homme (enregistrement électrocardiographique endocavitaire). *Archives des Maladies du Coeur et des Vaisseaux*, **53**, 757.

Kaiser, G. A., Waldo, A. L., Beach, P. M., Bowman, F. O., Hoffman, B. F., and Malm, J. R. (1970). Specialized cardiac conduction system. *Archives of Surgery*, **101**, 673.

Kelly, D. T., Brodsky, S. J., Mirowski, M., Krovetz, L. J., and Rowe, R. D. (1972). Bundle of His recordings in congenital complete heart block. *Circulation*, **45**, 277.

Kupersmith, J., Waldo, A. L., Krongrad, E., Kaiser, G. A., Malm, J. R., and Hoffman, B. F. (1972). Conduction times and velocities in the His-Purkinje system of man—studies during open heart surgery. *Federation Proceedings*, **31**, 313.

Lau, S. H., Damato, A. N., Berkowitz, W. D., and Patton, R. D. (1969). A study of atrioventricular conduction in atrial fibrillation and flutter in man using His bundle recordings. *Circulation*, **40**, 71.

Lev, M. (1959). The architecture of the conduction system in congenital heart disease. Tetralogy of Fallot. *Archives of Pathology*, **67**, 572.

Lev, M. (1960). The architecture of the conduction system in congenital heart disease. Ventricular septal defect. *Archives of Pathology*, **70**, 529.

Lev, M. (1962). The anatomy and pathology of the conduction system in the human heart. *Hebrew Medical Journal*, **1**, 262.

Lev, M., Licata, R. H., and May, R. C. (1963). The conduction system in mixed levocardia with ventricular inversion. *Circulation*, **28**, 232.

Massumi, R. A. (1970). Interpolated His bundle extrasystoles. An unusual cause of tachycardia. *American Journal of Medicine*, **49**, 265.

Narula, O. S., and Samet, P. (1970). Wenckebach and Mobitz type II A-V block due to block within the His bundle and bundle branches. *Circulation*, **41**, 947.

Roberts, N. K., and Olley, P. M. (1972). His bundle recordings in children with normal hearts and congenital heart disease. *Circulation*, **45**, 295.

Rosenbaum, M. B., Elizari, M. V., and Lazzari, J. O. (1970). *The Hemiblocks*. Tampa Tracings, Oldsmar, Florida.

Scherlag, B. J., Lau, S. H., Helfant, R. H., Berkowitz, W. D.,

Stein, E., and Damato, A. N. (1969). Catheter technique for recording His bundle activity in man. *Circulation*, **39**, 13.

Torresani, J., Amichot, J. L., Picard, J. P., and Jouve, A. (1969). Acquisitions récentes dans les techniques d'exploration électrocardiographique des cavités cardiaques. *Archives des Maladies du Coeur et des Vaisseaux*, **62**, 193.

Watson, H., Emslie-Smith, D., and Lowe, K. G. (1967). Intracardiac electrocardiogram of human atrioventricular conducting tissue. *American Heart Journal*, **74**, 66.

Requests for reprints to Dr. Grace S. Wolff, Division of Pediatric Cardiology, Department of Pediatrics, Albany Medical Center Hospital, Albany, New York, 12208, U.S.A.