Case Report

Isolated Intramuscular Cysticercosis: A Case Report

Sujata Kanhere, Manish Bhagat, Varsha Phadke, Riya George

Department of Pediatrics, K. J. Somaiya Medical College, Hospital and Research Centre, Sion (E), Mumbai - 400 022, Maharashtra, India

Submitted: 7 Apr 2014
Accepted: 29 Aug 2014

Abstract

Human cysticercosis is caused by *Cysticercus cellulosae*, larvae of a tapeworm, *Taenia solium*. Cysticercosis can involve any tissue in the body; the most common affected sites are central nervous system, subcutaneous tissue, eyes, and muscles. A few cases of isolated intramuscular cysticercosis without any other tissue involvement have been reported in pediatric population. Here, we report a case of intramuscular cysticercosis diagnosed by ultrasonography in a 5.5 year-old boy who presented with the swellings over the calf and the scapular region, without any associated neurological or ocular involvement. The patient responded well to the course of steroids and Albendazole with complete resolution of both the swellings.

Keywords: *cysticercosis, intramuscular, ultrasonography*

Introduction

Cysticercosis is a parasitic infection caused by *Cysticercus cellulosae*, the larval form of *Taenia solium*. Human cysticercosis is highly prevalent in African, Eastern European, Mexico, and South-East Asian regions (1–3). Cysticercosis involving central nervous system has been commonly described, but it may affect eyes, subcutaneous tissues, liver, skeletal muscle, and at times lung and heart, causing varied clinical manifestations (1–3). Soft tissue cysticercosis lesions are usually described with neurological or ocular involvement (1,4–7). There have been reports of a few cases of intramuscular cysticercosis that did not affect any other organ (2,8–11), although the reports are scarce in the pediatric age group. Here, we describe a case of intramuscular cysticercosis in a 5.5 year-old boy who presented with the swellings at two anatomically different sites, without any associated neurological or ocular involvement.

Case Report

A 5.5 year-old boy presented with a swelling over the right calf noticed for two months and a newly evolving swelling over the right scapular area noticed for 10 days prior to presentation. At both the sites, the swellings were non-tender, non-fluctuant, and non-reducible. The overlying skin appeared normal. The swelling over the right scapular area was nodular, well-defined, and soft to firm (Figure 1), while the swelling over the calf was diffuse, ill-defined, and firm (Figure 2). Clinically, the dimensions measured were 5.5 × 4.5 cm over the right calf and 3.5 × 3 cm in the scapular region. There was no history of cough, fever, or tuberculosis in the patient or among family members. The child was purely a vegetarian. Physical examination and hemogram of the child were normal. Ultrasonography (USG) of both the swellings (right scapular and right calf area) revealed a central cystic part with echogenic scolex in the intramuscular plane suggestive of intramuscular cysticercosis (Figure 3). The dimensions of the cystic lesions measured on ultrasound were 3 × 1.5 cm over the right calf and 2.3 × 0.6 cm over the right scapular area. The computed tomography (CT) scan of the brain and ophthalmic examination were normal. The patient

Figure 1: Swelling over the right scapula.

 © Penerbit Universiti Sains Malaysia, 2015
For permission, please email:mjms.usm@gmail.com

was treated with oral prednisolone for seven days. Albendazole (15 mg/kg/day) was commenced after first three days of steroid and given for 28 days. On follow-ups at second and fourth weeks, the swellings showed reduction in size and no new swellings or symptoms were noticed. There was complete resolution of the swellings at a three months follow-up.

Discussion

Human cysticercosis is a major health concern worldwide. It occurs only in the human host, after ingestion of undercooked pork infected with cysticerci or vegetables contaminated by *T. solium* eggs. *Cysticercus cellulosae*, the larval form of *T. solium,* invades the small intestine. Scolex (head) attaches to the mucosa and begins forming segments containing fertile eggs called proglottids. About two months after infection, gravid proglottids begin to detach from the distal end and are excreted in the feces. After ingestion of the eggs, oncospheres (embryos) in the eggs that are released by the action of gastric acid cross the bowel wall, enter the bloodstream, and are carried to the muscles and other tissues (3). Clinical manifestations depend on the organ involved, extent of involvement, and cysticerci load.

Intramuscular cysticercosis was reported in majority with the disseminated form of the disease (1,4–7). Hence, it warrants investigation to rule out neurological and ocular involvement. In the muscular type of cysticercosis, three different clinical manifestations described are the myalgic type; the mass-like, pseudotumor or abscess-like type; and the rare pseudohypertrophic type (6–8). Our patient presented with clinical nodular, mass-like abnormalities. Patients with the muscular cysticercosis are mostly asymptomatic as was seen in our case. Symptoms like redness, swelling, or pain may be observed after death or degeneration of the parasite with leakage of the antigens and cellular response of the body.

Fine-needle aspiration cytology (FNAC) or fine-needle aspiration biopsy (FNAB) is considered a diagnostic tool for soft tissue cysticercosis, but with the advancement in the imaging techniques, cysticercosis can be diagnosed with ease avoiding any invasive diagnostic methods. On high-resolution USG, cysticercosis usually appears as a cyst with an eccentric echogenic scolex similar to findings noticed in our case; other varied appearances described were (i) with an inflammatory mass around it; (ii) a large irregular collection of exudative fluid within the muscle,

Figure 2: Diffuse swelling over the right calf region.

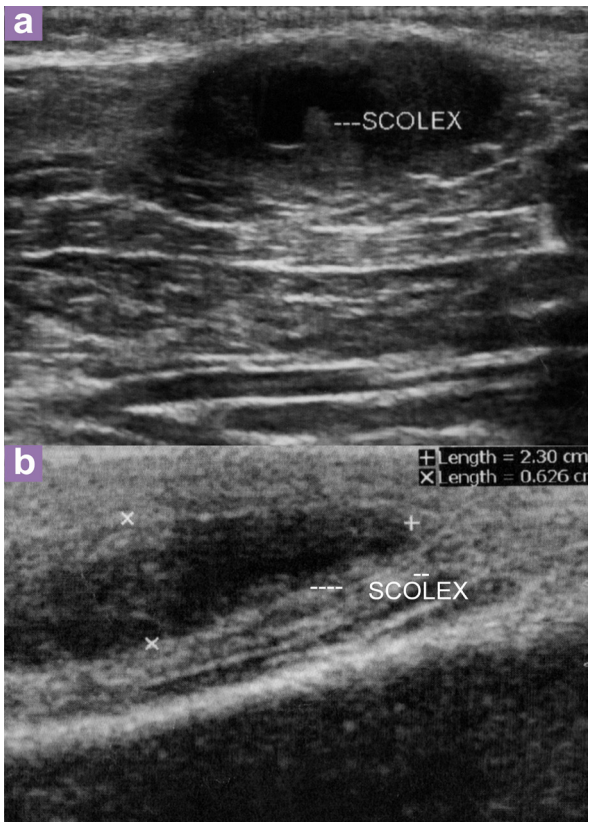

Figure 3: Ultrasonographic appearance of intramuscular cyticercosis. (a) right calf and (b) right scapular region USG showing cystic lesion with scolex.

with the typical cysticercus cyst containing the scolex situated eccentrically within the collection confusing with an intramuscular abscess; (iii) a cyst without echogenic scolex because it might escape outside the cyst, or because of the partial collapse of the cyst; and (iv) a calcified cyst (1,7–11). Magnetic resonance imaging can detect a live cyst; cysticercosis lesions appear hyperintense, with well-defined edges and a hypointense eccentric nodule within the cyst representing the scolex (4–7). Radiograph can depict multiple calcifications in the muscles or subcutaneous tissues if the cysts are calcified (4).

Albendazole and praziquantel are the two commonly used anticysticercal drugs. Steroids should be added to avoid an untoward anaphylactic reaction due to the massive release of larval antigen (5). On clinical grounds, diagnosis of intramuscular cysticercosis is difficult as the presentation may be confused with cystic lesions of echinococcus (hydatid cyst) or coenurus which may be differentiated on imaging (11,12). USG typically shows the floating membranes, daughter cysts, and hydatid sand in cystic echinococcus lesions. Further, hydatid cysts are bigger in size compared to cysticercus lesions. A human coenurus cyst contains numerous scolices. Other differentials for soft tissue cysticercosis include lipoma, epidermoid cyst, fibroma, neurofibroma, myositis, cold abscess or intramuscular abscess (2).

Conclusion

To conclude, the possibility of intramuscular cysticercosis should be thought in endemic regions like ours, whenever a patient presents with a nodule or swelling over the body. USG should be considered as an initial investigation to rule out intramuscular cysticercosis and in doubtful cases invasive techniques such as FNAC or FNAB could be performed for establishing the diagnosis.

Acknowledgement

None.

Conflict of interest

None.

Funds

None.

Authors' Contributions

Conception and design, provision of study materials or patient: SK
Analysis and interpretation of the data, statistical expertise, collection and assembly of data: MB
Drafting of the article: MB, RG
Critical revision of the article for the important intellectual content: SK, MB
Final approval of the article: SK, VP
Administrative, technical or logistic support: VP

Correspondence

Professor Sujata Kanhere
MBBS (LHMC New Delhi), DNB (Pediatrics), DCH (King Edward Memorial Hospital Pune), MNAMS (New Delhi), FRCPCH (London)
Department of Paediatrics
K. J. Somaiya Medical College
Hospital and Research Centre
Mumbai,India
Tel: +9122-2409 0635, +9122-2409 0253
Fax: +9122-2409 1855
Email: drsujatakanhere@gmail.com

References

1. Bothale KA, Mahore SD, Maimoon SA. A rare case of disseminated cysticercosis. *Trop Parasitol.* 2012;**2(2)**:138–141. doi: 10.4103/2229-5070.105183.

2. Ramraje S, Bhatia V, Goel A. Solitary intramuscular cysticercosis-A report of two cases. *Australas Med J.* 2011;**4(1)**:58–60. doi: 10.4066/AMJ.2011.483.

3. Jain BK, Sankhe SS, Agrawal MD, Naphade PS. Disseminated cysticercosis with pulmonary and cardiac involvement. *Indian J Radiol Imaging.* 2010;**20(4)**:310–313. doi: 10.4103/0971-3026.73532.

4. Banu A, Veena N. A rare case of disseminated cysticercosis: Case report and review of literature. *Indian J Med Microbiol.* 2011;**29(2)**:180–183. doi: 10.4103/0255-0857.81787.

5. Bhalla A, Sood A, Sachdev A, Varma V. Disseminated cysticercosis: a case report and review of the literature. *J Med Case Rep.* 2008;**2**;137. doi: 10.1186/1752-1947-2-137.

6. Asrani A, Morani A. Primary sonographic diagnosis of disseminated muscular cysticercosis. *J Ultrasound Med.* 2004;**23(9)**:1245–1248.

7. Bandyopadhyay D, Sen S. Disseminated cysticercosis with huge muscle hypertrophy. *Indian J Dermatol.* 2009;**54(1)**;49–51. doi: 10.4103/0019-5154.48987.

8. Singal R, Mittal A, Gupta S, Gupta R, Sahu P, Gupta A. Intramuscular cysticercosis diagnosed on ultrasonography in thigh: A rare case report. *N Am J Med Sci.* 2010;**2(3)**:162–164.

9. Tripathy SK, Sen RK, Akkina N, Hampannavar A, Tahasildar N, Limaye R. Role of ultrasonography and magnetic resonance imaging in the diagnosis of intramuscular cysticercosis. *Skeletal radiol*. 2012;**41(9)**:1061–1066. doi: 10.1007/s00256-011-1320-2.

10. Sharma P, Neupane S, Shrestha M, Dwivedi R, Paudel K. An ultrasonographic evaluation of solitary muscular and soft tissue cysticercosis. *Kathmandu Univ Med J*. 2010;**8(2)**;257–260.

11. Jain S, Kumar S, Joshi D, Kaushal A. Racemose cysticercosis presenting as cystic neck swelling. *Trop Parasitol*. 2012;**2(1)**:55–57. doi: 10.4103/2229-5070.97241.

12. Basarir K, Saglik Y, Yildiz Y, Yetis T, Cebesoy O. Primary muscular hydatidosis mimicking soft tissue tumour: a report of five cases. *J Orthop Surg (Hong Kong)*. 2008;**16(3)**:368–372.