Case Report

Case of Pseudoaneurysm Mimicking a Soft Tissue Sarcoma: A Diagnostic Pitfall

Sandeep Albert, Sanju Daniel, Mohamad Gouse, Vinu Mathew Cherian

Submitted: 6 Mar 2014
Accepted: 22 Jun 2014

Department of Orthopaedics, Unit 1, Christain Medical College, Vellore , 632004, Tamil Nadu, India

Abstract

Pseudoaneurysms represent a pulsating encapsulated hematoma in communication with the lumen of a ruptured vessel. We present a 33-year-old male with a pseudoaneurysm of the profunda femoris artery. At presentation and on further evaluation, he was diagnosed with a possible soft tissue sarcoma of the distal thigh. Catastrophic haemorrhage occurred at the time of a planned, elective open biopsy. This case report emphasises the importance of considering pseudoaneurysm as a crucial differential diagnosis in atypical swellings and scrutinising all suspected soft tissue tumours with a contrast study or a Doppler ultrasound.

Keywords: *pseudoaneurysm, soft tissue sarcoma, haematoma, foreign body, soft tissue injuries*

Introduction

A pseudoaneurysm or false aneurysm occurs after a disruption in arterial wall continuity, with blood dissecting into surrounding soft tissues without an arterial wall incorporated in the aneurismal sac (1). The causes of a pseudo aneurysm include iatrogenic, traumatic, neoplastic, infective, vasculitic, and inflammatory aetiology. Traumatic pseudoaneurysms are more common around the knee and elbow (2). They can occur following blunt or penetrating trauma. The clinical scenario may mimic a soft tissue tumour (2,3). In the lower limb, pseudoaneurysms mimicking a soft tissue tumour have been described arising from the popliteal artery, distal femoral artery, and the anterior tibial artery (2,4). We describe a case of post-traumatic pseudoaneurysm involving the profunda femoris in the posterior aspect of the thigh, which was initially misdiagnosed as an aggressive soft tissue tumour.

Case Report

A 33-year-old farmer presented to our orthopaedic clinic with complaints of pain and swelling over the back of the right thigh with deformity of the right knee and progressive weakness of the left lower limb for three months. Five months earlier, he had sustained a penetrating injury with a bamboo stick following an assault. Two months after his wounds healed, he developed progressive pain, swelling and difficulty walking. His pain and swelling had rapidly increased over a period of three weeks with associated deformity of the knee and weakness of the foot and ankle. He was wheelchair bound at the time of presentation.

He was thinly built, poorly nourished, cachexic, and pale. He had a diffuse swelling measuring 15 × 20 cm over the posteromedial aspect of the right thigh extending from mid to distal thigh. The skin over the swelling was stretched with dilated veins and a 2 cm scar over the posteromedial aspect of the mid thigh. The swelling was tender, warm with ill-defined margins, not fluctuant, not pulsatile, immobile, and variegated in consistency. There was no palpable thrill and no bruit. The knee was flexed to 90 degrees and any passive movement was painful. His foot was flail with grade zero power and with sensations preserved. Dorsalis pedis and posterior tibial pulsations were palpable. A clinical diagnosis of a soft tissue sarcoma was considered and he was appropriately investigated.

His laboratory investigations showed haemoglobin at 8.7 g%, total count 9600/mm3 and an elevated erythrocyte sedimentation rate (ESR). The plain radiograph showed a soft tissue shadow in the posterior aspect of the right thigh with no calcification, erosion or scalloping of the femur (Figure 1). A magnetic resonance imaging (MRI) examination of the thigh showed a multiloculated, ill-defined, and heterogeneously short tau inversion recovery (STIR) (fat suppression) hyperintense lesion,

 © Penerbit Universiti Sains Malaysia, 2015
For permission, please email:mjms.usm@gmail.com

measuring 17 × 12 × 10 cm, involving the posterior intramuscular compartment. The lesion enclosed the neurovascular bundle with no evidence of thrombosis. The lesion was predominantly hyperintense in T2 images with multiple thick internal septations noted. T1 images were isointense with the surrounding muscle. The findings were suggestive of a soft tissue sarcoma (Figure 2a, 2b). A contrast study was not done. Outpatient needle biopsies on two separate occasions were inconclusive and the patient was subsequently scheduled to undergo an open biopsy.

Under spinal anaesthesia, with the patient prone and under tourniquet, an open biopsy was performed incorporating the posteromedial scar. A large hematoma was encountered and evacuated with proximal extension. A 4 cm bamboo stick was retrieved from within the clots (Figure 3). The swelling appeared to have decompressed and reduced in size, and the wound was closed over a drain. When the tourniquet was released and the patient turned supine, he rapidly became tachycardic and hypotensive. A massive haemorrhage soaking through the dressing was evident. A tourniquet was quickly reapplied and the patient was aggressively resuscitated. Upon re-exploration with a vascular team, an active bleeder was discovered from the profunda femoris, which was ligated, and the wound was closed over drains. Post-operatively, his lower limb was well perfused and his knee deformity improved with physiotherapy. The histopathological examination was consistent with an organising haematoma.

Discussion

The region around the knee is the most common site for a post-traumatic pseudoaneurysm (4). A pressure effect of an expanding pseudoaneurysm is the cause of the majority of symptoms, and the timing of decompressive surgery is important (5). Post-traumatic pseudoaneurysm usually presents as an expansile, painful and warm mass near the site of trauma, which may be pulsatile with or without compromised distal pulse. Its presentation may be delayed (6–9). Plain radiographs in this patient did not reveal any bony erosions or scalloping apart from a large soft tissue component.

In reports by Erler et al. (2), and Kim et al. (4), the diagnosis of peripheral pseudo aneurysms was not straightforward. A pre-operative MRI helped by offering additional information on the extent and nature of the suspected lesion (10). Using MRI criteria, malignancy can be predicted

Figure 1: Lateral X-ray of the right thigh showing the soft tissue shadow and normal bone.

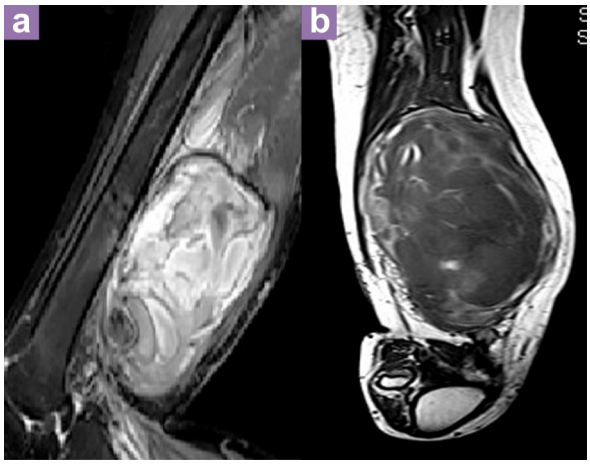

Figure 2: (a) T2 STIR sagittal image: heterogeneous hyperintense soft tissue lesion separate from the femur. (b) 1 image: isointensity of the soft tissue lesion with the surrounding muscle.

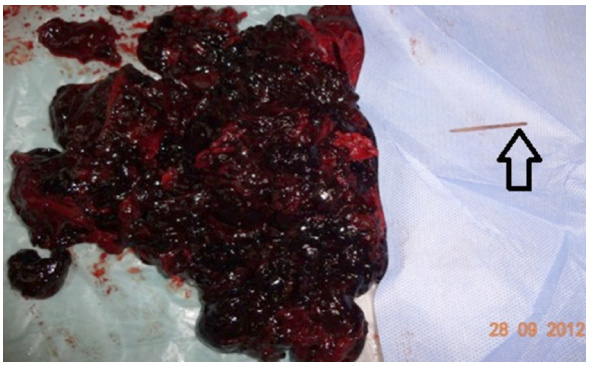

Figure 3: Intraoperative photograph: bamboo stick (arrow) and clots.

with the following four parameters (10):

1. Heterogeneous signal intensity in a T1 scan
2. Tumour necrosis
3. Bone or neurovascular involvement
4. Mean diameter 66 mm.

A contrast study in MRI is helpful when assessing recurrence and is not routinely advocated for the evaluation of soft tissue sarcomas (11). The MRI findings in this patient were confounding with these criteria. Classically, MRI findings in a soft tissue sarcoma are characterised by intensity similar to muscle on T1-weighted images and an intermediate to high signal relative to fat on T2-weighted images (12). Concurrently, in a chronic haematoma, T1 images are heterogeneous. Large areas of necrosis are similar in appearance and character to a chronic haematoma. Considering the size in our patient, the diameter was much higher than 66 mm (13,14).

In a high quality retrospective study involving 571 consecutive patients with suspected soft tissue sarcoma, such criteria lacked desired sensitivity and specificity to distinguish between malignant and non-malignant pathologies (12). The significance of this study was highlighted in a commentary where C J Wakeley noted the shortcomings of MRI in distinguishing between malignant and non-malignant lesions and the poor specificity using prior standard criteria (size/deep fascia) (15).

Newer modalities in MR imaging, such as dynamic, contrast-enhanced MRI characteristics, diffusion weighted MRI, MRI-guided diffuse optical spectroscopy and other conventional MRI spectroscopy techniques, may help achieve better characterisation of soft tissue pathology. Differentiation of a chronic haematoma from an aggressive tumour with large areas of necrosis can be difficult. In such a case, contrast enhanced/diffusion-weighted imaging (DWI) may be helpful. Such modalities are not universally available (15,14).

Using conventional criteria, our patients' imaging was consistent with an aggressive soft tissue tumour. A pseudoaneurysm was not considered in the diagnosis. The overall clinical picture was highly in favour of an aggressive soft tissue sarcoma. However, a few clues and leads were ignored. Despite the overall clinical picture favouring an aggressive soft tissue sarcoma with cachexia and local pressure effects, there was no evidence of metastasis at presentation. The plain radiographs failed to show erosions or scalloping, and there were no bone marrow changes in the MR images. However, such changes are not universal in all soft tissue tumours or pseudoaneurysms.
Two major drawbacks were the lack of a Doppler evaluation and the absence of a concurrent imaging with contrast. If these had been performed, they might have altered the course of events. A significant reason for the lapse in our diagnosis might have been the standard MRI protocols, which do not recommend the routine use of contrast. MRI protocols in another large series involved (12) the following:

1. Coronal and sagittal spin-echo (SE) T1-weighted sequence (repetition time (TR)/echo time (TE) 450–500 ms/15–20 ms)
2. Coronal and sagittal STIR; TR/TE (4800–5500 ms/30–150 ms)
3. Axial fat-suppressed dual-echo fast SE (FSE) sequence to incorporate both proton density (TR/TE 3500 ms/12 ms) and T2-weighted (TR/TE 3500 ms/84–108 ms) images

The basic minimum number of sequences involved a combination of T1-weighted and either STIR or fat-suppressed T2-weighted sequences. A contrast study was not performed (12). The initial imaging modality of choice in a pseudoaneurysm is a duplex ultrasound. A computed tomography angiography allows better visualisation and pre-operative planning (1). We did not order a duplex ultrasound because we did not suspect pseudoaneurysm. As per National Institute for Health and Clinical Excellence NHS[Ed1] guidelines, MRI with contrast is not routinely indicated when evaluating a soft tissue sarcoma. It is also not a routine protocol in our centre (16). In hindsight, in patients with 'a reasonable diagnostic dilemma', additional imaging modalities prior to attempting an invasive procedure may be warranted.

Many months following surgery, the MR images were shown to another senior radiology consultant who was unaware of the case. Yet again, the second opinion revealed that MR features were suggestive of a soft tissue sarcoma; however, a Doppler screening was suggested prior to any intervention.

Conclusion

Pseudoaneurysm should be considered in

any aggressive, atypical swelling. Additional evaluation is useful when there are doubts or contradictory findings in prior investigations. A contrast study (DWI) and/or a Doppler evaluation is suggested in the evaluation of all suspected soft tissue tumours prior to an invasive procedure.

Acknowledgements

The authors are indebted to Dr Sunithi Alexander Mani, Department of Radiodiagnosis, for her help with this manuscript.

Conflict of Interest

None.

Funds

None.

Authors' Contributions

Drafting of the article: SA
Critical revision of the article for the important intellectual content: MG
Final approval of the article: VMC
Provision of study materials or patient: SD

Correspondence

Dr Mohamad Gouse
MBBS (Pondicherry University), MS Ortho (MGR University, India)
Department of Orthopaedics , Unit 1
Christian Medical College
Vellore 632004, Tamil Nadu
India
Tel: + 91- 7598387281
Email: gousemohamad@yahoo.com

References

1. Sueyoshi E, Sakamoto I, Nakashima K, Minami K, Hayashi K. Visceral and peripheral arterial pseudoaneurysms. *AJR Am J Roentgenol*. 2005; **185(3)**:741–749.

2. Erler K, Ozdemir MT, Oguz E, Basbozkurt M. Does false aneurysm behave like a sarcoma? Distal femoral arterial false aneurysm simulated a malign mesenchymal tumor. A case report and review of the literature. *Arch Orthop Trauma Surg*. 2004;**124(1)**: 60–63. doi: 10.1007/s00402-003-0595-8.

3. Gantz ED, Sweet MB, Jakim I. False aneurysm mimicking an aggressive soft-tissue tumor. A case report. *J Bone Joint Surg Am*. 1988;**70(7)**:1090–1092.

4. Kim YJ, Baek WK, Kim JY, Park SW, Jeon YS, Lee KH, et al. Pseudoaneurysm of the popliteal artery mimicking tumorous condition. *J Korean Surg Soc*. 2011;**80(Suppl 1)**:S71–74. doi: 10.4174/jkss.2011.80.Suppl1.S71.

5. Robbs JV, Naidoo KS. Nerve compression injuries due to traumatic false aneurysm. *Ann Surg*. 1984;**200(1)**: 80–82.

6. Dickson JW. False aneurysm after intramedullary nailing of the femur. *J Bone Joint Surg Br*. 1968; **50(1)**: 144–145.

7. Scotti C, Marone EM, Brasca LE, Peretti GM, Chiesa R, Del Maschio A, et al. Pseudoaneurysm overlying an osteochondroma: a noteworthy complication. *J Orthop Traumatol*. 2010;**11(4)**:251–255.

8. Dympep B, Khangarot S, Hadke N. An unusual presentation of traumatic pseudoaneurysm of axillary artery mimicking soft tissue tumor. *J Surg Case Rep*. 2012;**2012(10)**:17. doi: 10.1093/jscr/2012.10.17.

9. Keller PM, Simon MS. Post-traumatic false aneurysm simulating a soft tissue tumor. *Orthopedics*. 1988; **11(4)**:641–643.

10. Costa FM, Ferreira EC, Vianna EM. Diffusion-weighted magnetic resonance imaging for the evaluation of musculoskeletal tumors. Magn Reson Imaging *Clin N Am*. 2011;**19(1)**:159–80. doi: 10.1016/j.mric.2010.10.007.

11. Barile A, Caulo M, Zugaro L, Di Cesare E, Gallucci M, Masciocchi C. Staging and restaging of soft tissue sarcoma using MRI: usefulness of contrast media. *Radiol Med*. 2001;**101(6)**:444–455.

12. Datir A, James SLJ, Ali K, Lee J, Ahmad M, Saifuddin A. MRI of soft-tissue masses: the relationship between lesion size, depth, and diagnosis. *Clin Radiol*. 2008; **63(4)**:373–378. doi: 10.1016/j.crad.2007.08.016.

13. Hanna SL, Fletcher BD. MR imaging of malignant soft-tissue tumors. *Magn Reson Imaging Clin N Am*. 1995;**3(4)**:629–650.

14. Subhawong TK, Durand DJ, Thawait GK, Jacobs MA, Fayad LM. Characterization of soft tissue masses: can quantitative diffusion weighted imaging reliably distinguish cysts from solid masses? *Skeletal Radiol*. 2013;**42(11)**:1583–1592. doi: 10.1007/s00256-013-1703-7.

15. Wakeley CJ. MRI of soft-tissue masses: the relationship between lesion size, depth, and diagnosis. *Clin Radiol*. 2008;**63(4)**:379–380. doi: 10.1016/j.crad.2007.08.016.

16. National Institute for Health and Clinical Excellence (Great Britain). Guidance on cancer services: improving outcomes for people with sarcoma: the manual. London (LN): National Institute for Health and Clinical Excellence; 2006.