THE MOTION OF THE THORAX DURING THE HEART CYCLE: A COMPARISON OF LONGITUDINAL, LATERAL AND DORSO-VENTRAL BALLISTOCARDIOGRAMS[1]

By J. LEONARD BRANDT, ANTHONY CACCESE, WILLIAM DOCK, AND ALVIN SCHRAGER

(From the Department of Medicine, State University of New York, College of Medicine and the Kings County Hospital, Brooklyn, N. Y.)

(Submitted for publication March 13, 1951; accepted June 30, 1951)

The lateral motion of the body during the cardiac cycle has been observed by Yandel Henderson and others who recorded the motion of a table on which the subject reclined (1). Antero-posterior, lateral and longitudinal recording (2), and recording of lateral motion at three levels simultaneously with the longitudinal ballistocardiogram (3) also has been carried out with the table method but in each case only a few records have been reproduced. When motion was recorded from three points along the side of a table, the foot moved in the opposite direction from the head and shoulders (3). It is therefore to be expected that records of lateral motion of the entire body will have less amplitude than records of motion at the level of the chest.[2]

With the introduction of photoelectric and electromagnetic methods (4) for recording the longitudinal ballistocardiogram directly from the body it was logical to attempt recordings of lateral thoracic motion by these methods for the purpose of determining possible "typical patterns" for the various congenital cardiac anomalies associated with right to left or left to right shunts. The lateral motion of the body may be recorded from any desired point, but we consider motion at the thoracic level of the greatest interest, and the level of the xiphoid process in the right midaxillary line the most useful and reproducible. Recordings from a similar position on the left may be interfered with by the apex thrust when the heart is large.

Using multichannel apparatus we have recorded the right lateral ballistocardiogram simultaneously with the electrocardiogram and longitudinal ballistocardiogram in 50 subjects without valvular disease, in 20 subjects with various congenital cardiac anomalies, and in a few subjects with acquired valvular disease. The electromagnetic pick-up, filtered to reduce somatic tremor, gives waves coinciding in time with those recorded simultaneously by the photoelectric method of the Starr table.

Lateral or dorsoventral records can be made with electromagnetic pick-ups with a hinged arm on which the coil moves in relation to a fixed magnet, or the magnet on a hinge moves in relation to a fixed coil. Contact can be made directly, with the hinge touching the body and swinging in the chosen plane. We have found the best contact is made by mounting a ball-point so as to project from the hinge in the line of motion and by fixing a glass slide over the surface of the skin at the chosen point. This gives a frictionless contact when the surface of the slide is parallel to the sagittal and longitudinal axis of the body and prevents picking up motion in any but the lateral direction; when parallel to the horizontal plane and longitudinal axis, only dorsoventral motion is recorded. (See Figure 1; A, B and C.)

The direct recording ballistocardiogram can be standardized in terms of either velocity or bodily motion. By applying tension to the body, and releasing the tension, the relation of displacement to applied force can be quantitated for each patient just as can be done for various table methods. On the average, the displacement of the body in a longitudinal ballistocardiograph on the direct method gives a 1 cm. deflection or 1 mv. of current, when a pull of 125 to 150 grams applied by cords over the shoulders is released. In the lateral plane, standardization is less simple. In general when the longitudinal and lateral records are recorded simultaneously lateral waves are recorded at 2–4 mm./mv. and longitudinal at 1 cm./mv. At these settings the largest waves have about the same amplitude. A similar ratio exists between dorsoventral and longitudinal recordings. Since no need for quantitation arose in our work, this matter has not been pursued. We are interested in relative size and timing of waves, not in the absolute force represented by a

[1] Supported by a grant from Federal Security Agency, Public Health Service, National Institutes of Health, Bethesda, Maryland.

[2] Scarborough and associates (2) suggest the use of antero-posterior ballistocardiograms, in concordance with radiologic practice, rather than use of dorsoventral, as used by Hamilton, Dow and Remington (1), or by Braunstein, Oelker and Gowdy (3). There are two disadvantages—lack of precision, since antero-posterior axes of quadrupeds and bipeds are at right angles, and three extra syllables. We adhere to the original and the more precise and concise terminology. In all tracings in this report, headward, rightward and ventral motion are upward deflections.

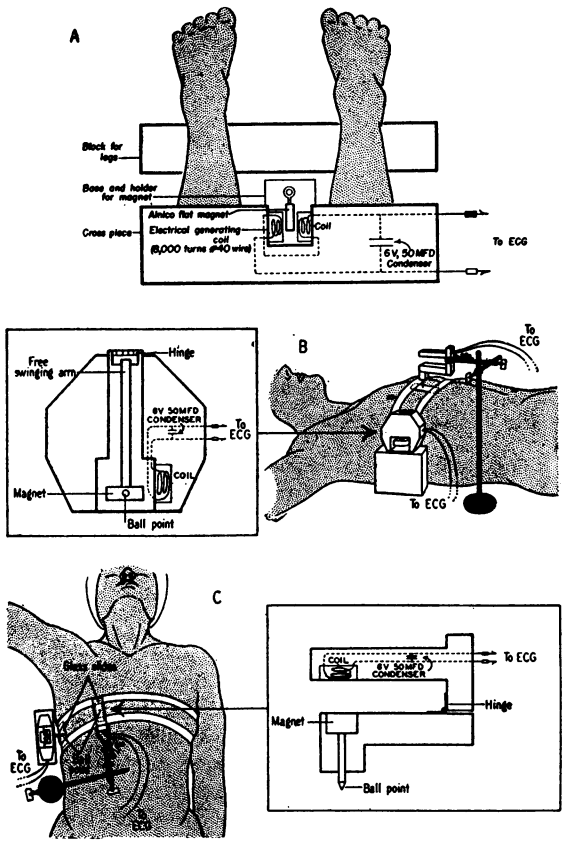

FIG. 1

A. Positioning of ballistocardiograph across shins for recording the longitudinal ballistocardiogram. A block is placed under the Achilles tendon to raise the thighs off the table to minimize damping by friction. *B* and *C*. Positioning of ballistocardiographs for recording the lateral and dorsoventral ballistocardiogram. A fourth channel (not shown) records the electrocardiogram simultaneously.

given wave. All longitudinal traces were recorded at 1 cm./mv., laterals and dorsoventral traces at a sensitivity which gave easily read curves. This rarely was more than 4 or less than 2 mm./mv.

The fact that thoracic motion caused voltage changes two to five times as great as longitudinal motion of the entire body does not mean that the forces in the lateral and dorsoventral directions are greater than those in the longitudinal plane. The force actually reaches the skeleton through the mediastinum, and motion of the thorax in the lateral and dorsoventral directions is great because the thoracic cage can respond to mediastinal tugging without equally great motion of the entire skeleton in the lateral and dorsoventral directions, but not in the longitudinal direction, where the skeleton is far more rigid. With a table, which records the total force acting on the entire body, lateral and dorsoventral motion will be far less than in direct thoracic records.

As seen in Figure 2, tracings from the optimal point (right midaxillary line at the level of the xiphoid) show larger and more regular waves with fewer small oscillations than those taken 10 cm. cephalad or caudad. The direction and timing of all the main waves in these positions are similar. The point giving greatest amplitude will vary from subject to subject depending upon body build, or even in the same subject with respiration suspended in different phases of respiration. As is evident in Figures 3 and 5, the position of the rib cage and diaphragm has far more effect on the lateral than on the longitudinal ballistocardiogram. The effect is chiefly on the amplitude of the waves,

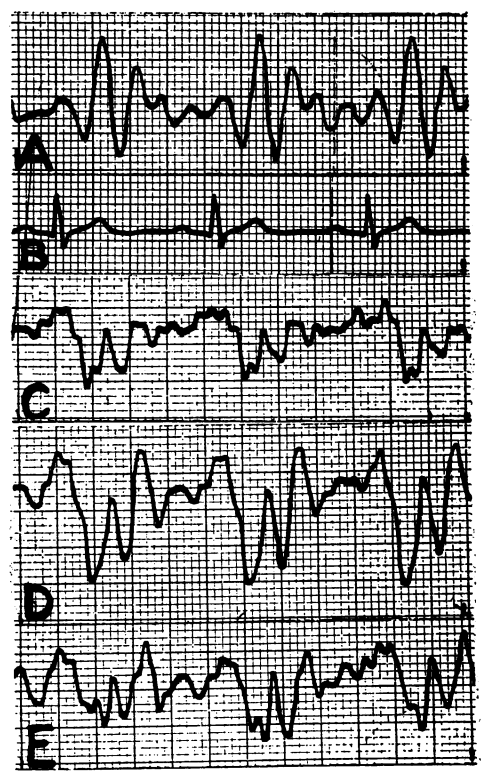

FIG. 2

A. Longitudinal ballistocardiogram. *B*. Simultaneous electrocardiogram. *C*. Right lateral ballistocardiogram recorded 10 cm. cephalad to the level of the xiphoid. *D*. Right lateral ballistocardiogram at the level of the xiphoid. *E*. Right lateral ballistocardiogram 10 cm. caudad to the xiphoid. All records were made from the most lateral point on the thorax which was about in the midaxillary line. In these traces rightward motion coincides with the headward H and J, leftward with the footward I and K. Lateral traces lined up by their coinciding electrocardiograms.

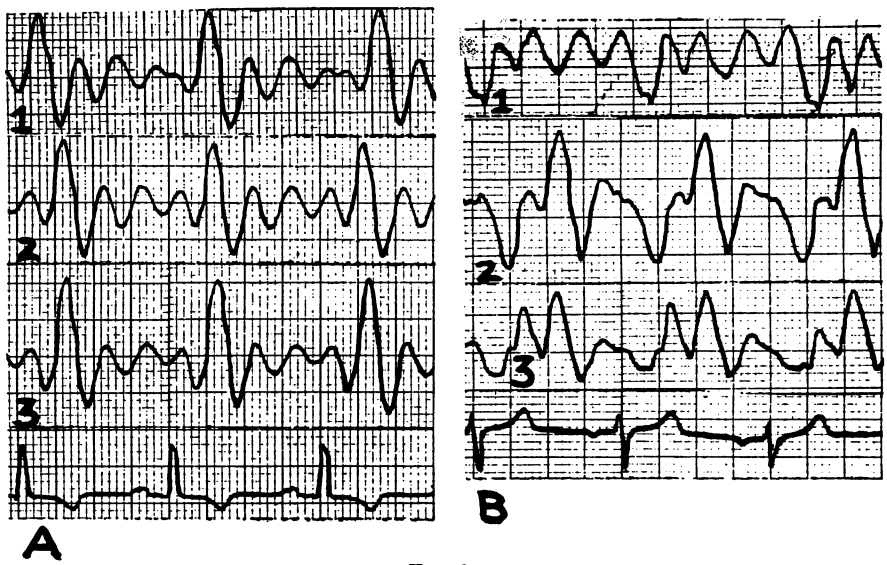

FIG. 3

Group *A* are longitudinal tracings. Group *B* right lateral traces. Tracings *A1* and *B1* taken in deep inspiration; *A2* and *B2* tracings during mid-position of respiration; *A3* and *B3* tracings during deep expiration. Lower tracings of *A* and *B* are the electrocardiograms fitting the tracings. The respective longitudinal and lateral tracings were taken simultaneously. Marked changes in the lateral traces occur with only slight changes in the longitudinal. Usually the I–J amplitude is larger in held inspiration than in expiration. In this experiment with deep inspiration there was sufficient Valsalva effect to cause a relative decrease in I–J amplitude.

not on their direction or on the time relation of peaks and troughs to those recorded in the longitudinal plane.

Curves obtained by high frequency tables moving laterally may show leftward motion synchronous with the headward H and J waves (2, 3), although Hamilton and associates present, as a characteristic curve, rightward and dorsal motion synchronous with the J wave (1). The latter relationship is what one would predict from the rightward and dorsal path of the jet of blood in the aorta, and this is the relationship usually seen in direct records of lateral motion of the thorax. It seemed possible that torsion of the thorax might occur, and in flat-chested people this might result in apparent leftward motion of the lateral convexity even though the thorax as a whole was moving to the right. If the torsion rolled the supine body to the right, the table would be pushed to the left, thus explaining the relative frequency of leftward motion of the table synchronous with the headward J waves.

We attempted to investigate the possibility of torsion by making records of vertical motion in the right and left mid-clavicular lines at the level of the xiphoid. Even on a hard surfaced table (Fig-

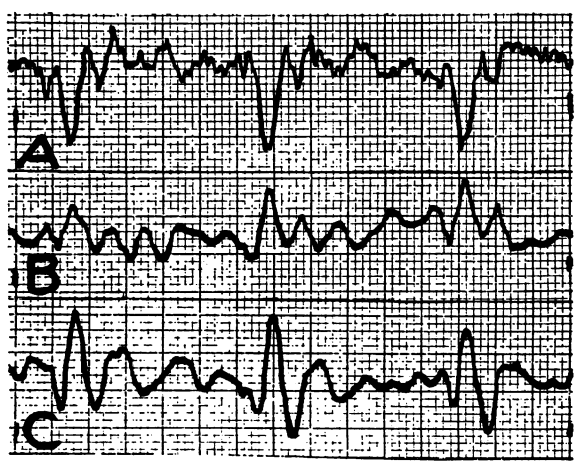

FIG. 4

A. Vertical motion of the thorax in the right midclavicular line at the level of the xiphoid. *B*. Simultaneous right lateral tracing. *C*. Simultaneous longitudinal tracing. Note sharp posterior motion simultaneous with rightward and headward J wave. The left vertical shows slight ventral motion at this time, but is distorted by the apex thrust which precedes it.

ure 4), the thorax does move dorsally during systole, and in most cases this movement is more marked on the right side. No actual ventral motion of the left hemithorax was recorded, although dorsal motion ended sooner than on the right, and a return to the base line occurred during headward inscription of the J wave. In some subjects the right dorsal motion is synchronous with the I wave rather than with J. With simultaneous table and direct lateral recording, this problem can be solved. Meanwhile it must be borne in mind that torsion acting on a table may either exaggerate or reverse the force due to actual lateral displacement when the body is supine or lying on one side.

Not infrequently, rather small lateral waves coincide with major systolic waves in the longitudinal tracing. In subjects without heart disease, rightward waves of significant amplitude coincided with the headward H wave in 57% of our tracings, but in 12% there was a leftward wave of comparable amplitude. Synchronous with the footward I wave in the longitudinal ballistocardiogram was a significant leftward wave in 45% and a rightward wave of comparable amplitude in 8% of the lateral records; rightward waves with the headward J wave appeared in 30% of the tracings and a corresponding leftward wave in 12%. Whether the motion opposite to that expected is due to torsion of the body or true displacement was not determined, but in two of these cases torsion did occur, as shown by dorsoventral records from the right and left midclavicular regions.

Poor correspondence of the longitudinal K wave with lateral waves was to be expected, since K is inscribed by forces generated as the blood is decelerated in the descending aorta, with minimal lateral component. Actually leftward motion was obvious in 10% and rightward in 4%, at the time the footward K wave was being inscribed. Rightward waves of significant amplitude coincided with the longitudinal L wave in 25% of the tracings, and corresponding leftward waves in 16%. The relative size of lateral waves decreased from H to I, I to J, and J to K, and then increased with L. As the auriculoventricular axis lies in a more transverse plane than the ventriculoarterial, lateral forces incident to systolic ejection might be relatively small, and those associated with venous pulse waves or with rapid ventricular filling relatively large. The latter would cause the large diastolic displacements of the lateral ballistocardiogram. Not infrequently a straight line in the lateral ballistocardiogram occupied the time covered by large waves in the longitudinal ballistocardiogram (Figure 5E). While the diastolic waves in the longitudinal ballistocardiogram rarely exceed the

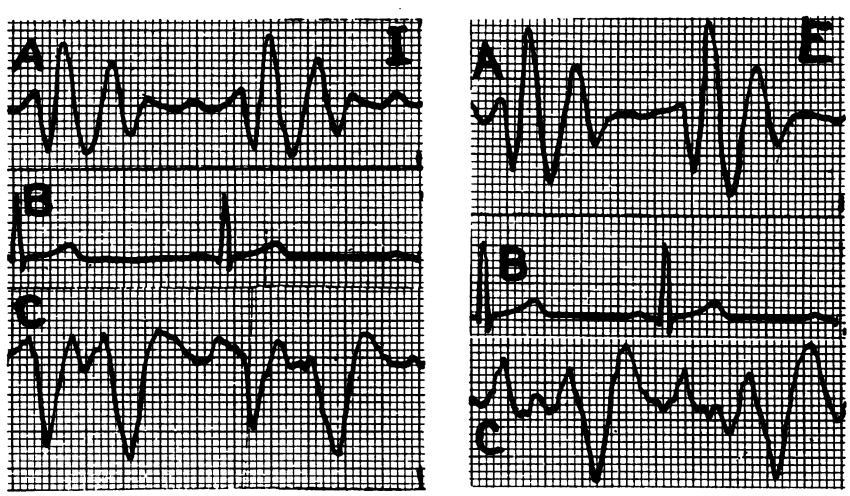

FIG. 5

In Figures 5–10: *A*. Longitudinal ballistocardiogram. *B*. Electrocardiogram. *C*. Right lateral ballistocardiogram.

Here, the left group of traces were taken in deep held inspiration, and the right group in deep held expiration. The diastolic waves are larger than systolic in the lateral trace, and much more altered by respiratory phase.

systolic waves in amplitude, this is quite often noted in the lateral records (Figure 3 [mid-position], Figure 5E).

It is tempting to relate waves in the ballistocardiogram with the motion of the heart, and especially with the apex impulse at the onset of systole. Experimental studies account for all the waves of the I–J–K complex without any apex impulse (5) and the H wave often is tall in cases of heart disease in which an apex beat is not palpable. In the lateral ballistocardiogram there is seen, in rare instances, a sharp rightward motion synchronous with the H wave and possibly due to recoil from the apex thrust. Sudden leftward motion is also occasionally recorded at the same point in systole in other subjects (Figure 6). No such abrupt motions are ever noted in other parts of the cycle, or in longitudinal traces. The subjects who exhibit such abrupt motion do not have unusually forceful apex beats; in some no thrust is palpable.

Of interest are the tracings from a patient with multiple valvular lesions and an enormous heart which fills almost the entire chest cavity. This patient exhibits an extremely forceful apex beat. Her longitudinal tracing reveals slurred and notched J wave and a very deep M wave, with a total of three marked upward and downward waves

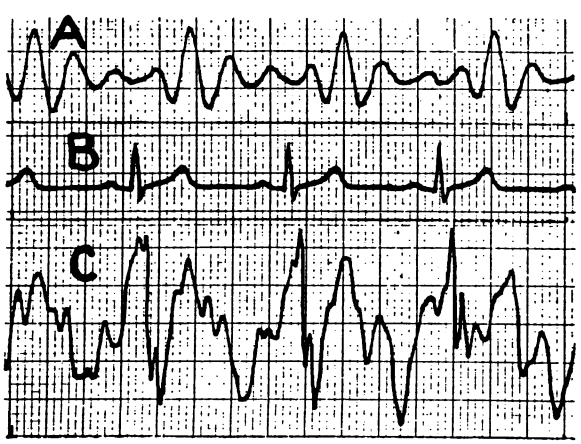

FIG. 6

Note the sharp leftward motion (downward on the trace) synchronous with the H wave. Such abrupt motion is only found in lateral traces, is rarely rightward, and while it occurs with isometric contraction there is no apparent relation of such a motion to a violent apex thrust. In this subject the apex thrust was not visible and was barely palpable.

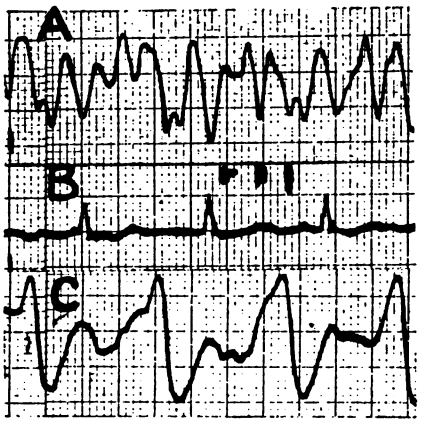

FIG. 7

From a patient with a violent apex thrust and a huge heart, due to rheumatic valvular disease. Dots on the electrocardiogram show approximate times of first, second and very loud third heart sounds. Comment in text.

in each cycle. The lateral ballistocardiograms (Figure 7) show only one wave per cycle with no significant motion synchronous with the apex beat or the J wave. There is slow rightward motion in late systole, accelerated rightward motion synchronous with L and a steep and deep leftward wave synchronous with the footward M wave and with a loud protodiastolic gallop. Her longitudinal ballistocardiogram recorded from the shin electromagnetically in 1951 is identical with that recorded from the head with a pulse recorder in 1948 (see Figure 1 in reference 6).

The longitudinal ballistocardiogram of a patient with complete heart block showed no waves related to auricular beats, and the I–J–K–L complexes varied only slightly with P–R intervals ranging from 0.16 to 0.80 seconds. The lateral traces were much the same with P–R intervals of 0.16 to 0.30 seconds, but quite different with intervals of 0.52 and 0.64 seconds (Figure 8). Auricular beats coinciding with the phase of early diastolic filling greatly augmented early diastolic rightward motion (L wave), which was much larger than any of the other waves, while auricular beats 0.16 to 0.30 seconds before the R wave produced a leftward displacement which was sustained throughout the entire I–J–K complex. Auricular waves in mid-diastole produced a rightward and then a leftward displacement.

Of special interest were the tracings on one elderly man with myxedema (Figure 9), and of

FIG. 8

From a case of complete heart block; a, in lateral trace, marks auricular complexes in mid-diastole. Comment in text.

another with angina pectoris following myocardial infarction (Figure 10). Both had featureless small waves in the longitudinal tracings, and very definite large waves in the laterals. One reason for this may be in the difference in natural vibration of the body in the longitudinal and lateral directions. While the frequency is about the same, damping of after waves is much greater in the lateral when the left chest wall is tapped, than in the longitudinal when the shoulder is tapped. It is, therefore, difficult to set the body in oscillation with repeated small impulses laterally, but this appears to occur not infrequently in longitudinal motion with feeble heart beats.

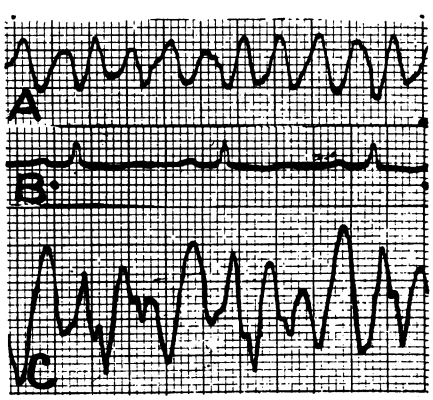

FIG. 9

From a case of myxedema. Continuous, characterless waves in the longitudinal trace, with distinct pattern of different phase in the lateral.

Both the above cases showed rather abrupt leftward motion synchronous with isometric contraction, though neither had a palpable apex thrust. In both there was no phase relationship between lateral and longitudinal waves and the lateral traces had one less peak and trough per cycle than the longitudinal records. Diastolic motion greatly exceeded systolic in the lateral curves. In no case did we record in the lateral plane the chaotic jumble seen in some longitudinal records of cases of angina or infarction, but in few of our cases were records made without suspending respiration, which usually diminishes the irregularity of the waves in such cases.

Most of the young congenital cardiacs we studied had longitudinal and lateral records which showed no remarkable features as compared with

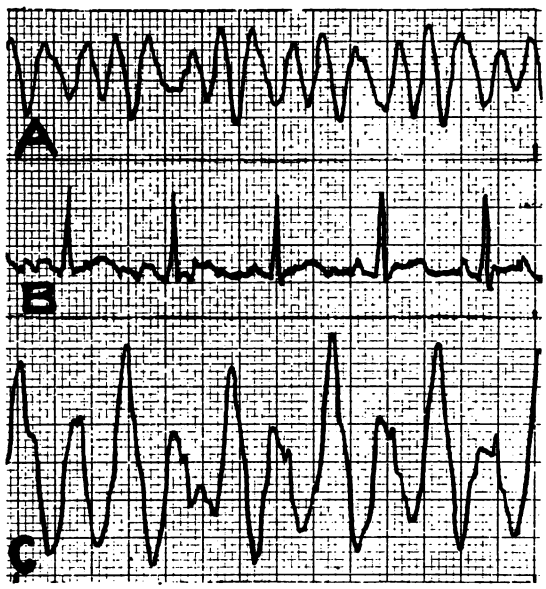

FIG. 10

From a case of angina pectoris. The J–K excursion, the largest in a longitudinal trace composed of simple oscillations, coincides with the peak of a rightward wave which begins with the trough of I and ends with the peak of L.

controls. Indeed, there is no consistent relation of lateral thoracic ballistocardiographic patterns even to marked right or left axis deviation; the waves were the reverse of the common pattern in one case of situs inversus. More careful studies on a larger number of cases verified by catheter technics may reveal correlations between lateral thoracic ballistocardiograms and such shunts or acquired valvular lesions. The simplicity of recording the lateral motion whenever precordial leads are being inscribed with four-channel recorders makes it seem desirable to do so in many cases of suspected myocardial disease as well as in valvular disease. Perhaps the most significant fact apparent in these tracings is that return flow and cardiac filling in diastole produce lateral motion of the thorax comparable to the longitudinal motion of the body caused by ventricular systole.

CONCLUSIONS

With electromagnetic pick-ups and a multichannel recorder the dorsoventral lateral motions of the thorax and the longitudinal motion of the body can be inscribed simultaneously with the electrocardiogram.

The lateral motion varies in amplitude at various levels in the right midaxillary line; the level of the xiphoid was chosen for systematic study.

Lateral motion is altered more than longitudinal by the phase of respiration in which the tracing is inscribed or by variations in the P–R intervals in a given subject.

In many normal subjects lateral motion during diastole is much greater than during systole, presumably because blood moves from right to left as the ventricles are filled. In general rightward and headward, leftward and footward motions are recorded with direct thoracic tracings. This conforms with the fundamentals of ballistic theory when the rightward and headward direction of the cardiac axis is considered.

Dorsoventral motion recorded from the right and left midclavicular lines seems to indicate torsion of the trunk in systole. This may explain the leftward and headward systolic motion recorded by table ballistocardiography, for such torsion would push the table in a direction opposite to the roll of the body.

No relation of congenital or acquired lesions to characteristic lateral ballistocardiograms was detected.

REFERENCES

1. Hamilton, W. F., Dow, P., and Remington, J. W., The relationship between the cardiac ejection curve and the ballistocardiographic forces. Am. J. Physiol., 1945, **144**, 557.
2. Scarborough, W. R., Beser, J., Talbot, S. A., Mason, R. E., Singewald, M. L., and Baker, B. M., Jr., A method for recording ballistocardiographic vectors; preliminary report. Bull. Johns Hopkins Hosp., 1950, **87**, 235.
3. Braunstein, J. R., Oelker, C. E., and Gowdy, R. C., Design of a two-dimensional ballistocardiograph. J. Clin. Invest., 1950, **29**, 1219.
4. Dock, W., and Taubman, F., Some technics for recording the ballistocardiogram directly from the body. Am. J. Med., 1949, **7**, 751.
5. Starr, I., Horwitz, O., Maycock, R. L., and Krumbhaar, E. B., Standardization of the ballistocardiograph by simulation of the heart's function at necropsy. Circulation, 1950, **1**, 1073.
6. Dock, W., Recording the motions of the heart and blood for clinical purposes. Tr. A. Am. Physicians, 1949, **62**, 148.