Case Report

Maxillofacial brown tumors in secondary hyperparathyroidism: A case report and literature review

Nasim Jafari-Pozve, Masoud Ataie-Khorasgani[1,2], Shahram Jafari-Pozve[3], Mahnaz Ataie-Khorasgani[2]
Dental Implants Research Center, Department of Oral and Maxillofacial Radiology, School of Dentistry, [1]Department of Internal Medicine, [2]Students' Research Committee, School of Medicine, Isfahan University of Medical Sciences, Isfahan, [3]Department of Radiology, School of Medicine, Tehran University of Medical Sciences, Tehran, Iran

Parathyroid glands produce parathyroid hormone (PTH). PTH has a main role in bone formation. Hyperparathyroidism (HPT) is explained as primary, secondary and tertiary types defined as overproduction of PTH. The brown tumor or osteitis fibrosa cystica is a benign bone lesion that is caused by HPT. This complication has been decreased by diagnosis and successful treatment of secondary hyperparathyroidism. Pelvis, ribs, clavicle, mandible and the extremities are most commonly affected bone in brown tumor, whereas maxillary involvement is rare. The present article report a 29-year-old man with chief complaints of bone pain, swelling cheeks and teeth displacement with secondary HPT. Parathyroidectomy was done due to bone disorder. It is important for dentists and endocrinologists to understand maxillofacial manifestation of secondary HPT to prevent its complication.

Key words: Chronic kidney disease, osteitis fibrosa cystica, secondary hyperparathyroidism

How to cite this article: Jafari-Pozve N, Ataie-Khorasgani M, Jafari-Pozve S, Ataie-Khorasgani M. Maxillofacial brown tumors in secondary hyperparathyroidism: A case report and literature review. J Res Med Sci 2014;19:1099-1102.

INTRODUCTION

Parathyroid glands are located behind the thyroid gland that produces parathyroid hormones (PTH). PTH has a main role in bone formation, vitamin D activation occurred in the kidney by PTH that leads to intestinal absorption of calcium and phosphate re-absorption. The primary function of PTH is to maintain the extracellular fluid calcium concentration, which is done by PTH effect on bone and kidney directly and on the intestine through its effects on synthesis of 1, 25 (OH)D, indirectly.[1] Hyperparathyroidism (HPT) is explained as primary, secondary and tertiary types.

Primary hyperparathyroidism (PHPT) is a generalized disorder of calcium, phosphate, and bone metabolism due to excessive secretion of PTH. The main cause of PHPT is adenoma in about 80% cases. Hypercalcemia and hypophosphatemia are the most common presentation in laboratory test.[2]

Secondary hyperparathyroidism (SHPT) is caused by impaired phosphate excretion, and failure to activate vitamin D. Hypocalcemia is caused by elevated levels of the fibroblast growth factor 23 (FGF-23), and reduced synthesis of calcitriol, which is the active form of vitamin D.[3] Elevated phosphate level, decreased ionized calcium level, and reduced serum calcitriol lead to continuous stimulation of the parathyroid glands that causes increased PTH release.[1]

Tertiary HPT is defined as long-time SHPT leads to autonomous parathyroid glands that lead to hypercalcemia, pruritis and extra-skeletal calcification, bone involvement despite aggressive treatment to suppress PTH.[3] HPT leads to bone involvement that include generalized osteoporosis, multiple focal areas of demineralization of the skull, and brown tumor.[4]

The brown tumor or osteitis fibrosa cystica is a benign bone lesion that caused by HPT. This complication has been decreased by diagnosis and successful treatment of secondary HPT. Pelvis, ribs, clavicle, mandible and the extremities are most commonly affected bones in brown tumor, whereas maxillary involvement is rare (0.1%).[5] This case report was unique due to the presentation of brown tumors in the maxillofacial region.

CASE REPORT

In July 2012, a 29-year-old man was referred to Internal Medicine clinic, Al Zahra hospital, Isfahan, Iran with

Address for correspondence: Dr. Masoud Ataie-Khorasgani, Number 13, Saghireesfahani Alley, Jey Street, Isfahan, Iran.
E-mail: m.ataie1360@yahoo.com
Received: 29-05-2013; **Revised:** 26-10-2013; **Accepted:** 09-04-2014

chief complaint of generalized bone pain that started seven months ago and, swelling in the cheek regions, which initiated three months ago and gradually increased in size. He presented that the distance between the teeth increased gradually. He had no history of fever, weight loss and dyspnea. The patient's medical history revealed that he had end-stage renal disease (ESRD) for about eight years, due to systemic lupus erythematous (SLE) that suppressed after renal failure. He was on dialysis three times weekly for the past eight years. Hyperparathyroidism was diagnosed 15 months ago with elevated PTH levels that vitamin D and calcium had been recommended for treatment. Other medications were as follows: Carbonate calcium 2 g/day, calciteriol 1μg/day, vitamin D 50000 units weekly, losartan 50 mg 2 × daily.

On oral examination, displaced teeth without normal alignment was seen, teeth were loose [Figure 1].

The patient compliance was poor and his follow-up laboratory test programs were not periodically in accordance with his medical condition.

Laboratory findings

Result of routine laboratory tests were as follows: PTH: 3552 pg/ml (8-60), calcium: 8.7 mg/dl (8.5-10), phosphorus: 6.3 mg/DL (2.5-5), alkaline phosphatase: 2800 u/L (55-200), hemoglobin: 8.5 mg/DL (14-18), creatinin: 6.5 mg/DL (0.7-1.2), potassium: 5.5 mg/DL (3.5-5), Alb: 3.5 mg/DL (3.5-4).

The level of PTH began to increase from 15 months that was 350 pg/ml, and so the dose of carbonate calcium and and pearl vitamin D was added to the patient's medications that did not respond to treatment. Carbonate calcium was started with two tabs daily and increased every two week that reached to eight tabs in divided dose. Vitamin D was given with 50000 every two week and increased till 50000 weekly.

Tc-99 m sestamibi of the parathyroid glands scan was advised two weeks before admission, which showed a normal uptake inminute 30 and 240.

Radiographic findings

Panoramic radiograph, shows multiple small unilocular well-defined radioluscencies, suggestive of brown tumors in the body of the mandible bone [Figure 2]. Computed tomography (CT) scan of the head and neck region, showed multiple small unilocular well-defined radioluscencies, suggestive of brown tumors in zygoma, maxilla, palate and mandibular bones [Figure 3]. Also, a generalized diffuse severe osteoporosis in maxillofacial bone with salt and pepper pattern was seen [Figure 3].

Figure 1: Bilateral swelling in the cheek regions. Increased distance between teeth and irregular alignment with displaced teeth

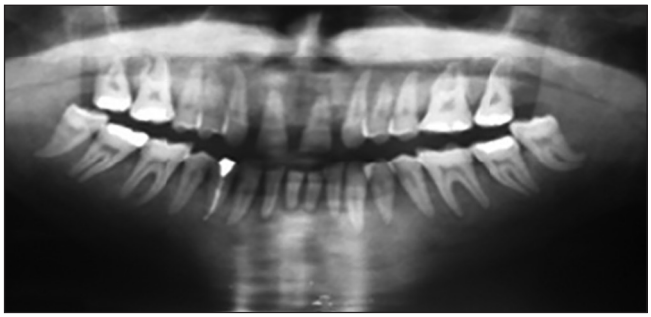

Figure 2: Panoramic radiograph, shows multiple small unilocular radioluscencies, suggestive of brown tumors

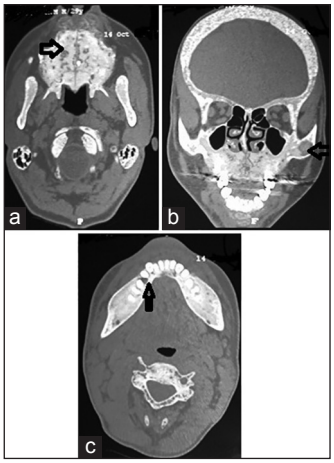

Figure 3: CT scan; (a) axial view shows multiple small unilocular well-defined radioluscencies, suggestive of brown tumors in hard palate (*arrow*); (b) coronal view shows a well-defined radioluscency in zygoma (*arrow*); (c) axial view shows multiple small unilocular well-defined radioluscencies in the mandibular body (*arrow*)

A radiograph of the forearm and elbow regions, showed a unilocular well-defined radioluscency, suggestive of brown tumor in ulnar bone, in addition to calcification of dialysis shunt and metastatic vascular calcification [Figure 4].

Finally, he underwent parathyroidectomy due to tertiary HPT diagnosis. His symptoms relieved after surgery and

the dialysis was started. He had no problem during the follow-up.

The histopathological examination showed a chief cell proliferation of parathyroid with clear cytoplasm and small central nucleus with oxiphilic cells seen between them. The tissue was surrounded by a thin capsule penetrated by thin septa that divided that into labels, all of these suggested HPT. [Figure 5]

DISCUSSION

The brown tumor is a bone lesion that is caused by osteoclast activity in HPT condition. Parathyroid glands include chief cell that produce PTH. The final result of increased secretion by the chief cells is HPT. It is not a real malignancy against the tumor term. The incidence of skeletal brown tumors in ESRD ranges from 1.5 to 13%, but this complication has been decreased with novel diagnostic PTH radioimmunoassay techniques and successful treatment of the disease.[5] This unusual complication of secondary HPT is more commonly seen in young female patients,[6] and so the patient in this report was unusual for his gender. Pelvis, ribs, clavicle, mandible and the extremities are most commonly affected bones in brown tumor, whereas involvement of the maxilla is considered rare.[7,8]

Laboratory findings of three types of HPT are different. Elevated PTH is the cornerstone of all HPT, but they differ in calcium and phosphate level. Primary HPT presented with an elevated calcium level, normal or low phosphate level, secondary HPT hypocalcemia and hyperphosphatemia are dominant, while hypercalcemia and hyperphosphatemia occurred in tertiary. Elevated alkaline phosphatase represents a high bone turnover. Hypocalcemia, hyperphosphatemia and calcitriol deficiency may be found in chronic kidney disease (CKD), that can lead to PTH, directly affecting the skeletal system.

Periapical radiographs reveal loss of lamina dura in 10% of patients with HPT. Depending on duration and severity of disease, loss of lamina dura may occur around one tooth or all remaining teeth. The loss may be either complete or partial around the particular tooth. The result of lamina dura loss may give the root a tapered appearance because of loss of image contrasts.[9]

The major clinical manifestations of HPT in the oral cavity are brown tumor, malocclusions, loss of bone density, soft-tissue calcifications, weak teeth, and dental abnormalities of such developmental defects, alterations in dental eruption and widened pulp chambers.[7] Brown tumor is a late manifestation of SHPT.[2]

According to the examination and using panoramic radiography, the differential diagnosis is multiple myeloma, bone metastases of a carcinoma, osteosarcoma, osteomyelitis or osteonecrosis secondary to bisphosphonate therapy and Paget's disease that elevated PTH level differentiate HPT from others.

Brown tumor is a late manifestation and happens in advanced SHPT, while they can rarely occur as an early sign of HPT. In the jaw bones, it may present sometimes painful, hard and clearly palpable swellings, if a large deformity in affected bone occurred. Also an altered masticatory function and facial deformities can be seen, as was seen in the presented case,[10] but it may be completely asymptomatic.

Diagnosis of brown tumor in PHPT dependent of histopathology, while Balloon *et al.*, showed that the diagnosis of brown tumor in ESRD condition is suggested clinically and confirmed by the endocrinological status of the patient,[11] and so based on history and labarotary test, brown tumor was his diagnosis. But Tc-99 m sestamibi scan can be useful for diagnosis of HPT, but normal scan in 30 and 240 minutes can be falsely negative. The scan must be done every 15 minutes, and false negative can be due to the fact that, it has been

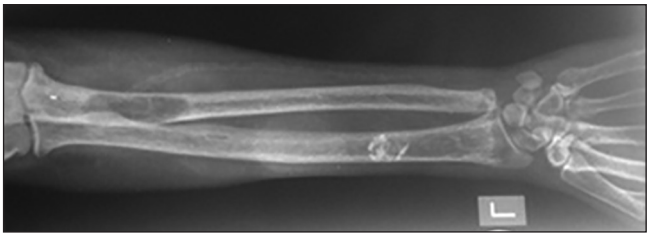

Figure 4: Radiograph of the forearm and elbow regions, showed a unilocular well-defined radioluscency, suggestive of brown tumor in ulnar bone. Note to the calcification of dialysis shunt and metastatic vascular calcification

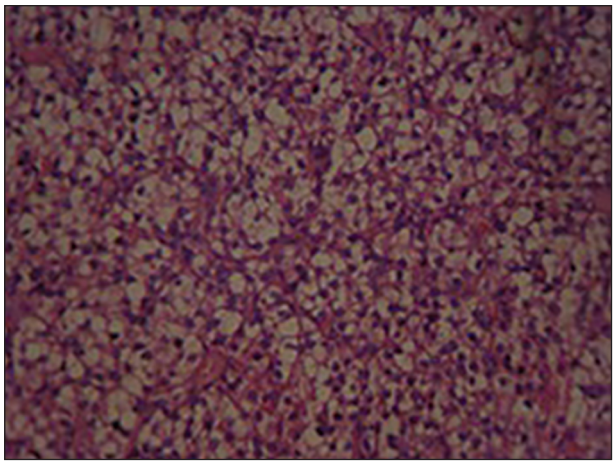

Figure 5: Chief cell hyperplasia of parathyroid (H & E ×40)

done only in 30″ and 240″. Chang CW *et al*., showed that imaging of parathyroid glands should be done only before to reoperation and is not usually required before initial parathyroidectomy.[12]

According to the fact that hypocalcemia has the main role in SHPT, correction of hypocalcemia and hyperphosphatemia with calcium and phosphate binders, and 1,25 dihydroxy vitamin D, is the cornerstone of treatment and prevention of secondary HPT and its complication. Patients with very severe SHPT may be unresponsive to high-dose vitamin D and require parathyroidectomy as seen in the presented patient. Ishikawa Y *et al*., presented parathyroidectomy was a good choice for patients with high PTH levels and diffuse brown tumor.[13]

CONCLUSION

Secondary hyperparathyroidism is a common complication of end-stage renal disease, on long time hemodialysis. The patient must have periodical follow-up to treat carefully. Correction of hypocalcemia is major treatment and decreased complication. A great attention must be done to detect this complication. The scan is not required to confirm the HPT, and diagnosis of brown tumor is clinically in ESRD. It is important for general practitioner dentists, oral and maxillofacial surgeon, oral and maxillofacial radiologist, an endocrinologist and internist to be aware of SHPT to diagnosis and treatment. Dentists should also be aware of possible presence of brown tumors in the jaws of patients having HPT or presented with radiologic finding of HPT to prevent fatal complications. Panoramic radiographs and CT scans were all useful radiographic methods for the correct diagnosis of brown tumour.

AUTHOR'S CONTRIBUTION

NJP contributed in the conception of the work, conducting the study, revising the draft, approval of the final version of the manuscript, and agreed for all aspects of the work. MAKh contributed in the conception of the work, drafting and revising the draft, approval of the final version of the manuscript, and agreed for all aspects of the work. ShJP contributed in the conception of the work, conducting the study, revising the draft, approval of the final version of the manuscript, and agreed for all aspects of the work. MAKh contributed in the conception of the work, revising the draft, approval of the final version of the manuscript, and agreed for all aspects of the work.

REFERENCES

1. Kumar R, Thompson JR. The regulation of parathyroid hormone secretion and synthesis. J Am Soc Nephrol 2011;22:216-24.
2. Selvi F, Cakarer S, Tanakol R, Guler SD, Keskin C. Brown tumor of the maxilla and mandible: A rare complication of tertiary hyperparathyroidism. Dentomaxillofac Radiol 2009;38:53-8.
3. Cunningham J, Locatelli F, Rodriguez M. Secondary hyperparathyroidism: Pathogenesis, disease progression, and therapeutic options. Clin J Am Soc Nephrol 2011;6:913-21.
4. Merz MN, Massich DD, Marsh W, Schuller DE. Hyperparathyroidism is presenting as brown tumor of the maxilla. Am J Otolaryngol 2002;23:173-6.
5. Tarello F, Ottone S, De Gioanni PP, Berrone S. Brown tumor of the jaws. Minerva Stomatol 1996;45:465-70.
6. Daniels JS. Primary hyperparathyroidism presenting as a palatal brown tumor. Oral Surg Oral Med Oral Pathol Oral Radiol Endod 2004;98:409-13.
7. Triantafillidou K, Zouloumis L, Karakinaris G, Kalimeras E, Iordanidis F. Brown tumors of the jaws associated with primary or secondary hyperparathyroidism. A clinical study and review of the literature. Am J Otolaryngol 2006;27:281-6.
8. Chowdhury S, Aggarwal A, Mittal N, Shah A. Brown tumor of hyperparathyroidism involving craniomaxillofacial region: A rare case report and literature review. Minerva Stomatol 2013;62:343-8.
9. White SC, Pharoah MJ. Oral radiology. 6th ed. St.Louis: Mosby Elsevier; 2009. p. 570-2.
10. Jakubowski JM, Velez I, McClure SA. Brown tumor as a result of hyperparathyroidism in an end-stage renal disease patient. Case Rep Radiol 2011;2011:41576.
11. Pecovnik Balon B, Kavalar R. Brown tumor in association with secondary hyperparathyroidism. A case report and review of the literature. Am J Nephrol 1998;18:460-3.
12. Chang CW, Tsue TT, Hermreck AS, Baxter KG, Hoover LA. Efficacy of preoperative dual phase sestamibi scanning in hyperparathyroidism. Am J Otolaryngol 2000;21:355-9.
13. Ishikawa Y, Konya E, Yamate T, Amasaki N, Umekawa T, Katayama Y, *et al*. Indications of parathyroidectomy for bone disease associated with secondary hyperparathyroidism. Nihon Hinyokika Gakkai Zasshi 1996;87:67-73.

Source of Support: Nil, **Conflict of Interest:** None declared.