Review article

Assessment Lumboperitoneal or Ventriculoperitoneal Shunt Patency by Radionuclide Technique: A Review Experience Cases

Sunanta Chiewvit, Sarun Nuntaaree[1], Potjanee Kanchaanapiboon, Pipat Chiewvit[2]

Departments of Radiology, Division of Nuclear Medicine, [2]Division of Diagnostic Radiology, [1]Department of Surgery, Division of Neurosurgery, Siriraj Hospital, Mahidol University, Bangkok 10700, Thailand

Abstract

Hydrocephalus-related symptoms that worsen after shunt placement may indicate a malfunctioning or obstructed shunt. The assessment of shunt patency and site of obstruction is important for planning of treatment. The radionuclide cerebrospinal fluid (CSF) shunt study provides a simple, effective, and low-radiation-dose method of assessing CSF shunt patency. The radionuclide CSF shuntography is a useful tool in the management of patients presenting with shunt-related problems not elucidated by conventional radiological examination. This article described the imaging technique of ventriculoperitoneal (VP) shunt and lumbar puncture (LP) shunt. The normal finding, abnormal finding of completed obstruction and partial obstruction is present by our cases experience. The radiopharmaceutical (Tc-99m diethylenetriaminepentaacetic acid) was injected via the reservoir for VP shunt and via lumbar puncture needle in subarachnoid space for LP shunt, then serial image in the head and abdominal area. The normal function of VP and LP shunt usually rapid spillage of the radioactivity in the abdominal cavity diffusely. The patent proximal tube VP shunt demonstrates ventricular reflux. The early image of patent LP shunt reveals no activity in the ventricular system contrast to distal LP shunt reveals early reflux of activity in the ventricular system. The completed distal VP and LP shunt obstruction show absence of tracer in the peritoneal area or markedly delayed appearance of abdominal activity. The partial distal VP and LP shunt obstruction recognized by slow transit or accumulation of tracer at the distal end or focal tracer in the peritoneal cavity near the tip of distal shunt. The images of the normal and abnormal CSF shunt as describe before are present in the full paper. Radionuclide CSF shuntography is a reliable and simple procedure for assessment shunt patency.

Keywords: LP shunt, normal pressure hydrocephalus, radionuclide cerebrospinal fluid shuntography, ventriculoperitoneal shunt

Introduction

Cerebrospinal fluid (CSF) is produced in the brain by modified ependymal cells in the choroid plexus (approximately 50-70%) and the remainder is formed around blood vessels and along ventricular walls. It circulates from the lateral ventricles to the foramina of Monro (Interventricular foramina) and exit lateral ventricle to third ventricle pass through aqueduct of Sylvius (Cerebral aqueduct) to fourth ventricle and eventually exit the cranial vault via foramen of Magendie (Median aperture) and foramina of Luschka (Lateral apertures), subarachnoid space over brain and spinal cord. It should be noted that the CSF moves in a pulsatile manner throughout the CSF system with nearly zero net flow. CSF is reabsorbed into venous sinus blood via arachnoid granulations. CSF is produced at a rate of 500 ml/day. Since the subarachnoid space around the brain and spinal cord can contain only 135–150 ml. CSF pressure, as measured by lumbar puncture (LP), is 10-18 cmH_2O with the patient lying on the side.

Cerebrospinal fluid shunts are inserted to treat the symptoms of hydrocephalus and idiopathic intracranial

Access this article online

Quick Response Code:

Website: www.wjnm.org

DOI: 10.4103/1450-1147.139135

Address for correspondence:
Dr. Sunanta Chiewvit, Department of Radiology, Division of Nuclear Medicine, Siriraj Hospital, Mahidol University, Prannok Road, Bangkoknoi, Bangkok 10700, Thailand. E-mail: schiewvit1@hotmail.com

hypertension. Hydrocephalus-related symptoms that worsen after shunt placement may indicate a malfunctioning or obstructed shunt. Shunt obstruction can occur at any time after insertion, and all points along the shunt course are suspect. A malfunctioning shunt may be caused by a mechanical issue such as disconnection or kinking of the shunt tubing. CSF shunt component are composed of a proximal catheter, a pressure-sensitive valve with reservoir and a distal peritoneal catheter. Radionuclide CSF shunt imaging is used to determine whether the shunt is patent and to exclude shunt obstruction. The finding that shunt obstruction in normal pressure hydrocephalus (NPH) is virtually always in the distal peritoneal catheter is strikingly different from shunt obstruction in children, in whom proximal ventricular catheter obstruction is more common.[1]

Proximal obstruction may be due to plugging of the catheter by brain parenchyma, choroid plexus, proteinaceous material, or tumor cells. Distal obstruction may be caused by adhesions within the peritoneum.

Imaging Technique for Radionuclide Cerebrospinal Fluid Cysternography to Assessment CSF Shunt Patency

Radiopharmaceutical

Tc-99m diethylenetriaminepentaacetic acid (Tc-99m DTPA) 3 mCi in 0.3–0.5 ml, the small volume is used to ensure minimal disruption of the normal CSF flow physiology.

Injection technique

Ventriculoperitoneal shunt

Injection of ^{99m}Tc-DTPA via reservoir by manually occlude the distal limb to help reflux a portion of the radiopharmaceutical into the ventricles, thereby assessing patency of the proximal limb of the ventriculoperitoneal (VP) shunt.

The selection of the site of injection should be made by a neurosurgeon that is familiar with the patient's shunt appliance.

Lumboperitoneal shunt

Injection of ^{99m}Tc-DTPA via lumbar puncture needle in subarachnoid space.

Imaging technique

Static images at skull and abdomen in anterior, posterior and both lateral views at 1, 3, 6 and 24-h. Imaging may be considered with the patient in the upright position to increase hydrostatic pressure and therefore encourage CSF flow. This procedure may be especially helpful to perform when supine imaging has not been successful and to help to decrease a false positive study.

Indication

The radionuclide CSF shunt study provides a simple, effective, and low-radiation-dose method of assessing CSF shunt patency. However, this method is not frequently requested and currently, no consensus guidelines or recommended approach to diagnostic imaging exists in the evaluation of CSF shunt obstruction. The reasons are due to initial assessment of the patient with a CSF shunt presenting with symptoms is performed clinically. The clinician cans simple assess the shunt system by pump test. The clinician may also access the shunt reservoir to measure opening pressure and obtain CSF for culture and laboratory analysis. Computed tomography (CT) is often performed initially to assess ventricular size in which dilatation of lateral ventricles [Figure 1a and b] is demonstrated and increase of ratio between frontal horns width to biparietal diameter width as Evan's ratio. Changing of configuration of frontal horns, temporal horn and 3rd ventricle are encountered by CT scan [Figures 2 and 3] and sign of increase intraventricular pressure such as transependymal edema as transmits of CSF into brain parenchyma [Figure 4]. However, this technique is not entirely reliable, however, as patients may have chronically enlarged ventricles. CT is most reliable in this setting if there are prior scans to allow determination of whether the ventricles have increased in size. The CT may also be used to verify the correct placement of a CSF shunt.

Routine radiography may be performed to examine the tubing to check for kinking or disconnection. However, when doubt persists, the nuclear medicine CSF shunt study remains a reliable means of assessing shunt patency. The radionuclide CSF shuntography is a useful tool in the management of patients presenting with shunt-related problems not elucidatedby conventional radiological examination.

The normal findings

Normal ventriculoperitoneal shunt

Ventricular reflux was demonstrated. The entire shunt system was visualized without any blockage, the isotope passed uniformly into the abdominal cavity and no focal activity was observed around the distal end of the peritoneal catheter. No activity or little activity in the distal tube and spinal canal were observed delayed image. There is excreted activity in the kidney and urinary bladder in the 1 and 3-h images [Figure 5]. The radionuclide CSF shuntography in Figures 6 and 7 patients were normal VP shunt clear of activity, but slower than Figure 5 patient.

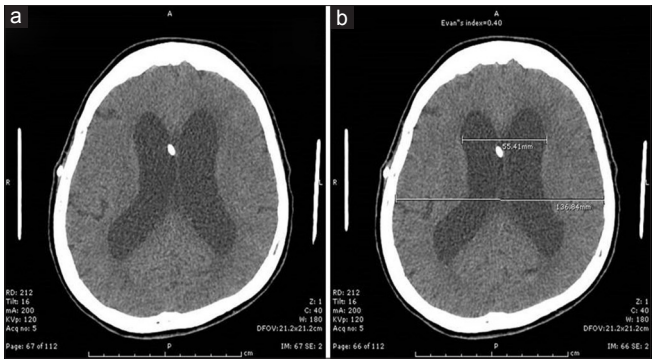

Figure 1: (a) ventricular dilatation of lateral ventricle out of proportion to CSF spaces over hemispheres convexity. (b) Evan's index = 0.4

Figure 2: widening of temporal horns of lateral ventricle greater than 3 mm

Figure 3: Round shape of 3rd ventricle

Figure 4: Periventricular cap hypodensity around frontal horns indicate transependymal effusion

Normal LP shunt

The radioactivity was usually early appearance of radioisotope in the spinal canal, shunt tubing, reservoir, and extravasations of radioactivity in peritoneal cavity. There is no activity in the basal cistern ventricular system[2] [Figure 8].

Occlusion ventriculoperitoneal shunt

Proximal shunt occlusion

Ventricular reflux did not occur in any patient who had proximal shunt blockage. However, absence of ventricular reflux may occur in normal shunts.

Distal shunt occlusion

Increased CSF pressure at the time of shunt puncture, absence of tracer in the peritoneal area, or markedly delayed appearance of abdominal activity [Figure 9]. There is activity in the ventricular system, in the distal tube and in the spinal canal.

Partial block

The shunt was patent, but the flow of CSF through the shunt was insufficient to maintain normal CSF dynamics. The most common cause of this slow flow through the shunt was that, as the child grew, the distal end of the tubing pulled out of the peritoneal cavity.[3]

Partial blockage may be recognized by slow transit or accumulation of tracer at the distal end or local of tracer in the peritoneal cavity. Activity is seen in the ventricular system, distal tube, and spinal canal [Figure 10].

Occlusion of LP shunt

Complete block

The radiopharmaceutical usually ascended rapidly into the basal cisterns and frequently refluxed into the lateral ventricles [Figures 11 and 12]. There was absent or minimal activity in the peritoneal cavity.

Partial block of LP shunt

The radioactivity delayed ascends to the basal cistern and delayed excretion in the abdominal cavity. The activity in the abdominal cavity is usually focally as shown in Figure 13.

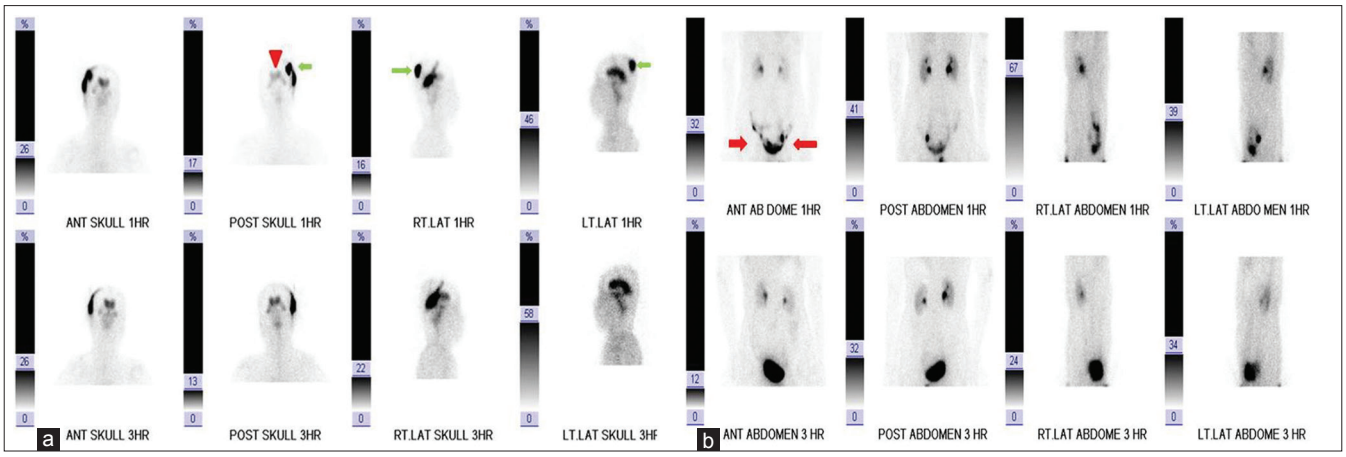

Figure 5: A 76- year-old man post VP shunt 1 hour images (Figure 5A) reveal activity in the ventricular system (red arrow head) and reservoir (green arrow). There is spillage activity in the abdominal cavity (Figure 5B red arrow) clearly seen in 1-hour image. The activity is in the kidneys and urinary bladder due to Tc-99m DTPA is reabsorbed and excretion. No activity in the distal limb and spinal canal are noted may be due to very well drainage of CFS via VP shunt. The 3 and 6 hours images reveal no activity in the reservoir. These findings are rapid drainage of normal VP shunt

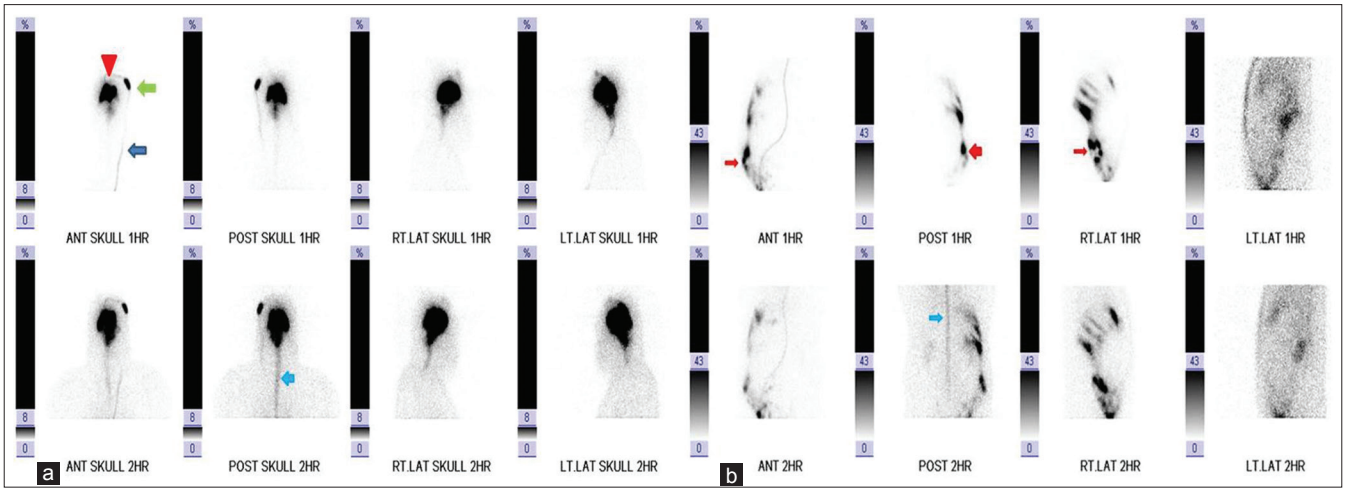

Figure 6: A 74-year-old man post VP shunt 1-hour images reveal activity in the ventricular system (Figure 6A red arrow head) and reservoir (green arrow). Activity in the distal limb (dark blue arrow) is seen. There is spillage activity in the abdominal cavity (Figure 6 B red arrow). The 2-hour posterior image shows activity in the spinal canal (blue arrow) which is not seen in the 1-hour image. These findings are normal VP shunt

Discussion

Classification of peritoneal distribution of radionuclide for determination CSF shunt obstruction was as follows: (1) Diffuse (radionuclide visible bilaterally mean normal CSF shunt; (2) loculated (radionuclide visible unilaterally restricted to region near the distal catheter) mean partial occlusion of CSF shunt; and (3) none or no activity in the abdominal cavity mean completed CSF shunt occlusion.

For normal function LP shunt, we did not see the activity in the ventricular system due to the activity injection via the lumbar puncture needle. The pressure is not high to reflux in the ventricular system. In case of partial LP shuntocclusion is usually delayed seeing the activity in the ventricular system >1-h. Competed LP shuntocclusion detect early filling of the activity in the ventricular system within 1-h. Normally no activity visualization in the distal limb is noted for LP shunt.

The radioisotope injected outside the shunt tubing or spinal subarachnoid space cause the tracer rapidly absorbed interstitially and there is a characteristic pattern with diffuse spread of tracer in the soft tissue and renal excretion.

Benefit and limitation

The assessment of shunt patency and site of obstruction is important. This has implications for the evaluation of shunt obstruction in NPH. First, it allows the revision surgery to be directed to the site of obstruction. Most patients do not initially require replacement of the shunt valve and instead only need repositioning of the

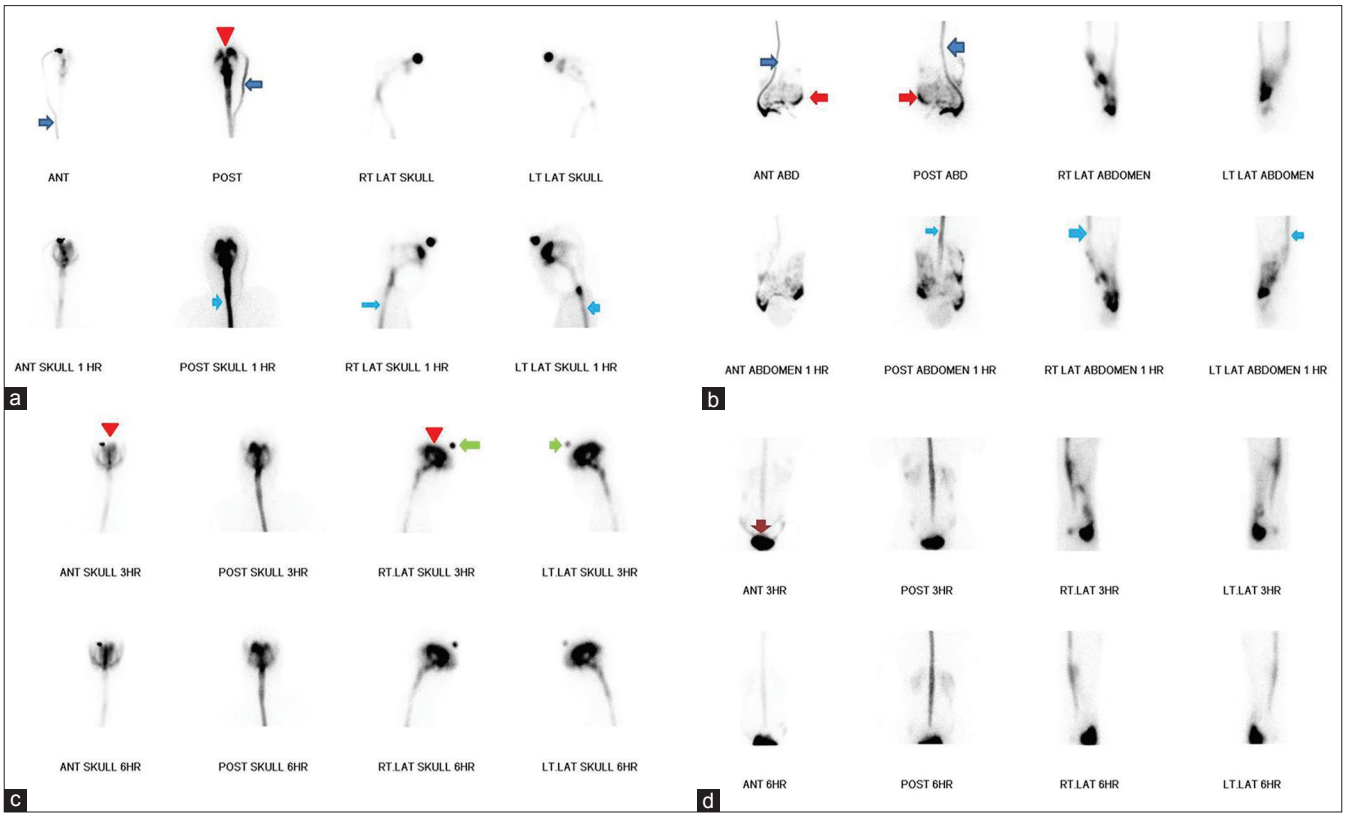

Figure 7: A 22-year-old woman post VP shunt and clinical suspicious VP shunt malfunction. The scan in the early image show the activity prompt excreted activity in the distal tube (dark blue arrow) and abdominal cavity (red arrow), indicated good function of VP shunt. The delayed images at 3 and 6 hour reveal decreased of the activity in the reservoir (green arrow), distal tube and abdominal cavity. There are faint activity in bilateral kidneys and significant urinary bladder activitydue to reabsorb of99mTc DTPA

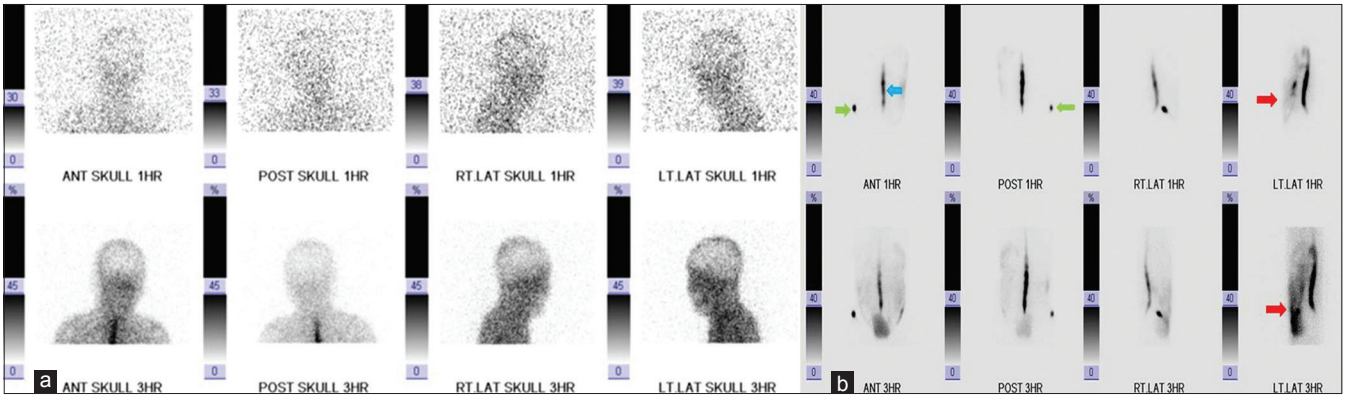

Figure 8: A 84-year-old man post right LP shunt 1-hour and 3- hour images reveal no activity in the basal cistern and ventricular system (Figure 8A). Present activity in the reservoir (green arrow) and spinal canal (blue arrow). The activity is diffuse spillage in the abdominal cavity (Figure 8B red arrow) with seen clearly in the anterior aspect of lateral image. These findings are normal LP shunt

distal tubing, which is a simpler and more cost-effective procedure. Rapid refill of the shunt reservoir cannot be used to exclude the possibility of shunt obstruction in NPH; this is also an unreliable technique in children, where the positive predictive value is as low as 12%.[4] In most shunts, the reservoir is proximal to the valve mechanism, which is designed for one-way flow to prevent reflux from the distal shunt system. Therefore, the distal shunt catheter could be completely obstructed and the shunt reservoir would still refill rapidly because the CSF from the reservoir is simply displaced into the ventricular system.[5] Radionuclide CSF shuntography is a reliable and simple procedure for assessment shunt patency. This study is usually augmented clinical diagnosis and management. For example, normal shunt study usually makes surgical intervention unnecessary and a diagnosis other than a blocked shunt likely. If a block is present, then localization of the site helps in planning the appropriate surgical technique.



Figure 9: A 83-year-old man post VP shunt 1-hour, 3- hour and 6-hour images reveal activity in the ventricular system (red arrow head), reservoir (green arrow), distal limb (dark blue arrow) and spinal canal (blue arrow). No activity is spillage in the abdominal cavity with kink at the distal limb. These findings indicated completed distal VP shunt obstruction

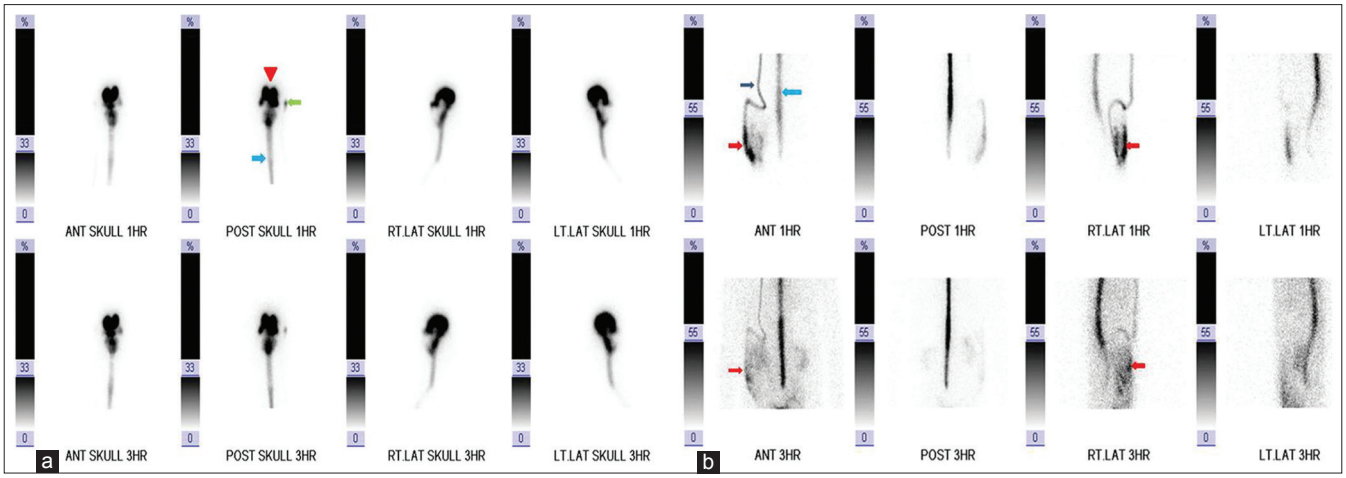

Figure 10: A 71-year-old man post VP shunt 1-hour and 3- hour images reveal activity in the ventricular system (Figure 10 A red arrow head), reservoir (green arrow), distal limb (dark blue arrow) and spinal canal (blue arrow). Focal activity is spillage in the right abdominal cavity(Figure 10 B red arrow). All of this finding indicated partial occlusion of VP shunt

The study by Graham *et al*.[6] 192 CSF shunt 140 were to assess VP shunts, 28 were for ventriculoatrial shunts, 15 for LP shunts, and seven for ventriculopleural (VPI) shunts. The results of the radionuclide CSF shuntography



Figure 11: A 64-year-old woman post left LP shunt 1-hour, 3- hour , 6-hour and 24-hour images reveal activity in the ventricular system (red arrow head), reservoir (green arrow) and spinal canal (blue arrow). No activity is spillage in the abdominal cavity. The activity in the ventricular system is seen rapidly with in 1 hour. The 24-hour images show the activity in bilateral kidneys and urinary bladder. These findings are compatible with completed LP shunt obstruction

were correlated with the subsequent clinical course of the patient, as shown in in Table 1.

The false negative in 2 patients, one of the patients on scanning had rapid excrete of radioisotope into the peritoneal cavity. However, at surgery 3 days later, the distal end was blocked. The other patient had the shunt replaced because the opening pressure was elevated. There was, however, no actual mechanical blockage. Eleven studies were regarded as being false positives. Nine of the 11 were interpreted as demonstrating proximal blockage to the shunt: Seven VP shunts and two VPI shunts. The other 2 cases had distal blockage. No ventricular reflux was noted in any of these 11 cases. This finding confirms that ventricular reflux did not occur in any patient who had proximal shunt blockage. However, absence of ventricular reflux may occur in normal shunts.

The sensitivity, specificity and accuracy of the radionuclide shuntography were 97%, 90%, and 93%, respectively.

Evaluation of CSF shunt patency by means of technetium-99m DTPA.

Comparison of radionuclide CSF shuntography false negative rate results in different centers utilizing ^{99m}Tc-DTPA from Vassilyadi *et al*.[7] reported in Table 2.

Table 1: Results of the radionuclide CSF shuntography were correlated with the subsequent clinical course of the patient

CSF shuntography	Clinical course		Total
	Shunt malfunction	Shunt functioning	
Abnormal scan	76	11	87
Normal scan	2	103	105
Total	78	114	192

CSF: Cerebrospinal fluid

Table 2: Comparison of radionuclide CSF shuntography false negative rate results in different centers

Study	Number of patient	Number of study	False negative rate
French and Swanson[2]	43	78	36 (13/36)
Graham *et al*.[6]	142	192	2 (2/105)
Vernet *et al*.[8]	47	56	14 (3/22)
May *et al*.[9]	85	85	11 (4/35)
Vassilyadi[6]	56	68	25 (10/40)

CSF: Cerebrospinal fluid

Although all patients are initially lying down when the tracer is being administered, that same position may not be maintained for the duration of the study. If peritoneal spillage does not occur by a certain time, some centers allow patients to sit up, move around, or even have their shunts pumped in order to facilitate the flow of CSF.[2,6,9,10]

The study by Kharkar *et al*.[11] study 59 patients with NPH post VP shunt were evaluated shunt function by radionuclide CSF shuntography for suspected shunt malfunction and opening pressure > 5 cmH_2O. The result of radionuclide CSF shuntography comparison with final diagnosis was presented in Table 3.

Table 3: The result of radionuclide CSF shuntography comparison with final diagnosis

Abdominal distribution	Final diagnosis (%)		
	Not obstructed	Partial distal obstruction	Completed distal obstruction
Diffuse	21 (100)	7 (43.7)	0
Loculated/localized	0	6 (37.5)	1 (4.5)
None	0	3 (18.7)	21 (95.5)

CSF: Cerebrospinal fluid

The result from the table showed diffuse abdominal distribution can excluded completed distal shunt obstruction.

The study by Ouellette *et al*.[12] for additional value of radionuclide CSF shuntography to CT in 69 pediatric patients who suspected CSF shunt obstruction. The result is shown in Table 4.

False negative rate for CT and radionuclide CSF shuntography are 8.7% and 2.9%, respectively.

Table 4: Comparison of the of radionuclide CSF shuntography and CT imaging with operatively result of positive for shunt obstruction

Operative result	CT		Shuntography		CT and shuntography	
	Positive	Negative	Positive	Negative	Positive	Negative
Positive	21	6	25	2	26	1
Nonoperative	14	28	17	25	4	38

CSF: Cerebrospinal fluid; CT: Computed tomography

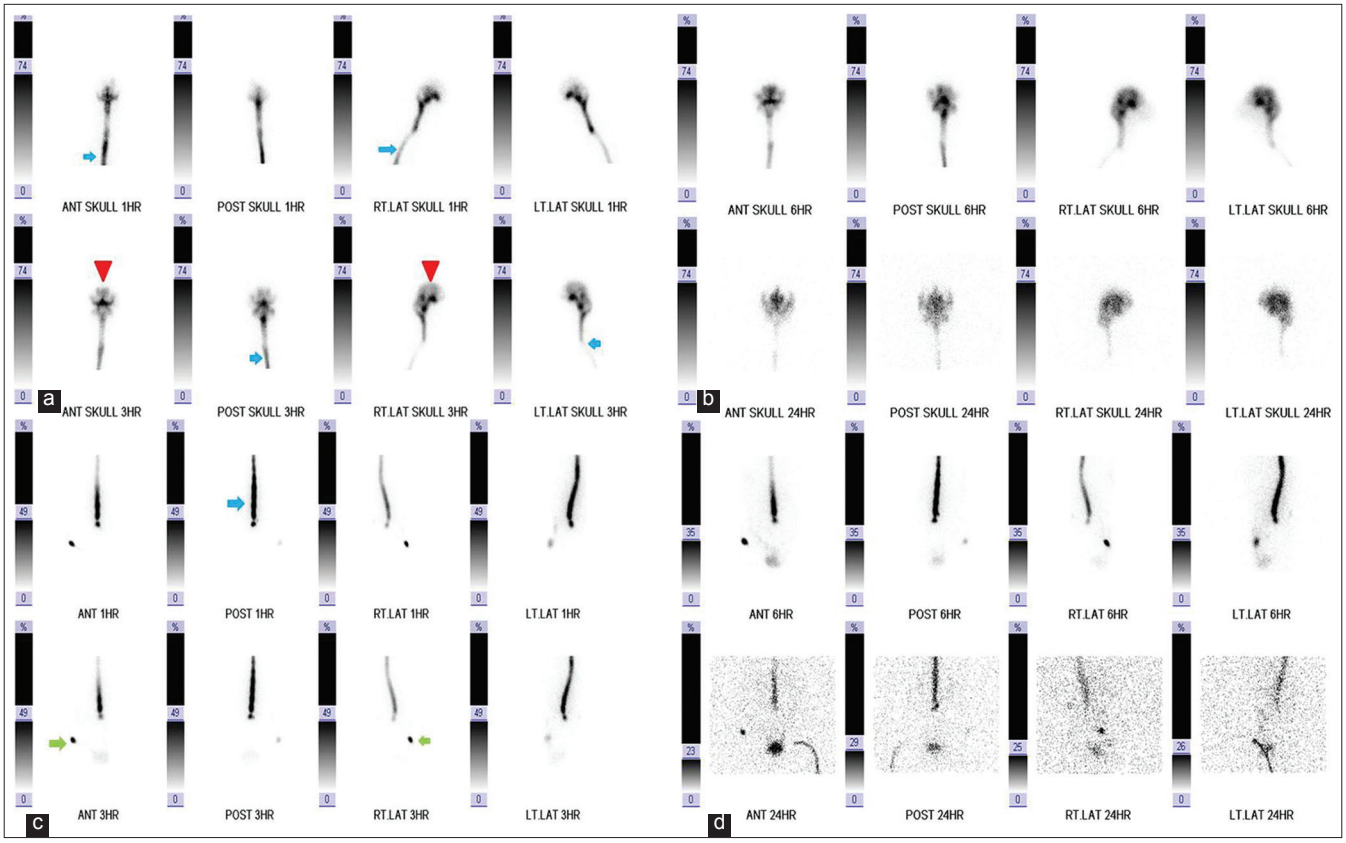

Figure 12: A 64-year-old woman post right LP shunt 1-hour, 3- hour , 6-hour images and 24-hour image reveal activity in the ventricular system (red arrow head), reservoir (green arrow) and spinal canal (blue arrow). No activity is spillage in the abdominal cavity until follow up 24 hours. These findings are compatible with completed LP shunt obstruction

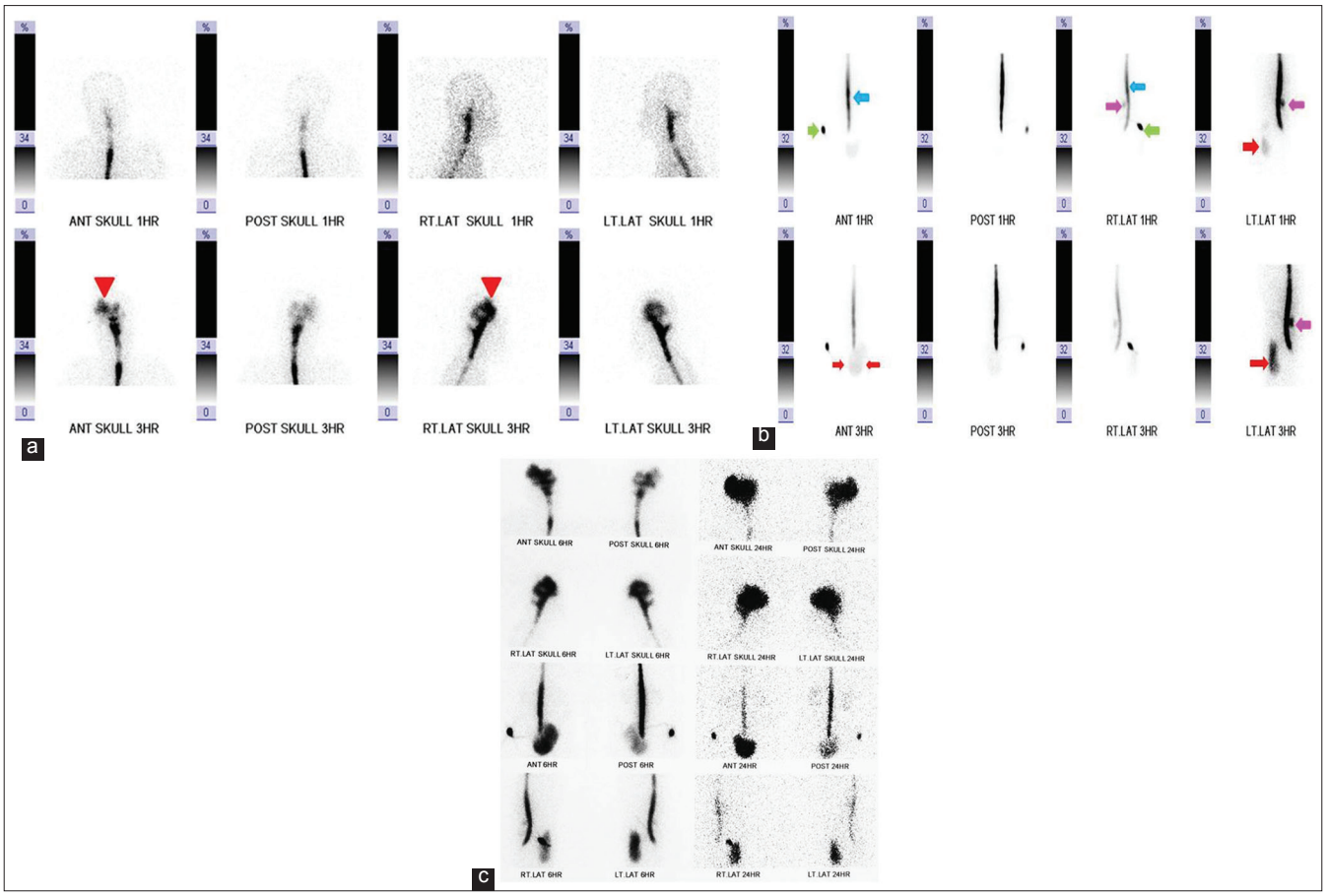

Figure 13: A 59-year-old man post LP shunt 1-hour ,3- hour,6-hour and 24-hour images reveal no activity in the ventricular system at 1 hour image and present activity in the ventricular system at 3-hour,6-hour and 24-hour images (red arrow head), reservoir (green arrow) and spinal canal (blue arrow).There is also leakage of activity at lumbar spinal canal (pink arrow). Focal activity is spillage in the lower abdominal cavity (red arrow) with seen clearly in the anterior image and left lateral image

Table 5: The statistical analysis of CT, radionuclide CSF shuntography and combined modalities for diagnosis of shunt obstruction

Parameter	CT	Shuntogram	Combined modalities
Sensitivity %	77.8	92.6	96.3
Specificity %	66.7	59.5	90.5
PPV %	60	59.5	86.7
NPV %	82.4	92.6	97.4
Positive likelihood ratio	2.3	2.3	10.1
Negative likelihood ratio	0.3	0.1	0.04

CSF: Cerebrospinal fluid; CT: Computed tomography; PPV: Positive predictive value; NPV: Negative predictive value

The statistical analysis of CT, radionuclide CSF shuntography, and combined modalities for diagnosis of shunt obstruction as shown in Table 5.

Conclusion

Radionuclide CSF shuntographyis a useful test for evaluation CSF shunt malfunction and management of patients presenting with shunt-related problems.

References

1. Drake JM, Kestle JR, Milner R, Cinalli G, Boop F, Piatt J Jr, *et al.* Randomized trial of cerebrospinal fluid shunt valve design in pediatric hydrocephalus. Neurosurgery 1998;43:294-303.
2. French BN, Swanson M. Radionuclide-imaging shuntographyfor the evaluation of shunt patency. Surg Neurol 1981;16:173-82.
3. Gilday DL, Kellam J. ^{111}In-DTPA evaluation of CSF diversionary shunts in children. J Nucl Med 1973;14:920-3.
4. Piatt JH Jr. Pumping the shunt revisited. A longitudinal study. Pediatr Neurosurg 1996;25:73-6.
5. Sood S, Canady AI, Ham SD. Evaluation of shunt malfunction using shunt site reservoir. Pediatr Neurosurg 2000;32:180-6.
6. Graham P, Howman-Giles R, Johnston I, Besser M. Evaluation of CSF shunt patency by means of technetium-99m DTPA. J Neurosurg 1982;57:262-6.
7. Vassilyadi M, Tataryn ZL, Matzinger MA, Briggs V, Ventureyra EC. Radioisotope shuntograms at the Children's Hospital of Eastern Ontario. Childs Nerv Syst 2006;22:43-9.
8. Vernet O, Farmer JP, Lambert R, Montes JL. Radionuclide shuntogram: Adjunct to manage hydrocephalic patients. J Nucl Med 1996;37:406-10.
9. May CH, Aurisch R, Kornrumpf D, Vogel S. Evaluation of shunt function in hydrocephalic patients with the radionuclide 99mTc-pertechnetate. Childs Nerv Syst 1999;15:239-44.

10. Bartynski WS, Valliappan S, Uselman JH, Spearman MP. The adult radiographic shuntogram. AJNR Am J Neuroradiol 2000;21:721-6.
11. Kharkar S, Shuck J, Kapoor S, Batra S, Williams MA, Rigamonti D. Radionuclide shunt patency study for evaluation of suspected ventriculoperitoneal shunt malfunction in adults with normal pressure hydrocephalus. Neurosurgery 2009;64:909-16.
12. Ouellette D, Lynch T, Bruder E, Everson E, Joubert G, Seabrook JA, *et al*. Additive value of nuclear medicine shuntograms to computed tomography for suspected cerebrospinal fluid shunt obstruction in the pediatric emergency department. Pediatr Emerg Care 2009;25:827-30.

How to cite this article: Chiewvit S, Nuntaaree S, Kanchaanapiboon P, Chiewvit P. Assessment Lumboperitoneal or Ventriculoperitoneal Shunt Patency by Radionuclide Technique: A Review Experience Cases. World J Nucl Med 2014;13:75-84.

Source of Support: Nil, **Conflict of Interest:** None declared.