Case Report

Widely Infiltrating Epithelioid Malignant Peripheral Nerve Sheath Tumour of Skull Base

Srilatha Parampalli Srinivas[1], Lakshmi Rao[2], Deepak Ranjan Nayak[3]

Submitted: 5 Jul 2012
Accepted: 2 Sept 2012

[1] *Department of Pathology, Melaka Manipal Medical College, Manipal campus, Manipal University, Manipal-576104, Karnataka, India*

[2] *Department of Pathology, Kasturba Medical College, Manipal University, Manipal-576104, Karnataka, India*

[3] *Department of ENT Surgery, Kasturba Medical College, Manipal University, Manipal-576104, Karnataka, India*

Abstract

The epithelioid variant of malignant peripheral nerve sheath tumours is a rare histological entity, and the occurrence of a malignant peripheral nerve sheath tumour in the skull base is even more unusual. We report a case of a 52-year-old man who presented with reduced hearing in the left ear, giddiness and left-sided facial weakness of short duration. He was a known hypertensive. On examination, left-sided 7th to 12th cranial nerve palsies were noted. Computed tomography (CT) and brain magnetic resonance imaging (MRI) were reported as an ill-defined heterogeneously enhancing mass left skull base suggestive of chondrosarcoma. Left tympanotomy and biopsy of the lesion were carried out. On light microscopy and immunohistochemical examination of the biopsy, a diagnosis of epithelioid malignant peripheral nerve sheath tumour was established. The patient underwent left extended modified radical mastoidectomy and selective neck dissection. Histopathological study of the resected surgical specimen confirmed left-sided extensive tumour involvement of skull base structures, as well as neck nodal metastases.

Keywords: *Nerve sheath neoplasm, malignant schwannoma, skull base*

Introduction

Malignant peripheral nerve sheath tumour (MPNST) is a rare sarcoma commonly located in deep soft tissue of the upper and lower extremities and trunk (1). Involvement of the head and neck is uncommon. Among the sarcomas, it is one of the most aggressive malignant tumours, with the highest local recurrence rate and a marked propensity for metastatic spread. A definitive diagnosis of MPNST is obtained by histopathology and S-100 immunostaining. Most cases of MPNST exhibit spindle cell histomorphology. The epithelioid variant or differentiation is a rare but well-recognized entity comprising of about 5% of MPNST (2,3). Once diagnosis is made, wide excision is the mainstay of treatment. We report a case of an elderly male with epithelioid malignant peripheral nerve sheath tumour of the skull base, involving extensive local invasion, and metastatic deposits in the neck nodes.

Case Report

A 52-year-old male presented with reduced hearing of the left ear lasting two months, and giddiness, voice change and facial weakness of one week's duration associated with nasal regurgitation. The patient is a known hypertensive on treatment. He gave a past history of cerebrovascular accident two years previously. On general examination, no skin lesions suggestive of neurofibromatosis-1 (NF-1) were noted. On examination of the central nervous system, left-sided 7th to 12th cranial nerve palsies were noted. Computed tomography (CT) and brain magnetic resonance imaging (MRI) showed an ill-defined mass lesion in the left jugular foramen, causing destruction of adjacent bones, the left occipital condyle, the clivus, the mastoid part of facial canal and the left mastoid air cells (Figure 1). It was reported as suggestive of chondrosarcoma of the skull base. Left tympanotomy and biopsy were

 © Penerbit Universiti Sains Malaysia, 2013
For permission, please email:mjms.usm@gmail.com

carried out. Histopathology showed malignant tumour comprising sheets and fascicles of spindled cells with moderate cytoplasm, and oval to spindly nuclei with fine to coarse chromatin and small inconspicuous nucleoli. Areas of epithelioid differentiation with abundant eosinophilic cytoplasm, vesicular nucleus and prominent nucleolus, frequent mitoses and occasional tumour giant cells were seen (Figure 2 and 3). Tumour cells were focally positive for S-100 (Figure 4) and negative for cytokeratin AE1/AE3 and HMB 45. A diagnosis of malignant peripheral nerve sheath tumour with epithelioid areas was rendered.

The patient underwent left radical mastoidectomy and selective neck dissection. Intra-operatively, a fleshy mass was seen involving the posterior wall of the middle ear extending into the meso and hypotympanum, the mastoid segment of the facial nerve, perisigmoid sinus cells, the mastoid antrum and abutting the dura of the posterior and middle fossa. Biopsies were taken from the above mentioned areas. The left facial nerve, level IIA and IIB cervical lymph nodes and spinal accessory lymph nodes were resected. On histopathology of the tumour biopsies, a malignant peripheral nerve sheath tumour with predominant epithelioid areas, areas of geographic necrosis and haemorrhage were

Figure 1: MRI of skull base showing the tumour (marked with arrow).

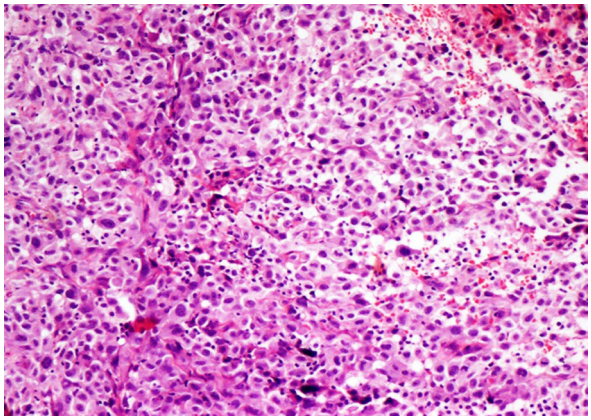

Figure 2: High power (40× magnification) microscopic view of the tumour showing epithelioid differentiation.

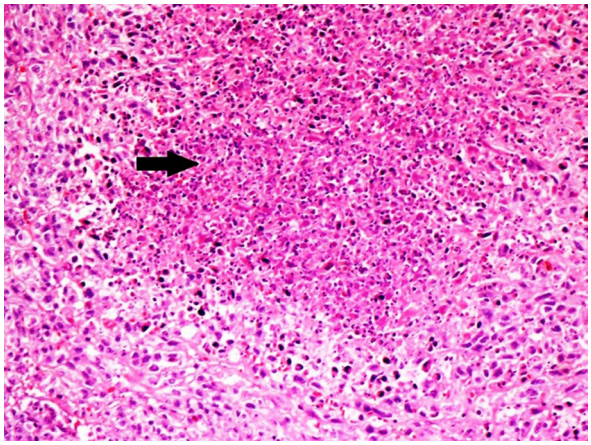

Figure 3: Low power (20× magnification) microscopic view of the tumour showing necrosis (marked by arrow).

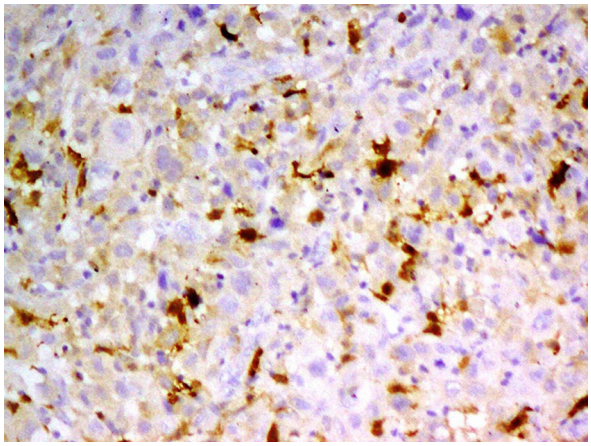

Figure 4: Immunohistochemistry: Focal S-100 positivity.

noted. Left level IIB and the spinal accessory lymph nodes were positive for metastatic deposits. A final diagnosis of widely infiltrating epithelioid malignant peripheral nerve sheath tumour of the skull base with lymph nodal metastasis was established.

Two weeks following the surgery, the patient developed massive haemorrhagic pleural effusion. The cytology of the effusion was negative for malignancy. The patient remained in the intensive care unit for four days and was subsequently discharged against medical advice due to financial constraints.

Discussion

MPNST, also known as malignant schwannoma or neurofibrosarcoma, accounts for 5% to 10% of all soft tissue sarcomas. It usually presents in adult life between 20 and 50 years of age. It arises as de novo, from pre-existing benign neurofibroma and schwannoma or following irradiation. It has a strong association with NF-1 (3,4). In our case, there were no visible manifestations of NF-1.

Approximately 80–85% of MPNST are spindle cell tumours with fasciculating patterns that contain histological features similar to those of a fibrosarcoma. They are often high grade, demonstrating four or more mitotic figures per high power field and areas of geographic necrosis. The remaining 15% of MPNST is composed of tumours that exhibit variable differentiation, allowing them to be sub-classified as distinct entities. These include epithelioid, glandular, rhabdomyoblastic (malignant triton tumour) and melanocytic variants (1,5). Our case represents the epithelioid variant of MPNST, which constitutes about 5% of MPNST. The biological behaviour and prognosis of this variant is not clear (6). Differential diagnosis of this variant includes malignant melanoma, metastatic carcinoma and epithelioid sarcoma. Immunohistochemistry helps in diagnosis. MPNST is positive for S-100, Leu 7, and myelin basic protein. Malignant melanoma is positive for S-100 and HMB 45 (7). Metastatic carcinoma is positive for cytokeratin and epithelial membrane antigen (EMA). Epithelioid sarcoma shows positivity for cytokeratin, EMA, vimentin, and CD34.

MPNST is a very aggressive tumour which spreads via direct perineural invasion and the hematogenous route. The local recurrence rate is about 54% and the rate of distant metastases to lung and bone is about 65% (8). Lymph nodal metastasis occurs in conjunction with widespread disease (9). In our case, there was lymph nodal metastasis. Treatment is aimed at radical resection followed by adjuvant radiotherapy and chemotherapy. Since tumours in the head and neck are in proximity to vital structures, a complete radical resection is not possible; hence, fractional excision is common. Prognosis of head and neck tumours are poorer compared to those of the extremities and the trunk, with five years survival rates from 15% to 35% (3).

Conclusion

In conclusion, MPNST involves a high rate of local invasion, distant spread, and local recurrence. MPNST of the head and neck has a poorer prognosis compared to that occurring in the trunk and extremities due to incomplete excision.

Acknowledgement

Nil.

Conflict of interest

Nil.

Fund(s)

Nil.

Authors' Contributions

Conception and design, collection and assembly of data: PSS
Drafting of the article: PSS, LR
Critical revision of the article for the important intellectual content and final approval of the article: PSS, LR, DRN
Administrative, technical or logistic support: LR
Provision of study materials or patient: DRN

Correspondence

Professor Dr Srilatha Parampalli Srinivas
MD (India)
Department of Pathology
Melaka Manipal Medical College (Manipal campus)
Manipal, Karnataka, 576104
India
Tel: +0091-0820 9740965865
Fax: +91-820 2571905
Email: drsrilatha2003@hotmail.com

References

1. Manganoni AM, Farisoglio C, Lonati A, Zorzi F, Tucci G, Pinton PGC. Cutaneous epithelioid malignant schwannoma: review of the literature and case report. *J plast Reconstr Aesthet Surg*. 2009;**62(9)**:318–321.

2. Miyakoshi N, Nishikawa Y, Shimada Y, Okada K, Yoshida M, Enomoto K, et al. Intraosseous malignant peripheral nerve sheath tumor with focal epithelioid differentiation of the thoracic spine. *Neurol India*. 2007;**55(1)**:64–66.

3. Pfeiffer J, Arapakis L, Boedeker CC, Ridder GJ. Malignant peripheral nerve sheath tumour of the paranasal sinuses and the anterior skull base. *J Craniomaxillofac Surg*. 2008;**36(5)**:293–299.

4. Lee JH, Lee HK, Choi CG, Suh DC, Lee KS, Khang SK. Malignant peripheral nerve sheath tumor in the parapharyngeal space: tumor spread through the eustachian tube. *Am J Neuroradiol*. 2001;**22(4)**: 748–750.

5. Malignant tumors of the peripheral nerves. In: Weiss SW, Goldblum JR, editors. *Enzinger and Weiss's Soft Tissue Tumors*. 5th ed. Philadelphia (PA): Mosby Elsevier; 2008. p. 903–944.

6. Minagawa T, Shioya R, Sato C, Shichinohe R, Yasui G, Ishikawa K, et al. Advanced epithelioid malignant peripheral nerve sheath tumor showing complete response to combined surgery and chemotherapy: a case report. *Case Reports in Oncol Med*. 2011;**2011(1)**:1–5.

7. Rekhi B, Ingle A, Kumar R, DeSouza M, Dikshit R, Jambhekar N. Malignant peripheral nerve sheath tumors: Clinicopathological profile of 63 cases diagnosed at a tertiary cancer referral center in Mumbai, India. *Indian J Pathol Microbiol*. 2010;**53(4)**:611–618.

8. Ueda R, Saito R, Horiguchi T, Nakamura Y, Ichikizai K. Malignant peripheral nerve sheath tumor in the anterior skull base associated with neurofibromatosis type 1. *Neurol Med Chir (Tokyo)*. 2004;**44(1)**:38–42.

9. Gwendolyn JG, Hanan F. Lymph node metastasis of malignant peripheral nerve sheath tumor in the absence of widespread disease five years after diagnosis: a rare finding. *Int J Clin Exp Pathol*. 2010;**3(8)**:812–814.