The Neurohospitalist
2(4) 129-131
© The Author(s) 2012
Reprints and permission:
sagepub.com/journalsPermissions.nav
DOI: 10.1177/1941874412450715
http://nhos.sagepub.com

Acute Loss of Bladder Control in a Stroke of the Frontal Cortex

Heidi Woessner[1], Prasanna Vibhute[1], and Kevin Barrett[1]

Abstract

Lesions of the medial frontal micturition center can result in the activation of the pontine and spinal micturition centers when the bladder is full, causing urinary incontinence. Recognition of acute bladder incontinence as part of a cortical hemispheric stroke syndrome may reduce the likelihood of false localization to the spinal cord in patients with acute ischemic stroke eligible for acute reperfusion therapy. We describe a case of urinary incontinence due to anterior cerebral artery infarction and discuss the cortical localization of voluntary bladder control to the anterior cingulate gyrus, inferior frontal gyrus, middle frontal gyrus, and superior frontal gyrus.

Keywords

stroke, cerebrovascular disorders, cerebrovascular disease, clinical specialty, neurologic manifestations

Introduction

Anterior cerebral artery distribution ischemic stroke is estimated to account for approximately 1% to 2% of all strokes. Bladder incontinence, particularly in combination with leg weakness, often localizes to the spinal cord or cauda equina. Recognition of bladder incontinence as part of the anterior cerebral artery syndrome may expedite the treatment of patients with acute ischemic stroke eligible for reperfusion therapy and reduce the likelihood of false localization to the spinal cord or cauda equina. The purpose of this report is to describe a case of anterior cerebral artery infarction with acute loss of bladder continence and to review the cortical localization of voluntary bladder control to the anterior cingulate gyrus, inferior frontal gyrus, middle frontal gyrus, and superior frontal gyrus.

Case Description

A 65-year-old man with a history of atrial fibrillation, hypertension, hyperlipidemia, and glucose intolerance presented to the emergency department after developing the sudden onset of right leg weakness and numbness with urinary incontinence. He also reportedly had mild right arm weakness and numbness that resolved prior to arrival to the emergency room. He denied loss of consciousness, involuntary movements, or headache. He was not treated with oral anticoagulants. The general physical examination was remarkable for a blood pressure of 161/110 and an irregularly irregular cardiac rhythm suggestive of atrial fibrillation. The neurologic examination was remarkable for drift in the right lower extremity. There was no facial asymmetry, arm weakness, dysarthria, or visual field deficit. The sensory, coordination, and language examinations were normal. The National Institutes of Health Stroke scale score was 1. The noncontrast head computed tomography (CT) demonstrated no hemorrhage or other acute intracranial abnormality. Multimodal CT with angiography demonstrated a filling defect at the A1 segment of the left anterior cerebral artery, suggestive of intraluminal thrombus. There were no contraindications to intravenous recombinant tissue-plasminogen activator (rt-pa), and the patient received 0.9 mg/kg alteplase 1 hour and 46 minutes after symptom onset.

Follow-up brain magnetic resonance imaging (MRI) demonstrated multiple tiny infarctions in both hemispheres, suggestive of a proximal source of embolism (Figure 1A). Most notably, there was an infarction of the left internal frontal hemispheric convexity, corresponding to the frontal micturition area of the somatosensory homunculus (Figure 1B).

Discussion

This case illustrates the localization of the frontal micturition center. Lesions of the bilateral medial frontal micturition center can result in the activation of pontine and spinal

[1] Mayo Clinic Florida, Jacksonville, FL, USA

Corresponding Author:
Heidi Woessner, Mayo Clinic, 4500, San Pablo Road, Jacksonville, FL 32224, USA
Email: woessner.heidi@mayo.edu

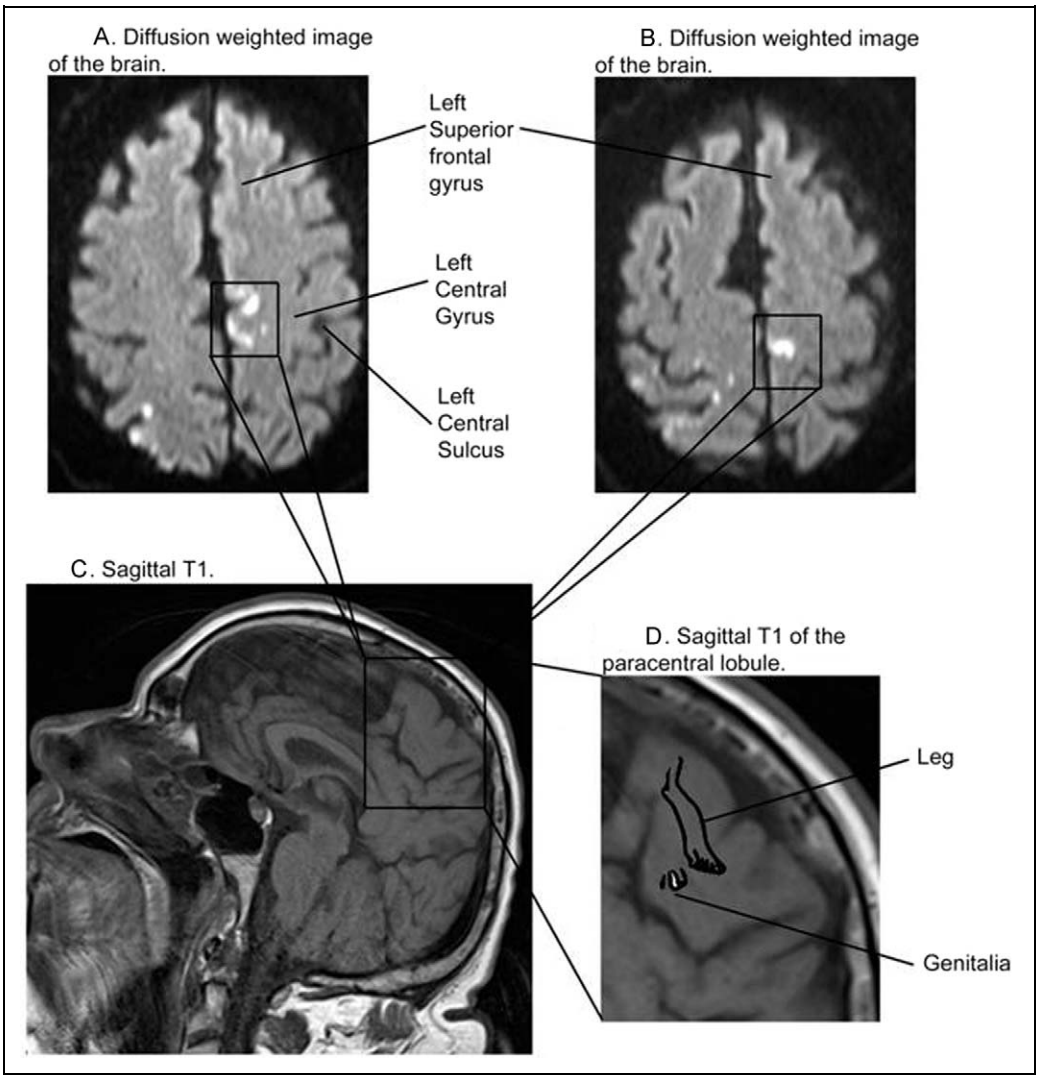

Figure 1. Magnetic resosnce imaging (MRI) without contrast of the brain. Diffusion-weighted image axial demonstrating a hyperintensity in the left central gyrus (A and B). Corresponding sagittal T1with enlargement of the paracentral lobule and overlaying homunculus depicting the leg and genitals (C and D).

micturition centers when the bladder is full, causing urinary incontinence (Figure 2). In normal adults, bladder fullness is sensed and micturition is initiated by medial frontal micturition centers that activate the detrusor reflex, which is mediated by spinal cord circuits regulated by the pontine micturition center.[3] Relaxation of the external urethral sphincter, which is voluntary, leads to inhibition of sympathetics at the bladder neck and activation of parasympathetics, causing detrusor muscle contraction. The flow of urine continues sphincter relaxation and detrusor contraction. When the urine flow stops, the sphincter contracts and the detrusor relaxes.[1]

In a review of the literature, multiple areas of the brain are involved in micturition. Positron emission tomography (PET) scans showed significant activity in the right inferior frontal gyrus and the right anterior cingulate gyrus during voiding.[4] The intended action to urinate was localized to the right inferior frontal gyrus and right anterior cingulate gyrus.[4] This has also been supported by others.[5] Cortical activation within the mid-cingulate cortex and the bilateral frontal lobe has also been noted.[6] In addition, there is increased activity with decreased urge to void at the cingulate cortex and premotor cortex.[6] Others have found multiple other areas of activation during voiding.[7,8] There are reports of transient incontinence associated with damage to the superior prefrontal region. There is more of a correlation of urinary disturbance and hemiparesis with a more anterior brain lesion, as seen in our case.[9] Patients having anterior cortical lesion with bladder disruption have various etiologies as in anterior cerebral artery aneurysms, tumors, or stroke in the mesial frontal lobes.

Conclusion

This case report highlights bladder incontinence as an uncommon manifestation of acute ischemic stroke and describes the neuroanatomical substrate of bladder control. Increased

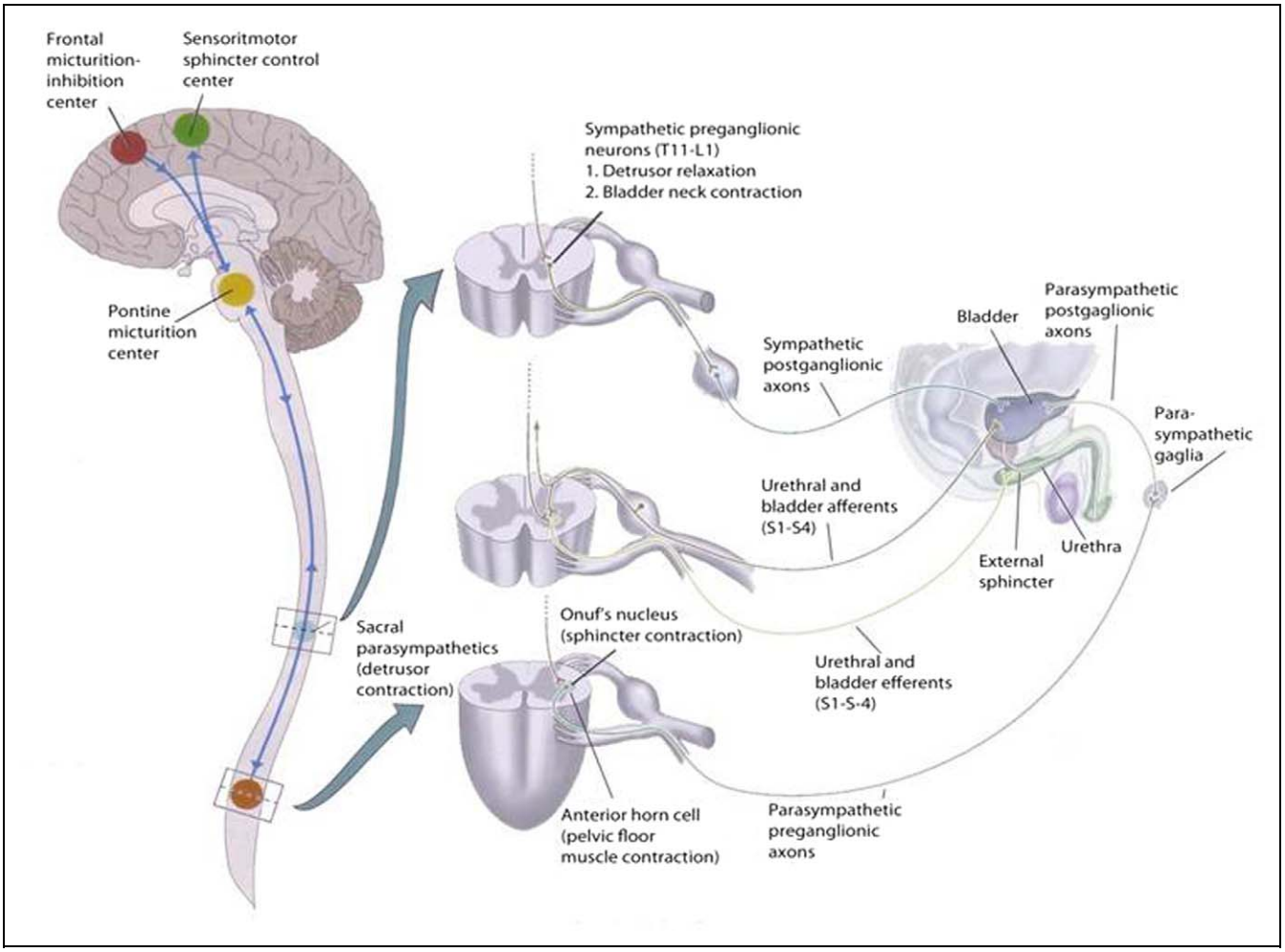

Figure 2. Pathway of the bladder from the cortex at the sphincter control and micturition inhibition center to the pontine micturition center, down the spinal cord to the sympathetics and parasympathetics to its final destination.[1,2]

awareness of the anterior cerebral artery ischemic stroke syndrome may increase rt-PA utilization and reduce the likelihood of false localization in such cases.

Acknowledgment

Special acknowledgment to Jason Williams for his help in creating the figures used in the article.

Declaration of Conflicting Interests

The authors declared no potential conflicts of interest with respect to the research, authorship, and/or publication of this article.

Funding

The authors received no financial support for the research, authorship, and/or publication of this article.

References

1. Blumenfeld H. *Neuroanatomy Through Clinical Cases*. Sunderland, MA: Sinauer; 2002.
2. Purves D. *Neuroscience*. 3rd ed. Sunderland, MA.: Sinauer Associates; 2004.
3. Bradley WG. *Neurology in Clinical Practice*. 5th ed. Philadelphia, PA: Butterworth-Heinemann/Elsevier; 2008.
4. Blok BF, Willemsen AT, Holstege G. A PET study on brain control of micturition in humans. *Brain*. 1997;120(pt 1):111-121.
5. Nour S, Svarer C, Kristensen JK, Paulson OB, Law I. Cerebral activation during micturition in normal men. *Brain*. 2000;123(pt 4):781-789.
6. Athwal BS, Berkley KJ, Hussain I, et al. Brain responses to changes in bladder volume and urge to void in healthy men. *Brain*. 2001;124(pt 2):369-377.
7. Zhang H, Reitz A, Kollias S, Summers P, Curt A, Schurch B. An fMRI study of the role of suprapontine brain structures in the voluntary voiding control induced by pelvic floor contraction. *Neuroimage*. 2005;24(1):174-180.
8. Kuhtz-Buschbeck JP, van der Horst C, Pott C, et al. Cortical representation of the urge to void: a functional magnetic resonance imaging study. *J Urol*. 2005;174(4 pt 1):1477-1481.
9. Fowler CJ. Neurological disorders of micturition and their treatment. *Brain*. 1999;122(pt 7):1213-1231.